

Full-Mouth Rehabilitation for a Patient With Dentinogenesis Imperfecta: A Clinical Report

Sompop Bencharit, DDS, MS, PhD^{1*}
Michael B. Border, BS²
C. Russell Mack, BS²
Warren C. Byrd, BS²
John T. Wright, DDS, MS³

Dentinogenesis imperfecta (DI) is a genetic disorder affecting the structural integrity of the dentin that can result in weakened dentin. The affected teeth, especially posterior teeth, often need to be extracted due to severe wear or fracture. This frequently yields a loss of posterior occlusion and occlusal vertical dimension. Besides wear and fracture, anterior teeth often have an unesthetic appearance because of discoloration. Current treatments of choice, including composite bonding restorations and, more recently, all-ceramic restorations, are typically suggested to preserve the remaining teeth and tooth structure. However, there are a limited number of studies on dental implants in patients with DI. The effectiveness of dentin bonding and dental implants in patients with DI is not known. This clinical report describes a 32-year-old Asian woman with DI who underwent full-mouth rehabilitation. The posterior occlusion, mostly in the molar areas, was restored with dental implants and ceramometal restorations. The anterior teeth and premolars were restored with bonded lithium disilicate glass-ceramic pressed veneers and crowns made with computer-aided design/computer-aided manufacturing. This case demonstrates that restoring functional occlusion and esthetics for a patient with DI can be completed successfully using contemporary implant therapy and adhesive dentistry.

Key Words: all ceramic, dental implants, dentinogenesis imperfecta, full-mouth rehabilitation, veneers

INTRODUCTION

Dentinogenesis imperfecta (DI) type II (OMIM #125490), also known as hereditary opalescent dentin, is a genetic disorder affecting the development of the dentin. The DI condition typically affects both primary and permanent dentition. The prevalence of DI is estimated to be about 1 in 6000 to 8000 people.¹ The DI condition often causes tooth discoloration ranging from an

opalescent blue gray to dark yellow brown. Because of the weakened dentinal structure, patients with DI often present with severely worn dentition, loss of tooth structure, missing teeth, and loss of occlusal vertical dimension. In addition, DI-affected teeth present with short and constricted roots as well as pulpal obliteration due to dentin hypertrophy. Although enamel in patients with DI most often appears normal in thickness and radiopacity, the underlying defective dentin often causes detachment of enamel. Exposed defective dentin is prone to severe wear. Tooth-to-tooth clinical variations due to variable expressivity within a person are common.

The DI condition is classified into 3 types based on the affected dentin and bone. Type I is of the dental phenotype associated with osteogenesis imperfecta (OI) (OMIM #166200), which is most commonly caused by genetic mutations of genes

¹ Department of Prosthodontics, School of Dentistry, and Department of Pharmacology, School of Medicine, University of North Carolina, Chapel Hill, NC.

² Department of Dental Research, School of Dentistry, University of North Carolina, Chapel Hill, NC.

³ Department of Pediatric Dentistry, School of Dentistry, University of North Carolina, Chapel Hill, NC.

* Corresponding author, e-mail: Sompop_Bencharit@dentistry.unc.edu

DOI: 10.1563/AAID-JOI-D-12-00217

associated with collagen type I, COL1A1 and COL1A2.² Type II and type III are associated with mutations in the gene encoding dentin sialophosphoprotein.³⁻⁵ Type III was denoted to describe a phenotype characterized by large pulp chambers that was first characterized in a triracial population from Maryland and Washington, DC.⁴ Type III, also known as the Brandywine isolate,⁴ is caused by mutations in the dentin sialophosphoprotein gene and thus represents a phenotypic variant of DI type II and not a separate entity. Teeth affected with DI type I or type II can have large pulp chambers in young people; however, the chambers become diminished and appear obliterated radiographically over time.⁴

Histologically, DI-affected dentin typically has a layer of normal mantle dentin that often appears to develop more normally compared with the circumpulpal dentin. The circumpulpal dentin is characterized by a diminution in the number of abnormalities in the structure of dentin tubules and atubular dentin. Although DI affects the dentin structure, the enamel structure and dentinoenamel junction are often normal. Loss of enamel is, therefore, often a consequence of compositionally and structurally defective dentin that has an altered modulus of elasticity and not defects in enamel structure or dentinoenamel junction.^{3,6}

Treatments for patients with DI can be complex and difficult depending on the severity of enamel fracturing, attrition, and pulpal involvement. Teeth affected with DI are not prone to dental caries compared with normal teeth and this is thought to be a result of severe wear, which tends to progress faster than caries. As a result, patients with DI often present with missing teeth and loss of vertical dimension.^{3,7} In addition, in DI type I, multiple bone fractures can propagate skeletal defects and complicate treatments. Although little is known about the effectiveness of dentin bonding agents on DI-affected teeth, several clinical reports show that DI-affected teeth can be restored with composite resin veneers and bonded restorations, which may in part result from enamel-composite bonding not necessarily dentin-composite bonding.⁸⁻¹⁰ Missing teeth due to wear and fracture often require extensive prosthodontic rehabilitation and, in some cases, preprosthodontic orthodontic treatment. Pulpal obliteration (in DI type I

and II) or large pulp chamber (in DI type III) as well as the restorability of the remaining tooth structure can present challenges to endodontic therapy and restoration of these teeth after endodontic treatment.¹¹ Dental implant therapy can be a viable treatment option for nonrestorable DI-affected teeth. In addition, bonded all-ceramic restorations may be a conservative treatment option for teeth with sufficient structure.

In this article, we present treatments for a patient with DI type II who presented with severely worn dentition, loss of occlusal vertical dimension (OVD), and missing multiple teeth. We used dental implants to replace missing teeth and to help restore the posterior occlusion and OVD. Full-mouth reconstruction was performed using bonded porcelain veneers, all-ceramic crowns, and ceramometal restorations.

PRETREATMENT ASSESSMENTS

Chief complaint and patient's history

A 33-year-old Asian woman presented with her chief complaint being, "My teeth are soft. They are easily broke. I have to have fillings redone all the time." The patient reported that she inherited her dental condition from her father. All her father's siblings and their children had the same dental condition, but her mother had normal teeth. Her older sister (and only sibling), and her niece were also affected. She reported that there was no history of bone fragility or fractures in her family. She was in good health except for high blood pressure, hyperlipidemia, and attention deficit disorder. She reported no tobacco or alcohol use. She reported that she had always had yellowish-brown teeth since she was a child. She had had her fillings replaced several times since she was a child. She had lost several teeth due to fracture associated with occlusal trauma. She reported that there was no problem associated with tooth extraction, and she seemed to have normal healing. About 5 years ago she had a fixed partial denture (FPD) made for teeth #11-13 to replace tooth #12. She also reported that she often had a hard time opening her mouth during dental procedures and often had temporomandibular joint (TMJ) pain. She had not seen a dentist for 2 or 3 years.

Clinical findings

The patient had no muscle tenderness or palpable nodes. Her maximal opening at the incisal edge was about 35 mm. However, she could not keep her mouth open for more than 2 or 3 minutes at a time. She reported tenderness on both TMJs. Clicking was found on both TMJs during her condylar translation. Overall, soft tissues of the lips, cheeks, tongue, oral mucosa, and pharyngeal tissues were within normal limits. The saliva was thin and serous. An examination of the hard tissue revealed that all her teeth appear to have dark yellowish-brown opalescent discoloration.

Intraoral examination showed extensive composite resin restorations for the anterior teeth. She had multiple missing posterior teeth. The remaining posterior teeth were restored with composite resin or amalgam; however, most of the restorations were fractured or defective. The color, size, texture, and contour of the maxillary and mandibular gingiva were within normal limits. Mild generalized plaque and calculus deposits were found mostly on the mandibular anterior and maxillary posterior teeth (in the fracture areas). Probing depth was 1 to 3 mm with minimal bleeding on probing (around maxillary fixed partial denture retainers). Adequate attached gingiva was present. Tooth mobility was normal. Occlusal analysis (Figure 1) demonstrated that her occlusion in maximal intercuspal position was shifted about 1 mm from forward right to left from the centric occlusion position. Her anterior occlusal plan tilted slightly downward on the right compared with the left. Her dental midline was tilted slightly to the right as well. The mandibular incisors were worn. The patient appeared to have right-side Class I occlusion and left-side Class III occlusion based on the position of her canines. She had a mutually protected occlusion in lateral excursion. No balancing contact was found. The maxillary anterior teeth and premolars appeared to flare out facially. In the early protrusive movement, there were contacts between all of her maxillary anterior teeth and mandibular anterior teeth and first premolars.

Radiographic findings (Figure 1) suggested that the trabecular bone pattern was generally normal. However, the bone appeared to be denser than normal. Note that bone in DI commonly looks denser because the observer's eye is used to contrasting it with normal dentin. In this case the

roots are radiolucent because they are poorly mineralized, so in contrast bone looks dense. The crown to root ratio ranged from 1:1 to 1:2. All the patient's teeth appeared to have bulbous crowns with a constricted cervical area. The remaining enamel appeared to have normal radiographic density. All her teeth appeared to have pulpal obliteration because of dentin hypertrophy. Note also that there was resorption of condylar head suggesting an osteoarthritic condition.

DIAGNOSIS

In addition to DI type II, the following diagnoses were made: generalized mild gingivitis; fracture at teeth #3, 17, 20, and 29; defective restorations at #3, 4, and 11–13; and Prosthodontic Index Classification IV. The patient was referred to a geneticist to identify the genetic mutations of DI associated with OI to see if her bone may be affected because, if so, it could have an adverse effect on implant therapy. However, no known genetic mutations associated with OI were identified.

TREATMENT PLAN

The following treatment plan was presented to the patient and discussed in detail before any treatment. Risks, alternatives, and benefits of treatment were explained. Informed consent was obtained before treatment. In the control phase, we planned to do scaling and root planning; provide oral hygiene instructions; extract teeth #17 and 32; and replace teeth #18, 19, 30, 31, and 12 with dental implants. An occlusal splint was provided (1) to evaluate the patient's tolerance of an increase of about 2 mm in the vertical dimension of occlusion in the posterior area and (2) to relax the muscles to provide a more accurate centric relation. In the definitive phase, for the maxillary arch we planned to fabricate fixed prosthodontic restorations, including ceramometal crowns for teeth #3, 4, 5, 13, and 14; a customized abutment/all-ceramic crown for tooth #12; and all-ceramic crowns for teeth #6, 7, 8, 9, 10, and 11. In the mandibular arch, the definitive plan included all-ceramic crowns for teeth # 20, 21, 28, and 29; implant-support splinted crowns for teeth #18, 19, 30, and 31. In the maintenance phase, we planned to fabricate a

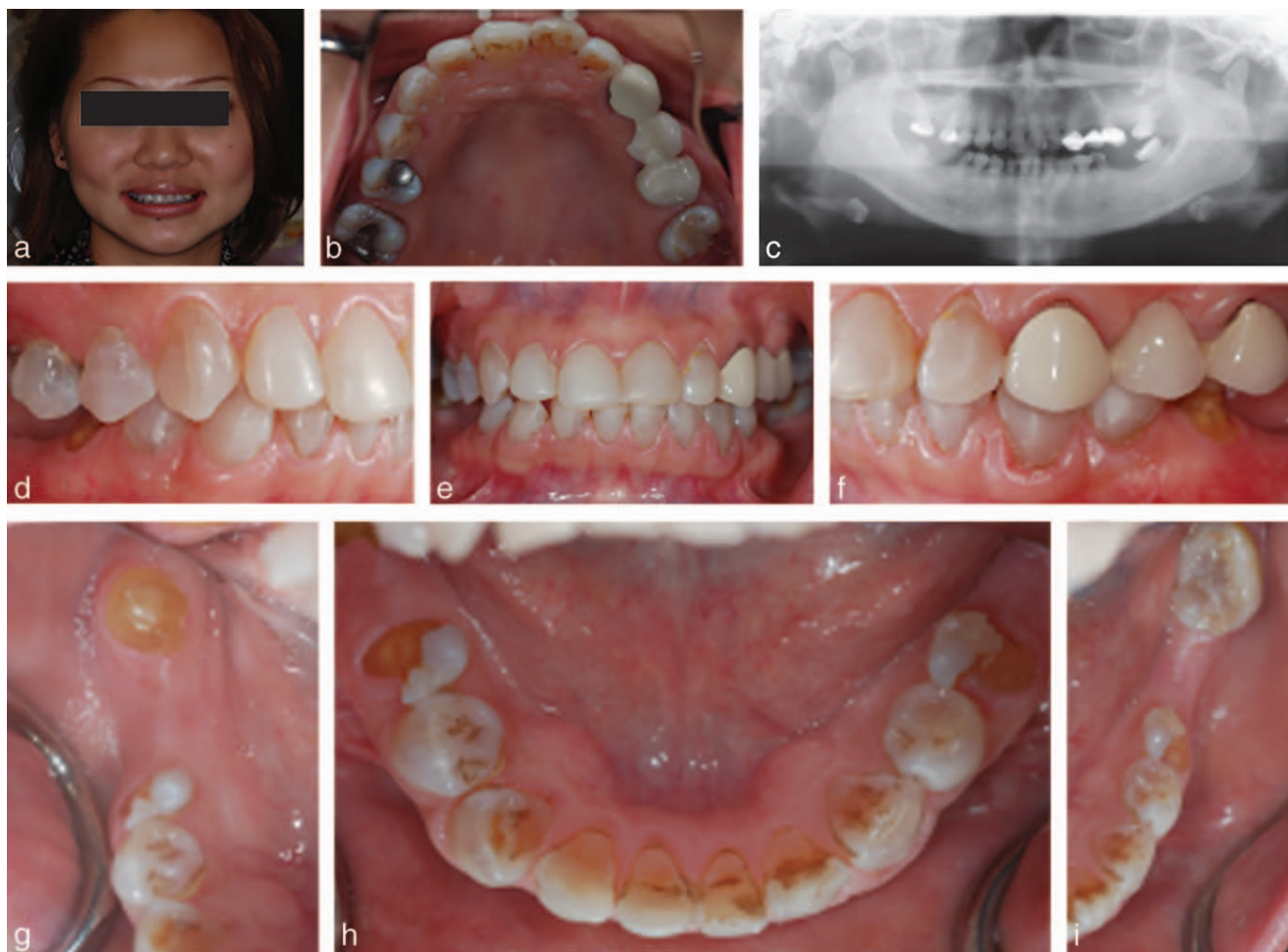

FIGURE 1. Pretreatment assessment. (a) Extra-oral photograph. (b) Maxillary arch. (c) Panoramic radiograph. (d) Right occlusion in maximal intercuspital position (MIP). (e) Front occlusion in MIP. (f) Left occlusion in MIP. (g) Mandibular right posterior. (h) Mandibular anterior teeth and premolars/ (i) mandibular left posterior.

maxillary occlusal splint and establish a periodontic and prosthodontic recall schedule.

TREATMENTS
Control phase

After the scaling and root planing and occlusal splint therapy, a diagnostic wax-up (Figure 2) was made from the patient’s study casts mounted in the semiadjustable articulator at the increased OVD. Nonrestorable teeth, #17 and 32, were extracted. Puros demineralized bone matrix (Zimmer Dental Inc, Carlsbad, Calif) was used to preserve the socket. About 4 months after extraction, 4 dental implants, TSV Zimmer implants with MTX surface and polished collar (Zimmer Dental Inc) were placed: 4.7 × 8.0 mm for teeth #30 and 31 sites and 3.7 ×

10.0 mm for teeth #18 and 19 sites. The implants were placed at the tissue level. Because of the patient’s limited mouth opening, the implants were tilted mesially. While the mandibular implants were healing, all her remaining teeth were prepared, and provisional restorations were fabricated at the increased OVD (Figure 3). A dental implant, 4.1 × 11.5 mm Zimmer TSV implant (Zimmer Dental Inc) was placed in the tooth #12 site.

Definitive phase

Because of the patient’s hypertensive condition, work schedule, availability, and financial concerns, it was decided to first restore the mandibular arch and then the maxillary arch (Figure 4). The mandibular implants at teeth #18, 19, 30, and 31 were restored with titanium custom abutments (Atlantis, Dentsply, York, Pa) and splinted ceramometal crowns. The

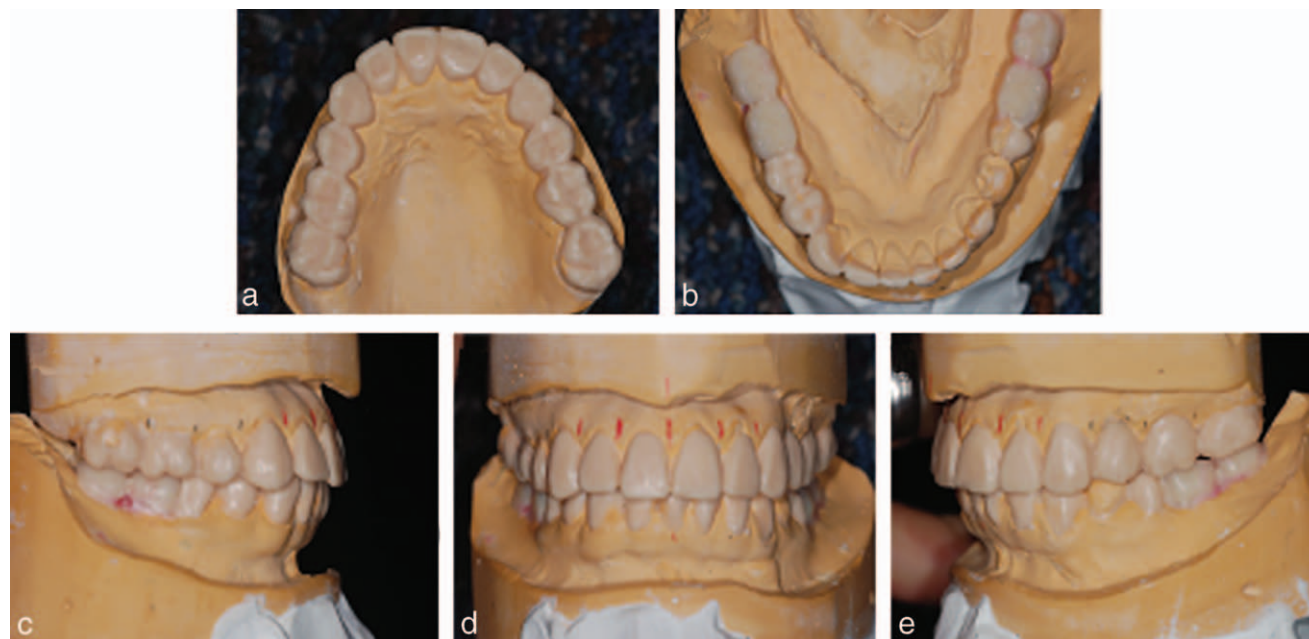
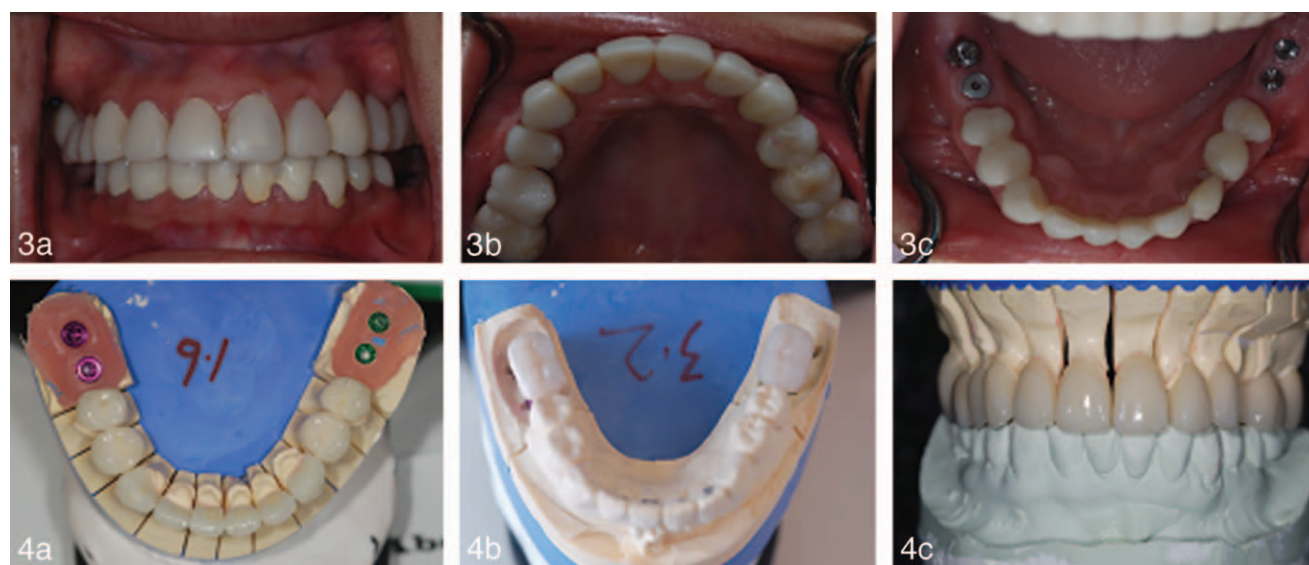


FIGURE 2. Diagnostic wax-up: Pretreatment study casts were used to fabricate a diagnostic wax-up at the centric relation (CR) position with increased occlusal vertical dimension. (a) Maxillary occlusal view. (b) Mandibular occlusal view. (c) Right view in occlusion. (d) Frontal view in occlusion. (e) Left view in occlusion.

ceramometal crowns were luted with glassionomer cement (Ketacem, GC America, Alsip, Ill). The mandibular premolars and anteriors were restored with lithium disilicate glass-ceramic crowns made with computer-aided design/computer-aided manufacturing (CAD/CAM) techniques (IPS Emax, Ivoclar

Vivadent, Amherst, NY) and pressed veneers (IPS Empress II, Ivoclar Vivadent), respectively. The all-ceramic restorations were bonded with composite resin cement (Variolink II, Ivoclar Vivadent). The maxillary posterior teeth (#2, 3, 4, 13, and 14) were restored with ceramometal crowns luted with



FIGURES 3 AND 4. **FIGURE 3.** Provisional Prostheses fabricated based on the diagnostic wax-up at increased occlusal vertical dimension were used for 12 weeks. (a) Frontal, (b) maxillary occlusal, and (c) mandibular occlusal views. **FIGURE 4.** Fabrication of the definitive prostheses. Because of the delayed placement of implant #12, the mandibular prostheses were fabricated first based on the patient's provisional prostheses (a and b). The maxillary prostheses (c) were then fabricated after the #12 implant healed.

Ketacem glassionomer cement. Implant #12 was restored with Zirconia abutment (Atlantis, Dentsply). Maxillary anterior teeth and implant abutment #12 were restored with lithium disilicate glass-ceramic all-ceramic crowns (IPS Emax, Ivoclar Vivadent) luted with composite resin cement (Variolink II, Ivoclar Vivadent). After the placement of all restorations (Figure 5), an occlusal splint was fabricated. The patient was instructed to wear the occlusal splint nightly to prevent fracture of the restorations. Oral hygiene instruction was reinforced. High fluoride toothpaste (Provident 5000, Colgate, New York, NY) and casein phosphate amorphous calcium phosphate paste (MI paste, GC America) was prescribed to prevent future secondary dental caries. The patient was also placed on a 6-month hygiene recall.

DISCUSSION

In this article, we present treatments for a patient with DI type II who presented with severely worn dentition, multiple defective and unesthetic restorations, loss of OVD, and missing multiple teeth. We used dental implants to replace missing teeth and to help restore the posterior occlusion and OVD. Full-mouth reconstruction was performed using all-ceramic veneers and crowns as well as ceramometal restorations.

Treatments for patients with DI can be complex because of the loss of tooth structure and missing teeth. Full-arch splinted ceramometal crowns and FPDs were recommended by Bouvier et al.¹² Henke et al¹³ described a patient with DI who underwent full-mouth reconstruction using dental implants in the mandible while preserving natural teeth in the maxilla. They restored the implants and natural teeth with full-arch splinted ceramometal crowns for the maxilla and 2 mandibular ceramometal FPDs in the mandible. It is important to rule out OI because it can further complicate treatments, especially for placement of dental implants. Binger et al¹⁴ demonstrated that with complex multiple surgical procedures, including osteodistraction, bone augmentation, and dental implant therapy, oral rehabilitation can be done with dental implants in patients with OI. Prabhu et al¹⁵ also show that long-term success of dental implants is not affected by the OI condition. However, in the current patient there were no known genetic mutations associated

with OI. Note that in this case the patient had no history of defects in bone metabolism. However, we found that she had osteoarthritis of the TMJ and other joints. Her TMJ condition resulted in limited opening and TMJ pain during dental procedures. Placement of dental implants was challenging because the patient could not open her mouth wide enough and had to close her jaw periodically during each dental procedure. In addition, we had to postpone the implant placement for the #12 area because of her hypertension. It is important to note that some patients with OI have problems with hypercholesterolemia and hypertension.¹⁶ Prabhu et al¹⁵ reported similar hypertensive conditions in a patient with OI. Hypertension in patients with DI and OI may need to be controlled by the patient's physician before implant placement. In addition, although our patient had no known OI-associated genetic mutations, she might have a mild form of OI similar to those reported by Stephen and Beighton.¹⁷

Several previous reports seem to suggest the use of composite resin and amalgam build-up to restore DI-affected teeth.¹⁸ Goud and Deshpande¹⁹ combined the use of acrylic facing base metal restorations in the maxilla and mandibular overdenture to restore a patient with DI. Knezevic et al⁹ used direct composite veneers similar to the treatment our patient had received as a young adult before she presented to us. Pattiette et al¹¹ suggested that endodontic treatments may be difficult in patients with DI because of the obliteration of the pulp and the defects in dentin mineralization. Although most case reports describe attempts to keep the natural dentition,^{12,13} Dam et al²⁰ demonstrated the use of implant-supported fixed complete dentures in a patient with DI.

Depending on how extensive the DI condition is, the remaining tooth structure can be severely compromised, which can lead to compromised bonded restorations, such as veneers or all-ceramic restorations. An *in vitro* scanning electron microscope study suggested that DI affects dentin structure, which may compromise resin bonding.²¹ This case report demonstrates that extensively bonded restorations, including CAD/CAM-manufactured lithium disilicate glass-ceramic veneers and crowns, can be used successfully in teeth affected by DI. Bartlett²² reported reasonable success with

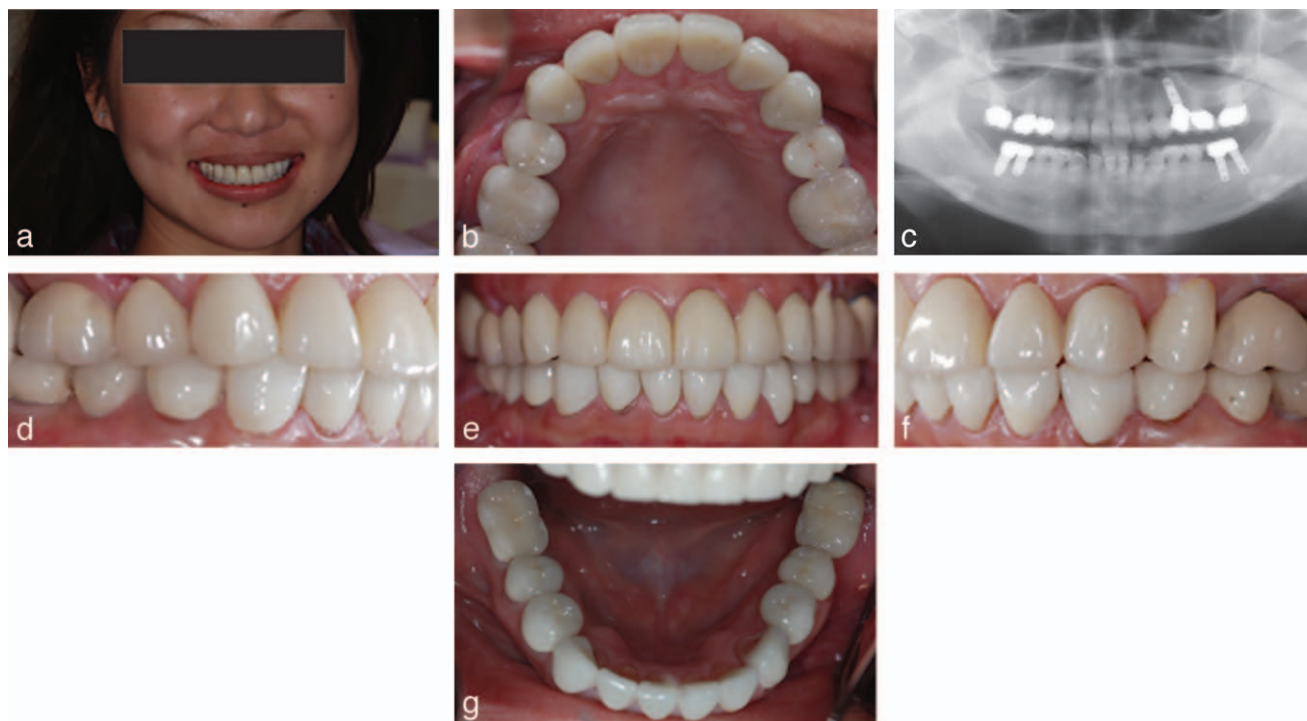

FIGURE 5. Definitive prostheses. In the maxillary arch, teeth #3, 4, 5, 13, and 14 were restored with ceramometal crowns, and teeth #6, 7, 8, 9, 10, and 11 were restored with all-ceramic lithium disilicate glass-ceramic crowns made using computer-aided design/computer-aided manufacturing (CAD/CAM) techniques; implant #12 was restored with a Zirconia CAD/CAM milled abutment and an all-ceramic lithium disilicate glass-ceramic crown CAD/CAM. In the mandibular arch, implants #18, 19, 30, and 31 were restored with titanium custom CAD/CAM abutments and splinted ceramometal crowns; teeth #20, 21, 28, and 29 were restored with all-ceramic lithium disilicate glass-ceramic CAD/CAM crowns; and teeth #22, 23, 24, 25, 26, and 27 were restored with all-ceramic lithium disilicate glass-ceramic pressed veneers.

bonded restorations in 3 patients with DI over a 10-year period. Within the limitations of this report, it seems that the bonding was not compromised from the dentin defect resulting from DI. Similar case reports have suggested that bonded all-ceramic restorations, especially CAD/CAM-manufactured all-ceramic restorations, can be used successfully in patients with DI.^{23–25}

SUMMARY

This case report combines the use of dental implants to restore the missing teeth and to establish posterior occlusal support with the use of bonded all-ceramic restorations to improve the anterior guidance and esthetics. Studies on the effectiveness of dentin bonding and implant restorations in the DI population are limited. Dental implants can be useful in full-mouth rehabilitation for patients with DI similar to other DI patient types that lose OVD and posterior occlusal support.^{13,26–27} Patients with DI can

exhibit a wide range of clinical features; therefore, clinicians need to use their own judgment in selecting materials and treatments that are appropriate on a case-by-case basis. A long-term clinical study is needed to establish treatment protocol for patients with DI in terms of bonding restorations and dental implant therapy.

ABBREVIATIONS

CAD/CAM: computer-aided design/computer-aided manufacturing

DI: dentinogenesis imperfecta

FPD: fixed partial denture

OI: osteogenesis imperfecta

OVD: occlusal vertical dimension

TMJ: temporomandibular joint

ACKNOWLEDGMENTS

The dental implants were provided through a University Educational Grant sponsored by Zimmer

Dental Inc. However, the funder had no role in the clinical diagnosis or treatment. The research was also partly supported by the American Academy of Implant Dentistry Research Foundation.

REFERENCES

1. Witkop CJ Jr. Manifestations of genetic diseases in the human pulp. *Oral Surg Oral Med Oral Pathol.* 1971;32:278–316.
2. Prockop DJ, Kivirikko KI. Heritable diseases of collagen. *N Engl J Med.* 1984;311:376–386.
3. Malmgren B, Lindskog S, Elgadi A, Norgren S. Clinical, histopathologic, and genetic investigation in two large families with dentinogenesis imperfecta type II. *Hum Genet.* 2004;114:491–498.
4. Dong J, Gu T, Jeffords L, MacDougall M. Dentin phosphoprotein compound mutation in dentin sialophosphoprotein causes dentinogenesis imperfecta type III. *Am J Med Genet A.* 2005;132A:305–309.
5. Rajpar MH, Koch MJ, Davies RM, Melody KT, Kiely CM, Dixon MJ. Mutation of the signal peptide region of the bicistronic gene DSPP affects translocation to the endoplasmic reticulum and results in defective dentine biomineralization. *Hum Mol Genet.* 2002;11:2559–2565.
6. Shields ED, Bixler D, el-Kafrawy AM. A proposed classification for heritable human dentine defects with a description of a new entity. *Arch Oral Biol.* 1973;18:543–553.
7. Kim JW, Nam SH, Jang KT, et al. A novel splice acceptor mutation in the DSPP gene causing dentinogenesis imperfecta type II. *Hum Genet.* 2004;115:248–254.
8. Kim JW, Simmer JP. Hereditary dentin defects. *J Dent Res.* 2007;86:392–399.
9. Knezevic A, Tarle Z, Panduric V. Esthetic reconstruction of teeth in patient with dentinogenesis imperfecta—a case report. *Coll Antropol.* 2006;30:231–234.
10. Huth K, Paschos E, Sagner T, Hickel R. Diagnostic features and pedodontic-orthodontic management in dentinogenesis imperfecta type II: a case report. *Int J Paediatr Dent.* 2002;12:316–321.
11. Pettiette MT, Wright JT, Trope M. Dentinogenesis imperfecta: endodontic implications. Case report. *Oral Surg Oral Med Oral Pathol Oral Radiol Endod.* 1998;86:733–737.
12. Bouvier D, Duprez JP, Morrier JJ, Bois D. Strategies for rehabilitation in the treatment of dentinogenesis imperfecta in a child: a clinical report. *J Prosthet Dent.* 1996;75:238–241.
13. Henke DA, Fridrich TA, Aquilino SA. Occlusal rehabilitation of a patient with dentinogenesis imperfecta: a clinical report. *J Prosthet Dent.* 1999;81:503–506.
14. Binger T, Rucker M, Spitzer WJ. Dentofacial rehabilitation by osteodistraction, augmentation and implantation despite osteogenesis imperfecta. *Int J Oral Maxillofac Surg.* 2006;35:559–562.
15. Prabhu N, Duckmanton N, Stevenson AR, Cameron A. The placement of osseointegrated dental implants in a patient with type IV B osteogenesis imperfecta: a 9-year follow-up. *Oral Surg Oral Med Oral Pathol Oral Radiol Endod.* 2007;103:349–354.
16. Jones AC, Baughman RA. Multiple idiopathic mandibular bone cysts in a patient with osteogenesis imperfecta. *Oral Surg Oral Med Oral Pathol.* 1993;75:333–337.
17. Stephen LX, Beighton P. Dental management of severe dentinogenesis imperfecta in a mild form of osteogenesis imperfecta. *J Clin Pediatr Dent.* 2002;26:131–136.
18. Eerikainen E. Prosthetic treatment of dentinogenesis imperfecta. A case report. *J Oral Rehabil.* 1981;8:97–102.
19. Goud A, Deshpande S. Prosthodontic rehabilitation of dentinogenesis imperfecta. *Contemp Clin Dent.* 2011;2:138–141.
20. Dam HG, Papaspyridakos P, Chen CJ, et al. Comprehensive oral rehabilitation of a patient with dentinogenesis imperfecta. *J Periodontol.* 2011;1:16–22.
21. Gallusi G, Libonati A, Campanella V. SEM-morphology in dentinogenesis imperfecta type II: microscopic anatomy and efficacy of a dentine bonding system. *Eur J Paediatr Dent.* 2006;7:9–17.
22. Bartlett DW. Three patient reports illustrating the use of dentin adhesives to cement crowns to severely worn teeth. *Int J Prosthodont.* 2005;18:214–218.
23. Moundouri-Andritsakis H, Kourtis SG, Andritsakis DP. All-ceramic restorations for complete-mouth rehabilitation in dentinogenesis imperfecta: a case report. *Quintessence Int.* 2002;33:656–660.
24. Groten M. Complex all-ceramic rehabilitation of a young patient with a severely compromised dentition: a case report. *Quintessence Int.* 2009;40:19–27.
25. Edelhoff D, Brix O. All-ceramic restorations in different indications: a case series. *J Am Dent Assoc.* 2011;142(suppl 2):145–195.
26. Bencharit S, Misiek D, Simon L, Malone-Trahey A. Full mouth rehabilitation with dental implants for a patient with skeletal class III malocclusion: a case report. *J Oral Implantol.* 2012;38:63–70.
27. Bencharit S, Schardt-Sacco D, Border MB, Barbaro CP. Full mouth rehabilitation with implant-supported prostheses for severe periodontitis: a case report. *Open Dent J.* 2010;4:165–171.