

# Implant-Supported Full-Mouth Restoration in a Young Patient With Generalized Aggressive Periodontitis

Cenker Zeki Koyuncuoglu, DDS, PhD<sup>1\*</sup>

Kerem Calisir, DDS<sup>2</sup>

Isil Saylan, DDS, PhD<sup>3</sup>

Zeynep Yassibag, DDS, PhD<sup>3</sup>

Suleyman Metin, DDS, PhD<sup>3</sup>

Ozen Tuncer, DDS, Prof Dr<sup>3</sup>

Alpdogan Kantarci, DDS, PhD<sup>4</sup>

## INTRODUCTION

**A**ggressive periodontitis is characterized by rapid loss of attachment and destruction of the periodontal ligament and bone in otherwise systemically healthy individuals.<sup>1</sup> Patients with generalized aggressive periodontitis (GAgP) demonstrate proximal attachment loss affecting at least 3 teeth other than the first molars and incisors. These patients are usually young individuals under 30 years of age with familial aggregation<sup>2</sup> and a high tendency toward recurrence.<sup>1</sup> The major challenge in treating the individuals with GAgP is the edentulism at a very young age when removable prosthetic restorations are usually not favored by the patients. Dental implant-supported restorations present a viable treatment option in young patients with edentulism, restoring masticatory function, phonetics, and esthetics. Yet, there is a controversy on the use of dental implants in GAgP patients; the evidence is limited and literature is inconclusive on the long-term outcomes of implant therapy.<sup>3</sup> In one such study for example, implants were placed in fully edentulous maxilla and partially edentulous mandible. Continuous abscess formation was observed and 3 of the maxillary implants and 1 of the mandibular implants were removed within 2 months of insertion.<sup>4</sup> The success rate of dental implants in patients previously treated for GAgP was approximately 10% below that of patients with a history of generalized chronic adult periodontitis.<sup>5</sup> While the success rate could be acceptably high, the possibility of continuous attachment and bone loss occurring around the implants placed in the GAgP patients could not be ruled out. Thus, the controversy continues and new studies with new methodologies to evaluate and define "success" are needed. The following case illustrates the rehabilitation of a young patient with dental implants.

## CASE DESCRIPTION

A 23-year-old female patient was referred to Department of Periodontology, Faculty of Dentistry, University of Istanbul with symptoms of pain, bleeding, and swelling of the gingiva, halitosis, and extensive mobility of teeth. The patient was a nonsmoker and did not present any systemic health problems. Marginal gingiva appeared edematous and extensive bleeding was noted (Figure 1a). Initial clinical evaluation and the panoramic radiography illustrated severe and generalized bone resorption especially around the posterior teeth (Figure 1b). Detailed periodontal examination showed that bleeding and plaque scores were 100% with supra- and subgingival calculus deposition. The probing depths ranged between 4 and 11 mm (Table 1). Multiple teeth presented with extensive mobility and pathological tooth migration was observed on the anterior teeth. The results of blood count, blood glucose, HbA1c, acid and alkaline phosphatase levels were in normal ranges (Table 2). PCR-based (Eppendorf, Mastercycler Personal, Hamburg, Germany) microbial analyses showed the presence of *Porphyromonas gingivalis* and *Treponema denticola* in microbial dental plaque. Clinical and radiographical examination and microbial analyses led to the diagnosis of generalized aggressive periodontitis.

Cone beam computerized tomography (NewTom 9000 CBCT, Verona, Italy) was used to analyze the tissue architecture and implant planning (Figure 1c). Initial stage of the therapy included extraction of the unsalvageable teeth, systemic antibiotic therapy (amoxicillin, 500 mg, 125 mg clavulanic acid-3 × 1 + metronidazole, 500 mg-3 × 1; Augmentin, GSK, Gebze, Turkey, and Flagyl, Eczacibasi Rhone Poulenc Pharmaceutical Marketing Co, Istanbul, Turkey), and scaling and root planing (Figure 1d). Detailed oral hygiene instructions were given. Temporary immediate prosthesis were prepared for maxilla and mandible. At this initial stage, we have used a staged extraction approach in order to provide support for the placement of immediate dentures (Figure 1e). Therefore, teeth numbered 17, 15, 28, 38, and 48 were kept even with a minimal bone support.

Definitive treatment plan included fabrication of mandibular and maxillary implant supported-bar retained overdentures. In order to avoid further bone loss after the extractions, we have used a delayed immediate implant placement

<sup>1</sup> Department of Periodontology, Faculty of Dentistry, Istanbul Aydin University, Istanbul, Turkey.

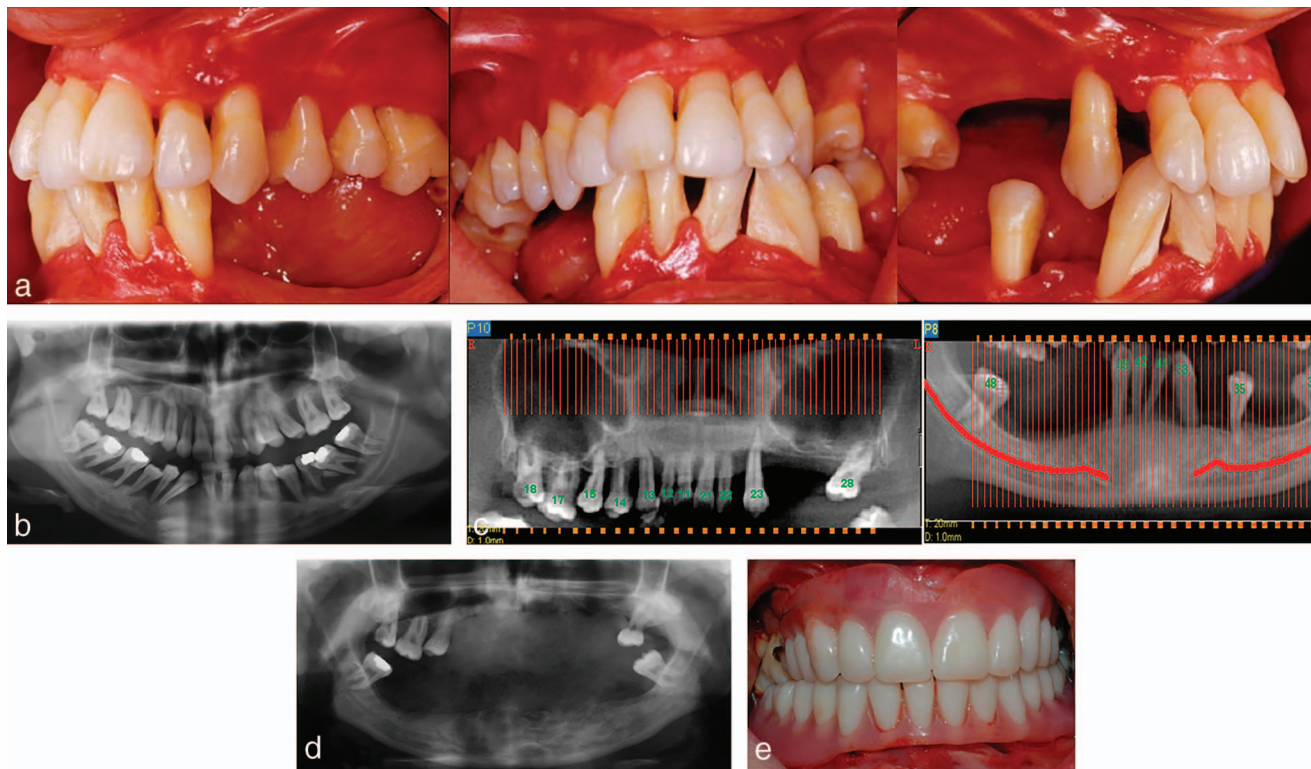
<sup>2</sup> Department of Prosthodontics, Faculty of Dentistry, Istanbul University, Istanbul, Turkey.

<sup>3</sup> Department of Periodontology, Faculty of Dentistry, Istanbul University, Istanbul, Turkey.

<sup>4</sup> Forsyth Institute, Department of Applied Oral Sciences, Center for Periodontology, Cambridge, Mass.

\* Corresponding author, e-mail: cenker.k@gmail.com

DOI: 10.1563/AAID-JOI-D-12-00226



**FIGURE 1.** (a) Preoperative intra-oral view. (b) Initial panoramic radiography. (c) Cone beam computerized tomography (maxilla-mandibula). (d, e) First extraction session and immediate dentures.

approach. One month after the extractions, 4 implants (Brånemark System, MkIII TiU, Nobel Biocare, Göteborg, Sweden) were placed in maxilla and 4 implants were placed in mandible anterior at 35 N torque. After 6 months, the healing abutments were connected and teeth numbered 18, 17, and 15 were extracted (Figure 2a, b, c). At this stage, provisional dentures were further modified. For the final construction of the restorations, individual trays were fabricated and impressions were taken with polyvinyl siloxane (Affinis, Putty Soft and Affinis, Regular Body Microsystem, Coltène/Whaledent GmbH + Co. KG Langenau, Germany) using an open-tray technique. Wax and metal framework try-in for the maxilla and mandibula were prepared (Figure 2d, e). In order to improve the esthetic results, light-cured microfilled composite resin (Gradia Indirect, GC America Inc, Alsip, Ill) combined with composite gingival material (GC Gradia Gum, GC America Inc) were used.

Completion of the restorations is shown in Figure 2f and Figure 2g.

A daily maintenance care was instructed with an interdental brush (Curaprox Soft Implant Brush CPS 508, Curaden Swiss, Istanbul, Turkey), superfloss (Curaprox Bridge & Implant Floss DF844, Curaden Swiss) and a single toothbrush (Curaprox Single CS 1009, Curaden Swiss). Professional maintenance program was instituted with periodontal and peri-implant recall visits every 3 months following delivery of the implant supported overdentures. Periodontal and peri-implant conditions were stable over a 24-month follow-up period (Figure 3a, b)

**DISCUSSION**

Aggressive periodontitis presents great challenges in treatment and prosthodontic rehabilitation. The remaining dentition is often compromised and prevents sufficient retention of fixed or

TABLE 1

The probing depths†

	8	6	5	4	3	2	1	1	2	3	4	5	6	8	
V	1 1 4	* 1 5 5 2 *	9 4 *	* 6 *	8 5 5 5 5 5 6 4 9 8 8 *	* 5 8									6 4 2
P	1 7 *	9 5 9 5 6 9 9 8 *	* * *	6 6 4	5 5 5 7 9 7 9 8 8	9 8 8									5 5 5
L	2 2 4			4 5 5	4 4 5 1 1 1					2 1 7		5 5 5		2 2 5	
V	2 2 3			4 1 9	9 5 9 2 3 3					5 2 7		4 3 3		5 4 4	
	8	6	5	4	3	2	1	1	2	3	4	5	6	8	

\*≥ 10 mm.

†TV indicates vestibule; L, lingual; P, palatine.

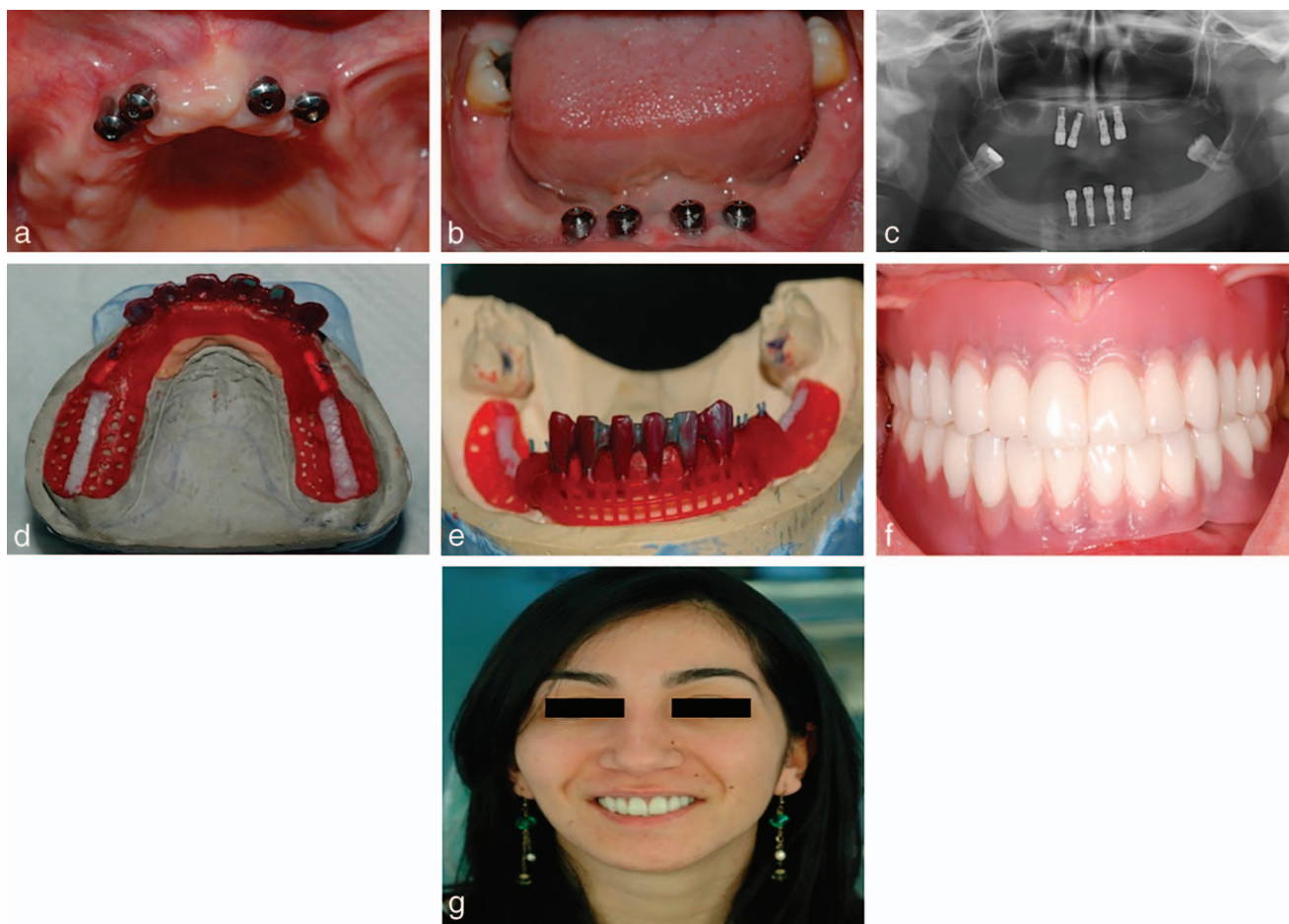
TABLE 2  
Blood parameters

Tests		Reference Unit
Leukocyte	6.0 K/uL	4.0–10.0 K/uL
Leucosite	2.0 K/uL	0.6–5.2 K/uL
Red blood cell	4.16 M/uL	4.00–6.00 M/uL
Hemoglobin	13.1 M/uL	12.0–18.0 M/uL
Hematocrit	% 32.6	% 35.0–50.0
Glucose	89 mg/dL	70–110 mg/dL
HbA1C	% 5.1	% 4.5–5.7
Alkaline phosphatase	106 U/L	90–290 U/L
Acid phosphatase	2 U/L	< 5.4 U/L

removable partial dentures. In GAgP patients, an interdisciplinary approach is essential to evaluate, diagnose, and restore the function and esthetic problems. Such treatment plans require extensive planning and careful execution at every stage utilizing a combination of prosthodontic and periodontic treatments. A close collaboration between dental professional is critical. Only a few studies<sup>5–9</sup> or case reports<sup>4,10–14</sup> and one review<sup>15</sup> have been published regarding the treatment of patients with aggressive periodontitis using dental implants.

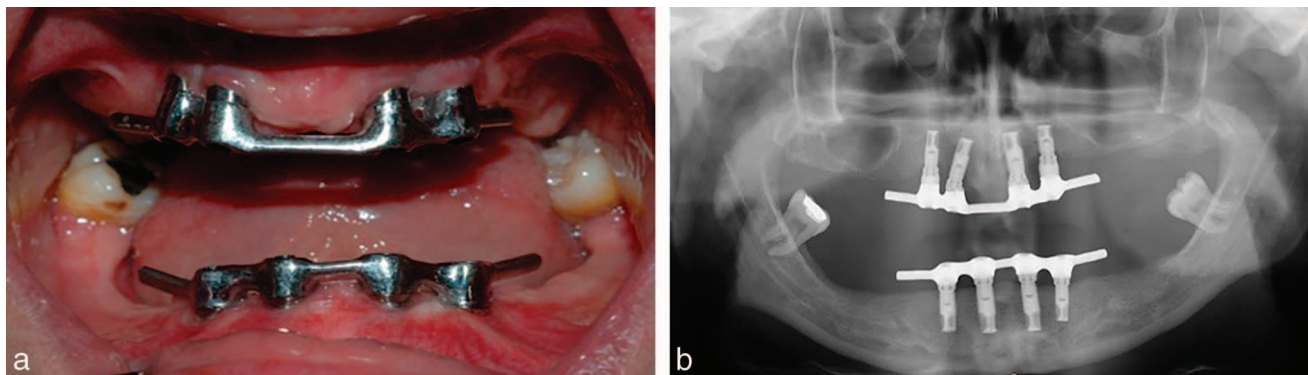
Since there is no consensus on treatment protocols and their long-term outcomes as well as survival of implants placed in such patients, dentists are in general hesitant to use dental implants in GAgP. Host response determines the approach taken by the dental professional during the placement of the dental implants in patients with GAgP. Lang et al suggested that such patients had poor serum antibody response to infective bacterial agents, which negatively affects the progression of the periodontitis.<sup>16</sup> Yet, Mengel et al suggested that partially edentulous patients treated for GAgP can be rehabilitated successfully with osseointegrated implants. The compromise is that the bone and attachment loss around the implants placed in GAgP were higher than in periodontally healthy cases<sup>8</sup> suggesting that the pathogenetic concerns heavily determine the outcomes. Thus, there is a strong need for more evidence towards the understanding of the tissue response to dental implants in GAgP. In this report, we provide support that such cases can be successfully treated using implants when a close collaboration between the periodontist and prosthodontist exist throughout the planning and treatment.

In a similar previous case report, subgingival microbiota was studied before and after complete edentulation and



**FIGURE 2.** (a, b, c) The healing abutments were connected and teeth numbered 18,17, and 15 were extracted (clinical-radiographical view). (d, e) Wax framework try-in for the maxilla and mandibula. (f) Final prosthesis, (intra-oral). (g) Soft tissue profiles were evaluated in the frontal view, after delivery of the final prosthesis.





**FIGURE 3.** (a) Periodontal and peri-implant conditions were stable over a 24-month follow-up period. (b) Panoramic radiography, 24 months after restoration.

reconstruction with dental implants in a 45-year-old female patient with GAgP. At 4- to 6-month recall visits after definitive prosthetic reconstruction, microbiological culture of three inflamed peri-implant sites showed an almost identical spectrum of pathogens, including pathogenic bacteria characteristic of aggressive periodontitis. As natural teeth were absent for 8 months, the authors suggested that periodontal pathogens can be retained for a prolonged period in edentulous areas, from where they can later colonize and compromise the health of dental implants.<sup>13</sup> Since this was the case, we have added antibiotics to the Phase I therapy and preferred a previously reported combination of metronidazole and amoxicillin. This combination has been reported to effectively reduce levels of *P. gingivalis*, *Actinobacillus actinomycetemcomitans* serotype b, *Tannerella forsythia* and *T. denticola*.<sup>17</sup> Such a combination may be essential for the suppression of the periodontopathogens during the critical healing around dental implants.

Al-Zahrani suggested that clinicians need to consider some other important factors when planning implant placement in GAgP patients: An appropriate length of time between active periodontal therapy and implant placement must be determined. It must also be decided whether to extract all questionable teeth prior to the placement of implants. It is important to ascertain the influence of periodontally compromised teeth on the adjacent implant.<sup>15</sup> Based on these suggestions, we have extracted all the questionable teeth as a part of the treatment prior to the connection of healing abutments. Mandibular third molars were retained since they had a good periodontal prognosis and were not "questionable." Retention of these teeth also added psychological benefit to her for not being completely edentulous.

The patient in this case is young. Treatment with a removable prosthetics therefore, was considered not an ideal option. The alternative was to restore with the fixed dental prosthesis. However, advanced vertical bone resorption posed esthetic problems, such as inadequate lip support. In order to overcome this limitation, extensive and advanced osseous grafting was necessary. To this end, such surgeries (autogenous bone blocks, synthetic grafts, distraction osteogenesis, etc) could not be performed due to financial limitations. Therefore, we have chosen a compromise by using implant supported overdentures (bar-retained) in order to restore dentition,

support lips, and enhance esthetics and phonation. We have used regular diameter implants in this study. Even better results can be obtained if narrow body implants were used based on a recent report that the clinical outcome, survival rate, bone-level changes were shown to be favorable over 5–10 suggesting narrow implants could be used with confidence where a regular diameter implant is not suitable.<sup>18</sup> This finding was further supported in a recent review.<sup>19</sup> Further research is needed if this would be applicable to the GAgP.

GAgP patients require a multidisciplinary approach for the dental treatment to regain appropriate function, aesthetics, and comfort. Dental implants present a viable treatment approach in restoring the lost dentition in subjects with GAgP due to the early loss of teeth at a young age in life. In this case, the restored function and esthetics in a young aggressive periodontitis patient by dental implants was presented. The possibility of a progressive and continuous attachment loss and bone loss occurring around teeth and implants cannot be ruled out and require long-term studies. The key to success is the close collaboration between the periodontist and the prosthodontist. GAgP presents a major challenge for conventional implantology. Therefore, a careful and meticulous prevention and maintenance regimen is crucial. This starts from the beginning at the planning stage and continues long after the restorations have been placed. In this case, all implants were successful according to the radiographic success criteria reported by Albrektsson et al.<sup>20</sup> While the follow-up time is relatively short, no implants were lost encouraging the use of dental implants in the treatment of patients with GAgP.

#### ABBREVIATION

GAgP: generalized aggressive periodontitis

#### REFERENCES

1. Armitage GC. Development of a classification system for periodontal diseases and conditions. *Ann Periodontol.* 1999;4:1–6.
2. Tonetti MS, Mombelli A. Aggressive periodontitis. In: Lindhe J, Lang NP, Karring T, eds. *Clinical Periodontology and Implant Dentistry.* 2 volumes. Iowa: Wiley-Blackwell; 2008: 428–458.
3. Schou S, Holmstrup P, Worthington HV, Esposito M. Outcome of

implant therapy inpatients with previous tooth loss due to periodontitis. *Clin Oral Implants Res.* 2006;17:104–123.

4. Malmstrom HS, Fritz ME, Timmis DP, Van Dyke TE. Osseo-integrated implant treatment of a patient with rapidly progressive periodontitis. A case report. *J Periodontol.* 1990;61:300–304.

5. Mengel R, Schroder T, Flores-de-Jacoby L. Osseointegrated implants in patients treated for generalized chronic periodontitis and generalized aggressive periodontitis: 3- and 5-year results of a prospective long-term study. *J Periodontol.* 2001;72:977–989.

6. Mengel R, Flores-de-Jacoby L. Implants in regenerated bone in patients treated for generalized aggressive periodontitis: a prospective longitudinal study. *Int J Periodontics Restorative Dent.* 2005;25:331–341.

7. Mengel R, Kreuzer G, Lehmann KM, Flores-de-Jacoby L. A telescopic crown concept for the restoration of partially edentulous patients with aggressive generalized periodontitis: a 3-year prospective longitudinal study. *Int J Periodontics Restorative Dent.* 2007;27:231–239.

8. Mengel R, Behle M, Flores-de-Jacoby L. Osseointegrated implants in subjects treated for generalized aggressive periodontitis: 10-year results of a prospective, long-term cohort study. *J Periodontol.* 2007;78:2229–2237.

9. De Boever AL, Quirynen M, Coucke W, et al. Clinical and radiographic study of implant treatment outcome in periodontally susceptible and nonsusceptible patients: a prospective long-term study. *Clin Oral Implants Res.* 2009;20:1341–1350.

10. Yalçın S, Yalçın F, Günay Y, et al. Treatment of aggressive periodontitis by osseointegrated dental implants. A case report. *J Periodontol.* 2001;72:411–416.

11. Wu AY, Chee W. Implant-supported reconstruction in a patient with generalized aggressive periodontitis. *J Periodontol.* 2007;78:777–782.

12. Hoffmann O, Beaumont C, Zafiroopoulos GG. Combined periodontal and implant treatment of a case of aggressive periodontitis. *J Oral Implantol.* 2007;33:288–292.

13. Emrani J, Chee W, Slots J. Bacterial colonization of oral implants from nondental sources. *Clin Implant Dent Relat Res.* 2009;11:106–112.

14. Hong JS, Yeo IS, Kim SH, et al. Implants and all-ceramic restorations in a patient treated for aggressive periodontitis: a case report. *J Adv Prosthodont.* 2010;2:97–101.

15. Al-Zahrani MS. Implant therapy in aggressive periodontitis patients: a systematic review and clinical implications. *Quintessence Int.* 2008;39:211–215.

16. Lang N, Bartold PM, Cullinan M, et al. Consensus report: aggressive periodontitis. *Ann Periodontol.* 1999;4:53.

17. Xajigeorgiou C, Sakellari D, Slini T, et al. Clinical and microbiological effects of different antimicrobials on generalized aggressive periodontitis. *J Clin Periodontol.* 2006;33:254–264.

18. Arisan V, Bölükbaşı N, Ersanli S, Ozdemir T. Evaluation of 316 narrow diameter implants followed for 5–10 years: a clinical and radiographic retrospective study. *Clin Oral Implants Res.* 2010;21:296–307.

19. Sohrabi K, Mushantat A, Esfandiari S, Feine J. How successful are small-diameter implants? A literature review. *Clin Oral Implants Res.* 2012;23:515–525.

20. Albrektsson T, Zarb GA, Worthington P, et al. The long-term efficacy of currently used dental implants: a review and proposed criteria of success. *Int J Oral Maxillofac Implants.* 1986;1:1–25.