

Assessment of Maxillary and Mandibular Bone Density in Controlled Type II Diabetes: A Computed Tomography Study

Sanju John Jolly, MDS^{1*}
Chethan Hegde, MDS²
N. Sridhar Shetty, MDS²

This study was undertaken to compare the bone density in nondiabetic and controlled type II diabetes patients using spiral computed tomography. A group of 40 edentulous men, comprising of 20 nondiabetics and 20 controlled type II diabetics between the ages of 50–65 years, were enrolled in the study. Glycemic control of the diabetic patients was assessed by glycosylated hemoglobin level. The controlled diabetic group had an HbA1c level between 6.1–8%. A radiographic stent was prepared by using chemically cured resin. Bone densities at trabecular, buccal, and lingual cortical regions of maxillary and mandibular edentulous arches were measured by a tomography machine. Mean bone density measurements were recorded in Hounsfield units. The data thus obtained from 10 sites of maxillary and mandibular arches were tabulated and analyzed using SPSS statistical software. This study showed no significant changes in bone density between the controlled diabetic and nondiabetic subjects. Within the limitation of this study, it can be concluded that bone density does not seem to be affected in controlled type II diabetics.

Key Words: diabetes, bone density, tomography, dental implants

INTRODUCTION

Osseointegrated endosseous implants are used in prosthodontics with a high rate of success. Patient selection, treatment planning, implant design, suitable implant materials, good surgical technique, and restorative treatment are critical in the success of the procedure. However, success can also be negatively influenced by factors such as poor bone quality and quantity of available bone, underlying systemic factors, impaired healing, and metabolic bone diseases.¹

The prevalence of obesity is dramatically increasing throughout the world. A growing waistline is accompanied by serious medical complications, such as arthritis, coronary artery disease, and diabetes mellitus. As the life expectancy of individuals continues to increase, an implantologist can expect to see an increased number of patients with diabetes mellitus. Type II diabetes develops from impaired insulin response to glucose stimulation or insufficient secretion of insulin, whereas type I diabetes is caused by deficient pancreatic β -cell secretion of insulin. Delayed wound healing and increased postoperative infection are seen in both types of diabetic patients due to

microvascular damage, diminished bactericidal capacity, and deficient leukocyte chemotaxis.^{2,3} Most of the clinical and laboratory studies have reported that bone formation around dental implants may be incomplete and delayed, and bone-to-implant contact might be impaired. It is found that newly formed bone is immature and poorly organized with diminished mechanical properties.^{4–11} Such complications affect the success of implant therapy. However, over the past decades, diabetes has not been regarded as an absolute contraindication for implant supported prosthesis therapy, but rather a relative contraindication related to stability of diabetic blood-sugar level.^{2,3,10} Balshi and Wolfinger reported a success rate of 94.3% in diabetic patients.¹² Farzad et al reported a success rate of 94.1% after 1 year in 136 implants for 25 patients with both type I and type II diabetes.¹³

Bone density is the amount of mineral matter per square centimeter of bone, and it is one of the important predictors for success in the placement of a dental implant.¹⁴ Failure rates are higher in softer bone type. The prevalence of reduced bone mass has been reported in type I diabetics.^{15–18} The effect of type II diabetes on bone density remains uncertain. Several studies have shown normal,¹⁹ elevated,^{20–22} or reduced^{17,23} bone densities.

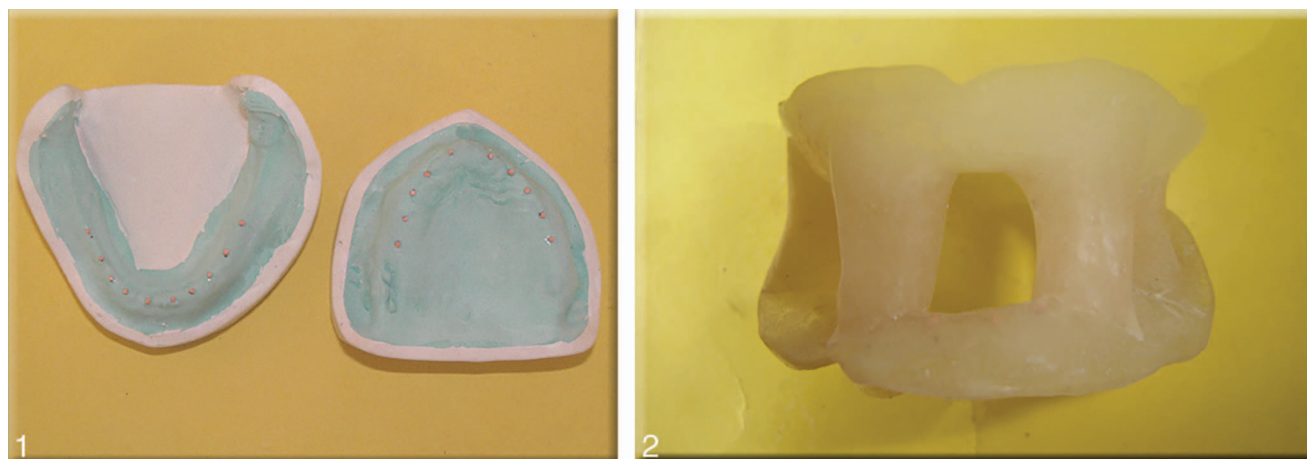
Pre-surgical assessment of a proper implant site requires very specific and accurate data. Various techniques such as histomorphometry of bone biopsies, dual-energy X-ray absorptiometry, digital image analysis of radiographs, qualitative ultrasound, and tomographies are used for evaluation of bone density. An evaluation of the presurgical bone site with

¹ Department of Prosthodontics, Indira Gandhi Institute of Dental Sciences, Nellikuzhi, Kothamangalam, Ernakulam District, Kerala State, India.

² Department of Prosthodontics, A.B. Shetty Memorial Institute of Dental Sciences, Deralakatte, Mangalore, Karnataka State, India.

* Corresponding author, e-mail: drsanjuj@rediffmail.com

DOI: 10.1563/AAID-JOI-D-12-00248



FIGURES 1 AND 2. FIGURE 1. Gutta-percha points placed on the cast to demarcate the correct location. **FIGURE 2.** Stent used to stabilize the maxillary and mandibular jaw during the scanning procedure.

computed tomography will reveal the bone quality, quantity, and the relationship to critical structures, which are not available from panoramic or periapical radiographs.^{24,25} Spiral computed tomography produces axial images of the patient's anatomy, perpendicular to the long axis of the body. Each axial image has many pixels, and each pixel has a computed tomographic number (Hounsfield unit) related with the density of the tissue within the pixel.²⁶

Thus, a study was undertaken to assess the bone density in type II diabetic male patients using spiral computed tomography.

MATERIALS AND METHODS

Forty edentulous male patients were enrolled in the study, comprised of 20 nondiabetic and 20 controlled type II diabetics between 50–65 years old. The mean age of the nondiabetic group was 60 ± 6 years, whereas it was 62 ± 5 years for the controlled diabetic. To avoid the gender-based difference in bone density,²⁰ only male patients were enrolled. All patients were informed about the study, and their written consent to participate in the study was taken. The ethics committee of the college cleared the study.

Patients enrolled met the following criteria:

Controlled type II diabetic group

- History of diabetes for at least 3 years.
- Glycosylated hemoglobin (HbA1c) level between 6.1–8%.
- Out of 20 subjects, 9 subjects were on diet control and 11 were on oral hypoglycemic drugs.

Nondiabetic group

- No systemic disease, no endocrine, metabolic, or skeletal bone disorders.

A routine screening panoramic radiograph was employed to rule out intra-alveolar pathoses. Blood and urine analyses were done to rule out any systemic endocrine, metabolic, or skeletal bone disorders.

Diagnostic impressions of the maxillary and mandibular arches were made with alginate (Tropicalgin, Badia Polesine,

Italy). Ten prospective implant sites in the region of central incisor, lateral incisor, canine, premolar, and molar on either side of the arches were marked on the maxillary and mandibular casts using a graphite pencil. Gutta-percha cones (Dentsply Maillefer, Ballaigues, Switzerland) of 1 mm diameter and 1 mm height were fixed with cyanoacrylate at the corresponding 10 sites on the cast (Figure 1). A radiographic stent incorporating the gutta-percha cones was prepared on the cast using chemically cured resins (DPI, Mumbai, India) (Figure 2). The maxillary and mandibular stents were joined together with chemically cured resin. This helped stabilize the jaws during the scanning procedure.

Bone density was assessed using a spiral computerized tomography machine (Siemens Somatom Esprit Plus, Siemens Medical Solutions, Malvern, Pa) fitted with a Kodak Ektascan 160 laser image printer. The X-ray source was attached rigidly to a fan beam geometry detector array, which rotated 360° around the patient. The patient was stabilized in a standardized position within the gantry. Computed tomography scans were obtained with the patient lying comfortably in supine position with the plane of occlusion positioned perpendicular to the horizontal plane.

The densities of bone in the various sites (trabecular and cortical) were obtained by locating a cursor at different positions on the image and using Dental Scan software (Medi-Tech Solutions, Bangalore, India) to determine the density, expressed in the Hounsfield unit (Figure 3). In general, higher the tomographic number, the denser the tissue. The bone density values were recorded on two successive slices in the trabecular and cortical regions of the maxillary and mandibular jaws, and the mean of these was obtained.

Statistical package for social sciences (SPSS) version 17.0 for Windows was used for statistical analysis. The descriptive statistic was summarized and expressed in terms of mean \pm SD of bone density in different sites.

RESULTS

On analyzing the results in the Table, the bone density at the trabecular region in the maxilla and mandible in nondiabetic

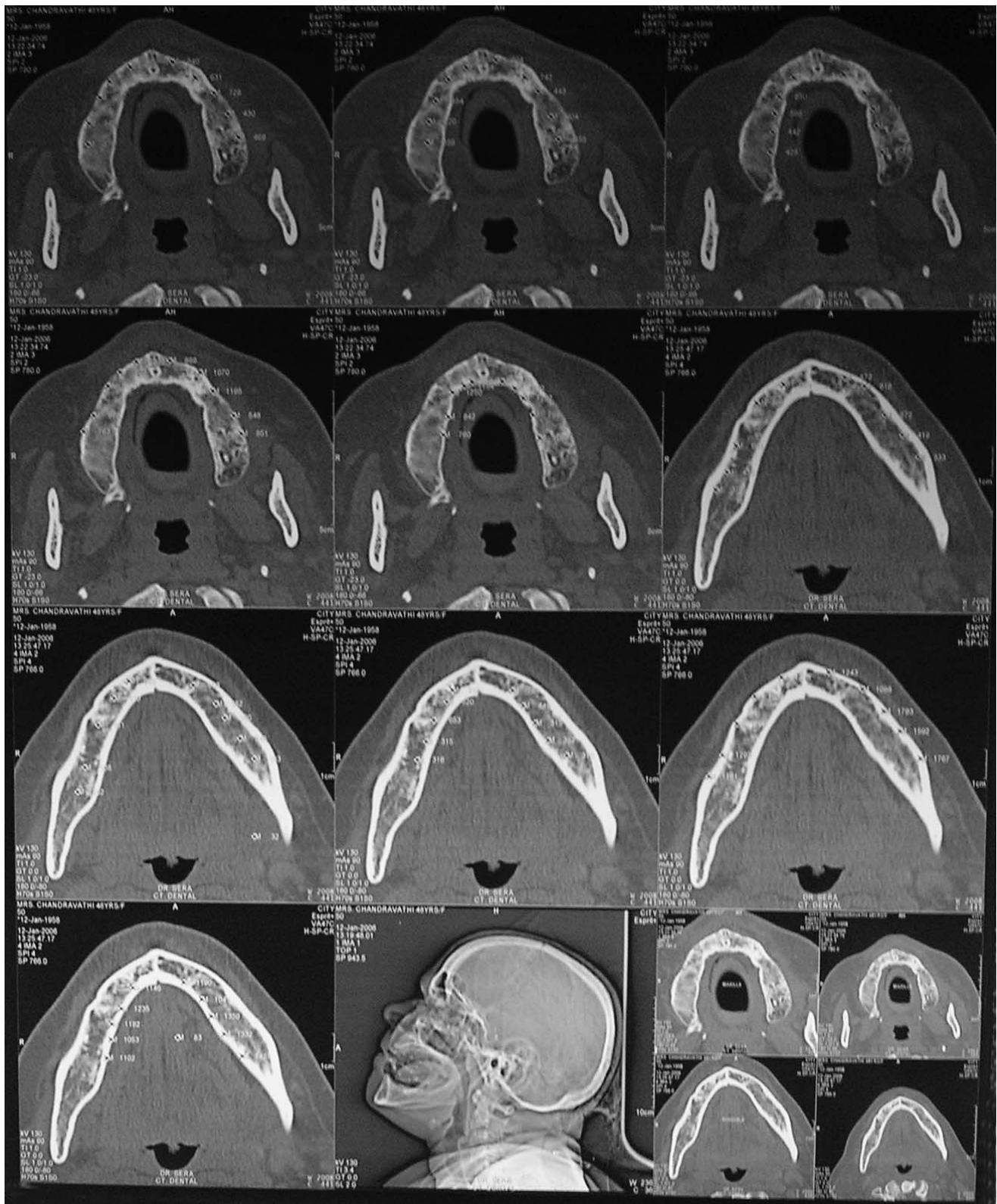


FIGURE 3. Computerized tomographic image of the patient.

TABLE

Comparison of bone mineral density at trabecular, buccal cortical, and lingual cortical regions of maxilla and mandible in nondiabetic and controlled diabetic subjects*

Region	Group	Class	Mean	Std. Deviation	Unpaired t Test
Trabecular	Maxilla	Nondiabetic	464.04	40.05	t value = -1.883
		Diabetic	445.06	20.64	P value = .067 (NS)
	Mandible	Nondiabetic	514.31	20.03	t value = -1.894
		Diabetic	498.12	32.59	P value = .066 (NS)
Buccal cortical	Maxilla	Nondiabetic	602.56	43.34	t value = -1.835
		Diabetic	576.51	46.37	P value = .074 (NS)
	Mandible	Nondiabetic	1268.23	68.24	t value = .277
		Diabetic	1261.36	87.57	P value = .783 (NS)
Lingual cortical	Maxilla	Nondiabetic	636.58	43.41	t value = -1.855
		Diabetic	590.75	101.62	P value = .071 (NS)
	Mandible	Nondiabetic	1459.92	105.20	t value = -1.817
		Diabetic	1407.61	74.21	P value = .077 (NS)

*NS indicates not significant; S, significant (at 95% confidence interval).

and controlled diabetic subjects did not show any statistically significant difference. The maxilla of nondiabetic subjects showed a mean value of 464.04 ± 40.05 Hounsfield units, where as diabetic subjects showed slightly less bone density of 445.06 ± 20.64 . Similarly, the mandible of nondiabetic subjects showed a mean value of 514.31 ± 20.03 and of diabetic subjects 498.12 ± 32.59 .

The bone density at various sites in buccal cortical plates in maxilla and mandible of nondiabetic subjects and controlled diabetic subjects did not show any statistically significant difference. The maxilla of nondiabetic subjects showed a mean value of 602.56 ± 43.34 , whereas diabetic subjects showed a density of 576.51 ± 46.37 . In the mandible, nondiabetic subjects showed a mean value of 1268.23 ± 68.24 , and diabetic subjects showed a mean value of 1261.36 ± 87.57 Hounsfield units.

The lingual cortical region in the maxilla and mandible of nondiabetic subjects and controlled diabetic subjects did not show any statistically significant difference. Lingual cortical bone density in the maxilla of nondiabetic subjects showed a mean value of 636.58 ± 43.41 , and diabetic subjects showed a mean 590.75 ± 101.62 Hounsfield units. Lingual cortical bone density in the mandible of nondiabetic subjects showed a mean value of 1459.92 ± 105.20 , and diabetic subjects showed 1407.61 ± 74.21 Hounsfield units.

DISCUSSION

Bone quality and quantity vary from site to site and from patient to patient. Patients having good bone quality and quantity have a higher success rate for implants. The initial bone density not only provides mechanical immobilization of the implant during healing, but also permits distribution and transmission of stresses from the prosthesis to the implant-bone interface.^{14,27-30} Adell et al. reported 10% greater success rate in the anterior mandible as compared with the anterior maxilla.³¹ Lower success was noted in the posterior mandible as compared to anterior mandible by Schnitman.³² The highest clinical failures have been reported in the posterior maxilla. The anterior mandible has greater density than the anterior

maxilla.³³ The posterior mandible has lower bone density than does the anterior mandible.³² Engquist et al.³⁴ reported 78% implant failure and Friberg et al.³⁵ observed 66% implant failure in soft bone type. The reduced implant survival was more related to bone density than location.³⁶ Therefore, an accurate presurgical assessment of the implant site is essential prior to implant placement.

Although intra-oral endosseous implant therapy continues to provide a consistent and predictable treatment options for most patients, some people with uncontrolled systemic disease may be denied implant treatment. Diabetes is one such disease that is characterized by a high concentration of blood glucose.^{1,2} Glycemic control is assessed by glycosylated hemoglobin level (HbA1c). HbA1c is an indicator of glucose levels over a three-month period.³⁷ In unaffected healthy individuals, HbA1c levels are 4–6. HbA1c level between 6.1–8 is considered well controlled, and levels above 8 are poorly controlled diabetes.³⁸ Glycemic control is directly related to the development of diabetic complications, so achieving a controlled HbA1c level is important for better survival rate for implants.^{12,13,38-40}

Due to the different pathogenesis of type I and type II diabetes mellitus, the effect upon the bone also differs. Many complications—such as chronic hyperglycemia, hypercalciuria, and a negative effect of accumulated glycated end product—are common for both groups. However, the differences are in the insulin concentrations and insulin-like growth factor (IGF) concentrations between type I and type II diabetes. This suggests that either direct or indirect effects of insulin, such as increased hepatic IGF-I production and increased IGF-I bioavailability, may play a significant role for the maintenance of bone health in type II diabetes.⁴¹ The insulin-like growth factor is a protein with a high sequence similarity to insulin. It is protective for cartilage cells and associated with activation of osteocytes, thus may be an anabolic factor for bone. Since IGF is capable of activating the insulin receptor at high concentrations, it can also complement for the effect of insulin. Studies have shown that insulin-deficient rat models have a deficit in mineralized surface area, less rate of mineral apposition, decreased osteoid surface, depressed osteoblast activity, and decreased number of osteoclasts,^{6,7,42} leading to an overall depression in bone

remodeling. It has been suggested that insulin therapy may reverse the effect of diabetes on bone metabolism.^{11,43} More recently, de Moraes et al. reported that insulin therapy maintained bone density around implants in diabetic rats when compared to non-insulin-treated diabetic rats.⁴⁴ In their study, Malekzadeh and colleagues noted that locally administered insulin from a titanium implant surface has the potential to increase bone formation not only in diabetic subjects but also in nondiabetic subjects.⁴⁵ Systemic insulin treatment can have an anabolic effect on bone.⁴⁶ Therefore, bone remodeling becomes a vital aspect of implant survival, once the implant is functionally loaded. The dependence on bone metabolism for implant survival is critical in patients with diabetes.

Considering these observations, an in vivo study to evaluate the bone density using spiral computed tomography in controlled diabetic and nondiabetic patients was undertaken. Our study does not show any statistically significant difference in bone density at trabecular, buccal, and lingual cortical regions between nondiabetic and controlled diabetic subjects. The results from the current study concurred with Tuominen et al.,¹⁹ Sert et al.,⁴⁷ and Sinan et al.,⁴⁸ who reported that bone density of the mandible does not seem to be affected in patients with type II diabetes mellitus as assessed by X-ray absorptiometry. Wakasugi et al. suggested that hyperinsulinemia and obesity were commonly associated with non-insulin-dependent diabetes mellitus, and appear to protect the bone loss in such patients. Hence, such factors may explain the slower loss of bone density.⁴⁹ In addition, adipose tissue releases various adipokines, such as adiponectin, which have been shown to regulate bone metabolism.^{50,51} Furthermore, studies have shown that plasma leptin levels are increased in diabetic men. Leptin is a protein hormone that is secreted by the fat tissue and is shown to induce osteoblastic proliferation and differentiation while inhibiting osteoclastic activity.⁵²⁻⁵⁴ The above studies show that various adipokines may have an effect in maintaining the bone mass in type II diabetes mellitus patients.

X-ray absorptiometry was employed in all the above studies for assessment of mean bone density; however, in the present study, computed tomography was used and is more specific in the assessment of bone density. Studies have shown that examining bone density at different sites may reveal different results. Most of the above studies have shown the results of bone density measured at femoral, forearm, lumbar, and the hip joint. Our study has evaluated the mean bone density at maxillary and mandibular arches and will be more specific when evaluating for prospective implant patient. However, statistical analysis showed that the results from the trabecular region were closer to the level of significance. Further studies with a larger sample size are recommended to confirm these observations.

CONCLUSION

The following conclusions were drawn from the ongoing study:

- Pre-operative evaluation of bone density is essential to assist the clinician with the treatment planning of intra-oral endosseous implant therapy.

- Bone density does not seem to be affected in controlled type II diabetes.
- The present study evaluates the bone density in type II diabetic subjects, and further studies are necessary in type I diabetics, poorly controlled diabetes, and female subjects.

ABBREVIATIONS

HbA1c: hemoglobin A1c
IGF: insulin-like growth factor

REFERENCES

1. Sugeran PB, Barber MT. Patient selection for endosseous dental implant: oral and systemic consideration. *Int J Oral Maxillofac Implants*. 2002;17:191-201.
2. Blanchaert RH. Implants in the medically challenged patient. *Dent Clin North Am*. 1998;42:35-45.
3. Javed F, Romanos GE. Impact of diabetes mellitus and glycemic control on the osseointegration of dental implants: a systematic literature review. *J Periodontol*. 2009;80:1719-1730.
4. Gooch HL, Hale JE, Fujioka H, Balian G, Hurwitz SR. Alterations of cartilage and collagen expression during fracture healing in experimental diabetes. *Connect Tissue Res*. 2000;41:81-85.
5. Amir G, Rosenmann E, Sherman Y, Greenfeld Z, Ne'eman Z, Cohen AM. Osteoporosis in the Cohen diabetic rat: correlation between histomorphometric changes in bone and microangiopathy. *Lab Invest*. 2002;82:1399-1405.
6. Beam HA, Parsons JR, Lin SS. The effects of blood glucose control upon fracture healing in the BB Wistar rat with diabetes mellitus. *J Orthop Res*. 2002;20:1210-1216.
7. Gebauer GP, Lin SS, Beam HA, Vieira P, Parsons JR. Low-intensity pulsed ultrasound increases the fracture callus strength in diabetic BB Wistar rats but does not affect cellular proliferation. *J Orthop Res*. 2002;20:587-592.
8. Lu H, Kraut D, Gerstenfeld LC, Graves DT. Diabetes interferes with the bone formation by affecting the expression of transcription factors that regulate osteoblast differentiation. *Endocrinology*. 2003;144:346-352.
9. Nevins ML, Karimbux NY, Weber HP, Giannobile WV, Fiorellini JP. Wound healing around endosseous implants in experimental diabetes. *Int J Oral Maxillofac Implants*. 1998;13:620-629.
10. Kotsovilis S, Karoussis IK, Fourmousis I. A comprehensive and critical review of dental implant placement in diabetic animals and patients. *Clin Oral Imp Res*. 2006;17:587-599.
11. Margonar R, Sakakura, CE, Holzhausen M, Pepato MT, Alba RC, Marcantonio E. The influence of diabetes mellitus and insulin therapy on biomechanical retention around dental implants: a study in rabbits. *Implant Dent*. 2003;12:333-339.
12. Balshi TJ, Wolfinger GJ. Implants in the diabetic patient: a retrospective study. *Implant Dent*. 1999;8:355-359.
13. Farzad P, Andersson L, Nyberg J. Dental implant treatment in diabetic patients. *Implant Dent*. 2002;11:262-267.
14. Misch CE. *Dental Implant Prosthetics*. Maryland Heights, Mo: Mosby Inc; 2005:130-141.
15. Carnevale V, Romagnoli E, D'Erasmo E. Skeletal involvement in patients with diabetes mellitus. *Diabetes Metab Res Rev*. 2004;20:196-204.
16. Isaia GO, Ardisson P, di Stefano M. Bone metabolism in type 2 diabetes mellitus. *Acta Diabetol*. 1999;36:35-38.
17. Nicodemus KK, Folsom AR. Type 1 and type 2 diabetes and incident hip fractures in postmenopausal women. *Diabetes Care*. 2001;24:1192-1197.
18. Forsen L, Meyer HE, Midthjell K. Diabetes mellitus and the incidence of hip fracture: results from the Nord-Trøndelag Health Survey. *Diabetologia*. 1999;42:920-925.
19. Tuominen JT, Impiraara O, Puukka P, Ronnemaa T. Bone mineral density in patients with type 1 and type 2 diabetics. *Diabetes Care*. 1999;22:1096-1120.
20. Barrett-Connor E, Holbrook TL. Sex differences in osteoporosis in older adults with non-insulin-dependent diabetes mellitus. *JAMA*. 1992;268:3333-3337.

21. Daele PL, Stolk RP, Burger H, et al. Bone density in non-insulin dependent diabetes mellitus. The Rotterdam study. *Ann Intern Med.* 1995; 122:409–414.
22. Lunt M, Masaryk P, Scheidt-Nave C. The effects of lifestyle, dietary dairy intake and diabetes on bone density and vertebral deformity prevalence: the EVOS Study. *Osteoporos Int.* 2001;12:688–698.
23. Cummings SR, Nevitt MC, Browner WS. Risk factors for hip fracture in white women. Study of Osteoporotic Fractures Research Group. *N Engl J Med.* 1995;332:767–773.
24. Tal H, Moses O. A comparison of panoramic radiography with computed tomography in the planning of implant surgery. *Dentmaxillofac Radiol.* 1991;20:20–40.
25. Lindh C, Nilsson M, Linge BK, Petersson A. Quantitative computed tomography of trabecular bone in the mandible. *Dentmaxillofac Radiol.* 1996;25:146–150.
26. Cann CE. Quantitative CT for determination of bone mineral density: a review. *Radiology* 1990;166:509–522.
27. Barewal RM, Oates TW, Meredith N, Cochran DL. Resonance frequency measurement of implant stability in vivo on implants with a sandblasted and acid-etched surface. *Int J Oral Maxillofac Implants.* 2003;18: 641–651.
28. Meredith N. Assessment of implant stability as a prognostic determinant. *Int J Prosthodont.* 1998;11:491–501.
29. Molly L. Bone density and primary stability in implant therapy. *Clin Oral Imp Res.* 2006;17(suppl 2):124–135.
30. Friberg B, Sennerby L, Meredith N, Lekholm U. A comparison between cutting torque and resonance frequency measurements of maxillary implants. *Int J Oral Maxillofac Surg.* 1999;28:297–303.
31. Adell R, Lekholm U, Rockler B. A fifteen year study of osseointegrated implants in the treatment of the edentulous jaws. *Int J Oral Surg.* 1981;6:387–416.
32. Schnitman PA. Implants for partial edentulism. *J Dent Educ.* 1988;52: 725–736.
33. Misch CE. Density of bone: effect on treatment plans, surgical approach, healing. *Int J Oral Maxillofac Impl.* 1990;6:23–31.
34. Enguist B, Bergendal T, Kallus T. A retrospective multicenter evaluation of osseointegrated implants supporting overdentures. *Int J Oral Maxillofac Impl.* 1988;3:129–134.
35. Friberg B, Jemt T, Lekholm U. Early failures in 4641 consecutively placed Branemark dental implants: a study from stage I surgery to the connection of completed prosthesis. *Int J Oral Maxillofac Impl.* 1988;3:134–138.
36. Tolstunov L. Implant zones of the jaws: implant location and related success rate. *J Oral Implantol.* 2007;33:211–220.
37. Derr R, Garrett E, Stacy GA, Saudek CD. Is HbA(1c) affected by glycemic instability? *Diabetes Care.* 2003;26:2728–2733.
38. Oates TW, Dowell S, Robinson M, McMahan CA. Glycemic control and implant stabilization in type 2 diabetes mellitus. *J Dent Res.* 2009;88: 367–371.
39. Fiorellini JP, Chen PK, Nevins M, Nevins ML. A retrospective study of dental implants in diabetic patients. *Int J Periodontics Restorative Dent.* 2000; 20:366–373.
40. Abdulwassie H, Dhanrajani PJ. Diabetes mellitus and dental implants: a clinical study. *Implant Dent.* 2002;11:83–86.
41. Thrailkill KM. Insulin-like growth factor-I in diabetes mellitus: its physiology, metabolic effects and potential clinical utility. *Diabetes Technol Ther.* 2000;2:69–80.
42. Colombo JS, Balani D, Sloan AJ, Crean SJ, Okazaki J. Delayed osteoblast differentiation and altered inflammatory response around implants placed in incisor sockets of type 2 diabetic rats. *Clin Oral Imp Res.* 2011;22:578–586.
43. Siqueira JT, Cavalher-Machado SC, Arana-Chavez VE, Sannomiya P. Bone formation around titanium implants in the rat tibia: role of insulin. *Implant Dent.* 2003;12:242–251.
44. de Moraes JA, Trindade-Suedam IK, Pepato MT, Marcantonio E, Wenzel A, Scaf G. Effect of diabetes mellitus and insulin therapy on bone density around osseointegrated dental implants: a digital subtraction radiography study in rats. *Clin Oral Imp Res.* 2009;20:796–801.
45. Malekzadeh B, Tengvall P, Ohnrlund LO, Wennerberg A, Westerlund A. Effects of locally administered insulin on bone formation in non-diabetic rats. *J Biomed Mater Res A.* 2013;101:132–137.
46. Thrailkill KM, Lumpkin CK, Bunn RC, Kemp SF, Fowlkes JL. Is insulin an anabolic agent in bone? Dissecting the diabetic bone for clues. *Am J Physiol Endocrinol Metab.* 2005;289:735–745.
47. Sert M, Tetiker T, Kirim S, Soyupak S, Canataroglu A, Kocak M. Type 2 diabetes mellitus and osteopenia: is there an association? *Acta Diabetol.* 2003;40:105–108.
48. Sinan Ay, Gursoy UK, Erselcan T, Marakoglu I. Assessment of mandibular bone mineral density in patients with type 2 diabetes mellitus. *Dentmaxillofac Radiol.* 2005;34:327–331.
49. Wakasugi M, Wakao R, Tawata M, Gan N, Koizumi K, Onaya T. Bone mineral density measured by dual energy X-ray absorptiometry in patients with non-insulin-dependent diabetes mellitus. *Bone.* 1993;14:29–33.
50. Reid IR. Relationships between fat and bone. *Osteoporos Int.* 2008; 19:595–606.
51. Bai Y, Yin G, Luo E. Adiponectin may improve osseointegration of dental implants in T2DM patients. *Med Hypotheses.* 2011;77:192–194.
52. Kanabrocki EL, Hermida RC, Wright M. Circadian variation of serum leptin in healthy and diabetic men. *Chronobiol Int.* 2001;18:273–283.
53. Hamrick MW, Della-Fera MA, Choi YH, Pennington C, Hartzell D, Baile CA. Leptin treatment induces loss of bone marrow adipocytes and increases bone formation in leptin-deficient ob/ob mice. *J Bone Miner Res.* 2005;20:994–1001.
54. Gordeladze JO, Drevon CA, Syversen U, Reseland JE. Leptin stimulates human osteoblastic cell proliferation, de novo collagen synthesis, and mineralization: impact on differentiation markers, apoptosis, and osteoclastic signaling. *J Cell Biochem.* 2002;85:825–836.