

Correction of Esthetic Complications of a Malpositioned Implant: A Case Letter

Sergio Alexandre Gehrke, PhD

INTRODUCTION

Initially, implant dentistry was focused on successful osseointegration of the implant body. Today, osseointegration of implants is readily attainable with high long-term survival rates. Good results in implant dentistry are based on adequate training, proper patient selection, precise surgery, thorough treatment planning, and comprehensive postoperative care. Currently, clinicians are focusing on improving implant esthetics and are incorporating this parameter into their definition of implant success. The most important objective is to create a natural smile. The attainment of this objective is far less complex if the natural anatomy of the soft tissue is preserved over time.¹

The placement of immediate implants into a fresh extraction socket is based on the concept of maximum preservation of the original anatomy of soft and hard tissues.² However, considerations must be made especially with regard to the loss of the wall of the buccal bone of the alveoli and consequent exposure of the implant.^{3,4} The esthetic restoration of dental implants in the anterior maxilla may be complex because of excessive alveolar ridge and soft-tissue loss following tooth extraction. The most common esthetic complication is gingival recession that exposes the implant-abutment junction. Poor shade selection for the prosthesis and lack of interdental papillae also account for implant esthetic failures.⁵

Thus, among the conditions considered essential for success in rehabilitation with dental implants, the prosthesis made over the implant has to be satisfactory to the clinician and patient.⁶ In cases of failure in treatment planning of implant placement

or technique errors, some alternative measures can be applied to favor the restoration. These include angled abutments and/or custom porcelain overcoat, artificial gingiva, elongated crowns, and secondary grafts.⁷

In extremely compromised cases, the treatment has been limited to abandonment, submersion, or surgical removal of the implant. However, surgical removal of the malpositioned implant often results in defects in bone and soft-tissue anatomy that require subsequent surgical repair.⁸

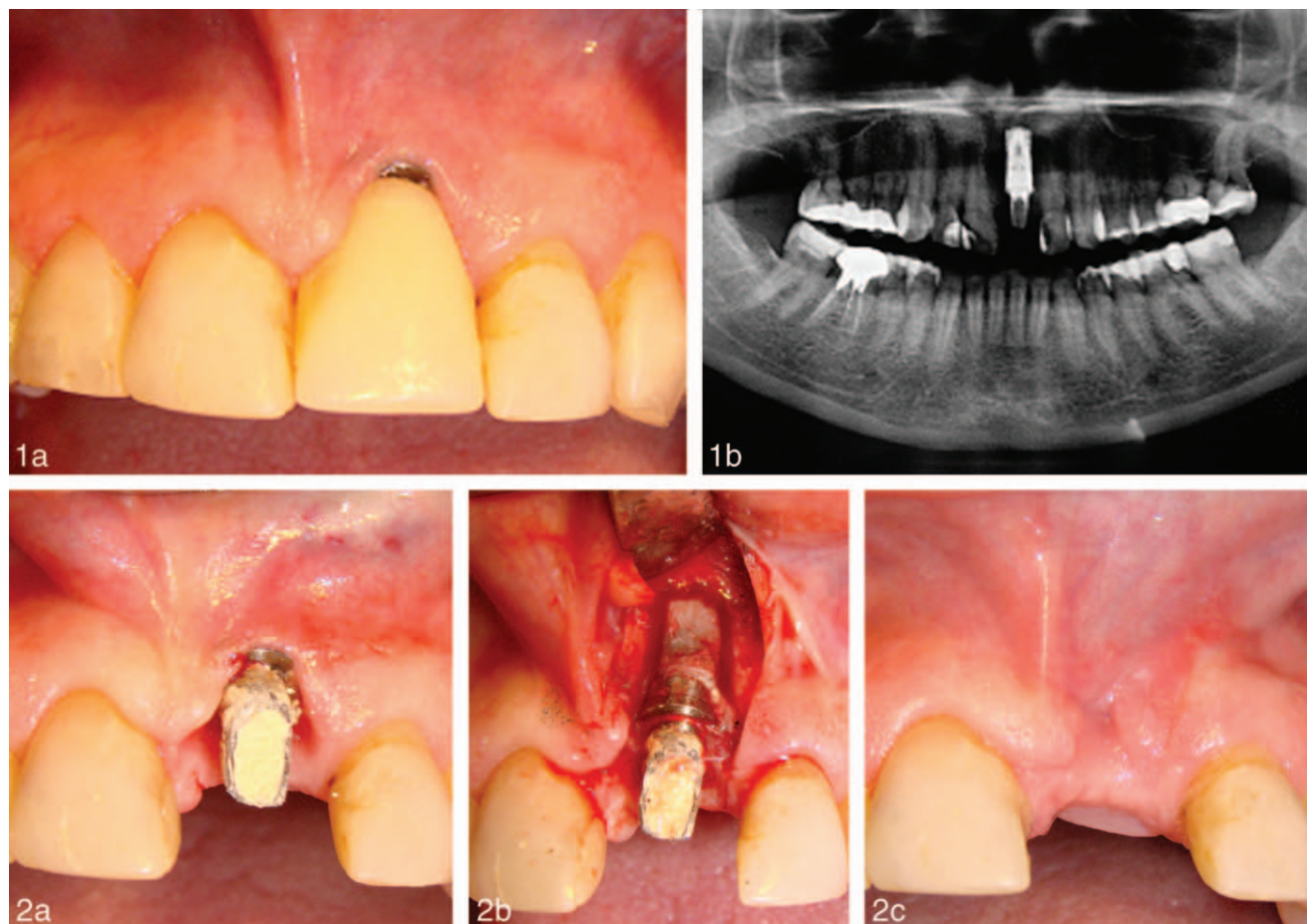
This article aims to demonstrate the correction of an esthetic problem caused by the improper positioning of a dental implant done simultaneously with the extraction.

DESCRIPTION OF THE CASE

A 43-year-old Caucasian man was treated for evaluation of a dental implant that had been placed 5 years previously to replace tooth No. 9 (maxillary left central incisor). Clinical examination revealed that the gingival margin was found to be approximately 6 mm above the gingival margin of that found on the adjacent teeth. Periodontal examination revealed a pink-colored gingiva without inflammation and probing depths within the normal range. The implant had no mobility. The patient reported that the implant began to appear out of the gum 30 days after its surgical placement, and multiple gingival graft attempts were made without success. To compensate for the lack of proper soft-tissue anatomy, the existing crown was made with an extension. The patient's chief complaint was the poor esthetics and the difficulty in cleaning the region (Figure 1a). The radiographic evaluation revealed that the implant did have adequate bone support (Figure 1b).

The proposed treatment plan presented to the patient was removal of the implant, placement of

Biocenos, Santa Maria, Brazil, and Catholic University of Uruguay, Montevideo, Uruguay.
Corresponding author, e-mail: sergio.gehrke@hotmail.com
DOI: 10.1563/AAID-JOI-D-12-00252



FIGURES 1 AND 2. FIGURE 1. Initial (a) clinical and (b) radiographic aspects. **FIGURE 2.** Image (a) after removal of crown and (b) of the osteotomy to remove the implant, and aspects 30 days after the remotion.

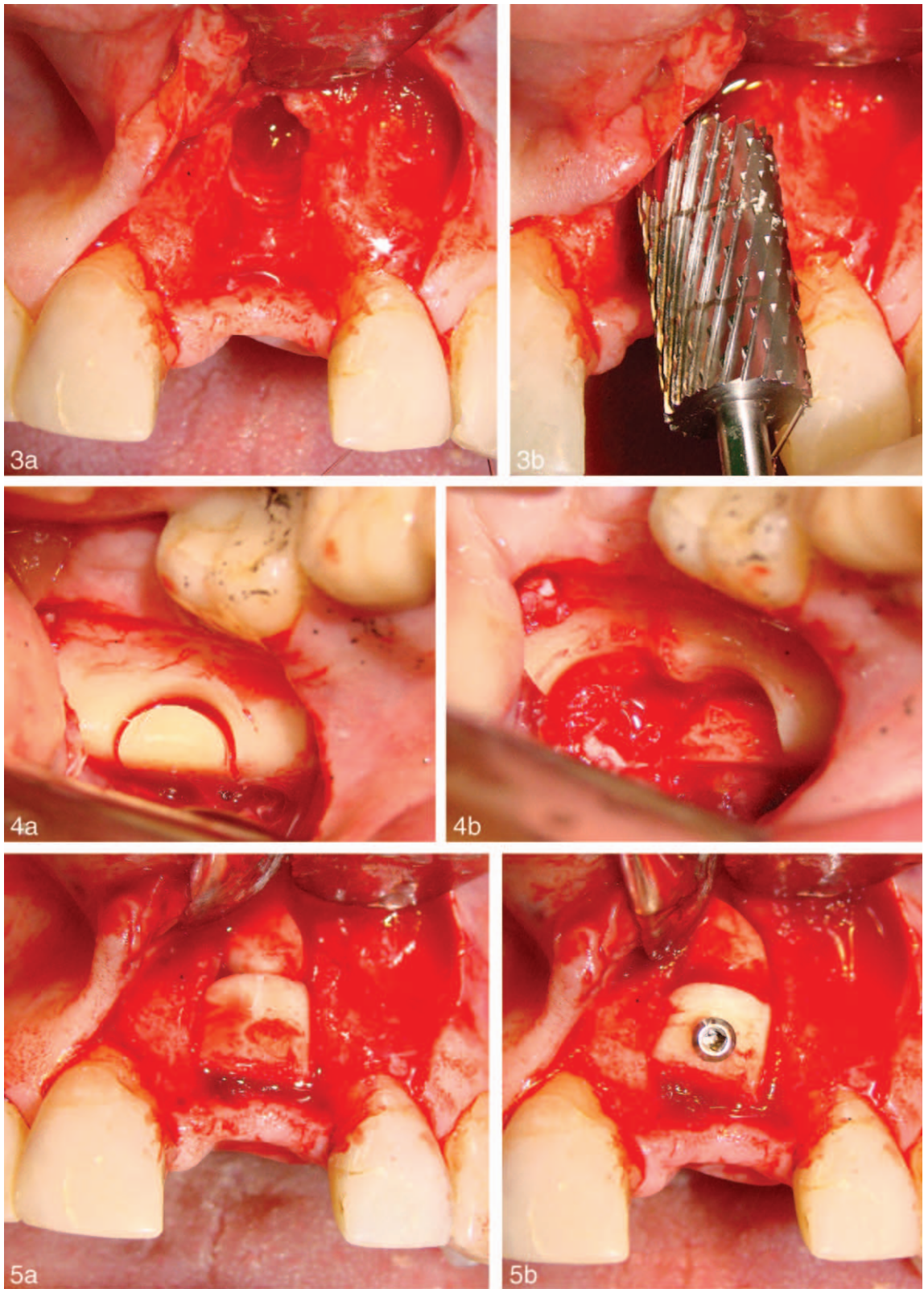
an autogenous block bone graft, and subsequent placement of another implant. However, the treatment option of replacing the implant with only a new osteotomy was discarded because of the complexity of the case and the need for a more predictable outcome.

Because of the inadequate volume of soft tissue, it would be difficult to remove the implant, place an immediate bone graft, and simultaneously achieve tension-free closure of the gingival tissue. Therefore, it was decided to remove the implant (Figure 2a and b), place a temporary removable prosthesis, and allow for adequate soft-tissue healing (30 days) before proceeding with the placement of a bone graft (Figure 2c). The space remaining between the adjacent teeth was larger than that of a normal-sized left central incisor.

Following a 30-day healing period, the patient underwent surgery for placement of bone graft. Local anesthesia was performed by the terminal

infiltrative technique on buccal and palatal regions. A horizontal incision through the gingival tissue was made on the crest of the ridge between tooth No. 8 (maxillary right central incisor) and tooth No. 9 (maxillary left central incisor). The incision then was extended to the gingival sulcus of these adjacent teeth. In addition, a vertical relaxing incision at the distal labial aspect of tooth No. 7 (maxillary right lateral incisor) was made. A full-thickness mucoperiosteal flap was then reflected to expose the relevant bone (Figure 3a). The recipient site grafting bed was prepared by using a conforming drill (Figure 3b) from the Transfer-Control kit (Hager and Messinger GmbH, Neuss, Germany).

Subsequent local anesthesia was performed by the terminal infiltrative technique on buccal and lingual regions of the mandibular ramus, and a horizontal incision in the gingival tissue was made on the crest of the area corresponding to tooth No.



FIGURES 3–5. **FIGURE 3.** Image of the second surgery, after opening and elevation of mucosa and use of drill for conformation of the receptor. **FIGURE 4.** Access to the mandibular ramus, marking with a trephine (a) and removing blocks (b) to graft. **FIGURE 5.** Positioning of the (a) fragments and (b) placement of the screw.

17 (mandibular left third molar). The incision then was extended to the gingival sulcus of tooth No. 18 (mandibular left second molar), and a vertical relaxing incision at the distal labial aspect of this tooth was made. A full-thickness mucoperiosteal flap was reflected. Using the corresponding trephine bur system (Figure 4a and b), two bone blocks (one large and one small) were removed from the anterior mandible. The use of the corresponding trephine system made it easier to acquire bone blocks of the adequate volume and length and to fixate the graft (Figure 5a and b). The smaller block was used to fill the apical portion of the bone defect. Soft-tissue closure was achieved with 5-0 nylon sutures (Johnson & Johnson, Ethicon, Blue Ash, Ohio; Figure 6a). On postoperative day 7, sutures were removed and a confirmation radiograph taken (Figure 6b).

After 4 months, a radiographic (Figure 7a) and clinical examination (Figure 7b) verified signs of healing of the bone. Subsequently, surgery for replacement of a new implant was performed.

A conical implant Morse taper 4 mm in diameter by 13-mm in length Implacil DeBortoli (São Paulo, Brazil) was placed 1 mm below the crestal bone level (Figure 8a and b). An abutment head 3.5 mm in diameter by 6 mm in height was immediately installed, and the provisional prosthesis was prepared (Figure 9a and b). Recheck radiographs were made after 7 and 90 days (Figure 10a and b).

At each surgery, the patient was treated with antibiotics (amoxicillin, 875 mg, 12/12 hours) for a period of 5 days and with an anti-inflammatory medication (profenid, 100 mg, 12/12 hours) for 3 days.

Three months following initiation of the implant procedures, the abutment was replaced with a new abutment measuring 4.5 mm in diameter. In addition, a metal-free crown was prepared and cemented (Figure 11a–c).

DISCUSSION

This case letter describes the correction of an esthetic defect caused by an error committed during the positioning of an implant. Ideal 3-dimensional implant placement and its relative positioning to neighboring teeth have been shown to influence the hard- and soft-tissue remodeling

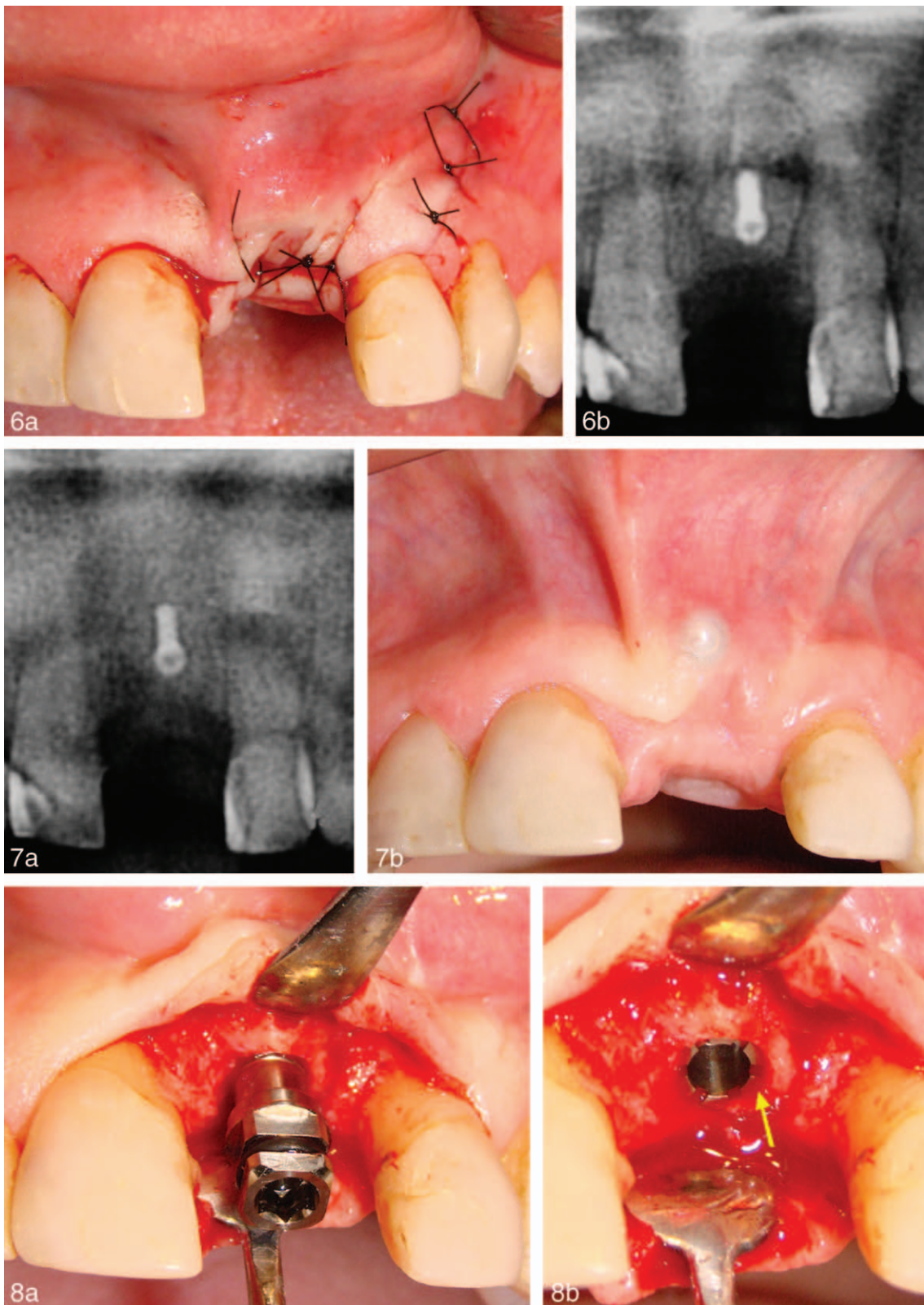
process during healing and after the abutment connection for 2-stage implant systems.⁹ Esthetic and functional demands require peri-implant soft-tissue contours that are in harmony with the adjacent dentition. This includes the presence of intact papillae and the appropriate location of the peri-implant mucosal margin on the labial aspect of an implant-supported restoration.¹⁰

Immediate implant placement is a technique widely used today. However, collapse of hard and soft tissues can lead to an esthetic complication.³ In addition, in this case, the selection of a 5-mm diameter and its angulation accommodated the available tooth space and available soft-tissue volume. The removal of an implant often results in bone and soft-tissue defects that require subsequent surgical correction.^{8,11}

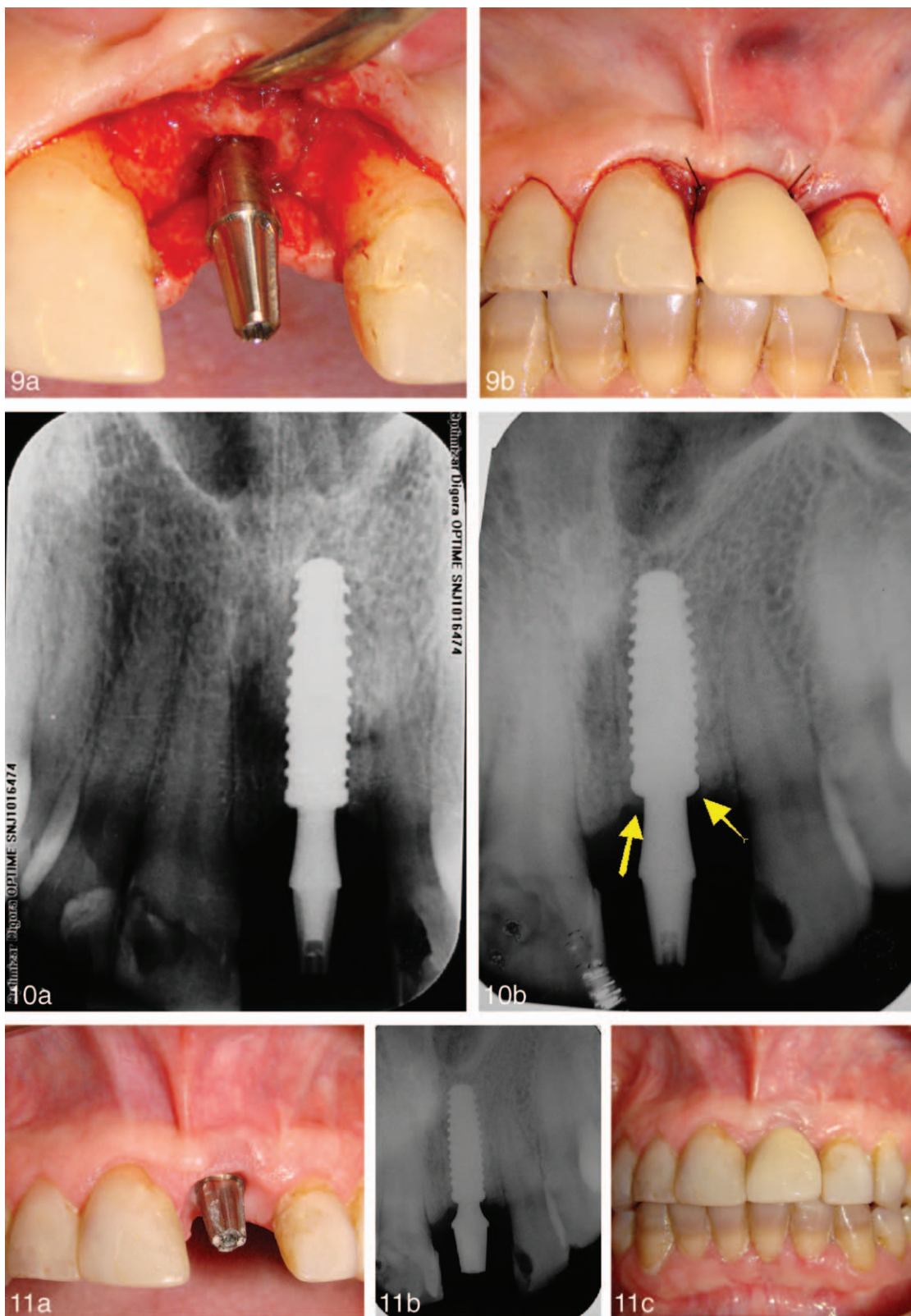
The reestablishment of normal tissue volume, contour, and architecture around dental implants may require the use of various augmentation techniques (both hard and soft tissue), depending on the magnitude and dimension of the defect. The position of the mucogingival junction, width of the keratinized mucosa, and time of intervention determine the type of procedure.¹² Several other factors have also been described that influence the stability of the peri-implant mucosa at the facial aspect, such as the mucosal quality (keratinized vs nonkeratinized), the mucosal attachment (mobile vs nonmobile), and the mucosal thickness.¹³ The etiology for soft-tissue fenestration or dehiscence may be due to excessive labial positioning of the implant and/or insufficient labial bone.^{14,15}

Segmental osteotomy is an alternative because many authors have reported long-term success of the correction of malpositioned implants with this technique.^{7,8,11,16,17} In addition, free and subepithelial connective tissue gingival grafts have been used to improve soft-tissue quality and quantity.⁷ However, as this patient had been previously submitted to some attempts to gingival enlargement, without success, the proposition of implant removal, autologous bone graft, and placement of a new implant was accepted. To minimize trauma, minimally invasive surgery, with more delicate and predictable instruments and techniques, was used.

This case letter has shown that the recuperation of esthetic defects in dental implants may be complex and lengthy.



FIGURES 6–8. **FIGURE 6.** (a) The suture and (b) the radiography of control at 7 days. **FIGURE 7.** The (a) radiographic and (b) clinical aspects after 4 months. **FIGURE 8.** Image of (a) the implant insertion and (b) the position 1 mm below the bone level (yellow arrow).



FIGURES 9–11. **FIGURE 9.** The (a) abutment positioned and (b) temporary tooth. **FIGURE 10.** Radiographic control, (a) 7 days and (b) 4 months postoperation. The yellow arrow indicates a possible bone growth on the implant platform. **FIGURE 11.** The (a) abutment with diameter of 4.5 mm, (b) the x-ray, and (c) metal-free crown cemented.

REFERENCES

1. Steigmann M, Wang HL. Esthetic buccal flap for correction of buccal fenestration defects during flapless immediate implant surgery. *J Periodontol.* 2006;77:517–522.
2. Barzilay I, Graser G, Iranpour B, Natiella J. Immediate implantation of a pure titanium implant into extraction socket: report of a pilot procedure. *Int J Oral Maxillofac Implants.* 1991;6:277–284.
3. Araújo MG, Wennström JL, Lindhe J. Modeling of the buccal and lingual bone walls of fresh extraction sites following implant installation. *Clin Oral Implants Res.* 2006;17:606–614.
4. Botticelli D, Renzi A, Lindhe J, Berglundh T. Implants in fresh extraction sockets: a prospective 5-year follow-up clinical study. *Clin Oral Implants Res.* 2008;19:1226–1232.
5. Klokkevold PR. Implant-related complications and failures. In: Newman MG, Takei HH, Perry R. Klokkevold, eds. *Carranza's Clinical Periodontology.* 10th ed. Philadelphia, Penn: WB Saunders; 2006:1182–1192.
6. Vermylen K, Collaert B, Lindén U, Björn AL, De Bruyn H. Patient satisfaction and quality of single-tooth restorations. *Clin Oral Implants Res.* 2003;14:119–124.
7. Guerrero CA, Laplana R, Figueredo N, Rojas A. Surgical implant repositioning: a clinical report. *Int J Oral Maxillofac Implants.* 1999;14:48–54.
8. Kassolis JD, Baer ML, Reynolds MA. The segmental osteotomy in the management of malposed implants: a case report and literature review. *J Periodontol.* 2003;74:529–536.
9. Esposito M, Hirsch J, Lekholm U, Thomsen P. Differential diagnosis and treatment strategies for biologic complications and failing oral implants: a review of the literature. *Int J Oral Maxillofac Implants.* 1999;14:473–490.
10. Shibli JA, d'Avila S, Marcantonio E Jr. Connective tissue graft to correct peri-implant soft tissue margin: a clinical report. *J Prosthet Dent.* 2004;91:119–122.
11. Poggio CE, Salvato A. Implant repositioning for esthetic reasons: a clinical report. *J Prosthet Dent.* 2001;86:126–129.
12. El Askary AS. Use of connective tissue grafts to enhance the esthetic outcome of implant treatment: a clinical report of 2 patients. *J Prosthet Dent.* 2002;87:129–132.
13. Bengazi F, Wennstrom, JL, Lekholm, U. Recession of the soft tissue margin at oral implants. *Clin Oral Implants Res.* 1996;7:303–310.
14. Wennstrom JL, Lindhe J, Sinclair F, Thilander B. Some periodontal tissue reactions to orthodontic tooth movement in monkeys. *J Clin Periodontol.* 1987;14:121–129.
15. Bashutski JD, Wang HL. Common implant esthetic complications. *Implant Dent.* 2007;16:340–348.
16. Storum K, Carrick JL. Implant-osseous osteotomy for correction of the misaligned anterior maxillary implant. *Dent Clin North Am.* 2001;45:181–187.
17. Warden PJ, Scuba JR. Surgical repositioning of a malposed, unserviceable implant: case report. *J Oral Maxillofac Surg.* 2000;58:433–435.