

# Alveolar Cleft Restoration Using Autogenous Tooth Bone Graft Material for Implant Placement: A Case Report

Kyung-In Jeong, DDS<sup>1†</sup>

Junho Lee, DDS<sup>2†</sup>

In-Woong Um, DDS, PhD<sup>3</sup>

Young-Kyun Kim, DDS, PhD<sup>4,5\*</sup>

## INTRODUCTION

Restoration of an alveolar cleft with bone grafting is necessary to stabilize alveolar segments, close oronasal fistulas, and provide bony support and volume for future implant placement where necessary. However, choosing appropriate bone grafting materials for the rehabilitation of cleft alveolus is not simple. Several studies have evaluated the available therapeutic choices to treat inadequate alveolar bone quantity and or quality to enable implant placement in cleft alveolar ridges.<sup>1–6</sup>

With the development of biomaterials and tissue engineering, implant therapy has been a reliable choice of treatment—even in alveolar cleft patients—due to the variety of available bone augmentation materials.

Autogenous bone is considered to be the gold standard bone graft due to its osteoconductivity, osteoinductivity, and osteogenicity. Nonetheless, autogenous bone grafting typically requires extensive surgeries with possible complications, such as postoperative pain and infection. Studies have attempted to identify an autogenous graft without the limitations of known autogenous grafts, and some researchers have become interested in the use of human dentin from extracted teeth in this context.<sup>7–12</sup> Dentin consists of inorganic and organic components that are very similar to human bone. In dentin, the inorganic content is near 75%, whereas the organic content is approximately 20%. Type I collagen composes up to 90% of the organic contents in dentin, and it plays a critical role in bone formation and mineralization. Dentin also contains bone morphogenetic proteins (BMPs), which promote the differentiation of mesenchymal stem cells into osteocytes and thus enhance bone formation.<sup>13</sup> In addition, both alveolar bones and teeth are derived from neural crest cells, and their organic and inorganic contents are therefore very similar to each other. Based on previous studies of rabbit and human dentin<sup>7,9,10,13</sup> researchers have developed an autogenous bone graft material made from extracted human teeth. Studies have demonstrated that autogenous tooth bone (AutoBT) graft

material has potential osteoconductive, osteoinductive, and bone remodeling capabilities.<sup>1,10,11</sup>

Recently, clinicians have explored the option of using this novel AutoBT in alveolar cleft restoration.<sup>1,5</sup> Here, we present a clinical case of restoration of an alveolar defect using AutoBT for site preparation prior to implant placement.

## CLINICAL CASE

### *Patient history, clinical examination, and teeth extraction for graft harvesting*

A 19-year old nonsmoking Korean male patient with a history of cleft lip and palate was referred from his orthodontist for the extraction of an impacted right maxillary lateral incisor and subsequent implant placement. The patient received a cleft lip surgery around 5 months after birth followed by a cleft palate surgery around the age of 6 years. However, types of surgeries were unknown since these were performed at a different hospital. After a series of surgeries, the patient started orthodontic treatment to correct an open bite, class III molar malocclusion, and the impacted right maxillary lateral incisor. The impacted right maxillary lateral incisor was initially orthodontically selected for forced eruption (Figures 1 and 2). However, due to its mobility and hopeless prognosis, extraction was inevitable. The patient was then transferred to our clinic to restore the alveolar defect followed by implant placement and the completion of orthodontic treatment. A clinical examination showed no existing oronasal fistula, and the intraoral conditions were within normal limits. In order to process AutoBT, right and left mandibular third molars were extracted under local anesthesia. The extraction socket was rinsed with saline, and curettage was performed. The extraction and wound healing were uneventful. The extracted teeth were stored in 75% alcohol and, with a consent form signed by the patient, were delivered to the Korea Tooth Bank for fabrication into AutoBT.

### *Autogenous tooth bone (AutoBT) graft material preparation*

The anatomical crown portion of the extracted tooth was dissected after removal of the attached soft tissues. Sample root portions were crushed into a particulate form, with sizes ranging from 400–800  $\mu\text{m}$  in diameter. Any remaining soft tissues and contaminants in the AutoBT particulate were removed with distilled water. AutoBT powder was then dehydrated and defatted, followed by lyophilization. After sterilization with ethylene oxide gas, the AutoBT powder was

<sup>1</sup> Department of Oral and Maxillofacial surgery, Section of Dentistry, Konyang University Hospital, Daejeon, Korea.

<sup>2</sup> Private practice, Zelkova Tree Dental Clinic, Seoul, Korea.

<sup>3</sup> Korea Tooth Bank, R&D Institute, Seoul, Korea.

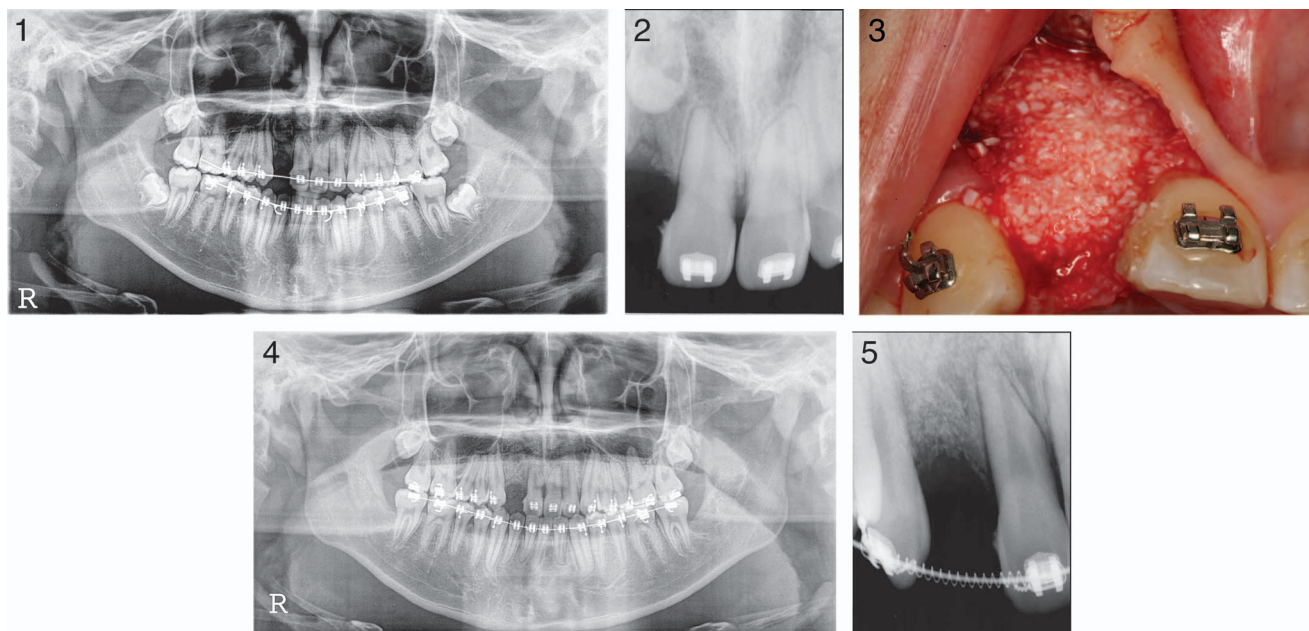
<sup>4</sup> Department of Oral and Maxillofacial Surgery, Section of Dentistry, Seoul National University Bundang Hospital, Seongnam City, Korea.

<sup>5</sup> School of Dentistry, Seoul National University, Seoul, Korea.

\* Corresponding author, e-mail: kyk0505@snuh.org

† Co-first authors.

DOI: 10.1563/AAID-JOI-D-12-00265



**FIGURES 1–5.** **FIGURE 1.** Initial panoramic radiograph. **FIGURE 2.** Periapical radiograph showed an impacted #7 around cleft alveolus defect at the first visit to our clinic. **FIGURE 3.** Autogenous tooth bone graft material (AutoBT) was fabricated using extracted #17 and 32 and was grafted at the cleft alveolus defected site. **FIGURE 4.** Panoramic radiograph immediately after AutoBT grafting. **FIGURE 5.** Two-week follow-up periapical radiograph.

packaged (Patent number: 10-1062381, Republic of Korea). The processing time took 10 days. The amount of AutoBT varied depending on the condition of tooth. Incisors provided approximately 0.2 to 0.6 cc, whereas molars provided approximately 0.6 to 1.0 cc. In the present case, since 2 mandibular third molars were processed, clinicians were able to obtain 1.8 cc of AutoBT.

#### ***Tooth extraction and alveolar ridge restoration***

The patient was prepared for intraoral surgery in a sterile environment, and a preoperative rinse with 0.2% chlorhexidine was performed. A crestal incision with a distal vertical incision was performed to raise a full thickness flap. The cleft defect was completely exposed, and the impacted right maxillary lateral incisor was extracted. The particulate AutoBT, fabricated from previously extracted right and left mandibular third molars, was condensed at the bony defect site (Figure 3). Then, an Ossix Plus membrane (OraPharma Inc, Warminster, Pa) was placed over the AutoBT. The flap was primarily closed with 3-0 Vicryl sutures (ETHICON Inc, Somerville, Mass). Panoramic radiographs (Heliodent DS, Sirona, Bensheim, Germany) were taken with settings of 60 KVp, 7 mA, and 0.25 seconds to confirm alveolar ridge restoration (Figure 4). The grafting procedure was uneventful, and a 2-week follow-up appointment was made to evaluate the integrity of the AutoBT graft (Figure 5).

#### ***Implant placement***

Reentry at 3.5 months for implant placement demonstrated an augmented alveolar ridge without any remaining cleft at the grafted area (Figure 6). The ridge volume appeared to be favorable for implant placement. An implant fixture (Astra Tech

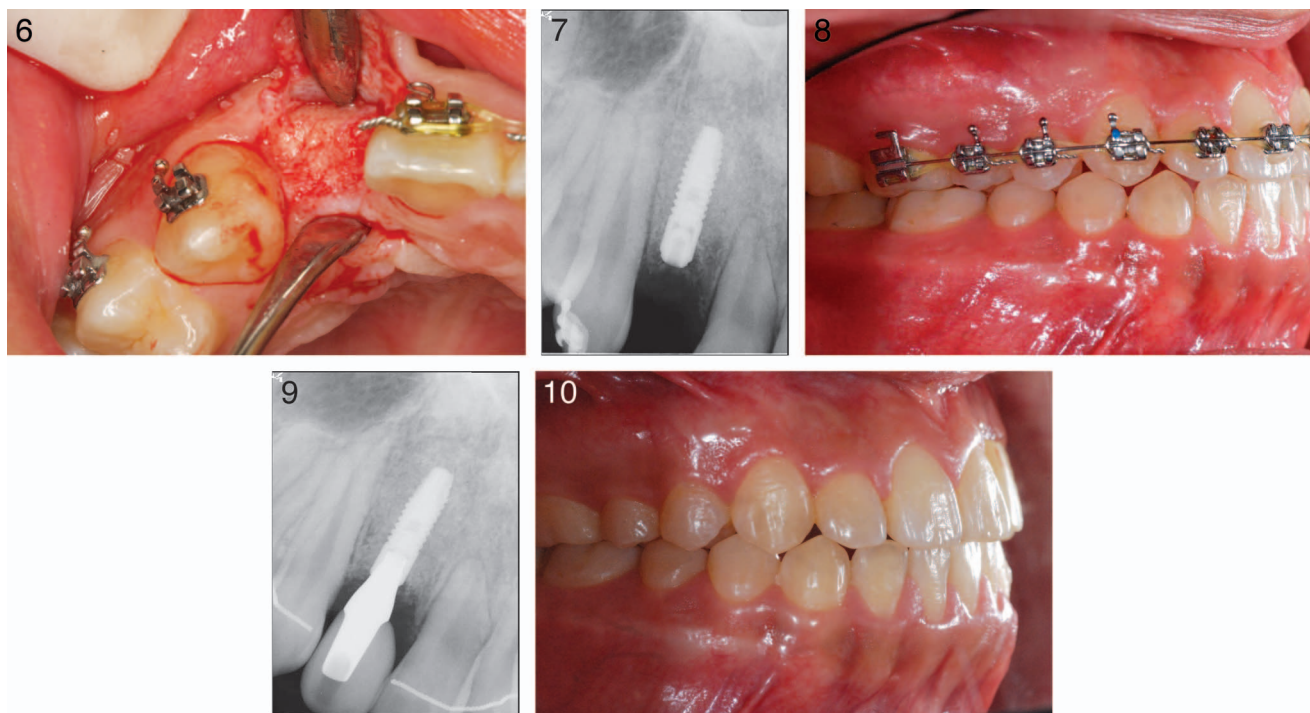
AB, Mölndal, Sweden) 3 mm in diameter and 11 mm in length was placed with an initial locking torque of 45 Ncm according to the routine and suggested protocols of the company (Figure 7). The flap was primarily closed with 3-0 Vicryl sutures. The implant placement surgery was uneventful. A prefabricated resin-bonded interim prosthesis was provided to the patient for esthetic reasons (Figure 8). Care was taken not to leave any occlusal contact on the provisional prosthesis in any excursive movement or centric occlusion. Postoperative medications included methylol cephalixin lysinate, 500 mg; meloxicam, 7.5 mg; and chlorhexidine gluconate solution, 0.1% 300 cc. The patient was advised not to brush the surgical site for 7 days. Soft diet was also recommended.

#### ***Implant restoration***

We allowed 6 months for healing and osseointegration of the placed implant. The implant was restored using a zirconia-customized abutment, and the final all-ceramic crown prosthesis was delivered.

#### ***Follow-ups***

There was no evidence of postoperative complications found at the follow-up examinations after the surgeries. Favorable oral hygiene was observed, and there were no periodontal issues found at the follow-up visits. On radiographic examination, the implant appeared to be within the normal limits of healing without any radiolucency associated with the fixture. During the 6-month follow-up evaluation after placing the functional prosthesis, there were no radiographic or clinical signs of implant failure, and orthodontic bracket removal was achieved (Figures 9 and 10).



**FIGURES 6–10.** **FIGURE 6.** Three and a half months after autogenous tooth bone graft, flap was raised for implant placement. **FIGURE 7.** Periapical radiograph of placed implant fixture immediately after the surgery. **FIGURE 8.** Three-month follow-up intraoral picture after implant placement with nonfunctional interim prosthesis. **FIGURE 9.** Periapical radiograph of the final implant prosthesis after 6-month of loading period. **FIGURE 10.** Final intraoral picture.

#### DISCUSSION

The objective of alveolar cleft restoration is to close the cleft and augment the ridge dimensions to accommodate implant fixture placement. For the repair of alveolar defects, the choice of grafting material has been debated over time. Traditionally, cancellous bone grafts were widely used in the management of alveolar cleft because successful bone remodeling was observed through rapid vascularization and osteoblastic activity.<sup>2,4</sup> Bosker and van Dijk showed the effectiveness and efficiency of the clinical use of mandibular chin bone as the choice of material for the reconstruction of alveolar atrophies. The mandibular bone graft is more accessible for harvesting and requires shorter operating times, leaving invisible intraoral scarring compared to the conventional iliac crest bone graft.<sup>2,3</sup> Moreover, due to the presence of cortical bone, intramembranous mandibular bone grafts retain more bone space through less resorption than an endochondral bone graft at the area of the alveolar cleft for future implant placement.<sup>3,4</sup>

Nevertheless, traditional autogenous bone grafts possess a few considerable pre- and postoperative drawbacks. In addition to the high costs involved, the procedure requires a donor site operation, leading to a longer operation time with an increased risk of postoperative complications, such as infection, discomfort, scarring, and unwanted changes in the facial profile.

To maintain the optimal autograft properties and improve the known limitations of intraoral autografting, AutoBT was recently introduced.<sup>11,12</sup> AutoBT is made from a patient's own extracted teeth. Vital teeth, including wisdom teeth, deciduous teeth, and extracted premolars, are used to fabricate AutoBT.

The fact that there is no need for donor site surgery adds to the simplicity and efficiency of AutoBT grafts.

AutoBT consists of 55% inorganic and 45% organic substances by weight.<sup>4</sup> These constituents, particularly type I collagen and noncollagenous proteins, closely resemble those in alveolar bone. Previous studies of AutoBT have demonstrated notable bone formation and remodeling through osteoconduction and osteoinduction.<sup>1,5,10–12</sup> Hence, reentry to the grafted site as early as 3.5 months was possible in the present case because of similar remodeling process and chemical compositions to alveolar bone. More importantly, with the use of a patient's own extracted tooth in AutoBT fabrication, the known issues of technique sensitiveness and postoperative patient comfort involved in using the conventional autogenous bone graft can be resolved. Thus, for patients who require extraction, and future implant placement is planned with site development, AutoBT can be considered as an excellent substitute to other bone graft materials.

Despite the discussed advantages of AutoBT, there remain a few limitations to AutoBT grafts. Tooth extraction is necessary, and simultaneous implant placement cannot be performed for sequential issues. Additionally, the number of teeth available for extraction is limited resulting unpredictable amount of bone graft material to be obtained.

In the presented case report, the use of AutoBT showed a favorable outcome in implant site development and implant placement, demonstrating that AutoBT is a potential substitute for autogenous bone grafts in alveolar cleft. However, insufficient evidence of histological assessment at the grafted

site, and a short follow-up time (6 months) remain as limitations. Esthetically, the restored clinical crown appeared to be longer than the left maxillary left incisor probably due to the reasons of insufficiently achieved vertical augmentation and partial bone resorption during the remodeling process. Within the limitations of this case report and future material development, we foresee increased use of AutoBT in various types of alveolar ridge augmentation in future implant dentistry.

**ABBREVIATIONS**

AutoBT: autogenous tooth bone  
BMP: bone morphogenetic protein

**REFERENCES**

1. Jeong KI, Kim SG, Kim YK, Oh JS, Jeong MA, Park JJ. Clinical study of graft materials using autogenous teeth in maxillary sinus augmentation. *Implant Dent.* 2011;20:471-475.
2. Rawashdeh MA, Telfah H. Secondary alveolar bone grafting: the dilemma of donor site selection and morbidity. *Br J Oral Maxillofac Surg.* 2008;46:665-670.
3. Enemark H, Jensen J, Bosch C. Mandibular bone graft material for

reconstruction of alveolar cleft defects: long-term results. *Cleft Palate Craniofac J.* 2001;38:155-163.

4. Boyne PJ, Sands NR. Secondary bone grafting of residual alveolar and palatal clefts. *J Oral Surg.* 1972;30:87-92
5. Park SM, Um IW, Kim YK, Kim KW. Clinical application of auto-tooth bone graft material. *J Korean Assoc Oral Maxillofac Surg.* 2012;38:2-8.
6. Johansson B, Grepe A, Wannfors K, Hirsch JM. A clinical study of changes in the volume of bone grafts in the atrophic maxilla. *Dentomaxillofac Radiol.* 2001;30:157-161.
7. Bang G, Urist MR. Bone induction in excavation chambers in matrix of decalcified dentin. *Arch Surg.* 1967;94:781-789.
8. Urist MR, Nakata N, Felsner JM. An osteosarcoma cell and matrix retained morphogen for normal bone function. *Clin Orthop.* 1977;124:251-266.
9. Bessho K, Tagawa T, Murata M. Purification of rabbit bone morphogenetic protein derived from bone, dentin, wound tissues after tooth extraction. *J Oral Maxillofac Surg.* 1990;48:162-169.
10. Butler WT, Mikulski A, Urist MR. Noncollagenous proteins of a rat dentin matrix processing bone morphogenetic activity. *J Dent Res.* 1977;56:228-232.
11. Kim YK, Kim SG, Byeon JH, et al. Development of a novel bone grafting material using autogenous teeth. *Oral Surg Oral Med Oral Pathol Oral Radiol Endod.* 2010;109:496-503.
12. Kim YK, Kim SG, Oh JS, et al. Analysis of the inorganic component of autogenous tooth bone graft material. *J Nanosci Nanotechnol.* 2011;11:7442-7445.
13. Kawai T, Urist MR. bovine tooth derived bone morphogenetic protein. *J Dent Res.* 1989;68:1069-1974.