

# Guided Bone Regeneration for Socket Preservation in Molar Extraction Sites: Histomorphometric and 3D Computerized Tomography Analysis

Stephen C. Wallace, DDS, MHS\*

## INTRODUCTION

**D**eveloping ideal sites for implant placement after tooth extraction depends on controlling the resorption and remodeling phenomena that is inevitably seen during healing of extraction sites. Bone resorption, vertically and horizontally, occurs most rapidly in the first 3 months after extractions,<sup>1</sup> so immediate augmentation is important at the time of extraction. Augmentation of extraction sites will prevent most resorption, thus preventing the necessity of future ridge augmentation procedures in order to have optimal positioning for implant placement. Autogenous bone is the first choice for augmentation due to the inherent osteogenic, osteoconductive, and osteoinductive properties, but limited quantities and a second surgery adding significant morbidity make a substitute material highly desirable. Numerous materials have been used for socket graft augmentation including autogenous bone, xenografts, allografts, alloplasts, and combinations of these.<sup>2-5</sup> Use of mineralized cancellous particulate allograft has been reported in numerous studies for sinus grafts, guided bone regeneration procedures, implant defects, furcation defects, and socket grafting.<sup>6</sup> Placement of a barrier over grafted socket sites has been shown to be essential to prevent soft tissue ingrowth and encapsulation of graft particles.<sup>7,8</sup> Barriers used over graft materials include resorbable and nonresorbable membranes with varying results with regard to graft retention and regeneration.<sup>9-12</sup>

The size of an extraction site defect affects the

extent of bone regeneration that occurs, so the combination of a socket graft with a barrier membrane is important in larger defects such as molar extraction sites to maximize woven bone regeneration throughout the site.<sup>13</sup> Complete flap closure over a grafted socket site is important in preventing infection and interference with maximal bone regeneration.<sup>14</sup>

Acellular dermis matrix (ADM) is cadaveric tissue that has had cellular components removed. Its remaining collagen scaffold structure lends itself to ingrowth of endothelial and fibroblast cells. Originally developed as therapy for burn patients,<sup>15</sup> reports have demonstrated positive results with ADM used as a guided bone regeneration barrier membrane in combination with different graft materials in socket preservation surgery.<sup>15-20</sup> However, there are few reports providing histologic data on new bone regeneration in extraction sockets where cortical or cancellous allograft has been used specifically with ADM for the guided bone regeneration barrier.<sup>21</sup> A new ADM is available that does not have to be hydrated before use. The purpose of this case series is to obtain data showing the histologic and clinical results of this new decellularized dermis matrix (DDM) used as a guided bone regeneration barrier over mineralized cancellous bone allograft (MCAB) in molar extraction sites in preparation for implant placement.

## MATERIALS AND METHODS

This study protocol was carried out with patient consent following guidelines according to the Helsinki Declaration of 1975, as revised in 2000. Subjects were between 25 and 70 years of age. Subjects excluded were: those with active periodontal disease, evident periapical radiolucencies or

Stephen C. Wallace, DDS, MHS, Wilmington, NC  
\* Corresponding author, e-mail: scwperio@bizec.rr.com  
DOI: 10.1563/AAID-JOI-D-13-00001

abscesses, autoimmune disorders, or uncontrolled diabetes; those taking bisphosphonate medications for osteoporosis, or congenital or metabolic bone disorders; smokers; and pregnant women. Six male patients and 2 female patients participated in this study. Surgeries were carried out with monitored intravenous sedation using an automatic pulse oximeter displaying heart rate, electrocardiogram, oxygen saturation, and blood pressure. Sedation was initiated with intravenous injection of medications that were titrated to induce and maintain the desired level of conscious sedation. Lidocaine (2%) with 1:100 000 epinephrine (Novocol, Septodont Inc, Ontario, Canada) was used for block and local anesthesia.

### ***Surgical method***

Atraumatic extraction of unsalvageable teeth as shown in Figures 1 and 2 was performed by elevating a full-thickness flap and sectioning horizontally to remove the clinical crown, then separating roots of molars with fissure burs, periostomes, and elevators. Sockets were debrided of epithelial remnants as shown in Figure 3 and grafted to fill the sockets with particulate MCAB, particle size 1000 to 2000  $\mu$  as shown in Figure 4 (OraGRAFT, LifeNet Health, Virginia Beach, Va). Sterile normal saline was used to wet the particulate bone graft. The mixture of bone and liquid was then placed with light compression to completely fill the extraction site. DDM (OrACELL, LifeNet Health, Virginia Beach, Va) was rinsed thoroughly in sterile saline for 1 minute, according to the manufacturer's recommendations to remove the preservative medium. The tissue was then cut to the appropriate shape to cover each socket site, extending 10 mm past the socket rim when used to cover intact sockets, and extended as necessary to cover bone wall defects completely when present as shown in Figure 5. Flaps were then released with tissue spreading using curved Iris scissors (Salvin Dental Specialties, Charlotte, NC) and periosteal scoring, then advanced to completely cover the ADM.

Continuous mattress PTFE 4-0 (Cytoplast, Osteogenics, Lubbock, Tex) or polypropylene 6-0 sutures were used to achieve full closure of flaps where possible. Augmentin (GlaxoSmithKline, Research Triangle Park, NC) antibiotic and hydroxycodone with ibuprofen for analgesia were prescribed for 5 days for all subjects postsurgically. Postsurgical

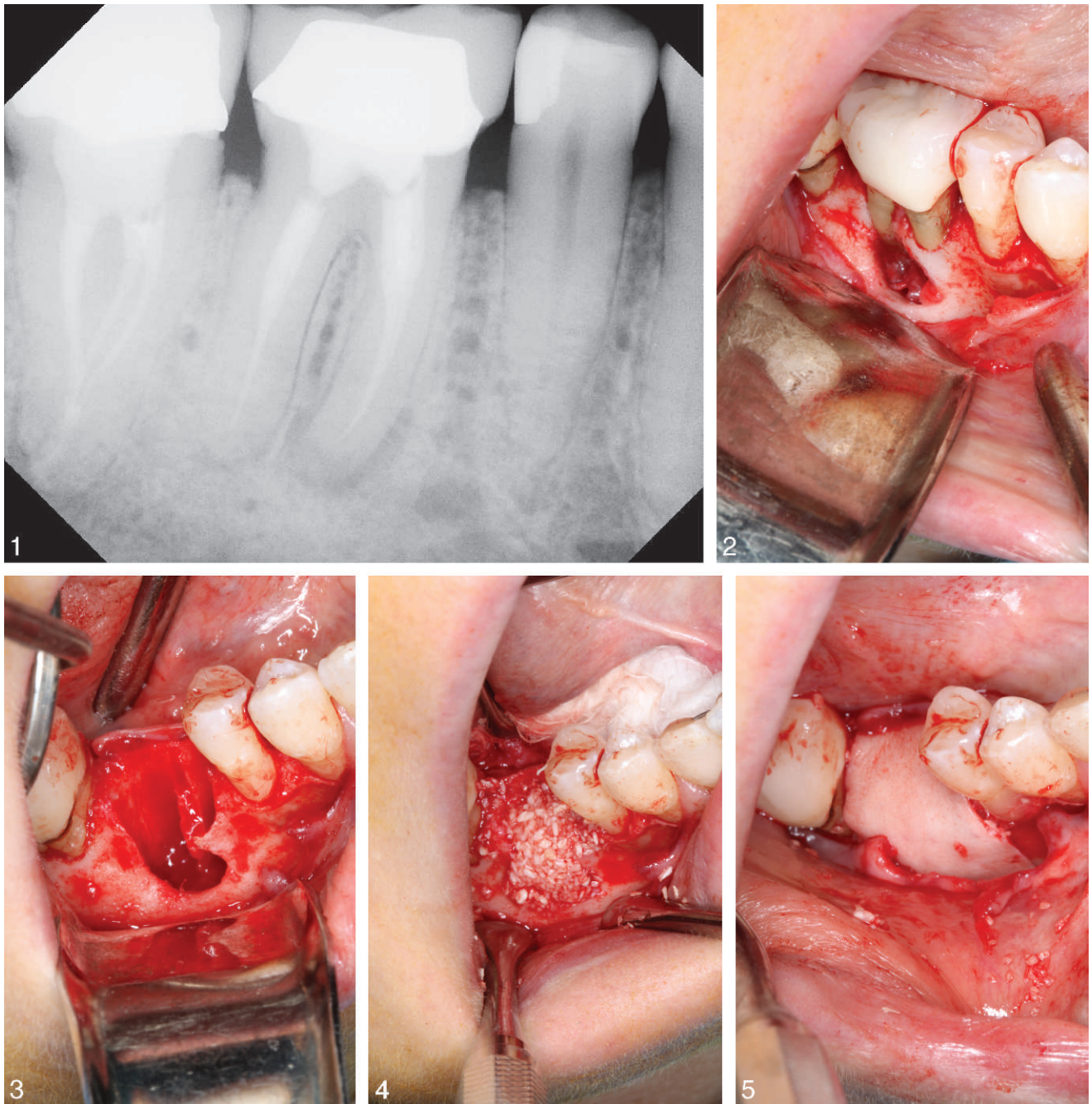
radiographs (Figure 6) were taken at the first appointment after the surgery for suture removal. These typically showed bone graft fill even with the socket bony rim. Each socket site was allowed to heal for 12 weeks before reentry. At the time of reentry for implant placement, a 3-dimensional cone-beam computerized tomographic scan (Prexion, San Mateo, Calif) as shown in Figures 7 and 8 was taken prior to implant placement surgery for evaluation of bone width, height, and measurement of the bone density in Hounsfield units. A 10-mm trephine with a 2.0-mm internal diameter (Salvin Dental Specialties, Charlotte, NC) as shown in Figure 9 was used to harvest bone cores for histomorphometric analysis as the first step in the implant osteotomy. The osteotomy was then completed, increasing in size up to the final drill size corresponding to the diameter of the implant chosen for the site. Implant placement is shown in Figure 10. Each implant (Internal RBT Laser-Lok, BioHorizons, Birmingham, Ala) was stable upon seating to a maximum torque of 50 Ncm or less. Figures 11 and 12 show an example of the restored implant's radiograph and photograph.

### ***Histologic preparation description***

Specimens contained within titanium trephines were processed and embedded into methyl methacrylate resin, thick sectioned longitudinally to collect 3 slides per specimen, and ground/polished to approximately 35  $\mu$ . All specimens were stained with Sanderson's Rapid Bone Stain for light microscopy. Histomorphometric analysis was conducted on all slides to calculate percent soft tissue, percent residual particle area, and percent new bone, with vital bone distinguished from nonvital bone by the presence of cells in the lacunae as shown in Figure 13, for each individual slide prepared.

### **RESULTS**

This private practice-based case series included 6 patients, 2 women, 4 men. All extractions were molar teeth. A significant number of the unsalvageable teeth were endodontically treated with root fractures. All sites were reentered for bone trephine biopsy as the first step in implant placement after a minimum of 12 weeks. The trephined bone cores were composed of a combination of vital bone,



**FIGURES 1–5.** **FIGURE 1.** Pretreatment periapical radiograph of number 30. **FIGURE 2.** Flap reflection showing bone defect from previous apicoectomy. **FIGURE 3.** Defect after atraumatic extraction number 30. **FIGURE 4.** Socket grafted with mineralized cancellous allograft. **FIGURE 5.** Decellularized dermis covering socket graft.

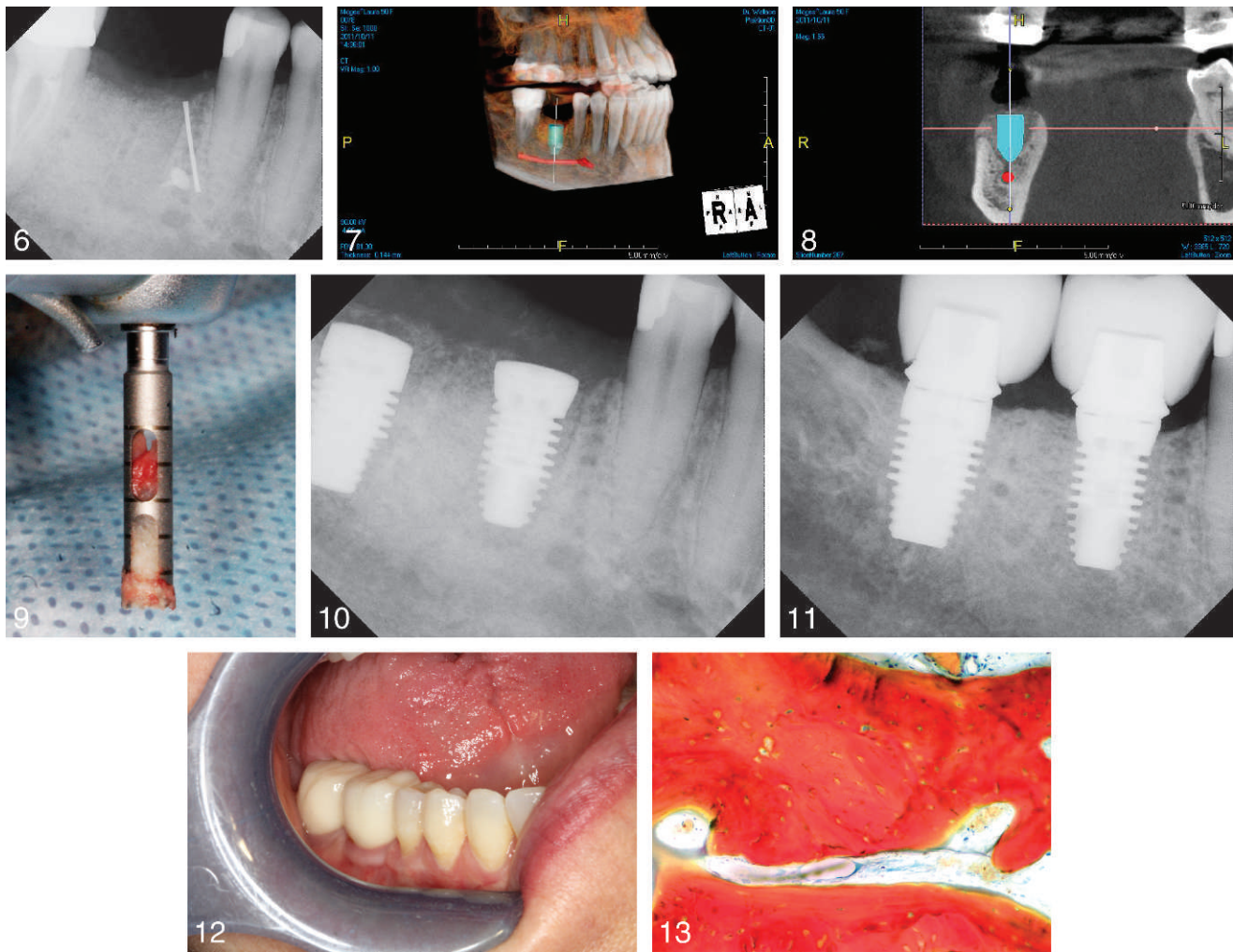
nonvital residual graft material, and fibrous tissue. The histomorphometric data shown in the Table demonstrated formation of a mean value of 28.7% of new bone with a range of 18.3% to 89.5%. The density in Hounsfield units had a mean value of 571 with a range of 385 to 729. None of the DDM was exfoliated prematurely, and none developed infec-

tion, even in those maxillary sites that were not fully closed over the DDM.

#### DISCUSSION

The allograft soft tissue and particulate bone used for socket preservation in this case series is treated





**FIGURES 6–13.** **FIGURE 6.** Radiograph of grafted site at 12 weeks. **FIGURE 7.** Three-dimensional (3D) cone-beam computerized tomography (CT) scan. **FIGURE 8.** Coronal view of 3D cone-beam CT scan. **FIGURE 9.** Trephine with bone biopsy. **FIGURE 10.** Restored implant at number 30 site. **FIGURE 11.** Periapical radiograph of completed restoration. **FIGURE 12.** Photograph of completed restoration number 30 site. **FIGURE 13.** Photograph of specimen showing trabecular bone with lamina, osteocytes in lacunae.

to remove cellular components in order to avoid rejection or infection:

- (1) The MCAB used is prepared by a solvent cell extraction, and ultrasonification and centrifugation process with hypotonic reagents and antimicrobial solutions.
- (2) DDM is prepared with a solvent detergent and endonucleases to remove cellular components.

Low dose gamma radiation at  $-78.5^{\circ}\text{C}$  is the final step in processing for both MCAB and DDM. Glycerol preserving medium allows DDM to be stored in a fully hydrated state at ambient temperature. This eliminates the need for time-consuming rehydration and can save valuable

surgery preparation time. DDM is ready to use with only rinsing to remove the preservative medium. The material handles well, and it is easily adapted to the shape of extraction site defects.

Bone regeneration in extraction sockets proceeds with angiogenesis and ingrowth of osteogenic cells from peripheral bony walls. This vascularized tissue serves then as scaffolding for the development of woven bone throughout the space. There are multiple positive clinical benefits from utilization of barrier membranes over grafted extraction sockets. They prevent soft tissue ingrowth that would disrupt the ingress and maturation of osteogenic and endothelial cells into socket spaces.<sup>22</sup> Loss of bone volume is prevented, thus

TABLE						
Histomorphometric and computed tomography data*						
ID	% Bone/Sample	% Graft/Sample	% AV	Wall Defect	Site	Hounsfield Units
S1	37.12	62.9	30.51	Yes	19	709
	22.71	77.3				
	31.69	68.3				
S2	18.71	81.3	14.79	No	18	479
	17.07	82.9				
S3	78.52	21.5	54.85	Yes	30	562
	81.68	18.3				
	23.18	76.8				
S4	36.03	63.9	24.99	No	3	458
	20.91	79.9				
	42.11	57.9				
S5	11.97	88.0	27.21	No	14	385
	25.73	74.3				
	27.97	72.0				
S6	27.92	72.1	21.61	No	19	427
	10.50	89.5				
	11.23	88.8				
S7	43.09	56.9	22.86	No	30	511
	20.72	79.3				
	23.94	76.1				
S8	23.91	76.1	32.87	No	30	570
	36.29	63.7				
	25.00	75.0				
Total average	37.31	62.7	28.7			

\*AV indicates average vital bone.

allowing for optimal positioning of implants and placement of larger diameter implants without encroaching on the 1.8-mm width of bone that is important to maintain adjacent to implants.<sup>23</sup> The need for sinus grafting over maxillary molar extraction sites can be reduced by maintaining the vertical ridge dimension.<sup>24</sup> It has been shown that implants placed in grafted sites will exhibit similar clinical results to those placed into non-grafted sites.<sup>25</sup> Primary closure was achieved from extensive flap release whenever possible, since this is important in preventing infection complications which can interfere with the maturation of woven bone, and result in decreased gain in bone fill.<sup>26</sup>

Materials used as barriers over grafted extraction sites can be resorbable or nonresorbable products. Resorbable membranes used include bovine and porcine collagen, polylactide, pericardium, and acellular dermis matrix. The use of nonresorbable barrier membranes can lead to a high percent of complications due to infection and dehiscence. A second surgery for removal risks loss of the bone fill gained and healing complications.<sup>27</sup> Recent reports

describing the amount of new bone regenerated where barriers were not used demonstrate the importance of barriers placed over extraction sockets: Crespi et al<sup>28</sup> reported 36%, 38%, and 30% with magnesium-enriched hydroxyapatite, porcine bone, and untreated controls, respectively. Tolve et al<sup>29</sup> reported 32% and 17% with calcium sulfate and freeze-dried bone allograft, respectively. Gholami et al,<sup>30</sup> reported 28% and 27% with nanocrystalline hydroxyapatite and bovine xenograft, respectively. Wood and Mealey<sup>31</sup> reported 38% and 24% with mineralized and demineralized freeze-dried bone allograft respectively.

Acellular dermis matrix can generate a thicker biotype, which is desirable around implants, as reports show less width of keratinized gingiva marginal tissue is associated with significantly more gingival inflammation, more plaque accumulation, adverse esthetic appearance, and more gingival recession.<sup>32,33</sup> In contrast to other nonallograft resorbable barriers, acellular dermis acts as a scaffold permitting the ingrowth of epithelial cells. After 10 weeks, the reparative turnover of dermis is

complete with histologic examination showing no inflammatory or macrophage cells.<sup>34,35</sup> However, documentation of soft tissue thickness changes was not included in the present data.

There were dehiscence defects in bony walls in 2 of the treated sites. The influence of wall defects compared to intact bony walls on bone regeneration results is not possible to determine within the limits of this study, but it is recommended to investigate this with a larger sample study with comparable bony wall defects in molar extraction sites. None of the membranes were exfoliated early, and all sites healed well without apparent complications. The particulate allograft was retained without loss in all extraction socket sites. All implants placed showed primary stability at an insertion torque of 45 Ncm or greater.

There are few reports describing results from utilization of acellular dermis matrix for guided bone regeneration over extraction sites grafted with mineralized cancellous allograft bone. The new bone gain of 12.8%, with a range of 5.3% to 28.4% at 12 weeks compares favorably to results from a comparable study by Fotek et al,<sup>35</sup> that reported 41.8% new bone with a range of 30% to 56% after 16 weeks in sites grafted with freeze-dried mineralized allograft bone and covered with an acellular dermis membrane. It should be noted that none of these sites were molar teeth, so with a smaller volume of socket area to regenerate and 4 weeks additional time before reentry, the higher percent of new bone is not unexpected. Decortication of the lamina dura in the socket sites with a number 4 round bur could increase the blood supply to the graft. A longer time between socket grafting and implant placement would most likely increase the new bone present in the implant sites. Also of significant interest was the observation by Fotek et al<sup>35</sup> that the change in soft tissue thickness, though small, was significant. It would be of interest in a future study with more sample sites to measure accurately the soft tissue thickness using an endodontic file with a rubber stop to prevent compression of tissue that occurs with a periodontal probe, along with histologic analysis of the soft tissue. This could be done by utilizing a flapless entry in augmented molar socket sites for harvesting a trephined core as the first step in implant osteotomy.

This limited study was designed to gather

histologic, histomorphometric, and computerized tomographic data from trephined bone specimens harvested from healed molar extraction sites that had been grafted with mineralized cancellous allograft bone and covered with DDM.

## CONCLUSIONS

Within the limits of this case series, decellularized dermis used as a barrier over extraction sites grafted with freeze-dried mineralized cancellous particulate allograft bone can produce a significant percentage of new bone regeneration after 12 weeks in molar extraction sites and support stable implant placement.

## ABBREVIATIONS

ADM: acellular dermis matrix  
DDM: decellularized dermis matrix  
MCAB: mineralized cancellous allograft bone

## ACKNOWLEDGMENTS

Materials and financial support for this case series were provided by LifeNet Health and Salvin Dental Specialties.

## REFERENCES

- Schropp L, Wenzel A, Kostopoulos L, Karring T. Bone healing and soft tissue contour changes following single-tooth extraction: a clinical and radiographic 12-month prospective study. *Int J Periodontics Restorative Dent.* 2003;23:313–323.
- Lekovic V, Kenney EB, Weinlaender M, et al. A bone regenerative approach to alveolar ridge maintenance following tooth extraction. Report of 10 cases. *J Periodontol.* 1997;68:563–570.
- Wang HL, Tsao YP. Histologic evaluation of socket augmentation with mineralized human allograft. *Int J Periodontics Restorative Dent.* 2008;28:231–237.
- Vastardis S, Yukna RA. Evaluation of allogeneic bone graft substitute for treatment of periodontal osseous defects: 6-month clinical results. *Compend Contin Educ Dent.* 2006;27:38–44.
- Almasri J, Camarda AJ, Ciaburro H, Chouikh F, Dorismond SJ. Preservation of posterior mandibular extraction site with allogeneic demineralized, freeze-dried bone matrix and calcium sulphate graft binder before eventual implant placement: a case series. *J Can Dent Assoc.* 2012;78:c15.
- Darby I, Chen ST, Buser D. Ridge preservation techniques for implant therapy. *Int J Oral Maxillofac Implants.* 2009;24(suppl): 260–271.
- Becker W, Becker BE, Caffesse R. A comparison of demineralized freeze-dried bone and autologous bone to induce bone formation in human extraction sockets. *J Periodontol.* 1994;65: 1128–1133.
- Becker W, Clokie C, Sennerby L, Urist MR, Becker BE.

Histologic findings after implantation and evaluation of different grafting materials and titanium micro screws into extraction sockets. Case reports. *J Periodontol.* 1998;69:414–421.

9. Wood R, Mealey B. Histologic comparison of healing after tooth extraction with ridge preservation using mineralized versus demineralized freeze-dried bone allograft. *J Periodontol.* 2012;83:329–336.

10. Lekovic V, Camargo PM, Klokkevold PR, et al. Preservation of alveolar bone in extraction sockets using bioabsorbable membranes. *J Periodontol.* 1998;69:1044–1049.

11. Froum S, Cho SC, Elian N, Rosenberg E, Rohrer M, Tarnow D. Extraction sockets and implantation of hydroxyapatites with membrane barriers: a histologic study. *Implant Dent.* 2004;13:153–164.

12. Molly L, Vandromme H, Quirynen M, Schepers E, Adams JL, van Steenberghe D. Bone formation following implantation of bone biomaterials into extraction sites. *J Periodontol.* 2008;79:1108–1115.

13. McAllister BS, Haightaiti K. Bone augmentation techniques. *J Periodontol.* 2007;78:377–396.

14. Machtei EE. The effect of membrane exposure on the outcome of regenerative procedures in humans: a meta-analysis. *J Periodontol.* 2001;72:512–516.

15. Wainwright D, Madden M, Luterman A, et al. Clinical evaluation of an acellular allograft dermal matrix in full-thickness burns. *J Burn Care Rehabil.* 1996;17:124–136.

16. Fernandes PG, Novaes AB Jr, de Queiroz AC, et al. Ridge preservation with acellular dermal matrix and anorganic bone matrix cell-binding peptide P-15 after tooth extraction in humans. *J Periodontol.* 2011;82:72–79.

17. Novaes AB Jr, de Barros RR. Acellular dermal matrix allograft. The results of controlled randomized clinical studies. *J Int Acad Periodontol.* 2008;10:123–129.

18. Luczyszyn SM, Papalexou V, Novaes AB Jr. Acellular dermal matrix and hydroxyapatite in prevention of ridge deformities after tooth extraction. *Implant Dent.* 2005;14:176–184.

19. Novaes AB Jr, Papalexou V, Luczyszyn SM, Muglia VA, Souza SL, Taba Júnior M. Immediate implant in extraction socket with acellular dermal matrix graft and bioactive glass: a case report. *Implant Dent.* 2002;11:343–348.

20. Park JB. Healing of extraction socket grafted with deproteinized bovine bone and acellular dermal matrix: histomorphometric evaluation. *Implant Dent.* 2010;19:307–313.

21. Fowler EB, Breault LG, Rebitski G. Ridge preservation utilizing an acellular dermal allograft and demineralized freeze-dried bone allograft: part I. A report of 2 cases. *J Periodontol.* 2000;71:1353–1359.

22. McAllister B, Haghiahati K. Bone augmentation techniques. *J Periodontol.* 2007;78:377–396.

23. Spray JR, Black CG, Morris HF, Ochi S. The influence of bone thickness on facial marginal bone response: stage I placement through stage 2 uncovering. *Ann Periodontol.* 2000;5:119–128.

24. Rasperini G, Luigi Canullo L, Dellavia C, Pellegrini G, Simion M. Socket grafting in the posterior maxilla reduces the need for sinus augmentation. *Int J Periodontics Restorative Dent.* 2010;30:265–273.

25. Barone A, Orlando B, Cingano L, Marconcini S, Derchi G, Covani U. A randomized clinical trial to evaluate and compare implants placed in augmented versus non-augmented extraction sockets: 3-year results. *J Periodontol.* 2012;83:836–846.

26. Machtei E. The effect of membrane exposure on the outcome of regenerative procedures in humans: a meta-analysis. *J Periodontol.* 2001;72:512–516.

27. Simion M, Baldoni M, Rossi P, Zaffe D. A comparative study of the effectiveness of e-PTFE membranes with and without early exposure during the healing period. *Int J Periodontics Restorative Dent.* 1994;14:166–180.

28. Crespi R, Cappare P, Gherlone E. A 4-year evaluation of the peri-implant parameters of immediately loaded implants placed in fresh extraction sockets. *J Periodontol.* 2010;81:1629–1634.

29. Tolue S, Chesnoiu-Matei L, Blanchard S. A clinical and histomorphometric study of calcium sulfate compared to freeze dried bone allograft (FDBA) for alveolar ridge preservation. *J Periodontol.* 2012;83:847–855.

30. Gholami G, Naiafi B, Mashhadiabbas F, Goetz W, Najafi S. Clinical, histologic and histomorphometric evaluation of socket preservation using a synthetic nanocrystalline hydroxyapatite in comparison with a bovine xenograft: a randomized clinical trial. *Clin Oral Implants Res.* 2012;23:1198–1204.

31. Wood R, Mealey B. Histologic comparison of healing after tooth extraction with ridge preservation using mineralized versus demineralized freeze-dried bone allograft. *J Periodontol.* 2012;83:329–336.

32. Woodyard J, Greenwell H, Hill M, Isabella JM, Scheetz J. The clinical effect of acellular dermal matrix on gingival thickness and root coverage compared to coronally positioned flap alone. *J Periodontol.* 2004;75:44–56.

33. Fu J, Lee A, Wang H. Influence of tissue biotype on implant esthetics. *Int J Oral Maxillofac Implants.* 2011;26:499–508.

34. Scarano A, Barros RRM, Lezzi G. Acellular dermal matrix graft for gingival augmentation: a preliminary clinical, histologic, and ultrastructural evaluation. *J Periodontol.* 2009;80:253–259.

35. Fotek PD, Neiva TG, Wang HL. Comparison of dermal matrix and polytetrafluoroethylene membrane for socket bone augmentation: a clinical and histologic study. *J Periodontol.* 2009;80:776–785.