

Evaluation of Peri-Implant Bone Response in Implants Retrieved for Fracture After More Than 20 Years of Loading: A Case Series

Carlo Mangano, DDS, MD¹
 Adriano Piattelli, MD, DDS²
 Carmen Mortellaro, MD, DDS³
 Francesco Mangano, DDS¹
 Vittoria Perrotti, DDS, PhD²
 Giovanna Iezzi, DDS, PhD^{2*}

Analysis of human retrieved dental implants is a useful tool in the evaluation of implant success and failure. More human histological data are needed from samples of long-term implant service. The aim of the present case series was a histological and histomorphometrical evaluation of the peri-implant bone responses in implants retrieved for fracture after more than 20 years loading. The archives of the Implant Retrieval Center of the Department of Medical, Oral and Biotechnological Sciences of the University of Chieti-Pescara, Italy were searched. A total of 5 implants, retrieved after a loading period of more than 20 years, were found: 2 had been retrieved after 20 years, 1 after 22 years, 1 after 25 years, and 1 after 27 years. All these implants were histologically processed. Compact, mature bone in close contact with the implant surface was observed in all specimens, with no gaps or connective tissue at the interface. Bone in different maturation stages was found around some implants. Primarily newly formed bone was observed in proximity of the implant surface, while mature compact bone with many remodeling areas and cement lines were detected in areas distant from the implant. Many primary and secondary osteons were present. Bone to implant contact percentage varied from 37.2% to 76%. In conclusion, histology and histomorphometry showed that even after many years of function, all implants presented more than adequate bone to implant contact and they appeared to be very well integrated in the peri-implant bone.

Key Words: bone remodeling, human histology, implant surfaces, retrieved dental implants

INTRODUCTION

Analysis of human retrieved dental implants is a very useful tool in the evaluation of implant success and failure.¹ These retrieved specimens are extremely valuable because they contain answers to the biological reaction from the host and the effects produced by the presence of the implant on bone remodeling.¹ The studies on retrieved implants have helped to produce new designs in the macro- and microstructure of the implant surface, trying to improve the response of the peri-implant bone.² As far as osseointegration is concerned, retrieved implants play a relevant role in the long-term evaluation of implants subjected to functional loading.³ Clinical human studies are invaluable for many reasons, but they cannot provide information about the

nature of the bone-implant interface.^{4,5} More human histological data are needed from samples of long-term implant service.⁶ Even single case reports are extremely important due to the scarcity of long-term human data.⁴ Human specimens, moreover, are extremely important in validating the results obtained from in vitro or animal experimental studies, and the performance of the bone-implant interface over time must be evaluated.⁷

Two main problems are related to the evaluation of retrieved human implants: (1) the frequent lack of relevant clinical information, and (2) the problems that can be encountered during implant retrieval, as in some cases where only small portions of peri-implant bone are present and can be evaluated.⁸ Moreover, the quality of the material may vary widely between specimens.⁸ These limitations notwithstanding, often it will be possible to draw some conclusions of clinical importance from the retrieved implants.⁹

Implant effectiveness is largely dependent on biological stability and integration between the bone and the implant.⁹ Long-term maintenance and success of an implant is related to a continuous remodeling at the interface to avoid bone fatigue fractures and to replace bone that may have sustained microfractures as a result of cyclic loading.⁹⁻¹¹

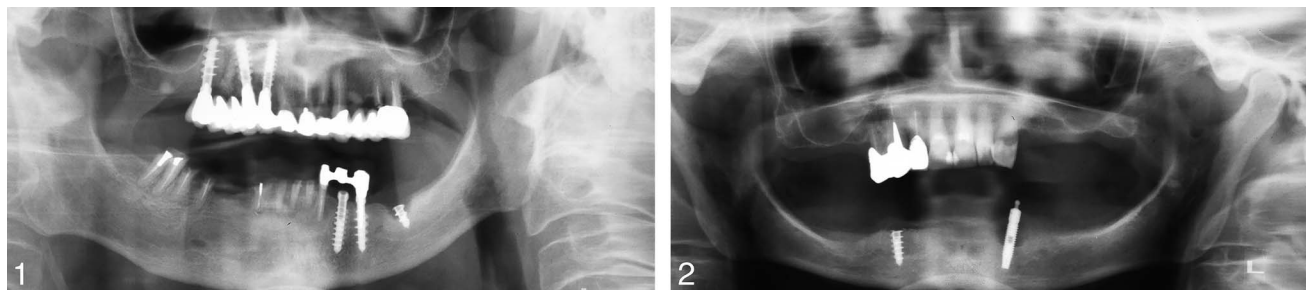
¹ Department of Surgical and Morphological Sciences, University of Insubria-Varese, Varese, Italy.

² Department of Medical, Oral and Biotechnological Sciences, University of Chieti-Pescara, Chieti, Italy.

³ Department of Health Sciences "A. Avogadro", University of Eastern Piedmont, Novara, Italy.

* Corresponding author, e-mail: gio.iezzi@unich.it

DOI: 10.1563/AAID-JOI-D-13-00037



FIGURES 1 AND 2. **FIGURE 1.** Orthopantomography showing a fractured implant located in the left mandible. It is possible to observe a peri-implant bone resorption in the most coronal portion of the implant. **FIGURE 2.** Orthopantomography showing a fractured implant located in the right mandible. The implant supported an overdenture.

The aim of the present study was a histological and histomorphometrical case series of the peri-implant bone responses in implants retrieved for fracture after more than 20 years' loading period.

MATERIALS AND METHODS

The archives of the Implant Retrieval Center of the Department of Medical, Oral and Biotechnological Sciences of the University of Chieti-Pescara, Italy were searched for human dental implants retrieved for fracture after a loading period of more than 20 years (Figures 1 and 2). A total of 5 implants (Dispo, Milano, Italy) inserted in 5 patients were found: 2 had been retrieved after 20 years, 1 after 22 years, 1 after 25 years, and 1 after 27 years. The surface of all these implants was obtained by a sandblasting with 150 microns particles of Al_2O_3 , followed by acid-etching with 20% nitric acid for 30 minutes. The implants were then washed under oxygen peroxide, and dried at 100°C temperature. The macrodesign of the implants was characterized by the presence of large threads with a 2-mm distance between the threads. All the implants had been loaded; none had been immediately loaded. All implants had been retrieved for a fracture of the body of the implant. All the patients agreed that their specimens could be used for scientific purposes, and they signed a written informed consent form. In 3 cases, the implants supported partial fixed bridges, while in 2 cases there was a mandibular overdenture supported by 2 implants. Four implants were located in the mandible, and 1 in the maxilla. All these implants were stable before retrieval. All the implants had been retrieved with a 5-mm trephine bur.

Specimen processing

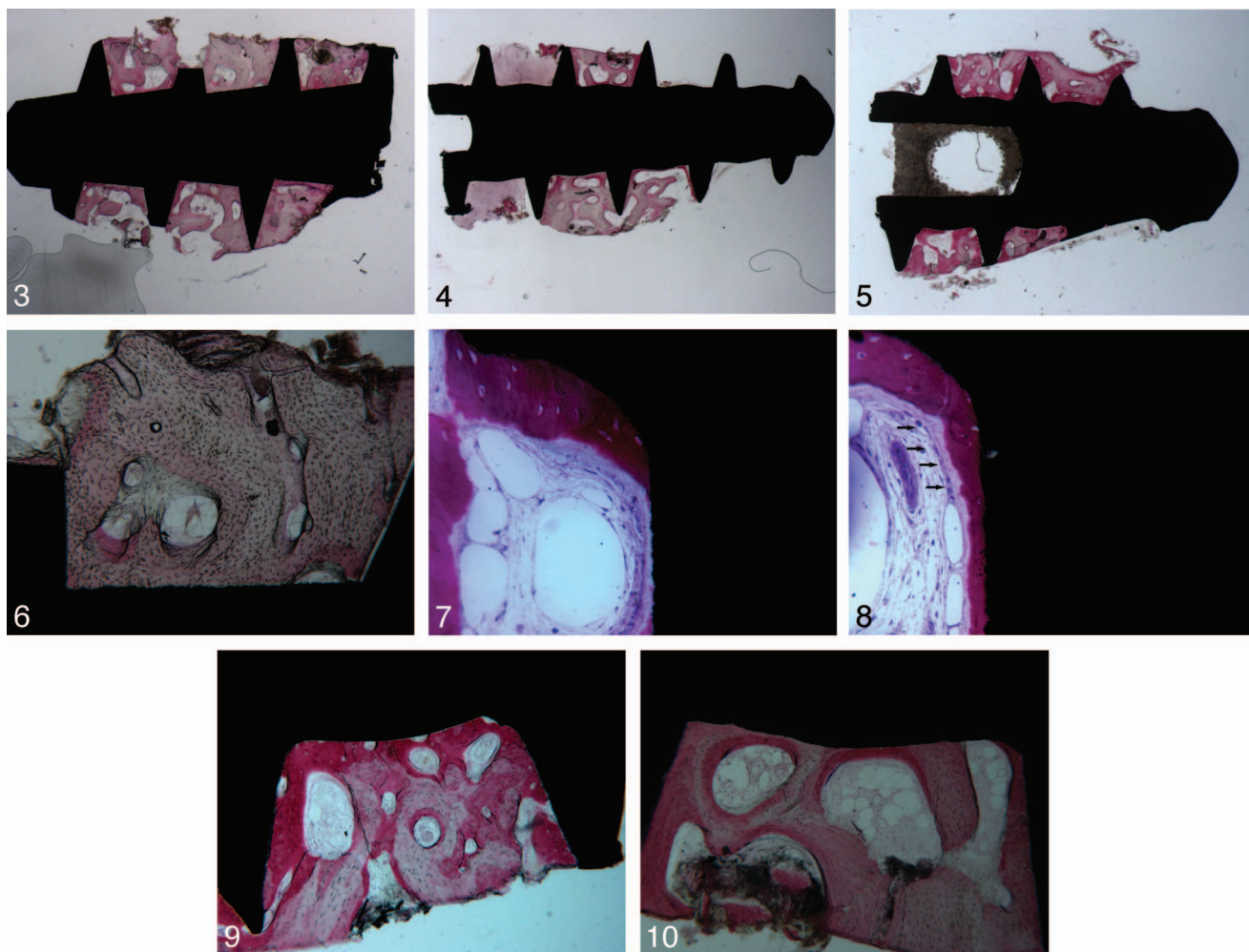
All the specimens were washed in saline solution and immediately fixed in 4% para-formaldehyde and 0.1% glutaraldehyde in 0.15 M cacodylate buffer at 4°C and pH 7.4, to be processed for histology. The specimens were processed to obtain thin ground sections with the Precise 1 Automated System (Assing, Rome, Italy).¹² The specimens were dehydrated in an ascending series of alcohol rinses and embedded in a glycolmethacrylate resin (Technovit 7200 VLC, Kulzer, Wehrheim, Germany). After polymerization, the specimens were sectioned along their longitudinal axis at about 150 μ m with a high-precision diamond disk (Micromet, Ceretolo di Casalecchio di Reno [Bo], Italy), and were ground down to about 30 μ m with

a specially designed grinding machine. A total of 2 slides were obtained for each specimen. The slides were stained with acid fuchsin and toluidine blue. The slides were observed in normal transmitted light under a Leitz Laborlux microscope (Leitz, Wetzlar, Germany) and polarized-light microscopy (Leitz, Wetzlar, Germany).

Histomorphometry of the percentages of bone-implant contact percentages was carried out on all the surface available of the fractured implants using a light microscope (Laborlux S, Leitz, Wetzlar, Germany) connected to a high resolution video camera (3CCD, JVC KY-F55B, JVC, Yokohama, Japan) and interfaced to a monitor and PC (Intel Pentium III 1200 MMX, Intel, Santa Clara, Calif). This optical system was associated with a digitizing pad (Matrix Vision GmbH, Oppenweiler, Germany) and a histometry software package with image capturing capabilities (Image-Pro Plus 4.5, Media Cybernetics Inc., Immagini & Computer Snc Milano, Italy).

RESULTS

Compact, mature bone in close contact with the implant surface was observed in all specimens, with no gaps or connective tissue at the interface (Figures 3 through 5). In all implants, the peri-implant bone started below the fracture line of the implant. Small- or medium-sized marrow spaces were present with no inflammatory infiltrate. Around the implants, bone was present in different maturation stages. Many remodeling areas and secondary osteons were present (Figure 6). Primarily newly formed bone was observed in proximity of the implant surface, while mature compact bone with many remodeling areas and cement lines were detected in areas distant from the implant. In some areas, a rim of osteoblasts depositing osteoid matrix directly on the implant surface was observed (Figures 7 and 8). In some areas of the peri-implant bone, it was possible to see a hemi-osteon in direct contact with the implant surface (Figure 9). In the apical portion of some of the implants, there was a lesser quantity of osteoblasts with a more compact bone and many cement lines. In some portion of the interface, it was possible to observe a small gap, an artifact produced during the implant retrieval. Many small blood vessels were present in the marrow spaces (Figures 9 and 10). In the most coronal portion of one implant, it was possible to detect the presence of connective tissue adhering to the implant surface with few fibroblasts and, in some fields, a moderate inflammatory infiltrate. The results of



FIGURES 3–10. **FIGURE 3.** Compact, mature bone at the interface of the implant. Bone remodeling areas are present. Acid fuchsin-Toluidine blue $\times 18$. **FIGURE 4.** Compact mature bone at the interface. Connective tissue is present in the most coronal portion of the implant. Acid fuchsin-Toluidine blue $\times 18$. **FIGURE 5.** Newly formed bone is present near the implant surface. Wide marrow spaces are present. Acid fuchsin-Toluidine blue $\times 18$. **FIGURE 6.** Bone remodeling areas and osteons are present near the implant surface. No gaps are present at the interface. Acid fuchsin-Toluidine blue $\times 100$. **FIGURE 7.** Newly-formed bone (NB) in direct contact to the implant surface. Not jet mineralized osteoid matrix (OM) can be observed. In the marrow spaces small and big sized blood vessels (V) are present. Acid fuchsin-Toluidine blue $\times 200$. **FIGURE 8.** A rim of osteoblasts (arrows) depositing osteoid matrix directly on the implant surface. Acid fuchsin-Toluidine blue $\times 200$. **FIGURE 9.** Blood vessels of different sizes are present within the marrow spaces. Osteoid matrix is present inside the marrow spaces. Secondary osteons are present abutting the implant surface. Acid fuchsin-Toluidine blue $\times 100$. **FIGURE 10.** Wide marrow spaces are present. Lamellar bone is present. Acid fuchsin-Toluidine blue $\times 100$.

the histomorphometric evaluation of bone-to-implant contact were summarized in the Table.

DISCUSSION

Few papers are present in the literature discussing histology of human implants retrieved after a long period of function.^{13–28} These studies, reporting human retrieved implants after in vivo functional loading periods ranging from months to decades, have usually shown an intimate contact between bone and implant surface. Human retrieval analysis is one of the most valuable tools for evaluation of implant successes or failures,¹ due to the fact that clinical studies cannot provide information regarding BIC.⁴ The retrieved specimens contain important

information regarding the biological reaction from the host and the effects of the implant presence on bone remodeling.¹

In the present case series, histology and histomorphometry showed that even after many years of function, all implants presented more than adequate bone-to-implant contact, ranging from 37% to 76%.^{1,4,23,29–31} All implants were clinically stable and were not mobile before retrieval. All implants appeared to be very well integrated in the peri-implant bone. Haversian canals were frequently seen in close proximity to the implant-bone interface. Many remodeling areas and cement lines—lines visible in microscopic examination of bone, marking the boundary of an osteon (haversian system)—were present between osteons at different maturation stages. Many primary and secondary osteons were also present; some of these osteons were seen abutting the implant surface. No signs

TABLE

Implants' characteristics and histomorphometric evaluation of bone-to-implant contact				
Specimens	Loading Period	Bone-to-Implant Contact, %	Reason for Retrieval	Type of Prosthesis
Implant A	20 years	38.0 ± 5.0	Fracture	Fixed bridge
Implant B	22 years	46.0 ± 4.4	Fracture	Mandibular overdenture
Implant C	20 years	76.0 ± 4.2	Fracture	Fixed bridge
Implant D	25 years	37.2 ± 3.4	Fracture	Fixed bridge
Implant E	27 years	54.6 ± 4.1	Fracture	Mandibular overdenture

of epithelial migration were present. No foreign body reactions or osteolytic lesions were present at the interface. These findings suggested that bone immediately adjacent to these implants maintained structure and biomechanical properties after about 20 years in vivo.⁹

It is widely accepted that mechanical stimuli alter the mass and the structure of bone.¹³ The load induces strains in the bone that affects the remodeling processes to adapt the bone.¹³ In a recent study using a very sophisticated technique called nanoindentation, Baldassarri et al found that both the elastic modulus and the hardness of the peri-implant bone showed increased values as time in vivo progressed.²⁹ These authors found that human cortical bone presented an increase in elastic modulus and hardness during the first 5 years, and presented stable mechanical properties thereafter. These results suggest that bone remodeling around the implants had achieved full maturity only after 5 years.²⁹ Implant effectiveness is largely dependent upon biological stability and integration between bone and implant.⁹ Endosseous implants may function over a wide range of degrees of osseointegration.¹

CONCLUSION

In conclusion, the present case series that histologically and histomorphometrically characterized the bone-implant environment after several years of function helped to formulate the following:

- Analysis of retrieved dental implants may help to investigate the possible reasons for the implant removal;
- The condition of the retrieved implants and the surrounding peri-implant bone can be thoroughly evaluated;
- The histological and histomorphometrical analysis could produce an evaluation of the biocompatibility of the implants over the long term;
- There is always a more than adequate bone-to-implant contact percentage in fractured implants;
- The bone is always present below the fracture line;^{32–34}
- Many remodeling areas of bone were present and these were probably critical for the long-term success of the implants.

ACKNOWLEDGMENT

This work was partially supported by the Ministry of Education, University, Research (M.I.U.R.), Rome, Italy.

REFERENCES

1. Coelho PG, Marin C, Granato R, Suzuki M. Histomorphologic analysis of 30 plateau root form implants retrieved after 8 to 13 years in function. A human retrieval study. *J Biomed Mater Res Appl Biomater*. 2009; 91B:975–979.
2. Dattilo DJ, Misch CM, Arena S. Interface analysis of hydroxyapatite-coated implants in a human vascularized iliac bone graft. *Int J Oral Maxillofac Implants*. 1995;10:405–409.
3. Uehara T, Takaoka K, Ito K. Histological evidence of osseointegration in human retrieved fractured hydroxyapatite-coated screw-type implants: a case report. *Clin Oral Impl Res*. 2004;15:540–545.
4. Proussaefs P, Olivier HS, Lozada J. Histologic evaluation of a 12-year-old threaded hydroxyapatite-coated implant placed in conjunction with subantral augmentation procedure: a clinical report. *J Prosthet Dent*. 2004;92:17–22.
5. de Lange G, Tadjoein E. Fate of the HA coating of loaded implants in the augmented sinus floor: a human case study of retrieved implants. *Int J Periodontics Restorative Dent*. 2002;22:287–296.
6. Rohrer MD, Bulard RA, Patterson MK. Maxillary and mandibular titanium implants 1 year after surgery: histologic examination in a cadaver. *Int J Oral Maxillofac Implants*. 1995;10:466–473.
7. Sakakura LE, Nociti FH Jr, Mello GP, de Mello ED, de Rezende ML. Histomorphometric evaluation of a threaded, sandblasted, acid-etched implant retrieved from a lower human jaw: a case report. *Implant Dent*. 2005; 14:289–293.
8. Bolind PK, Johansson CB, Becker W, Langer L, Sevetz EB Jr, Albrektsson TO. A descriptive study of retrieved non-threaded and threaded implant designs. *Clin Oral Impl Res*. 2005;16:447–455.
9. Baker MI, Eberhardt AW, Martin DM, McGwin G, Lemons JE. Bone properties surrounding hydroxyapatite-coated custom osseous integrated dental implants. *J Biomed Mater Res Appl Biomater*. 2010;95B:218–224.
10. Degidi M, Scarano A, Piattelli M, Perrotti V, Piattelli A. Bone remodeling in immediately loaded and unloaded titanium implants: a histologic and histomorphometric study in man. *J Oral Implantol*. 2005;31: 18–24.
11. Jayme SJ, de Oliveira RR, Muglia VA, Novaes AB Jr, Ribeiro RF. The effects of different loading times on the bone response around dental implants: a histomorphometric study in dogs. *Int J Oral Maxillofac Implants*. 2010;25:473–481.
12. Piattelli A, Scarano A, Quaranta M. High-precision, cost-effective cutting system for producing thin sections of oral tissues containing dental implants. *Biomaterials*. 1997;18:577–579.
13. Haldin A, Jimbo R, Johansson CB, et al. Implant stability and bone remodeling after 3 and 13 days of implantation with an initial static strain. *Clin Implant Dent Relat Res*. 2014;16:383–393.
14. Trisi P, Emanuelli M, Quaranta M, Piattelli A. A light microscopy, scanning electron microscopy and laser scanning microscopy analysis of retrieved blade implants after 7 to 20 years of clinical function. *J Periodontol*. 1993;64:374–378.
15. Piattelli A, Scarano A, Paolantonio M. Immediately loaded screw implant removed for fracture after a 15-year loading period: histological and histochemical analysis. *J Oral Implantol*. 1997;23:75–79.
16. Traini T, De Paoli S, Caputi S, Iezzi G, Piattelli A. Collagen fibers orientation near a fractured dental implant after a 5 years loading period: a case report. *Implant Dent*. 2006;15:70–76.
17. Di Stefano D, Iezzi G, Scarano A, Perrotti V, Piattelli A. Immediately loaded blade implant retrieved from man after a 20 years loading period: a histological and histomorphometrical case report. *J Oral Implantol*. 2006;32: 171–176.
18. Traini T, Iezzi G, Pecora G, Piattelli A. Preferred collagen fiber

orientation in the human peri-implant bone after short and long-term loading periods: a case report. *J Oral Implantol*. 2006;32:177–181.

19. Iezzi G, Scarano A, Petrone G, Piattelli A. Two human hydroxyapatite-coated dental implants retrieved after a 14 years loading period. A histologic and histomorphometric case report. *J Periodontol*. 2007;78:940–947.

20. Iezzi G, Scarano A, Mangano C, Cirotti, Piattelli A. Histologic results in a human implant retrieved for fracture 5 years after insertion in a sinus augmented with an organic bovine bone. A case report. *J Periodontol*. 2008;79:192–198.

21. Iezzi G, Orlandi S, Pecora G, Piattelli A. Histologic and histomorphometric evaluation of the bone response around a hydroxyapatite-coated implant retrieved after 15 years. *Int J Periodontics Restorative Dent*. 2009;29:99–105.

22. Iezzi G, Pecora G, Scarano A, Perrotti V, Piattelli A. Immediately loaded screw implant retrieved from man after a 12 years loading period: a histological and histomorphometrical case report. *J Osseointegr*. 2009;1:54–59.

23. Proussaefs P, Lozada J, Ojano M. Histologic evaluation of threaded HA-coated root-form implants after 3.5 to 11 years of function: a report of three cases. *Int J Periodontics Restorative Dent*. 2001;21:21–29.

24. Proussaefs PT, Tatakis DN, Lozada J, Caplanis N, Rohrer MD. Histologic evaluation of hydroxyapatite-coated root-form implants retrieved after 7 years in function: a case report. *Int J Oral Maxillofac Implants*. 2000;15:438–443.

25. Block MS, Finger IM, Misiak DJ. Histologic examination of a hydroxyapatite-coated implant nine years after placement. *J Oral Maxillofac Surg*. 1996;54:1023–1026.

26. Stellino G, Landi L. A 6-year unloaded hydroxyapatite-coated dental implant placed into an extraction socket in conjunction with nonresorbable

hydroxyapatite grafting material: histologic evaluation. *Int J Periodontics Restorative Dent*. 2002;22:575–581.

27. Ledermann PD, Schenk RK, Buser D. Long-lasting osseointegration of immediately loaded bar-connected TPS screws after 12 years of function: a histologic case report of a 95-year-old patient. *Int J Periodontics Restorative Dent*. 1998;18:553–563.

28. Iezzi G, Scarano A, Perrotti V, Tripodi D, Piattelli A. Immediately loaded blade implants. A histological and histomorphometrical evaluation after a long loading period. A retrospective 20 years analysis (1989–2009). *J Osseointegr*. 2012;4:39–42.

29. Baldassarri MM, Bonfante EA, Suzuki M, et al. Mechanical properties of human bone surrounding plateau root form implants retrieved after 0.3–24 years of function. *J Biomed Mater Res Part B*. 2012;100B:2015–2021.

30. Iezzi G, Pecora G, Scarano A, Perrotti V, Piattelli A. Immediately loaded screw implant retrieved after a 12-year loading period: a histologic and histomorphometric case report. *J Osseointegr*. 2009;2:54–59.

31. Iezzi G, Scarano A, Perrotti V, Tripodi D, Piattelli A. Immediately loaded blade implants. A histological and histomorphometrical evaluation after a long loading period. A retrospective 20 years analysis (1989–2009). *J Osseointegr*. 2012;3:39–42.

32. Piattelli A, Piattelli M, Scarano A, Montesani L. Light and scanning electron microscopic report of four fractured implants. *Int J Oral Maxillofac Implants*. 1998;13:561–564.

33. Piattelli A, Scarano A, Piattelli M, Vaia E, Matarasso S. Hollow implants retrieved for fracture: a light and scanning electron microscope analysis of 4 cases. *J Periodontol*. 1998;69:185–189.

34. Piattelli A, Scarano A, Piattelli M. Histologic observations on 230 retrieved dental implants: 8 years' experience (1989–1996). *J Periodontol*. 1998;69:178–184.