

# Rehabilitation of Surgically Relocated Integrated Dental Implants With and Without Bone Morphogenesis Protein-2

Gilbert Tremblay, DMD\*

In the following case report, three osseointegrated implants placed in a dysfunctional and nonaesthetic position were successfully relocated with innovative surgical techniques were followed by a comprehensive dental rehabilitation. The goal of this report is to communicate the surgical techniques used to successfully relocate dental implants rather than replace them. Two techniques were used for these implants relocation. One technique consisted of displacing the integrated implant with some similarity to the alveolar distraction osteogenesis but without using the distraction device. The second surgical technique involved the displacement of the 2 adjacent implants, similarly to the first approach, except that an osseoinductive molecule, recombinant human bone morphogenetic protein-2, was used for guided bone growth. It was possible to relocate dental implants within bone blocs and rehabilitate them to adopt new dental abilities by complying with bone regeneration parameters. However, advanced treatment planning with computerized tomography scans, parametric software, and stereolithography models as well as guided surgery and bone regeneration products were used.

**Key Words:** dental implant, bone graft, recombinant human bone morphogenetic protein-2, guided surgery, implant relocation, dental rehabilitation, osteotomy, segmentation, parametric software, stereolithography

## INTRODUCTION

Relocating failing integrated dental implants can be a challenging procedure that involves some surgical risks. Conventionally, failing implants can be retrieved, bone grafted, and replaced. Poor positioning of integrated implants can be salvaged by complex abutment design or relocated by distraction-osteogenesis.<sup>1</sup> This case study involves multiple implant complications that includes poor implant location with bone dehiscence, occlusion, and phonation concerns as well as aesthetic issues. An innovative approach was developed involving meticulous computerized tomography (CT) scan planning and guided surgery combined with biomolecular biology. Planning with a parametric software and stereolithography maxillary model, performing surgery with osteotomy

guides and implant relocation guides, and using osteoinductive molecules enhance the guided bone remodelling and the surgical outcomes. This case also includes soft tissue engineering and predictable prosthetics.

## METHODS

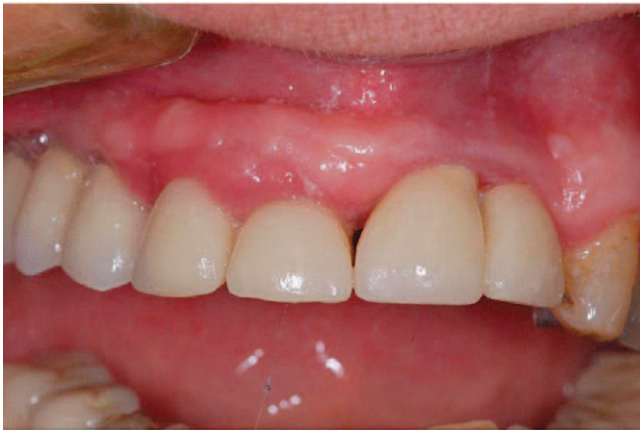### Clinical evaluation

The patient described in this study is a 55-year-old woman with severe complications associated to her dental implant restorations. Her main complaints were that she cannot speak properly or chew with her restored dental implants. She also states having a tooth (#8) located "at the back of her dental arch" causing her discomfort and concerns about poor esthetics (Figure 1).

The clinical exam reveals 7 dental implants located in the edentulous space of teeth #4–#10. Implant #8 is in fact positioned on the palate and is lying against the floor of the nasal cavity, restored with a porcelain fused to metal single crown, and

Quebec Dental Implant Institute, Pierrefonds (Montreal), Quebec, Canada.

\* Corresponding author, e-mail: implant@bellnet.ca  
DOI: 10.1563/AAID-JOI-D-13-00077



**FIGURE 1.** Patient's complaints: tooth #8 up into her palate causes speech impediment; poor aesthetics of teeth #9 and 10.

designed in a cantilever manner when viewed in an anterior-posterior cut. This implant presents a bone dehiscence on the vestibular surface (Figure 2). Implants #9 and 10 are almost in contact at the coronal one-third and are more apical compared with the other teeth. All these prosthodontic implant-supported restorations are out of occlusion. Only her 4 natural teeth support the complete occlusion of her maxilla.

Aesthetically, all of her maxillary incisors were short of her smile line at the rest position; maxillary incisors were draped by her lip in that same position. The patient's upper lip dynamics while smiling covered the gingival one-third of her maxillary teeth.

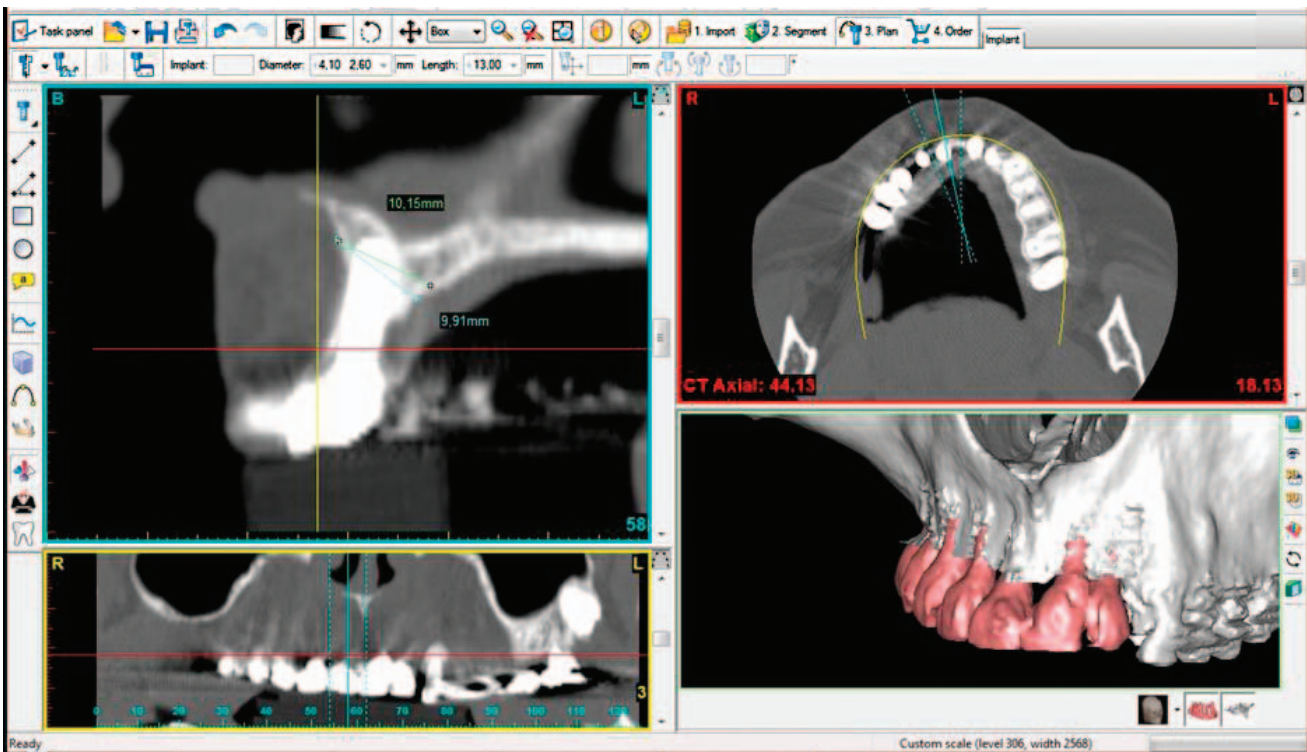
Periodontal findings showed lack of attached gingiva facially to implants #9 and 10 (American Academy of Periodontology type 1).

Caries, defective restorations, and structural compromises were observed on several teeth. A compromised occlusal vertical dimension was observed in the premaxilla with an end-to-end occlusion that had no contact in protrusion.

The patient has no contributory medical history or known allergies. A diagnostic risk assessment was performed using the Kois protocol.<sup>2</sup> Treatment plan options and their prognosis also were presented to the patient.

**Treatment plan**

The treatment plan is divided into 3 phases. The first phase involves relocating implant #8. The second phase involves relocating both implants #9 and 10. The third phase involves rehabilitating the patient



**FIGURE 2.** Computerized tomography scan with parametric software reveals proximity of implant #8 to the nasal cavity floor. Buccal bone plates of all maxillary implants are dehiscent, covering one-half to two-thirds of the implant surface.

with a complete prosthetic comprehensive restoration.

### **Phase 1: relocating 1 implant**

A cone-beam CT scan was prescribed and a SimPlant study was followed. Observations of the three-dimensional radiography reconstruction reveal the palate position of implant #8 and the fenestration of many implants. Two treatment proposals were presented to the patient.

The first proposal was to remove implant #8 with a trephine; place a bone graft where the surgery took place; wait several months for the bone graft to heal; and finally, place a new dental implant in a more functional position. This proposal presented a low-to-fair prognosis given the risk of perforating the nasal cavity floor, thus causing oronasal communication. Also, when removing the implant with a trephine, the remaining cortical vestibular bone would be insufficient and result in a 7.3-mm vertical bone defect. The risk related to the correction of this defect would be high.

The second proposal was to relocate implant #8 by cutting a bone block around it to relocate the bone block along with the implant.<sup>3-6</sup> To improve the prognosis, an apicoectomy of the implant would be performed to maintain an intact nasal cavity floor, such as in the osteogenesis-distraction technique.<sup>7</sup> A full-thickness buccal flap of the implant will be reflected without separating the bone block from its palatal mucosa.<sup>8</sup> This procedure will maintain the block's blood supply. This proposal presented a good prognosis.

The patient agreed to the second proposal, and this approach would subsequently be accompanied by a comprehensive prosthodontic rehabilitation.

An evaluation of region #8 soft tissue revealed a thin attached gingiva as well as a reduced thickness of the alveolar mucosa. The augmentation of the gingiva with an acellular connective tissue (AlloDerm, BioHorizons, Markham, Ontario, Canada) was done using the pouch technique<sup>9</sup> (Figure 3). A stereolithography laser plastic model<sup>10</sup> was designed as well as a surgical osteotomy guide from the aforementioned model (Figure 4). The latter was used to determine the osteotomy cut of the future bone block that needed relocation.

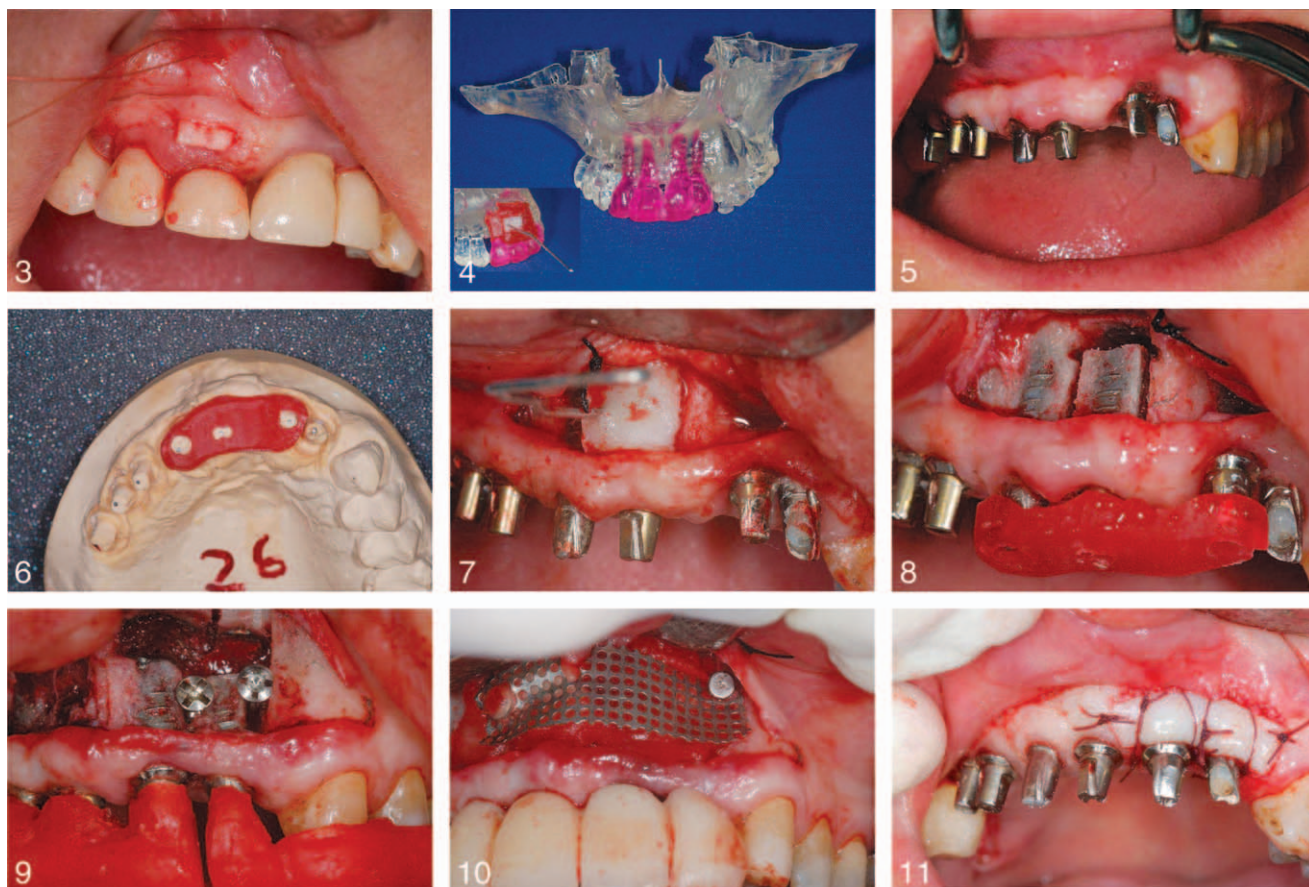
A polyvinyl siloxane (PVS) print was taken to record the 7 implant abutments (Figure 5). The PVS print was poured with stone to cut abutment #8, and

relocated it in an ideal position, resulting in a diagnostic mounting. An occlusal index was designed to guide the future bone block in the same position as the pillar's diagnostic mounting (Figure 6). Seven temporary crowns were fabricated in the laboratory from the diagnostic model and were cemented on the relocated bone block during the surgery.

After 6 weeks of healing, the implant surgery took place. The patient's preparation was done with the following pharmaceutical protocol: clindamycin (Dacilin C, Pfizer Canada, Kirkland, Quebec, Canada) at 150 mg q.i.d. for 7 days. An infiltration of 2% lidocaine with 1:100 000 epinephrine was provided, followed by a horizontal 4–5-mm incision apical to the crest of the gingiva and a reflection of a full-thickness buccal flap.<sup>11,12</sup> The surgical osteotomy guide was placed on the premaxillary bone, at the buccal of implant #8. It should be noted that the surgical osteotomy guide becomes stable only if it is placed where it was designed on the stereolithography model, thus ensuring the right location for the osteotomy cut (Figure 7). The bone osteotomy is executed with a Piezosurgery ultrasound instrument (Mectron Medical Technology, Genoa, Italy) at the vertical axis.<sup>13</sup> The horizontal cut of the implant apex is done with a bur. The bone block containing implant #8 was separated from the maxillary while being pediculated to the palatal mucosa. This bone block was relocated based on the location of the occlusal index (Figure 8) and maintained in the position with retaining screws<sup>7</sup> (ACE Surgical Supply Co, Inc, Brockton, Mass). The spaces between the relocated block and the maxillary were filled with allograft bone particles (Accell Connexus, Integra Orthobiologics, Irvine, Calif). The grafted bone and the bone block were covered with a Bioguide porcine collagen membrane<sup>14</sup> (Osteohealth, Shirley, NY). The flap was closed by first intention with Teflon suture (GORE-TEX Suture, W.L. Gore & Associates, Flagstaff, AZ). The 7 temporary crowns that had been prepared in laboratory were cemented with Tembound noneugehol (Kerr Corp, Romulus, Mich).

### **Phase 2: Relocating 2 adjacent implants**

The second surgical phase entailed the relocation of 2 adjacent dental implants. This proximity between implants posed an additional risk compared with the first intervention. Relocating 2 adjacent bone blocks results in a weaker blood supply to the region between the 2 blocks. This lack of blood supply can



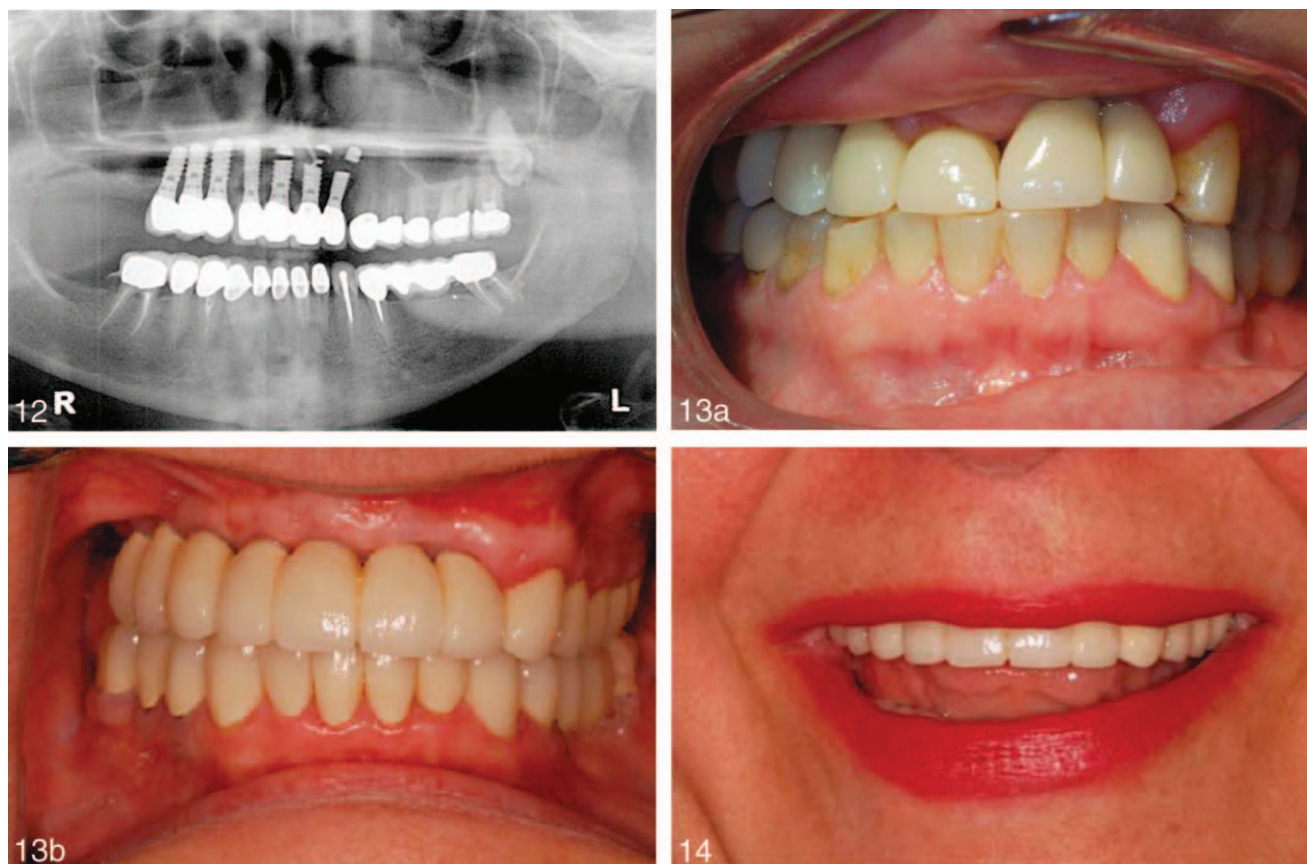**FIGURES 3–11.** **FIGURE 3.** Acellular dermis collagen membrane installed through tunnelization. Therapeutic goal was to increase soft tissue thickness and stimulate vascularization where the operation will take place. **FIGURE 4.** Stereolithographic model with coloration of implants #7–10 is developed for the surgery. An osteotomy surgical guide was prepared based on the stereolithographic model. Purpose was to locate osteotomy lines, reduce the iatrogenic risks, and increase the surgical prognosis. **FIGURE 5.** Implants #9 and 10 very close to one another; the soft tissue surrounding the implants is deficient. Note the absence of keratinized tissue between implants #9 and 10. These implants are apical with regard to the alignment of the teeth. **FIGURE 6.** Based on the alignment and aesthetics required for the creation of new crowns cemented to the implant, a model is prepared with the repositioning of the abutment of implant #8. Afterward, an abutment repositioning guide will serve to relocate the implant during surgery. **FIGURE 7.** The osteotomy surgical guide is placed on the relevant site. Guide stability confirms its position on the sought site. **FIGURE 8.** The bone bloc is separated and relocated with the implant abutment positioning guide. **FIGURE 9.** Second relocation surgery of implants #9 and 10. The implants are relocated with the repositioning guide and secured with external fixation screws. Note the significant implant relocation and the slight bone residue around the implants. **FIGURE 10.** A physical barrier made with a titanium mesh maintains a space between the bone near the operated site and the soft tissue. The recombinant human bone morphogenetic protein-2 collagen support is placed between the titanium mesh and the bone. **FIGURE 11.** A free gingival soft tissue autograft is placed where there is complication.

lead to necrosis of one or both bone blocks. To reduce this surgical risk, an osteoinduction molecule, recombinant human bone morphogenetic protein-2 (rh-BMP2)<sup>15–17</sup> was used on the periphery and between both bone blocks for its potential for rapid regenerative bone processing.<sup>18,19</sup> We use rh-BMP2 to optimize bone regeneration without any other product combination.<sup>20</sup>

Planning was similar to phase 1: Soft tissue free gingival auto graft of area #9 and 10, relocation of

implant abutments #9 and 10 on the stone model; preparation of a temporary prosthesis from this new implant abutment relocation; preparation of a surgical osteotomy guide from the stereo lithography model; planning of the virtual surgery with SimPlant; surgical incision design such as the *distraction osteogenesis*; setting of the two osteotomy blocks with internal retaining screws (Figure 9).

The surgical procedure begins once the surgical blocks are prepared. An absorbable collagen



**FIGURES 12–14.** **FIGURE 12.** Complete dental rehabilitation. The dental implants restored with 2 sections of matching crowns. Given the week ratio crown/implant #10, the occlusion is adjusted on this implant, as if crown #10 was a cantilever. **FIGURE 13.** Frontal view; significant improvement of the implant-supported crown aesthetic profile. **FIGURE 14.** Smile view. The occlusal line harmony and the incisor elongation translate into a more harmonious smile.

sponge (ACS) was coated with the rh-BMP2. This ACS was placed between and over the bone blocks buccal surface, as well as the surface of all implants with a bone dehiscence. A Bioguide collagen membrane was coated with Platelet Rich Plasma (PRP), which was activated with autologous thrombin, and covered the rh-BMP2 membrane. PRP is used for its soft tissue healing properties, thus maintaining the incision closed and reducing the risk of postoperative reopening.<sup>21</sup> A physical barrier made of perforated titanium mesh was placed between the Bioguide collagen membrane and the ACS, the barrier was maintained in that position with retaining screws (Figure 10). The titanium mesh is used for space maintenance to allow bone growth.<sup>22,23</sup> The closing of the incision was completed with Teflon-based sutures. Temporization was done with a lab-made acrylic bridge from the second modified cast study.

Ten days following the surgery, a surgical

complication arose. Between implants #9 and 10, the soft tissue bridge of the crestal area became affected by necrosis. This physiological phenomenon appeared due to the tension caused to the tissue by the significant stretching of the implant relocation, as well as the small volume of the soft tissue bridge between both implants. This situation was resolved by proceeding with a free gingival auto graft on the affected area.<sup>24</sup> (Figure 11).

After the healing tissue and the bone tissue regeneration, the final prosthetic phase took place.

### **Phase 3: Prosthetic comprehensive rehabilitation**

Verification of the vertical dimension of occlusion and of her maximum intercuspitation position was done with the help of her temporary restorations.<sup>25</sup> The permanent crowns supported by the 7 implants were prepared in 2 sections: 7, 8, 9, 10 and 4, 5, 6 (Figure 12). The advantage of this prosthodontic pairing is to fight shear forces and to increase stress

resistance. Individual crowns were prepared on all natural teeth, with the exception of a fixed partial bridge on teeth #21-X-X-18. At the end of the prosthodontic treatments, an occlusal night guard was prepared.

A postoperative control 24-months after the surgery did not reveal any implant mobility or bone loss proximal to the implants. The prosthodontic restorations were stable, and the patient was satisfied with the functions and aesthetics (Figures 13 and 14). This case has now been active for 5 years without any complications or peri-implant bone loss.

### CONCLUSIONS

The use of computer-assisted technology allows for accurate evaluations of risks in future treatments. Customized computer-generated surgical guides and osteoinduction molecules increase precision, safety, and foreseeable results. This innovative surgical treatment was used to relocate integrated implants. The separation of both adjacent osseous blocks also presented significant bone loss. This treatment allowed for implant repositioning along with bone regeneration. Implant repositioning was possible with the use of customized positioning guides and osteotomy guides based upon a stereolithographic model. Bone regeneration was enhanced and block merging was obtained, despite poor vascularization of the adjacent separated blocks. The implants were restored without complication, and the stability of the bone volume is still observed 5 years posttreatment. This therapeutic approach elucidates new ways to improve the treatment of functional and aesthetic complications in dental implantology. As there is minimal literature available on this topic, additional investigations and studies are needed to provide evidence-based conclusions regarding this treatment.

### ABBREVIATIONS

ACS: absorbent collagen sponge  
 CT: computerized tomography  
 PRP: platelet-rich plasma  
 PVS: polyvinyl siloxane  
 rh-BMP2: recombinant human bone morphogenesis protein-2

### ACKNOWLEDGMENTS

I thank Therese Lanciault, MSc, Director of the Quebec Dental Implant Institute, for guidance, support, and assistance with this manuscript, and Anas Raffoul (R&B Laboratories, Roxboro, Quebec, Canada) and Tim Van Cleynenbreugel (Materialise Dental, Altran, Brussels, Belgium) for their support in developing this new guided technology.

### REFERENCES

1. Zechner W, Bernhart T, Zauza K, Celar A, Watzek G. Multidimensional osteodistraction for correction of implant malposition in edentulous segments. *Clin Oral Implants Res.* 2001;12:531–538.
2. Kois J. *Creating Restorative Excellence. 10 Step Management Approach.* Seattle, Wa: Centre for Advanced Learning Seminar Series.
3. Kassollis JD, Baer ML, Reynolds MA. The segmental osteotomy in the management of malposed implants: a case report and literature review. *J Periodontol.* 2003;74:529–536.
4. Raghoobar GM, Visser A, Vissink A. Correction of a malpositioned endosseous implant by a segmental osteotomy: a case report. *Int J Oral Maxillofac Implants.* 2005;20:627–631.
5. Storum K, Carrick JL. Implant-osseous osteotomy for correction of the misaligned anterior maxillary implant. *Dent Clin North Am.* 2001;45:18–27.
6. Stacchi C, Bonino M, Di Lenarda R. Surgical relocation of malpositioned, unserviceable implant protruding into the maxillary sinus cavity. a clinical report. *J Oral Implantol.* 2012;38:417–423.
7. Oduncuoglu BF, Alaaddinoglu EE, Oguz Y, Uckan S, Erkut S. Repositioning a prosthetically unfavorable implant by vertical distraction osteogenesis. *J Oral Maxillofac Surg.* 2011;69:1628–1632.
8. Toscano N, Sabol J, Holtzclaw D, Scott T. Implant repositioning by segmental osteotomy: a case series and review. *Int J Periodontics Restorative Dent.* 2011;31:e102–e108.
9. Cummings LC, Kaldahl WB, Allen EP. Histologic evaluation of autogenous connective tissue and acellular dermal matrix grafts in humans. *J Periodontol.* 2005;1976:178–186.
10. Cummings LC, Kaldahl WB, Allen EP, et al. Preoperative stereolithographic model planning for primary reconstruction in craniomaxillofacial trauma surgery. *J Craniomaxillofac Surg.* 1998;26:136–139.
11. Martin RJ, Goupil MT, Goldschmidt M. Single-implant segmental osteotomy: a case report. *Int J Oral Maxillofac Implants.* 1998;13:710–712.
12. Da Cunha HA, Filho HN, Batista JG, Matsumoto MA. Segmental osteotomy for the correction of a malpositioned single implant: an 8-year follow-up. *Quintessence Int.* 2011;42:817–822.
13. Stacchi C, Constantinides F, Biasotto M, Di Lenarda R. Relocation of a malpositioned maxillary implant with piezoelectric osteotomies. a case report. *Int J Periodontics Restorative Dent.* 2008;28:489–495.
14. Retzepi M, Donos N. Guided bone regeneration: biological principle and therapeutic applications. *Clin Oral Implants Res.* 2010;21:567–576.
15. Triplett RG, Nevins M, Marx RE, et al. Pivotal, randomized, parallel evaluation of recombinant human bone morphogenetic protein-2/absorbable collagen sponge and autogenous bone graft for maxillary sinus floor augmentation. *J Oral Maxillofac Surg.* 2009;67:1947–1960.

16. Boyne PJ, Marx RE, Nevins M, et al. A feasibility study evaluating rhBMP-2/absorbable collagen sponge for maxillary sinus floor augmentation. Feasibility study. *Int J Periodontics Restorative Dent*. 1997;17:11–25.
17. Hanisch O, Tatakis DN, Rohrer MD, Wöhrle PS, Wozney JM, Wikesjö UM. Bone formation and osseointegration stimulated by rhBMP-2 following subantral augmentation procedures in non-human primates. *Int J Oral Maxillofac Implants*. 1997;12:785–792.
18. Nevins M, Kirker-Head C, Nevins M, Wazney JA, Palmer R, Graharn D. Bone formation in the goat maxillary sinus induced by absorbable collagen sponge implants impregnated with recombinant human bone morphogenetic protein-2. *Int J Periodontics Restorative Dent*. 1996;16:8–19.
19. Cochran DL, Nummikoski PV, Jones AA, Makins SR, Turek TJ, Buser D. Radiographic analysis of regenerated bone around endosseous implants in the canine using recombinant human bone morphogenetic protein-2. *Int J Oral Maxillofac Implants*. 1997;12:739–748.
20. Kao DWK. The negative effect of combining rhBMP-2 and Bio-Oss on bone formation for maxillary sinus augmentation. *Int J Periodontics Restorative Dent*. 2012;32:61–67.
21. Marx RE, Garg AK. Bone graft physiology with use of platelet-rich plasma and hyperbaric oxygen. In: Jensen OT, ed. *The Sinus Bone Graft*. Chicago, Ill: Quintessence Publishing; 1999:183–190.
22. Misch CM. Bone augmentation of the atrophic posterior mandible for dental implants using rhbmp-2 and titanium mesh: clinical technique and early results. *Int J Periodontics Restorative Dent*. 2011;31:581–589.
23. Misch CM. The use of recombinant human bone morphogenetic protein-2 for the repair of extraction socket defects: a technical modification and case series report. *Int J Oral Maxillofac Implants*. 2010;25:1246–1252.
24. Wilson TG, Kornman Kenneth S. Restorative and esthetic treatment aspects of periodontal therapy. In: Caudill RF, Oringer RJ, Langer L, Langer B, Bahat O, Handelsman M, eds. *Fundamentals of Periodontics*. Chicago, Ill: Quintessence Publishing; 2003:544–553.
25. Tremblay G. Innovative advance occlusion planning with superimposed CT and optical scans. *Compend Contin Educ Dent*. 2011;32:50–58.

#### ERRATUM

In the 39(2), April 2013, issue of *Journal of Oral Implantology*, the article by Ohno M, Kimoto K, Toyoda T, Kawata K, and Arakawa H was published with an error in the title. The correct title for the article is “Fluoride-treated bio-resorbable synthetic nonceramic hydroxyapatite promotes proliferation and differentiation of human osteoblastic MG-63 cells” (*J Oral Implantol*. 2013;39:154-160).