

# Implant Treatments for Edentulous Maxilla With Anterior Hyperfunction

Yoichiro Ogino, DDS, PhD\*  
 Masafumi Kihara, DDS, PhD  
 Junichi Yamada, DDS  
 Kohei Toriya, DDS  
 Kiyoshi Koyano, DDS, PhD

## INTRODUCTION

**M**astication tends to shift to the anterior regions that are not designed for a heavy occlusal load biomechanically after the loss of established posterior occlusal contacts. In many cases, the presence of excessive anterior occlusal function by anterior mandibular teeth leads to the progressive collapse or the loss of residual anterior teeth in the maxilla. This occlusal trauma also causes significant maxillary anterior alveolar resorption in a patient with a completely edentulous maxilla and a partially edentulous mandible with preserved anterior teeth and is known as "anterior hyperfunction." This hyperfunction causes some specific oral changes such as bone loss in the maxillary anterior ridge and palatal papillary hyperplasia, which were defined as combination syndrome (CS) by Kelly in 1972.<sup>1</sup> To avoid and manage anterior hyperfunction and CS, implant-retained or implant-supported prostheses have become a popular and successful prosthetic rehabilitation for partially and fully edentulous patients.<sup>2,3</sup> Furthermore, the timing of clinical decision-making for implant treatment might determine the therapeutic regimens and the difficulty of the treatment. The present article was designed to present the successful implant treatment procedures for 3 anterior hyperfunction patients, each classified into pre-CS, moderate CS, and severe CS and discuss the preventive and manageable therapies for anterior hyperfunction and CS.

## Descriptions of the cases

### *Case 1: Pre-CS Patient; Immediate Placements at Maxillary Anterior Site to Prevent CS*

A 62-year-old female presented with a chief complaint of poor chewing function, especially in the anterior sites, and instability of her mandibular Class I partial denture (Figure 1). Bone resorption around the residual teeth was remarkable as analyzed in a panoramic X-ray film due to mastication shift to the anterior regions. However, the computerized tomographic (CT) scan showed that height and width of bone in the maxilla, including right maxillary second premolar and lateral incisor

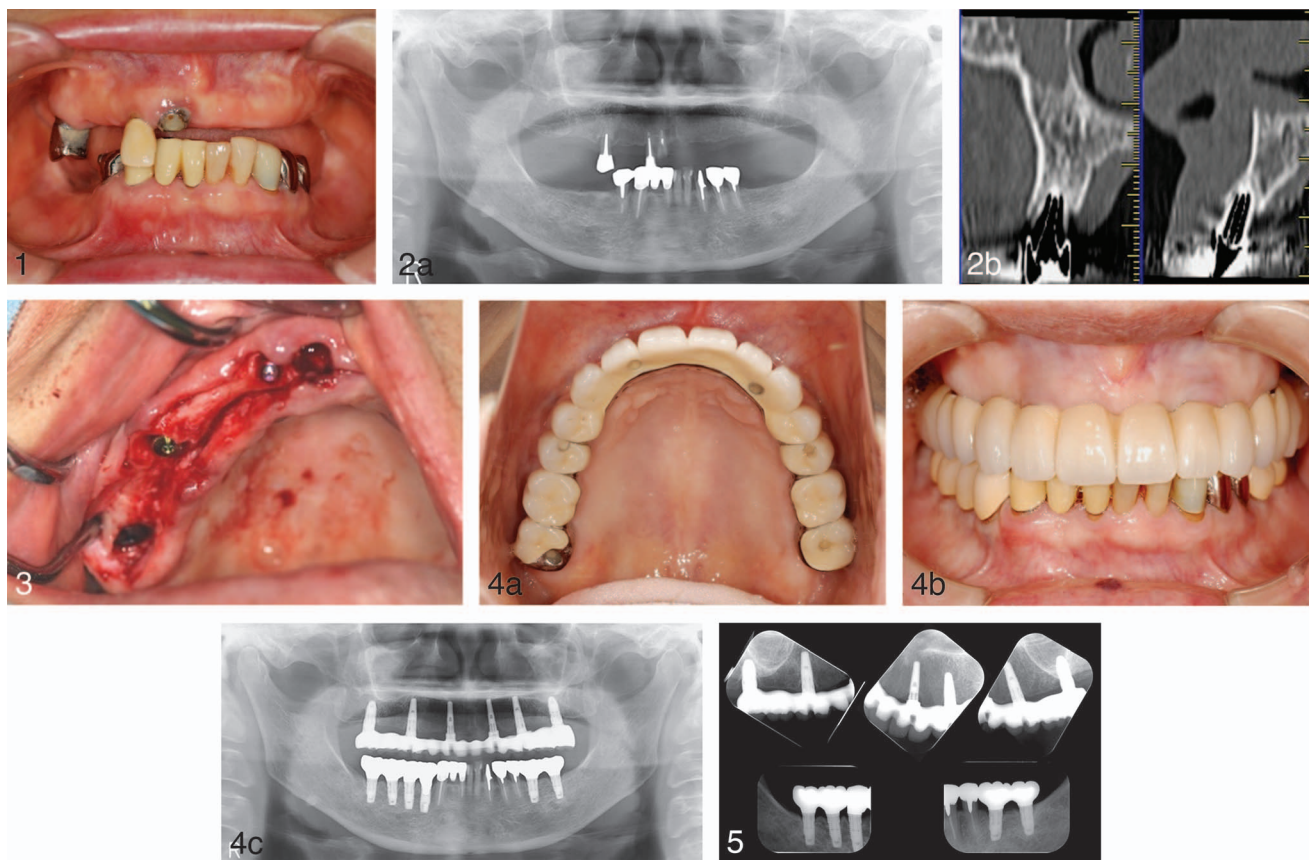
sites, was sufficient for implant placement (Figure 2). On the basis of the clinical and radiographic evaluation, 6 implants, including immediate placements at second premolar and lateral incisor sites, were placed for the fabrication of an implant-retained prosthesis (Replace Select Tapered, Figure 3). As the definitive prosthesis, screw-retained hybrid resin faced cast fixed partial dentures (FPD, Procera Implant Bridge [PIB]) were fabricated in the mandible (Figure 4). For the duration of the treatment and a follow-up period, the patient did not present with any complications (Figures 5 and 6). After the delivery of the final prosthesis, the patient was diagnosed with myeloma and decided house-moving for the treatment of it. She had been followed up for 8 months and did not complain of any concerns.

### *Case 2: Moderate CS Patient; A fixed Implant Rehabilitation Using a Hybrid Prosthesis in the Maxilla and Fixed Implant-Retained Prostheses in the Mandible*

A 51-year-old male presented with an edentulous maxillary (except for right second molar functioning as a root cap with a magnet attachment) and a dentate mandibular arch for prosthetic treatment. A clinical examination and a radiographic assessment were conducted and revealed flabby gum, papillary hyperplasia (Figure 7) and loss of bone at the anterior part of the maxillary ridge (Figure 8). The analysis of CT sections revealed that implant placements in the anterior maxilla were possible and posterior sites in the maxilla and the mandible also had adequate height and overall bone volume for implant placements. All 8 implants in the maxilla and 4 implants in the mandible (Replace Select Tapered) were placed uneventfully and acquired osseointegration. The maxillary prosthesis was articulated with a face bow transfer, and the mandibular prosthesis was articulated with the aid of a centric relation record made with vinyl polysiloxane material at the desired occlusal vertical dimension based on the provisional prostheses. Next, the maxillary fixed implant-retained hybrid prosthesis was fabricated with artificial teeth and denture base acrylic resin and processed onto a cast metal framework (Figure 9). In the mandible, the screw-retained definitive prostheses were also fabricated with ready-made abutments (Figure 10). The patient was given proper oral hygiene instructions for the prostheses and scheduled for routine maintenance recalls. Over the following 24 months, no complications were observed, including bone resorption around implants, and the patient was satisfied with both functions and comfort (Figure 11).

Section of Implant and Rehabilitative Dentistry, Division of Oral Rehabilitation, Faculty of Dental Science, Kyushu University, Fukuoka, Japan.

\* Corresponding author, e-mail: ogino@dent.kyushu-u.ac.jp  
 DOI: 10.1563/AAID-JOI-D-13-00123



**FIGURES 1–5.** **FIGURE 1.** Pretreatment frontal view of case 1 patient. **FIGURE 2.** Pretreatment panoramic radiograph and computerized tomographic scan images (sagittal view) at the residual teeth sites of case 1 patient. **FIGURE 3.** Intraoral view of the inserted implants of case 1 patient. **FIGURE 4.** Clinical photograph of completed prosthesis and posttreatment panoramic radiograph of case 1 patient. **FIGURE 5.** Posttreatment radiograph of case 1 patient at recall visit.

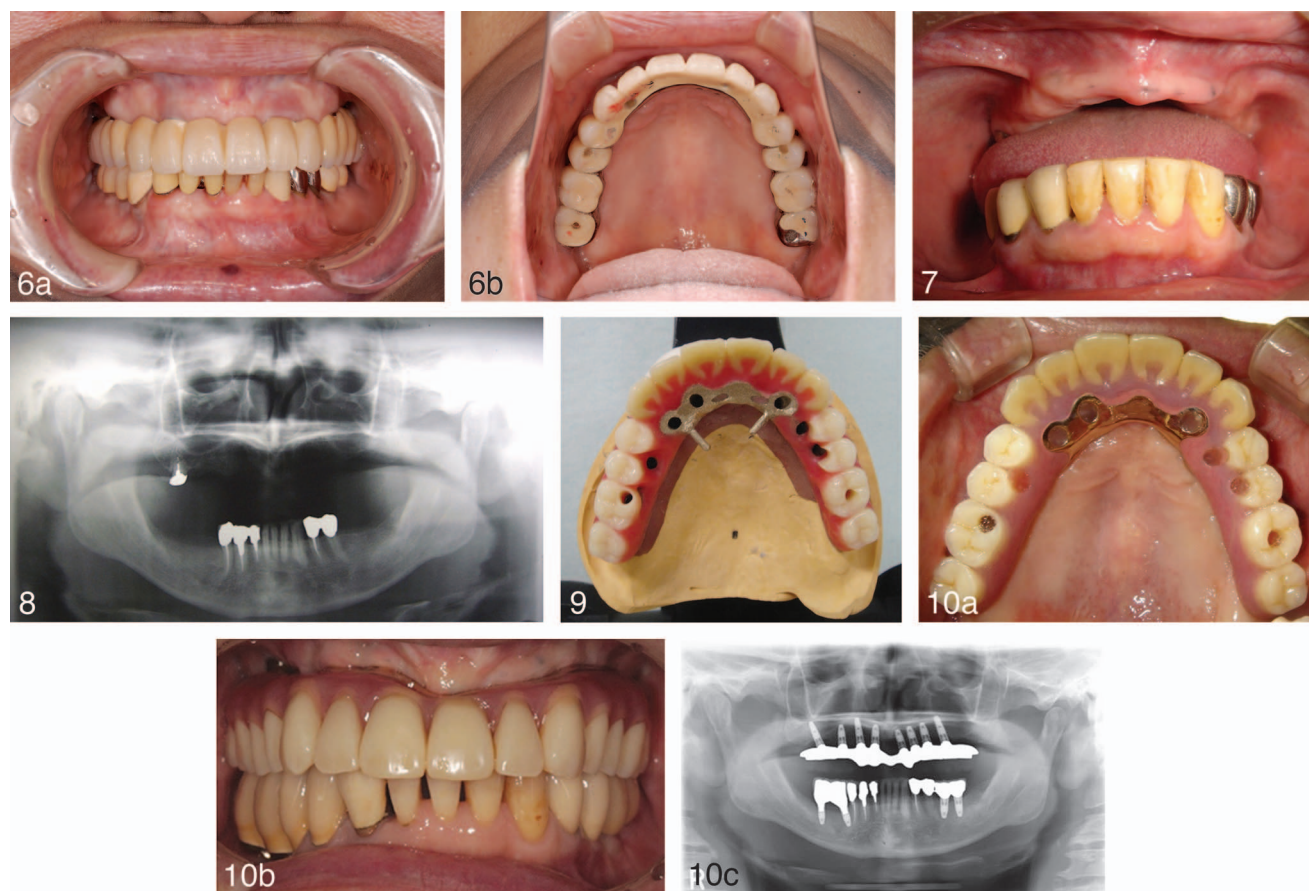
*Case 3: Severe CS Patient; A Fixed Implant Rehabilitation Using a Hybrid Prosthesis Without the Anterior Implants in the Maxilla and Fixed Implant-Retained Prostheses in the Mandible*

A 62-year-old female with a maxillary complete denture and a mandibular bilateral distal extension removable partial denture (RPD) presented and reported the difficulties in using her maxillary complete denture. She was exploring the option of a fixed maxillary prosthesis. Her medical history included chronic sinusitis (Figure 12). The maxilla had generalized very severe alveolar bone resorption in the anterior site and the posterior residual ridge, and the mandible appeared narrow and demonstrated moderate resorption (Figure 13). A CT examination of the maxilla revealed that the alveolar bone volume at the anterior site was insufficient for implant placements (Figure 14). Some treatment alternatives such as conventional and implant-supported fixed or removable prosthetic options were discussed and the patient’s treatment plan included surgical placement of 6 implants into the maxillary canine and posterior sites, and 4 implants into the posterior mandible, followed by a restorative prosthetic treatment with an implant-retained fixed prostheses in both jaws based on the patient’s expectations and the diagnostic findings. The patient had 6 implants from canine to molar in the maxilla (NobelSpeedy Groovy) and 4 implants in the mandible (molar: NobelReplace Straight Groovy,

premolar: NobelSpeedy Replace) placed uneventfully. The maxillary fixed implant-retained prosthesis was fabricated using the CAD-CAM milled titanium framework fabrication process (PIB). Porcelain fused to metal (PFM) restorations were fabricated as superstructures, while 8-unit PFM-FPD (Figures 15 and 16) and cement-retained PFM prostheses were fabricated as the definitive prostheses in the mandible (Figure 17). The patient was given proper oral hygiene instructions for the procedure and scheduled for routine maintenance recalls. No prosthetic complications were reported by the patient at the 2-year follow-up appointment (Figure 18).

**DISCUSSION**

Anterior hyperfunction, traumatic occlusion by preserved anterior teeth, causes CS. Tolstunov reported that anterior maxillary resorption resulting from the occlusal force of anterior mandibular teeth is the key feature of CS and proposed a clinically relevant classification.<sup>4</sup> Prevention of loss of posterior occlusion and avoidance of anterior hyperfunction are considered to be the main treatment approaches for CS. However, a conventional treatment, or a prosthetic treatment with a maxillary complete denture opposing a mandibular partial denture, cannot prevent CS completely. In other words, the



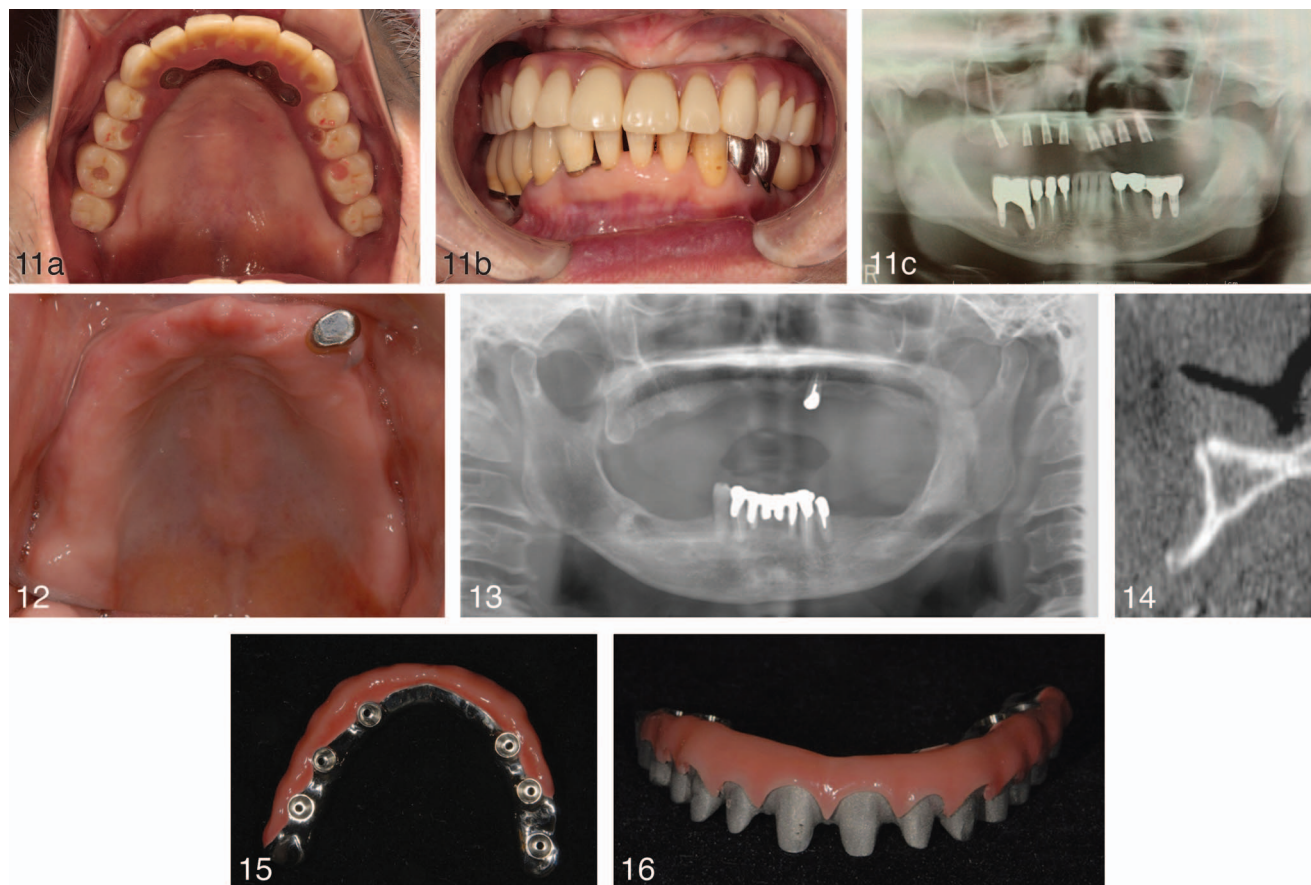
**FIGURES 6–10.** **FIGURE 6.** Clinical photograph of completed prosthesis of case 1 at recall visit. **FIGURE 7.** Pretreatment frontal view of case 2 patient. **FIGURE 8.** Pretreatment panoramic radiograph of case 2 patient. **FIGURE 9.** Occlusal view of maxillary definitive prosthesis of case 2 patient. **FIGURE 10.** Clinical photograph of completed prosthesis and posttreatment panoramic radiograph of case 2 patient.

deteriorating effects of CS can be less severe when both dentures are constantly adjusted and properly maintained as the bone resorption progresses, but continuous resorption is observed when patients do not return for follow-up care.<sup>5</sup> Prosthetic reconstructions with implants can definitely contribute to stable posterior occlusion, avoidance and support of anterior hyperfunction and even distribution of masticatory force over the entire dentition.

The presented 3 cases showed the symptom transition caused by anterior hyperfunction (bone resorption around anterior teeth, tooth loss, and hard and soft tissue changes). From this point of view, we can understand that there are several treatment modalities for the edentulous maxilla in accordance with the situation and discuss the treatment options and the management of anterior hyperfunction and CS through these 3 cases. When only the posterior occlusion is lost, reconstruction of posterior support with implants might be sufficient. However, the fabrication of implant-retained prostheses in both jaws including immediate implant placement in the maxilla would be required to avoid the unfavorable situation when the maxillary anterior teeth shift out of place and begin to flare out due to occlusal forces from the mandibular anterior teeth or some of the anterior teeth have already lost like case 1. The advantages of immediate implant

placement are considered to be the conservation of bony structures<sup>6–8</sup> and the ideal positioning of implants according to the natural teeth.<sup>8</sup> In this case, the patient could be adaptable to immediate implant placement fortunately, but careful patient selection might be required. In general, the fabrication of full-arch maxillary prosthesis after the immediate or the early implant placements and the reconstruction of posterior occlusion with implants can be effective procedures in avoiding anterior hyperfunction and bone resorption.

When the edentulous maxilla is treated with implants, an implant-supported or -retained removable prosthesis could be also the alternative prosthetic option.<sup>8,9</sup> Some papers propose that decisions regarding fixed or removable implant prostheses should be made at the diagnostic phase of treatment.<sup>10–12</sup> Although all patients desired to have the fixed prostheses, especially in their maxilla, a variety of prosthetic design were discussed. In previous reports, a minimum number of 6 implants for a fixed implant-supported reconstruction were needed in the edentulous maxilla and an even distribution of 6 implants in the anterior and the posterior region of the maxilla is the most accepted design due to some biomechanical problems that are evident in CS and pre-CS patients in particular.<sup>13,14</sup> For the fabrication of the maxillary implant-retained or -supported prosthesis, splinting and cross-arch

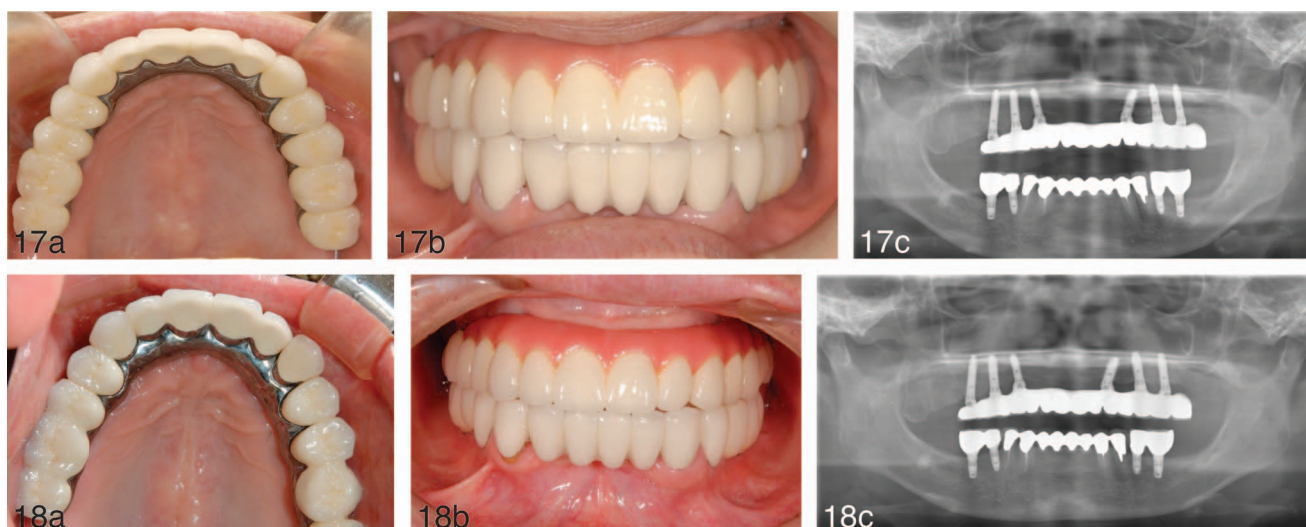


**FIGURES 11–16.** **FIGURE 11.** Clinical photograph of completed prosthesis and posttreatment panoramic radiograph of case 2 patient at 24 months recall. **FIGURE 12.** Pretreatment occlusal view of case 3 patient. **FIGURE 13.** Pretreatment panoramic radiograph of case 3 patient. **FIGURE 14.** Computerized tomographic scan image (sagittal view) at the maxillary anterior site of case 3 patient. **FIGURE 15.** Intaglio view of maxillary definitive prosthesis of case 3 patient. **FIGURE 16.** Frontal view of maxillary definitive prosthesis of case 3 patient.

stabilization and occlusal managements should be considered. Furthermore, the relationship between implant position and optimal artificial tooth positions is critical in determining the design for implant prostheses. From the standpoint of these factors, 6 implants could be placed into the planned positions of the artificial teeth and were consistent with the proposed prosthetic design in case 1 (Figures 4 and 5). In cases 2 and 3, posterior implants could be placed relative to the planned locations of the artificial teeth (Figures 8 and 14). In case 2, several implants could be placed into the anterior site. This strategic distribution of 8 implants and a splinted design with metal-reinforced prosthesis allowed the fabrication of a fixed prosthesis as the previous studies recommended,<sup>15–17</sup> and supported a predictable result. In case 3, treatment options, including bone grafts and prosthetic design (implant-supported removable overdenture), were discussed with the patient due to severe bone loss in anterior site in the maxilla. She declined a bone graft and eagerly desired to have a fixed-prosthesis. We decided to avoid bone graft and treat with a fixed-prosthesis for the following reasons: (1) 6 implants including canine sites could be placed evenly; (2) native bone in the posterior maxilla was sufficient for implantation; (3) the distribution of 6 implants enabled the splinting of implants together in the arch following a cross-arch stabilization

principle.<sup>12,13,18</sup> If these criteria are not met, a removable design should be considered. However, it is important to note that there are many standard surgical and prosthetic principles of treatment for the fixed rehabilitation of the edentulous maxilla with anterior hyperfunction, including not only the reconstruction of stable posterior occlusion as the main treatment approach for anterior hyperfunction or CS, but also available bone quantity and quality, appropriate implant position and placement, protective occlusal scheme, cross-arch stabilization, prosthetic design and adequate esthetics and phonetics as the considerations for the implant treatment of edentulous maxilla.<sup>12,13,18</sup>

The longevity of oral implants can be accomplished by well-controlled oral hygiene and an appropriate occlusal load. Case 2 and 3 patients could accept the regular maintenance and no complications have been reported. In case 1 patient, although we could not follow up directly, any complications have not been reported so far. To maintain soft tissue health around implants, the presence of keratinized tissue (keratinized gingiva or keratinized mucosa) has been shown to be advantageous for plaque control and physical barrier.<sup>19</sup> In these patients, the presence of KT was observed and we believe that it can contribute to better prognosis. Free gingival graft



**FIGURES 17 AND 18.** **FIGURE 17.** Clinical photograph of completed prosthesis and posttreatment panoramic radiograph of case 3 patient. **FIGURE 18.** Clinical photograph of completed prosthesis and posttreatment panoramic radiograph of case 3 patient at 24 months recall.

can be one of the therapeutic options for establishment of KT when the patients lacking KT are treated.<sup>20,21</sup>

Treatment of patients with anterior hyperfunction or pre-CS and CS can be a challenge for a dental practitioner because of the complexities associated with these conditions. To overcome these complexities, practitioners need to understand the pathogenesis and symptomatology of anterior hyperfunction and CS. Although an implant-retained or -supported prosthetic treatment can change the occlusal force distribution and seems to be one of the most effective treatment options, it is important to understand that it may be considerably more difficult to obtain successful results in implant treatment for the edentulous maxilla than the corresponding edentulous mandible. It is of utmost importance that an individualized approach for each anterior hyperfunction patient or CS patient is considered from both surgical and prosthetic aspects to rehabilitate CS symptoms effectively and long-term.

#### ABBREVIATIONS

CS: combination syndrome  
 FPD: fixed partial dentures  
 PFM: porcelain fused to metal  
 PIB: Procera implant bridge

#### REFERENCES

- Kelly E. Changes caused by a mandibular removable partial denture opposing a maxillary complete denture. *J Prosthet Dent.* 1972;27:140–150.
- Cibirka RM, Razzoog M, Lang BR. Critical evaluation of patient responses to dental implant therapy. *J Prosthet Dent.* 1997;78:574–581.
- Adell R, Eriksson B, Lekholm U, Branemark PI, Jemt T. Long-term follow-up study of osseointegrated implants in the treatment of totally edentulous jaws. *Int J Oral Maxillofac Implants.* 1990;5:347–359.
- Tolstunov L. Combination syndrome: classification and case report. *J Oral Implantol.* 2007;33:139–151.
- Carlsson GE, Ragnarson N, Astrand P. Changes in height of the alveolar process in edentulous segments. A longitudinal clinical and radiographic study of full upper denture cases with residual lower anteriors. *Odontol Tidskr.* 1967;75:193–208.
- Shanaman RH. The use of guided tissue regeneration to facilitate ideal prosthetic placement of implants. *Int J Periodontics Restorative Dent.* 1992;12:256–265.
- Watzek G, Haider R, Mensdorff-Pouilly N, Haas R. Immediate and delayed implantation for complete restoration of the jaw following extraction of all residual teeth: a retrospective study comparing different types of serial immediate implantation. *Int J Oral Maxillofac Implants.* 1995; 10:561–567.
- Werbitt MJ, Goldberg PV. The immediate implant: bone preservation and bone regeneration. *Int J Periodontics Restorative Dent.* 1992;12:206–217.
- Jivraj S, Chee W, Corrado P. Treatment planning of the edentulous maxilla. *Br Dent J.* 2006;201:261–279.
- Zitzmann NU, Marinello CP. Treatment outcomes of fixed or removable implant-supported prostheses in the edentulous maxilla. Part I: patients' assessments. *J Prosthet Dent.* 2000;83:424–433.
- Zitzmann NU, Marinello CP. Treatment outcomes of fixed or removable implant-supported prostheses in the edentulous maxilla. Part II: clinical findings. *J Prosthet Dent.* 2000;83:434–442.
- Drago C, Carpentieri J. Treatment of maxillary jaws with dental implants: guidelines for treatment. *J Prosthodont.* 2011;20:336–347.
- Lambert FE, Weber HP, Susarla SM, Belser UC, Gallucci GO. Descriptive analysis of implant and prosthodontic survival rates with fixed implant-supported rehabilitations in the edentulous maxilla. *J Periodontol.* 2009;80:1220–1230.
- Sagat G, Yalcin S, Gultekin BA, Mijiritsky E. Influence of arch shape and implant position on stress distribution around implants supporting fixed full-arch prosthesis in edentulous maxilla. *Implant Dent.* 2010;19:498–508.
- Tolstunov L. Management of biomechanical complication of implant-supported restoration of a patient with combination syndrome: a case report. *J Oral Maxillofac Surg.* 2009;67:178–188.
- Bergkvist G, Simonsson K, Rydberg K, Johansson F, Dérand T. A finite element analysis of stress distribution in bone tissue surrounding uncoupled or splinted dental implants. *Clin Implant Dent Relat Clin Res.* 2008; 10:40–46.
- Rossetti PH, Bonachela WC, Rossetti LM. Relevant anatomic and biomechanical studies for implant possibilities on the atrophic maxilla: critical appraisal and literature review. *J Prosthodont.* 2010;19:449–457.
- Att W, Bernhart J, Strub JR. Fixed rehabilitation of the edentulous maxilla: possibilities and clinical outcome. *J Oral Maxillofac Surg.* 2009;67:60–73.

19. Brito C, Tenenbaum HC, Wong BK, Schmitt C, Nogueira-Filho G. Is keratinized mucosa indispensable to maintain peri-implant health? A systematic review of the literature. *J Biomed Mater Res B Appl Biomater.* 2014;102:643–650.

20. Speroni S, Cicciu M, Maridati P, Grossi GB, Maiorana C. Clinical

investigation of mucosal thickness stability after soft tissue grafting around implants: a 3-year retrospective study. *Indian J Dent Res.* 2010;21:474–479.

21. Herford AS, Tandon R, Pivetti L, Cicciu M. Pedicled Lingual flap to provide keratinized tissue regeneration over dental implants: A description of the technique and a case report. *J Oral Implantol.* 2015;41:196–199.