

# Monolithic Lithium Disilicate Full-Contour Crowns Bonded on CAD/CAM Zirconia Complete-Arch Implant Bridges With 3 to 5 Years of Follow-Up

Alessandro Pozzi, DDS, PhD\*  
 Marco Tallarico, DDS  
 Alberto Barlattani, MD, DDS

This study was carried on to assess the clinical performance of a novel restorative concept consisting in single monolithic lithium disilicate full-contour crowns bonded on computer-aided design/computer-aided manufacturing (CAD/CAM) zirconia complete-arch implant bridges, to overcome the drawbacks related to the chipping of porcelain fused to zirconia restorations. Sixteen patients received 18 implant-supported hybrid screw-cement-retained complete-arch restorations, consisting of single monolithic lithium disilicate full-contour crowns bonded on CAD/CAM zirconia frameworks. The restorations were supported by 4–8 implants. All patients were followed up for at least 3 years on function (range 36 to 60 months, mean 49.3 months). Clinical controls were scheduled every 4 months. The outcomes were implant and prosthetic survival and success rates, any complications, patient satisfaction, and soft tissue parameters. No dropouts occurred. The overall implant and prosthesis survival rates were 100%. One of 18 restorations (1 of 236 dental units) showed a chip-off fracture of the veneering ceramic that was polished intraorally without any additional treatment, scoring a cumulative prosthetic success rate of 100%, according to the California Dental Association index. All patients were functionally and esthetically highly satisfied with their restorations. Successful soft tissue parameters were found around all implants. Single monolithic lithium disilicate full-contour crowns, bonded on CAD/CAM screw-retained complete-arch zirconia frameworks, showed favorable preliminary outcomes with medium-term follow-up. However, randomized controlled studies of this technique are required for further conclusive recommendations.

**Key Words:** complete-arch fixed dental prosthesis, computer-assisted design/computer-assisted manufacturing, dental implants, edentulous, zirconia, lithium disilicate

## INTRODUCTION

**M**etal-ceramic crowns constitute the most common and reliable prosthodontic treatment.<sup>1</sup> Nevertheless, metal-ceramic fixed partial dentures (FPDs) might not be ideal from an esthetic perspective, and they can suffer other problems, such as galvanism and toxicity.<sup>2–4</sup> Ongoing research into esthetic and biocompatible materials has popularized the use of all-ceramic reconstructions as an alternative to conventional metal-ceramic restoration (MCRs).<sup>5,6</sup> In a systematic review, based on at least 3 years of function in the anterior dentition, all-ceramic crowns showed comparable survival rates to metal-ceramic crowns.<sup>7</sup> Conversely, all-ceramic restorations in molars showed significantly higher fracture rates than restorations in premolars and anterior teeth (21%, 7%, and 3%, respectively).<sup>7,8</sup> High-strength metal-oxide ceramics have been developed to address the high fracture rate of the pristine all-ceramic systems.<sup>9</sup> Zirconium dioxide (ZrO<sub>2</sub> or zirconia) has gained increasing popularity in contemporary dentistry due to its high biocompatibility,<sup>10,11</sup> low plaque

surface adhesion,<sup>12</sup> high flexural strength and toughness,<sup>13</sup> absence of mucosal discoloration,<sup>14</sup> and favorable esthetic properties.<sup>15,16</sup> Comparing yttria-stabilized tetragonal zirconia polycrystal (Y-TZP) with high-gold cast alloys from the standpoint of biocompatibility, bacterial and plaque adhesion has been reduced, preventing soft tissue inflammation,<sup>14,15,17–19</sup> contributing to implant-supported restorations achieving healthy soft tissue integration, and improving the long-term stability of the marginal bone.<sup>19,20</sup> Nevertheless, the latest published systematic review regarding the survival and complications of zirconium dioxide frameworks concluded that porcelain-fused-to-zirconia (PFZ) FPDs could serve as alternatives to conventional metal-ceramic FPDs in the anterior and posterior dentition, but short-term clinical data are currently available.<sup>21</sup>

The primary clinical concern reported in the literature regarding the use of Y-TZP as framework material has been the higher incidence of veneering porcelain chip-off fractures, ranging between 11.5% and 54.0% over a 3- to 5-year period,<sup>5,6,17,21</sup> compared to the 2.9% and 8.8% ceramic fracture rates observed in conventional tooth- and implant-supported metal-ceramic restorations over 5 years.<sup>22</sup> According to a comparative review,<sup>5</sup> zirconia-based FPDs exhibited 7% more veneer chipping when directly compared with metal-based

Department of Oral Rehabilitation, University of Rome, Tor Vergata, Rome, Italy.

\* Corresponding author, e-mail: profpozzi@me.com

DOI: 10.1563/AAID-JOI-D-13-00133

TABLE

## Inclusion and exclusion criteria

Inclusion Criteria	Exclusion Criteria
Informed consent	General medical and/or psychiatric contraindications (ASA Class III or IV)
Full mouth bleeding on probing $\leq 25\%$	Bisphosphonate therapy
Full mouth plaque index $\leq 25\%$	Alcohol or drug abuse
Residual alveolar crest of at least 10 mm in length and 3.5 mm in width	Radiation therapy to head or neck region in the previous 5 years
Stable occlusal relationship	Heavy smoking (more than 10 cigarettes/day)
Soft and/or bone tissue grafts performed at least 6 months before the implant insertion	Severe bruxism
Hopeless teeth extracted at least 8 weeks before implant placement	Absence of teeth/dentures in the opposite jaw
	Untreated periodontitis
	Poor oral hygiene
	Unavailability to attend the follow-up visits

FPDs, and core fractures occurred in less than 1% of the zirconia-based FPDs, while none of the metal cores fractured. Several hypotheses concerning the causes of chipping of porcelain veneer have been reported, and factors such as the framework design, the laboratory handling, the baking procedures, and the mechanical properties of the veneering material have been reported to be of particular importance.<sup>20–23</sup>

In the late 1990s, the lithium disilicate glass-ceramic system (IPS Empress II, Ivoclar Vivadent AG, Schaan, Liechtenstein) was introduced into daily practice as an alternative option for single-unit restorations, as well as for 3-unit FPDs limited to the anterior and premolar areas<sup>24–27</sup> to overcome the mechanical drawbacks of the pristine all-ceramic systems and to fulfill better the esthetic demands of patients. The latest developments have improved the physical and optical properties of the lithium disilicate glass-ceramic system,<sup>28,29</sup> the ingots of which, produced in a wide range of shades and translucencies, can be processed using the lost-wax hot pressing technique (IPS e.max Press, Ivoclar Vivadent AG) or computer-aided design/computer-aided manufacturing (CAD/CAM) milling procedures (IPS e.max CAD, Ivoclar Vivadent AG).<sup>30</sup> The microstructure of this pressable lithium disilicate glass-ceramic (IPS e.max Press, Ivoclar Vivadent AG) consists of approximately 70% of lithium disilicate crystals ( $\text{Li}_2\text{Si}_2\text{O}_5$ ), which are embedded in a glassy matrix. The glass matrix and crystals have a refractive index of light similar to that of the dental structure, allowing for high standard esthetics.<sup>28</sup> The flexural strength of the lithium disilicate glass-ceramic varies from 360 to 400 MPa.<sup>31,32</sup>

Single full-contour lithium-disilicate glass-ceramic crowns can be used for the rehabilitation of the anterior and posterior regions, irrespective of adhesive or conventional cementation.<sup>33</sup> High survival rates (100% after 2 to 5 years) with no fractures have been reported for monolithic pressable, as well as for CAD/CAM-fabricated lithium disilicate crowns.<sup>24,33</sup> To date, few *in vivo* studies of lithium disilicate glass-ceramic FPDs have been published. Furthermore, there has been a severe lack of literature on all-ceramic single crowns bonded on CAD/CAM frameworks for the rehabilitation of edentulous patients.<sup>34</sup> The primary concern with lithium disilicate glass-ceramic is with regard to its clinical reliability for multiple restorations in both the anterior and posterior areas.<sup>24,26</sup> The fracture rate in the

esthetic region after a 10-year follow-up was 28.6%, and the fractures were mostly located at the interface between the connector and the pontic.<sup>25</sup>

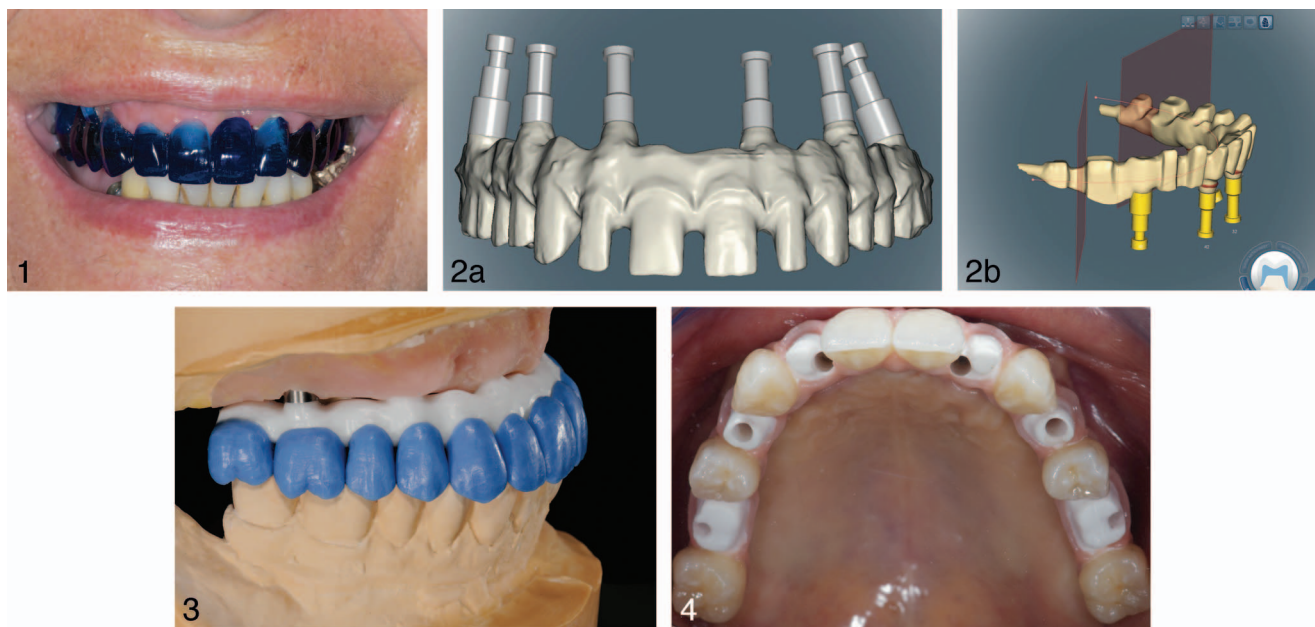
The aim of this exploratory study was to evaluate the implant survival and prosthetic success and survival rates of patients rehabilitated with monolithic lithium disilicate full-contour crowns bonded on CAD/CAM complete-arch zirconia implant bridges. This study design was chosen to follow this novel restorative option prospectively over at least 3 years in function. The rationale of this treatment protocol was to increase the clinical reliability of zirconium dioxide as a framework material for complete-arch implant-supported restorations and to reduce the mechanical drawbacks of traditional ceramic layering using high-strength lithium disilicate crowns. This study followed the STROBE (STrengthening the Reporting of OBservational studies in Epidemiology) guidelines (<http://www.strobe-statement.org/>).<sup>35</sup>

## MATERIALS AND METHODS

This study was performed in accordance with the guidelines of the Declaration of Helsinki and with the participants' informed consent. The patients were recruited from and treated in a specialized rehabilitation center (Department of Oral Rehabilitation, University of Rome Tor Vergata, Rome, Italy) between April 2008 and March 2010, and all the subjects were followed up in function for at least 3 years. The Scientific Technical and Ethical Committee of Tor Vergata University of Rome approved the study protocol. One clinician performed all surgical and prosthetic procedures, and a dental laboratory manufactured all restorations. The inclusion and exclusion criteria are reported in the Table.

### Pretreatment surgical and prosthetic planning

Before implant placement, every patient underwent cone-beam computerized tomography (CBCT) (SCANORA 3D, Soredex, Tuusula, Finland) with a double-scan protocol.<sup>36</sup> Radiographic acrylic resin templates, without any vestibular prosthetic flanges (Figure 1), were created from diagnostically waxed casts and were modeled according to functional and esthetic



**FIGURES 1–4.** **FIGURE 1.** Radiographic acrylic resin templates without any vestibular prosthetic flanges, to assess the prosthetic emergence profile according to the smile line of the patient. **FIGURE 2.** The CAD design of the zirconia frameworks, customized to accommodate the single lithium disilicate full-contour crowns and to ensure the minimum thickness of the connectors recommended by the manufacturer: (a) in the upper jaws and (b) in the lower jaws. **FIGURE 3.** The single lithium disilicate full-contour crowns waxed up onto the zirconia framework. **FIGURE 4.** The lithium disilicate full-contour crowns, not involving the screw access holes of the zirconium dioxide framework, were cemented in the laboratory, and the remaining crowns were placed directly into the mouth after having screwed the restoration.

parameters. Six to 8 radiopaque markers (Hygenic Temporary Dental Stopping; Coltène/Whaledent Inc, Cuyahoga Falls, Ohio), measuring 1.5 mm in diameter, were placed in the lingual and palatal flanges. A centric occlusion rigid vinyl polysiloxane index (Exabite II NDS, GC America Inc, Alsip, Ill) was made to stabilize the template against the opposing dentition during the CBCT scan. The Digital Imaging and Communication in Medicine data of the 2 sets of scans were transferred to a 3-dimensional software planning program (NobelGuide, Nobel Biocare AB, Kloten, Switzerland) and were matched to each other. All implants were placed by means of computer-assisted software (NobelGuide, Nobel Biocare AB), according to the biomechanical, biological, and esthetic demands of the patients. The implant position and angulation were guided by the prosthetic emergence profile. The digital data were sent to the central production unit for fabrication of surgical templates.

Four to 8 implants were planned for the rehabilitation of each participant. Three different types of implants were used; however, all implants had the same porous anodized surfaces (TiUnite, Nobel Biocare AB). A total of 132 (38 NobelSpeedy Groovy, 32 NobelSpeedy Replace, 62 NobelActive, Nobel Biocare AB) implants were placed with a flapless (86) or mini-flap approach (46). The implants were placed axially ( $n = 120$ ) or tilted ( $n = 12$ ). The selection of axial or tilted implant placement was based on clinical and radiologic judgments to overcome the anatomic limitations of atrophic posterior jaws.

The stereolithographic surgical templates were used to pour the preoperative master casts with the implant replicas in place. A complete mounting technique was applied to articulate the opposite arch cast with the surgical template seated onto the master cast. A surgical occlusion index (Exabite

II NDS, GC America Inc) was created to enable the accurate seating of the surgical template during the intervention. Subsequently, in all patients, a metal-reinforced, screw-retained, acrylic resin interim restoration without any cantilever was prefabricated for immediate implant loading. Marginal precision, retention, and stability were obtained by relining with an autopolymerizing polyurethane resin (Voco GmbH, Cuxhaven, Germany) on the non-engaging titanium temporary abutments (Temporary Abutment Non-Engaging, Nobel Biocare AB), which were screwed onto the implants. Occlusion was carefully assessed by means of a 40- $\mu$ m articulating paper (Bausch Articulating Paper, Köln, Germany), until light occlusal contacts, uniformly distributed on the entire prosthetic arch, were obtained, avoiding any lateral contact.

#### **Prosthetic workflow**

Following an uneventful healing period of 3 months for the mandible and 4 months for the maxilla, definitive impressions were obtained at the implant level. An open-tray implant impression was used for each patient. A set of digital radiographs was obtained to verify the complete seating of the impression copings. The impressions were obtained using custom impression trays (Elite LC tray, Zhermack SpA, Badia Polesine, Rovigo, Italy) and plaster (Snow White Plaster No. 2, Kerr, Romulus, Mich). New implant replicas (Nobel Biocare AB) were connected; subsequently, all definitive casts were made with the same materials (Gingifast, Zhermack SpA and low-expansion type IV stone, FujiRock EP, GC Europe, Leuven, Belgium), according to the manufacturer's instructions. The interim restoration was used to transfer a fully adjustable

articulator into the occlusion and the vertical dimension of the patients. The prosthetic volume and the related esthetic and phonetic information, functionally established during an uneventful healing period of 3–4 months in function, were gathered from the temporary prosthesis using a silicone putty index. A cross-mounting technique was applied to articulate the opposite arch cast with the interim restorations screwed onto the master cast, using an interocclusal jig. Furthermore, the provisional restoration provided functionally established anterior guidance for the patient, which was recorded to customize the anterior guide table of the articulator.<sup>37</sup> Non-engaging abutments (Nobel Biocare AB) were screwed onto the master cast, and a low-shrinkage acrylic resin (GC Pattern resin LS, GC Europe NV) was injected into the silicone index to obtain a full-contour mock-up. The acrylic-resin framework was customized by a cutback procedure to ensure both an adequate volume to accommodate the single lithium disilicate full-contour crowns and the minimum thickness of the connectors, as recommended by the manufacturer. The connector area of the complete-arch frameworks had a minimum cross-sectional area of 12 mm<sup>2</sup>, with a minimum of 4 mm in height and 3 mm in width between the units. To eliminate the shrinkage effect of the acrylic material, 0.1 mm cuts were made between the implants, and a small amount of acrylic material was used to reconnect the sections. All frameworks were designed with a cross-section calyx-shape, with the lingual/palatal shoulder located at least 3 mm from the gingival tissue, to increase the volume of the zirconia framework and to keep the prosthetic interface far from the soft tissue. The acrylic-wax framework was scanned using 2 technologies: tactile (Procera Forte scanner; Nobel Biocare AB) or optical, with a conoscopic holographic technique (Nobel-Procera scanner; Nobel Biocare AB) (Figure 2a and b). The data obtained were digitized and subsequently milled at a centralized production facility.

The accuracy of all the CAD/CAM zirconium dioxide frameworks was assessed on the master casts, using a Nikon microscope (SMZ1B, Nikon Instruments, Calenzano, Florence, Italy) at  $\times 35$  magnification and the Sheffield one-screw test.<sup>38</sup> The zirconia frameworks designed were checked and eventually reshaped to enhance the proper seating of the single lithium disilicate crowns. A silicone index, reporting the prosthetic volume of the temporary restorations, was used to transfer the functional and esthetic information, regarding the smile design, tooth morphology, and position on the master cast. The single lithium disilicate full-contour crowns were manufactured by means of a conventional lost-wax hot pressing technique (Figure 3). The shades of the lithium disilicate ingots were selected according to the esthetic requirements of the patients and to match the color of the opposing dentition. Under heat and pressure, the ceramic material was melted and injected into the investment mold, filling the space previously occupied by the wax. After the cooling phase, the injected structures were separated from the molds and were adapted onto the framework surfaces to achieve an adequate contour of the restoration and the accuracy of the prosthetic finishing line. The upper anterior single pressed dental units were veneered by conventional ceramic stratification to obtain a more natural, lifelike restoration (GC Initial Zr-FS, GC Europe NV), after

trimming the original contour with a cut-back procedure in the areas requiring higher esthetics (ie, the incisal third). The lower single-pressed crowns and the upper posterior crowns were stained with newly developed 3-dimensional ceramic stains, which could be applied in thicker layers onto the lithium disilicate surfaces, creating color deepness and lifelike translucency (GC Initial IQ Lustre Pastes, GC Europe NV). All restorations were tried on, their superficial texture was created, and final individual characterizations were performed as needed to produce a more lifelike appearance.

### **Cementation protocol**

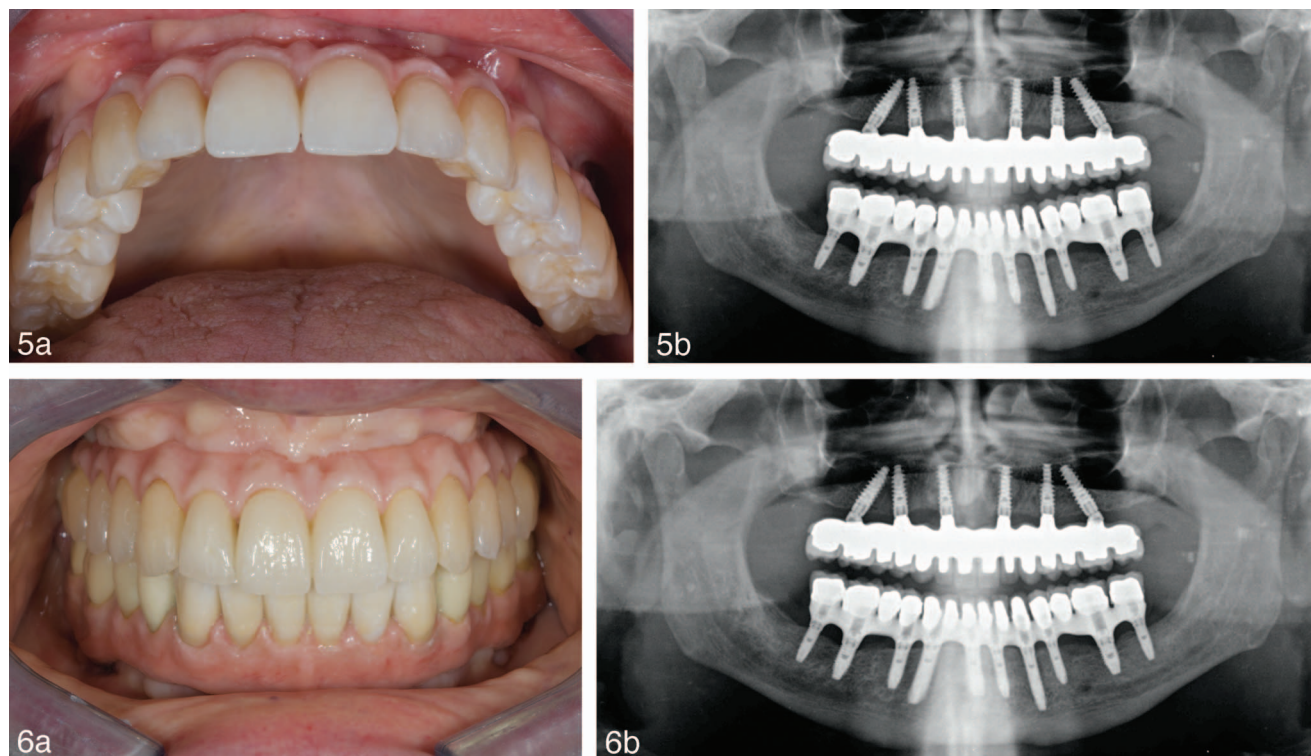
The surface conditioning of the zirconium dioxide framework was performed in the laboratory with aluminum oxide airborne-particle abrasion (50  $\mu\text{m}$  Al<sub>2</sub>O<sub>3</sub>, <0.2 MPa, 5.0 cm far from the framework), and the frameworks were then steam cleaned. The internal surfaces of the lithium disilicate crowns were etched for 20 seconds with 4.9% hydrofluoric acid, rinsed with water for 2 minutes, and air-dried with oil-free air. Then, a 10-methacryloyloxydecyl dihydrogen phosphate-containing bonding/silane coupling agent mixture (Clearfil Ceramic Primer, Kuraray Europe GmbH, Frankfurt, Germany) was applied on both the zirconium dioxide frameworks and the etched surfaces of the crowns for 60 seconds before adhesive cementation. Furthermore, a self-adhesive resin cement (Clearfil SA Cement, Kuraray Europe GmbH) was used for the luting procedure. The lithium disilicate full-contour crowns, not involving the screw access holes of the zirconium dioxide framework, were cemented in the laboratory, and the remaining crowns were placed directly in the mouth, after screwing the restorations according to the manufacturer's instruction (Figure 4). The zirconium dioxide framework surfaces and the remaining lithium disilicate crowns were cleaned intraorally with a solution of isopropanol and were prepared and bonded with the same aforementioned procedures, after displacing the gingival tissue with a cord if needed and isolating the screw access holes with Teflon tape (Figure 5a and b).

All restorations were assessed by a prosthodontist with regard to their design, marginal fit, surface finish, and occlusion. Mutually protected occlusion with anterior guidance or balanced occlusion was used in cases of opposing fixed prostheses and completely removable dentures, respectively. A rigid acrylic nightguard was provided to protect the veneering porcelain from occasional parafunctional habits, and the patients were informed about the importance of the daily wearing of this appliance. The patients were recalled every 4 months for hygiene maintenance and annually for occlusal adjustment. In addition to the recall intervals, the patients were asked to consult the clinic immediately if complications were observed. The final visit occurred at least 3 years after prosthesis delivery (mean 49.3 months, range 36–60 months) (Figure 6a and b).

### **Study outcomes**

The primary outcome measurements, assessed 15 days after prosthesis delivery and then annually, were the implant and prosthetic survival and success rates. Regarding the implants, the success and survival criteria used in this study were





**FIGURES 5 AND 6. FIGURE 5.** (a) Occlusal view of monolithic lithium disilicate full-contour crowns bonded on a CAD/CAM zirconia complete-arch implant bridge in the upper jaw. (b) Postinsertion panoramic radiograph, verifying accurate fit of the definitive restoration. **FIGURE 6.** (a) The clinical and (b) radiographic outcomes at the 5-year follow-up.

modifications of the success criteria suggested by van Steenberghe.<sup>39</sup> According to the above criteria, a “successful implant” was an implant that: (1) did not cause allergic, toxic, or gross infectious reactions, either locally or systematically; (2) offered anchorage to a functional prosthesis; (3) did not show any signs of fracture or bending; and (4) did not show any sign of radiolucency on intraoral radiography using a paralleling technique, strictly perpendicular to the implant-bone interface. A surviving implant was defined as an implant remaining in the jaw and that was stable, though all of the individual success criteria were not fulfilled, while a failed implant was an implant that had been removed. A “surviving prosthesis” was a prosthetic reconstruction that was stable and in good function. Prosthesis success was evaluated following a modification of the evaluation criteria, suggested by the California Dental Association (CDA).<sup>40</sup>

The secondary outcomes were patient satisfaction and soft tissue parameters. Patient satisfaction was assessed at the 3-year follow-up examination. Patients provided personal overall satisfaction scores regarding masticatory function and the esthetics of their restorations on a visual analog scale (VAS). The patients marked their opinions on a 100-mm scale between 0 (maximal disagreement or minimal experience) and 100 (maximal agreement or maximal experience). An independent outcome assessor asked the following questions:

- Are you satisfied with the function of your implant-supported prosthesis?

- Are you satisfied with the esthetic outcome of your implant-supported prosthesis?

Soft tissue parameters (bleeding on probing, plaque index, and gingival index scores) around the implants were assessed at the 1- and 3-year examinations. Bleeding on probing (BoP) was assessed using a plastic periodontal probe (Plast-o-Probe, Dentsply Maillefer, Ballaigues, Switzerland) on 4 sites around each implant (mesial, distal, buccal, and lingual), according to the Mombelli index,<sup>41</sup> and was reported at the restoration level. Plaque score (PS) and gingival index (GI) were assessed and reported at the implant level. PS, defined as the presence of plaque (yes/no), was scored by running a periodontal probe (PCP15, Hu-Friedy, Chicago, Ill) around the implant, parallel to the abutment surfaces, and was calculated as a percentage on the basis of the total measurement points. GI was defined as follows: 0 = normal gingiva; 1 = mild inflammation, slight change in color, slight edema, no BoP; 2 = moderate inflammation, redness, edema, and glazing, BoP; and 3 = severe inflammation, marked redness and edema, ulceration, and tendency toward spontaneous bleeding.

### RESULTS

Sixteen patients (9 women and 7 men), with an overall mean age of 73.9 years (range 61–81) at definitive prosthesis delivery, met the inclusion/exclusion criteria and were consecutively enrolled in this study. Two (11.1%) patients were smokers (less than 10 cigarettes per day), and 1 patient (5.5%) showed signs

of occasional parafunctional activity (based on the patient's history and clinical examination). All patients had at least 1 arch to be restored. The opposite arches were implant-supported PFZ or MCR complete-arch restorations ( $n = 6$ ), removable partial dentures ( $n = 1$ ), and natural dentitions ( $n = 7$ ). Two of 16 patients were edentulous in both arches, resulting in a total of 18 implant-supported complete-arch restorations. Twelve of 18 restorations were made in the upper jaw. All restorations were supported by 4 to 8 implants, for a total of 132 implants. Each restoration consisted of 12–16 dental units, resulting in a total of 236 single lithium disilicate full-contour crowns. Two of 18 restorations presented distal cantilevers not exceeding 10 mm.

No implants were lost, and all prostheses were in situ at the time of examination, accounting for a cumulative implant and prosthetic survival rate of 100% up to 5 years. All restorations were structurally intact, and only one chip-off fracture of the veneering ceramic, classified as "Sierra,"<sup>40</sup> occurred. No replacements of the prostheses were necessary, for a cumulative prosthetic success rate of 100%. The only experienced chip-off fracture was judged as "cohesive," due to the lack of exposure of the core material.<sup>17</sup> This cohesive fracture was found on the lingual surface of a left mandible first molar and was polished intraorally (Dialite, Brasseler USA, Savannah, Ga), without requiring any additional treatment due to its small size.

No other mechanical complications (such as screw loosening and/or zirconium dioxide framework fracture) occurred during the entire follow-up period.

The results of the VAS revealed that all participants were functionally and esthetically satisfied with their prostheses. The average VAS score was 98.1 (SD 2.8; range 90–100) for esthetics and 95.5 (SD 2.3; range 90–100) for function.

After 1 year in function, BoP was reported for 12 implant/abutment complexes of 3 restorations (16.6%). The cumulative PS was 6.4%. The GI was reported as 83.8% normal gingiva, 10.8% with mild inflammation, and 5.4% with moderate inflammation. Significant reductions in plaque and bleeding scores were observed throughout the study. At the 3-year follow-up visit, the results for BoP and PS were 5.2% and 2.3%, respectively. The GI was reported as 92.1% normal gingiva, 4.2% mild inflammation, and 3.7% moderate inflammation.

## DISCUSSION

This preliminary study was undertaken to assess the implant and prosthetic survival and success rates of a novel restorative concept, consisting in single monolithic lithium disilicate full-contour crowns bonded on CAD/CAM zirconia complete-arch implant bridges for a medium-term period.

The main limitations of the present study were the absence of a control group and the relatively small sample size. An exploratory study is undertaken when not much is known about the investigated procedure at hand, or no information is available regarding how similar research issues have been investigated. The clinical performance of lithium disilicate glass ceramic for the implant rehabilitation of partially and fully edentulous patients has not yet been investigated. There have been only a few studies reporting clinical data for single implant-supported lithium disilicate crowns.<sup>24,33</sup> Thus, preliminary research was undertaken to comprehend better the

results of the tested procedure because very few studies have been conducted in this area. Future rigorous multicenter, randomized, controlled trials, with a priori sample size calculations, could then proceed. However, in this study, all patients were followed for at least 3 years, and the sample size was similar to that of previous studies investigating lithium disilicate for both single crowns<sup>24,33</sup> and FPDs.<sup>24–27</sup>

The presented research was the first study of monolithic lithium disilicate full-contour crowns bonded on CAD/CAM zirconia complete-arch implant bridges. Hence, it is not possible to compare it directly with other studies, and the present research should be considered an exploratory work. Furthermore, the study population would not allow for the detection of the potential effects of some variables, such as surgical procedure, type of bone, number, and/or angulation of implants, different opposing dentition or restorations, and cantilevers.

Excluding a few case reports, only 1 retrospective study, with follow-up of up to 10 years, has investigated the prosthetic outcomes of a similar prosthetic concept.<sup>34</sup> Nevertheless, the aforementioned study reported the clinical outcomes of porcelain-layered alumina or zirconia single crowns, bonded on CAD/CAM titanium frameworks, with cumulative survival rates of 92.4% at 10 years and 100% at 5 years for the alumina group and zirconia group, respectively. However, ceramic fractures occurred in 41.6% of the prostheses. The prosthetic concept's flexibility was highlighted by the easy and comfortable replacing of the fractured crowns, without the need to remove definitive restorations from the patients' mouths.

The 5-year survival rates of pristine all-ceramic crowns and conventional MCRs, from comprehensive and systematic reviews, have indicated that metal-ceramic implant crowns showed a survival rate (95.4%) significantly higher than the all-ceramic crown survival rate (91.2%).<sup>22,42</sup> The failure types of the all-ceramic restorations were fractures or porcelain chipping, often requiring the replacement of the restoration itself.<sup>22,34,42,43</sup> Furthermore, the molar crowns revealed higher failure rates, compared with premolar crowns.<sup>6,44</sup> In contrast, only minor chipping of a lithium disilicate crown was observed in this study, resulting in overall prosthetic survival and success rates of 100% at up to 5 years, according to the CDA index.<sup>40</sup>

Lithium disilicate glass ceramic was used to fabricate FPDs on natural anterior teeth, resulting in a fracture rate of 28.6% after 10 years in function.<sup>25</sup> Marquardt and Strub<sup>24</sup> obtained similar results, with a failure rate of 30% observed in 31 patients over a 5-year period. Nevertheless, the high fracture rate was correlated by the authors with the inadequate dimensions of the connectors, that did not meet the manufacturer's specifications. In contrast, a recent prospective study by Wolfart et al,<sup>26</sup> evaluating the clinical outcomes of 36 lithium disilicate glass-ceramic FPDs (84% in posterior sectors and 16% in anterior sectors), reported a 7% fracture rate over 8 years in function.

The high flexural strength of zirconium dioxide has allowed for its use as a framework material for FPDs in the anterior and posterior regions, as well as for complete-arch restorations.<sup>6,45</sup> Paspaspyridakos and Lal,<sup>20</sup> in a recent retrospective case series study, concluded that CAD/CAM zirconia-based implant-supported FPDs were a viable prosthetic treatment after 2–4 years

in function. Similarly, Larsson et al,<sup>46</sup> in a recent prospective clinical study of zirconia-based implant-supported complete-arch restorations, did not report any fractures of the zirconium dioxide frameworks 3 years after definitive prosthesis delivery, as well as high overall patient satisfaction. Zirconium dioxide, due to its high strength, combined with its high biocompatibility, low plaque surface adhesion, absence of mucosal discoloration, and esthetic properties contributed to achieving successful soft tissue integration and patient satisfaction over time.<sup>6,20,46</sup> However, the strength of the zirconium dioxide frameworks can be influenced by different surface treatment methods, which exert different degrees and types of surface damage.<sup>45-48</sup> These areas of surface flaws can act as stress concentration sites, leading to crack initiation and propagation, thus decreasing the strength of the veneering material.<sup>46</sup> Surface microcracks can also be induced by framework grinding performed on fully sintered zirconia material. Accurate and precise implant placement, according to the biomechanical, biological, and esthetic demands of the patient, is advocated to deliver a customized zirconium dioxide framework, to reduce the amount of postsintering reshaping and thus the occurrence of surface flaws. In the present study, the surface conditioning of the zirconium dioxide frameworks was performed with aluminum oxide airborne-particle abrasion (50  $\mu\text{m}$   $\text{Al}_2\text{O}_3$ , <0.4 MPa, 5.0 cm from the framework) and steam cleaning. The 50- $\mu\text{m}$  airborne particle abrasion of the zirconium dioxide framework is a crucial step in increasing the interfacial bond strength between the zirconium dioxide framework and the resin luting agent, by removing the weakly attached surface grains and the milling and grinding trace lines.<sup>47,49,50</sup> Further treatments, such as liner application, regeneration firing before porcelain veneering, and the backing of the veneering material, were avoided. The use of a cold framework represented an important improvement in the novel treatment option investigated in this study, to overcome the poor heat conductivity of the zirconia framework. The lower thermal diffusivity of Y-TZP can result in unfavorable temperature distributions during the backing and cooling procedures, consequently affecting the development of the internal stresses within the framework, in the veneering material and at the interface.<sup>51,52</sup> However, chipping of the veneering porcelain seems to be a frequent problem with zirconia-based restorations on teeth<sup>3,5,21</sup> and implants,<sup>46,53</sup> and it sometimes cannot be resolved only by porcelain polishing.<sup>46,53</sup> Technical factors in the manufacturing process, such as the design of the framework, grinding of zirconium dioxide after sintering, bond strength at the veneering interface, mechanical properties, and handling of the veneering porcelain, have been reported to be of particular importance in avoiding veneering fractures.<sup>3,5,20-23</sup> Moreover, no universal consensus favoring any of these theories has been expressed,<sup>46</sup> and no consensus-based guidelines to overcome these drawbacks have been reported.

To merge long-term durability and biocompatibility with a natural, lifelike appearance, this proof of concept study was developed for the treatment of fully edentulous patients, combining the advantages of CAD/CAM zirconia-based frameworks (NobelProcera, Nobel Biocare AB) with those of pressable lithium-disilicate glass ceramic (IPS e.max Press, Ivoclar Vivadent). No fractures of the frameworks were reported. No

fractures of the single lithium disilicate full-contour crowns, requiring the replacement of the dental units, were reported. The clinical implications of this proof-of-concept study are the providing of a novel treatment option that could improve the clinical performance and reliability of zirconia-based restorations, thus minimizing their mechanical drawbacks. The mechanical and biological properties of Y-TZP, combined with an accurate clinical and laboratory protocol and the state-of-the-art CAD/CAM fabrication procedure, allowed for the production of large and complex restorations with high accuracy and success rates, broadening the application of all ceramic restorations. The flexural strength and fracture toughness of lithium disilicate and of zirconium dioxide are merged throughout the bonding of the single lithium disilicate crowns onto the zirconia surface, preventing the occurrence of fractures of the veneering material and of the framework over the medium-term period and ensuring at the same time high patient esthetic and functional acceptance. Furthermore, the significantly lower specific gravity of Y-TZP, compared with Co-Cr-Mo alloy, palladium, gold, and silver (6.1 vs 8.2, 12.02, 19.3 or 21.45  $\text{g}/\text{cm}^3$ , respectively), ensures the fabrication of light-weight prosthetic frameworks. When the interarch distance is moderately increased, and the vestibulum depth is adequate, it is reliable to deliver a fixed complete-arch implant-bridge, with longer prosthetic crowns or pink ceramic, to compensate for the vertical discrepancy. Hence, the lower weight of the  $\text{ZrO}_2$ , compared with the MCRs, contributes to reducing the gravity-induced loading stress, especially when a large-volume restoration is needed or when a protocol with a reduced number of implants is adopted to rehabilitate an edentulous maxilla. Furthermore, the potential lack of accuracy and fit of the metal casting procedure can be overcome by CAD/CAM milling fabrication of these large-volume frameworks. Although only fully edentulous patients were treated, the conclusions of the present proof-of-concept study can also be extended to partially edentulous patients.

Although no crown fractures were experienced in this study, the capability to remove the fractured crown and repair it immediately, directly in the patient mouth, underlines the flexibility of this restorative concept, assuring that a rapid and comfortable repairing procedure can contribute to the long-term success of implant-supported restorations.

## CONCLUSIONS

Within the limitations of the present exploratory study, single monolithic lithium disilicate full-contour crowns bonded on CAD/CAM screw-retained implant-supported zirconium dioxide complete-arch frameworks showed favorable preliminary outcomes. However, wider application of this technique for longer follow-up durations is required for further conclusive recommendations.

## ABBREVIATIONS

BoP: bleeding on probing

CAD/CAM: computer-aided design/computer-aided manufacturing

CBCT: cone-beam computerized tomography



CDA: California Dental Association  
 FPD: fixed partial denture  
 GI: gingival index  
 MCR: metal-ceramic restoration  
 PFZ: porcelain-fused-to-zirconia  
 PS: plaque score  
 VAS: visual analog scale  
 Y-TZP: yttria-stabilized tetragonal zirconia polycrystal

## REFERENCES

- Dolan TA, Lauer DS. Delphi study to identify core competencies in geriatric dentistry. *Spec Care Dentist*. 2001;21:191–197.
- Branemark PI, Hansson BO, Adell R, et al. Osseointegrated implants in the treatment of the edentulous jaw. Experience from a 10-year period. *Scand J Plast Reconstr Surg Suppl*. 1977;16:1–132.
- Sailer I, Pjetursson BE, Zwahlen M, Hämmerle CHF. A systematic review of the survival and complication rates of all-ceramic and metal-ceramic reconstructions after an observation period of at least 3 years. Part II: fixed dental prostheses. *Clin Oral Implants Res*. 2007;18:86–96.
- Raigrodski AJ, Chiche GJ, Swift EJ. All-ceramic fixed partial dentures, Part III: clinical studies. *J Esthet Restor Dent*. 2002;14:313–319.
- Heintze SD, Rousson V. Survival of zirconia- and metal-supported fixed dental prostheses: a systematic review. *Int J Prosthodont*. 2010;23:493–502.
- Pozzi A, Holst S, Fabbri G, Tallarico M. Clinical reliability of CAD/CAM cross-arch zirconia bridges on immediately loaded implants placed with computer-assisted/template-guided surgery: a retrospective study with a follow-up between 3 and 5 years. *Clinic Implant Dent Relat Res*. 2015;17(suppl 1):e86–e96.
- Pjetursson BE, Sailer I, Zwahlen M, Hämmerle CHF. A systematic review of the survival and complication rates of all-ceramic and metal-ceramic reconstructions after an observation period of at least 3 years. Part I: single crowns. *Clinic Oral Implants Res*. 2007;18:73–85.
- Goodacre CJ, Bernal G, Rungcharassaeng K, Kan JYK. Clinical complications in fixed prosthodontics. *J Prosthet Dent*. 2003;90:31–41.
- Esquivel-Upshaw JF, Anusavice KJ, Young H, Jones J, Gibbs C. Clinical performance of a lithium disilicate-based core ceramic for three-unit posterior FPDs. *Int J Prosthodont*. 2004;17:469–475.
- Uo M, Sjogren G, Sundh A, Watari F, Bergman M, Lerner U. Cytotoxicity and bonding property of dental ceramics. *Dent Mater*. 2003;19:487–492.
- Piconi C, Maccauro G. Zirconia as a ceramic biomaterial. *Biomaterials*. 1999;20:1–25.
- Scarano A, Piattelli M, Caputi S, Favero GA, Piattelli A. Bacterial adhesion on commercially pure titanium and zirconium oxide disks: an in vivo human study. *J Periodontol*. 2004;75:292–296.
- Chai J, Chu FCS, Chow TW, Liang BMH. Chemical solubility and flexural strength of zirconia-based ceramics. *Int J Prosthodont*. 2007;20:587–595.
- Jung RE, Holderegger C, Sailer I, Khraisat A, Suter A, Hämmerle CHF. The effect of all-ceramic and porcelain-fused-to-metal restorations on marginal peri-implant soft tissue color: a randomized controlled clinical trial. *Int J Periodontics Restorative Dent*. 2008;28:357–365.
- Papaspyridakos P, Lal K. Immediate loading of the maxilla with prefabricated interim prosthesis using interactive planning software, and CAD/CAM rehabilitation with definitive zirconia prosthesis: 2-year clinical follow-up. *J Esthet Restor Dent*. 2010;22:223–232.
- Guess PC, Att W, Strub JR. Zirconia in fixed implant prosthodontics. *Clinic Implant Dent Relat Res*. 2012;14:633–645.
- Guess PC, Zavanelli RA, Silva NRFA, Bonfante EA, Coelho PG, Thompson VP. Monolithic CAD/CAM lithium disilicate versus veneered Y-TZP crowns: comparison of failure modes and reliability after fatigue. *Int J Prosthodont*. 2010;23:434–442.
- Abrahamsson I, Berglundh T, Glantz PO, Lindhe J. The mucosal attachment at different abutments. An experimental study in dogs. *J Clin Periodontol*. 1998;25:721–727.
- Glauser R, Sailer I, Wohlwend A, Studer S, Schibli M, Scharer P. Experimental zirconia abutments for implant-supported single-tooth restorations in esthetically demanding regions: 4-year results of a prospective clinical study. *Int J Prosthodont*. 2004;17:285–290.
- Papaspyridakos P, Lal K. Computer-assisted design/computer-assisted manufacturing zirconia implant fixed complete prostheses: clinical results and technical complications up to 4 years of function. *Clinic Oral Implants Res*. 2013;24:659–665.
- Raigrodski AJ, Hillstead MB, Meng GK, Chung KH. Survival and complications of zirconia-based fixed dental prostheses: a systematic review. *J Prosthet Dent*. 2012;107:170–177.
- Pjetursson BE, Brägger U, Lang NP, Zwahlen M. Comparison of survival and complication rates of tooth-supported fixed dental prostheses (FDPs) and implant-supported FDPs and single crowns (SCs). *Clin Oral Implants Res*. 2007;18:97–113.
- Augstin-Panadero R, Fons-Font A, Roman-Rodriguez JL, Granell-Ruiz M, del Rio J, Sola-Ruiz MF. Zirconia versus metal: a preliminary comparative analysis of ceramic veneer behavior. *Int J Prosthodont*. 2012;25:294–300.
- Marquardt P, Strub JR. Survival rates of IPS Empress 2 all-ceramic crowns and fixed partial dentures: results of a 5-year prospective clinical study. *Quintessence Int*. 2006;37:253–259.
- Solá-Ruiz MF, Lagos-Flores E, Roman-Rodriguez JL, Highsmith JDR, Fons-Font A, Granell-Ruiz M. Survival rates of a lithium disilicate-based core ceramic for three-unit esthetic fixed partial dentures: a 10-year prospective study. *Int J Prosthodont*. 2013;26:175–180.
- Wolfart S, Eschbach S, Scherrer S, Kern M. Clinical outcome of three-unit lithium-disilicate glass-ceramic fixed dental prostheses: up to 8 years results. *Dent Mater*. 2009;25:e63–e71.
- Makarouna M, Ullmann K, Lazarek K, Boening KW. Six-year clinical performance of lithium disilicate fixed partial dentures. *Int J Prosthodont*. 2011;24:204–209.
- Oh SC, Dong JK, Luthy H, Scharer P. Strength and microstructure of IPS Empress 2 glass-ceramic after different treatments. *Int J Prosthodont*. 2000;13:468–472.
- Albakry M, Guazzato M, Swain MV. Biaxial flexural strength and microstructure changes of two recycled pressable glass ceramics. *J Prosthodont*. 2004;13:141–149.
- Tysowsky GW. The science behind lithium disilicate: a metal-free alternative. *Dent Today*. 2009;28:112–113.
- Holand W, Schweiger M, Frank M, Rheinberger V. A comparison of the microstructure and properties of the IPS Empress 2 and the IPS Empress glass-ceramics. *J Biomed Mater Res*. 2000;53:297–303.
- Cattell MJ, Palumbo RP, Knowles JC, Clarke RL, Samarawickrama DYD. The effect of veneering and heat treatment on the flexural strength of Empress 2 ceramics. *J Dent*. 2002;30:161–169.
- Gehrt M, Wolfart S, Rafai N, Reich S, Edelhoff D. Clinical results of lithium-disilicate crowns after up to 9 years of service. *Clin Oral Investig*. 2012;17:275–284.
- Malò P, de Araújo Nobre M, Borges J, Almeida R. Retrievable metal ceramic implant-supported fixed prostheses with milled titanium frameworks and all-ceramic crowns: retrospective clinical study with up to 10 years of follow-up. *J Prosthodont*. 2012;21:256–264.
- Elm von E, Altman DG, Egger M, Pocock SJ, Gotsche PC, Vandenbroucke JP. The Strengthening of Reporting of Observational Studies in Epidemiology (STROBE) statement: guidelines for reporting observational studies [in Spanish]. *Rev Esp Salud Publica*. 2008;82:251–259.
- van Steenberghe D, Glauser R, Blomback U, et al. A computed tomographic scan-derived customized surgical template and fixed prosthesis for flapless surgery and immediate loading of implants in fully edentulous maxillae: a prospective multicenter study. *Clin Implant Dent Relat Res*. 2005;7(suppl 1):S111–S120.
- Naylor CK. Fabrication of a custom anterior guide table. *J Prosthet Dent*. 1979;42:466–469.
- Abduo J, Lyons K, Bennani V, Waddell N, Swain M. Fit of screw-retained fixed implant frameworks fabricated by different methods: a systematic review. *Int J Prosthodont*. 2011;24:207–220.
- van Steenberghe D. Outcomes and their measurement in clinical trials of endosseous oral implants. *Ann Periodontol*. 1997;2:291–298.
- Association CD. *Quality Evaluation for Dental Care: Guidelines for the Assessment of Clinical Quality and Professional Performance and the Standards for the Program Design to Assure the Quality of Care*. Los Angeles: California Dental Association; 1976.
- Mombelli A, Lang NP. The diagnosis and treatment of peri-implantitis. *Periodontol*. 1998;17:63–76.
- Jung RE, Pjetursson BE, Glauser R, Zembic A, Zwahlen M, Lang NP. A



systematic review of the 5-year survival and complication rates of implant-supported single crowns. *Clin Oral Implants Res.* 2008;19:119–130.

43. Sailer I, Zembic A, Jung RE, Siegenthaler D, Holderegger C, Hämmerle CHF. Randomized controlled clinical trial of customized zirconia and titanium implant abutments for canine and posterior single-tooth implant reconstructions: preliminary results at 1 year of function. *Clin Oral Implants Res.* 2009;20:219–225.

44. Kassem AS, Atta O, El-Mowafy O. Survival rates of porcelain molar crowns—an update. *Int J Prosthodont.* 2010;23:60–62.

45. Rinke S, Ziebolz D. Fabrication of an implant-supported overdenture using CAD/CAM technology: a clinical report. *Quintessence Int.* 2013;44:127–134.

46. Larsson C, Vult von Steyern P, Nilner K. A prospective study of implant-supported full-arch yttria-stabilized tetragonal zirconia polycrystal mandibular fixed dental prostheses: three-year results. *Int J Prosthodont.* 2010;23:364–369.

47. Larsson C, Madhoun SE, Wennerberg A, Vult von Steyern P. Fracture strength of yttria-stabilized tetragonal zirconia polycrystals crowns with different design: an in vitro study. *Clin Oral Implants Res.* 2012 2;23:820–826.

48. Zhang Y, Lawn BR, Rekow ED, Thompson VP. Effect of sandblasting on the long-term performance of dental ceramics. *J Biomed Mater Res B Appl Biomater.* 2004;71:381–386.

49. Sato H, Yamada K, Pezzotti G, Nawa M, Ban S. Mechanical properties of dental zirconia ceramics changed with sandblasting and heat treatment. *Dent Mater J.* 2008;27:408–414.

50. Nakamura T, Wakabayashi K, Zaima C, Nishida H, Kinuta S, Yatani H. Tensile bond strength between tooth-colored porcelain and sandblasted zirconia framework. *J Prosthodont Res.* 2009;53:116–119.

51. Isgro G, Pallav P, van der Zel JM, Feilzer AJ. The influence of the veneering porcelain and different surface treatments on the biaxial flexural strength of a heat-pressed ceramic. *J Prosthet Dent.* 2003;90:465–473.

52. Al-Dohan HM, Yaman P, Dennison JB, Razzoog ME, Lang BR. Shear strength of core-veneer interface in bi-layered ceramics. *J Prosthet Dent.* 2004;91:349–355.

53. Papaspyridakos P, Chen CJ, Chuang SK, Weber HP, Gallucci GO. A systematic review of biologic and technical complications with fixed implant rehabilitations for edentulous patients. *Int J Oral Maxillofac Implants.* 2012; 27:102–110.