

# Dental Implants in Oral Rehabilitation of A Maxillary Cancer Reconstruction: A Case Report

Tomoki Sumida, DDS, PhD<sup>1,2\*</sup>  
 Hiroyuki Nakano, DDS, PhD<sup>1</sup>  
 Hiroyuki Hamakawa, DDS, PhD<sup>2</sup>  
 Yoshihide Mori, DDS, PhD<sup>1</sup>

## INTRODUCTION

The treatment of patients with oral cancer usually involves surgery, radiotherapy, and/or chemotherapy.<sup>1</sup> Various complications can develop after oral cancer resection, particularly if a major maxillectomy was performed. Maxillary resection sometimes results in oroantral communication, which leads to difficulties in speech and swallowing. Pterygoid and zygomatic implants were reported to be useful in these cases.<sup>2,3</sup> Dentures can be constructed in edentulous cases involving reconstruction of large defects using thick flaps; however, this is not always effective. Thus, resection of the maxilla often leads to damage that affects not only mastication, but also speech and swallowing; as a result, the patient's quality of life (QOL) invariably declines.<sup>4</sup>

This report discusses the application of implant dentistry for the oral rehabilitation of an oral cancer patient who underwent a hemimaxillary resection, reconstruction with a microvascular free abdominal flap (FAF), and radiotherapy. Maxillary reconstruction with a thick FAF is a method used to close the space between the oral cavity and the maxillary sinus.<sup>5</sup> However, thick flaps disrupt oral functions, particularly occlusion. If there is enough remaining alveolar bone for implant insertion, implant-retaining treatment may be able to restore occlusion. This case report describes a successful oral reconstruction via the implementation of an implant-supported prosthesis for a large maxillary defect after reconstruction with a FAF.

## CASE REPORT

A 67-year-old male patient presented at our hospital with the chief complaint of dysfunctional occlusion. He had cancer of the right maxilla and underwent preoperative radiotherapy and chemotherapy in another hospital. After the radiotherapy, a hemimaxillectomy and a FAF graft were performed. There were no serious complications following the surgery. However, treatment with a denture was impossible because of the thick

flap and lack of residual teeth, and the patient was thus able to eat only soft foods.

The condition of the patient at the first visit, 2 years after surgery, is shown in Figures 1 and 2. The panoramic radiograph before implantation revealed that the sinus floor was low on the left side, corresponding to the upper molar region (Figure 3). The bone height from sinus floor to alveolar ridge was less than 5 mm. Therefore, sinus floor elevation was performed via the lateral window technique, using autologous bone from the mental region. After 6 months, 12–14 mm of bone height was confirmed by panoramic radiograph. A total of 5 MkIII implants (Brånemark System) were inserted into the left maxilla, each with a diameter of 4.0 mm and with lengths of 12 mm (1 implant) and 10 mm (4 implants; Figures 4 and 5). Six months after the insertion of the implants, a second operation was performed, and good osseointegration of the implants was achieved. The prosthetic procedure was then performed. Because of the angle of the insertion of the implants, a multi-unit system (Brånemark System) was used. After the multi-unit abutments were set, the temporary prostheses were adjusted to the patient's satisfaction with regard to occlusion and the shape of the prostheses. After adjustment of the temporary prostheses, the final hybrid prostheses lined with metal were set with retaining screws.

Using standard procedures, the final prosthesis was set in the oral cavity. The final prosthesis was elongated to the canine on the right side, for esthetic reasons (Figure 6). Masticatory function improved after implant treatment, and the patient was able to eat a normal diet and chew on the left side. However, the right anterior teeth were not in contact with the lower teeth (Figure 7). Maximum bite force improved dramatically after the implantation increased to within the normal range, as did masticatory function as measured by xylitol gum (Figures 8 and 9). The patient was able to eat a normal diet, and he was satisfied with the outcome. There were no serious problems for more than 5 years. It was, however, very difficult for the patient to clean the area around the abutment; therefore, follow-up was required every 3 months for cleaning.

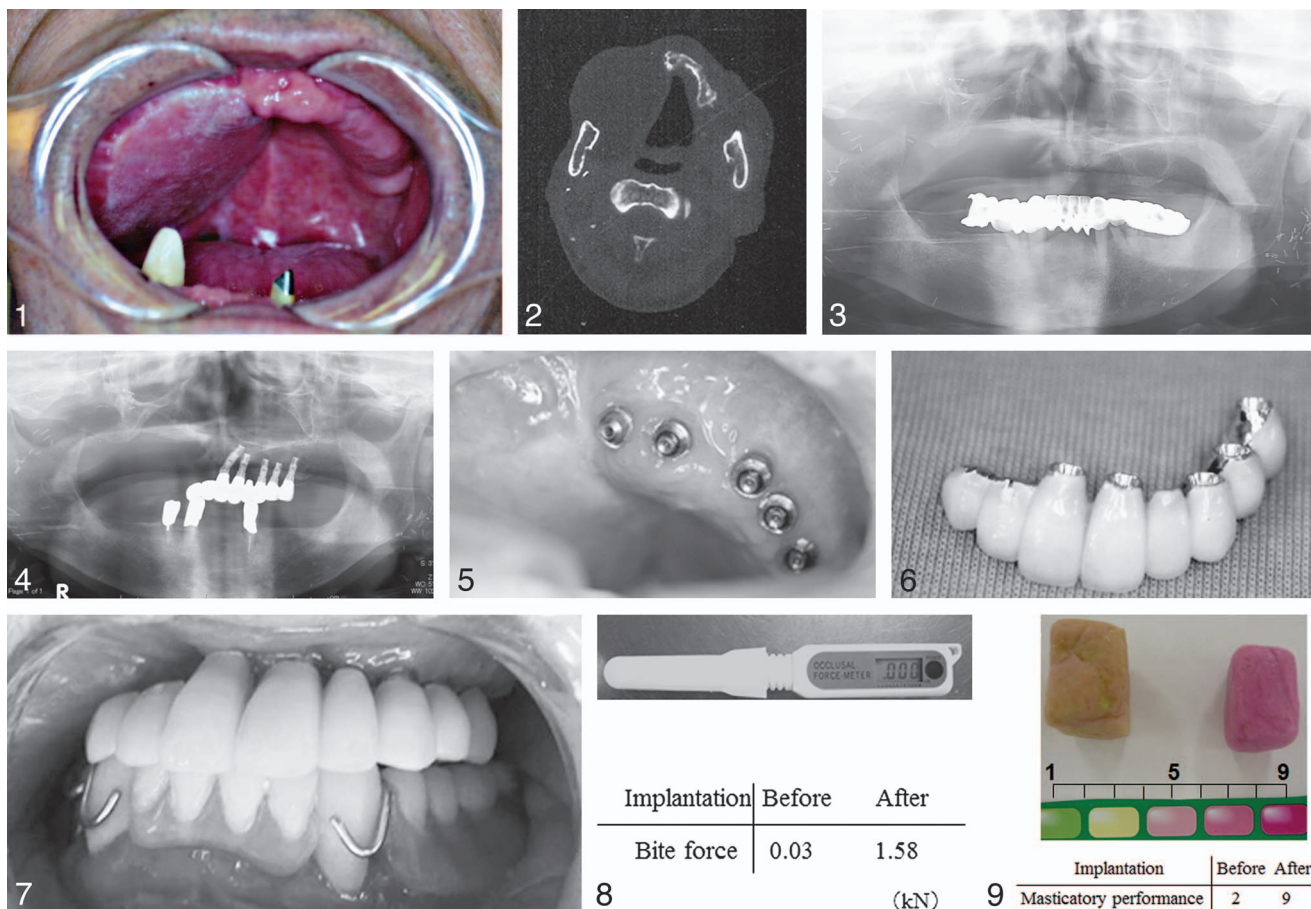
## DISCUSSION

After a minor maxillectomy, the defect is usually covered by an obturator prosthesis. In such cases, this type of prosthesis is usually sufficient for helping the patient with activities such as

<sup>1</sup> Division of Oral and Maxillofacial Surgery, Department of Maxillofacial Diagnostic and Surgical Sciences, Kyushu University School of Dentistry, Fukuoka, Japan.

<sup>2</sup> Department of Oral and Maxillofacial Surgery, Ehime University Graduate School of Medicine, Ehime, Japan.

\* Corresponding author, e-mail: tomoki@dent.kyushu-u.ac.jp  
 DOI: 10.1563/AAID-JOI-D-13-00136



**FIGURES 1–9.** **FIGURE 1.** A 67-year-old male patient with carcinoma of the maxilla underwent preoperative radiotherapy and chemotherapy. Intraoral findings at the first visit. **FIGURE 2.** A right partial maxillectomy and rectus abdominis myocutaneous flap graft were performed. **FIGURE 3.** The panoramic view before implantation. **FIGURE 4.** Two years after surgery, 5 implants were inserted into the remnant maxilla with sinus floor elevation. **FIGURE 5.** After the tumor surgery, placement of a denture was not possible. The patient deemed the final prosthesis satisfactory. This figure shows the upper prostheses. **FIGURE 6.** Masticatory function improved after implant treatment, and the patient was able to eat a normal diet and chew on the left side. **FIGURES 7.** After implant treatment, both masticatory performance and maximum bite force improved drastically. **FIGURE 8.** The bite force increased to within the normal range. **FIGURE 9.** Masticatory performance as measured by xylitol gum indicated that the patient’s bite force was restored to a satisfactory level after implant treatment.

eating and speaking, even if the defect resulted in orotracheal communication.

If the defect cannot be obturated using a conventional obturator prosthesis, the use of an implant support obturator prosthesis is a very useful treatment approach. Thus, a large proportion of patients with maxillary cancer use an obturator prosthesis supported by implants. Moreover, obturator prostheses are easy to maintain and are associated with a favorable prognosis with regard to the implants.<sup>6</sup> Obturation, local or locoregional flaps, and soft-tissue free flaps are good options for maxillary reconstruction; however, the lack of bone reconstruction often leads to difficulties in occlusal reconstruction, because osseous implants cannot be used for dental rehabilitation.<sup>7</sup> Implant therapy using reconstructed bone with skin flaps greatly increases patient QOL.<sup>8</sup> However, the problem of reversal of the implant: crown ratio due to the thickness of the soft tissue and the thinness of the bone remains,<sup>9</sup> and this problem was observed in the case reported herein.

Another maxillary cancer patient underwent total maxillectomy and reconstruction using the fibula and flaps. In such

cases, an implant-supported obturator prosthesis is difficult to stabilize because of the soft, thick flaps. Therefore, the placement of implants into the residual zygomatic bone is sometimes chosen and used to set the screw-retained obturator prosthesis.

Based on such experiences, a decision was taken to treat the patient in the present case by inserting 5 implants, all on the left side. Fortunately, esthetic considerations were not of great importance to this patient, and he was satisfied with the occlusal reconstruction of the dentulous remains.

After placement of the dental implant, this patient was very satisfied because he had regained the ability to masticate. However, some problems remained; for example, it was difficult for the patient to perform self-maintenance of the implant because it is a long-span, 1-piece bridge. However, daily self-cleaning is necessary. Therefore, the upper structure of the prosthesis must be changed to a more hygienic one before bone loss occurs. Compared with our routine work, it was extremely rewarding to help this patient return to a normal life.

Even in a patient who had undergone a hemimaxillectomy, the restoration of function using dental implants was quite useful.

#### ABBREVIATIONS

FAF: free abdominal flap  
QOL: quality of life

#### ACKNOWLEDGMENT

This work was supported by a Grant for Scientific Research from the Amada Foundation, awarded to T. Sumida.

#### REFERENCES

1. Deng H, Sambrook PJ, Logan RM. The treatment of oral cancer: an overview for dental professionals. *Aust Dent J*. 2011;56:244–252.
2. Bidra AS, May GW, Tharp GE, Chambers MS. Pterygoid implants for

maxillofacial rehabilitation of a patient with a bilateral maxillectomy defect. *J Oral Implantol*. 2013;39:91–97.

3. D'Agostino A, Procacci P, Ferrari F, Trevisiol L, Nocini PF. Zygoma implant-supported prosthetic rehabilitation of a patient after subtotal bilateral maxillectomy. *J Craniofac Surg*. 2013;24:e159–e162.

4. Lin PY, Lin KC, Jeng SF. Oromandibular reconstruction: the history, operative options and strategies, and our experience. *ISRN Surg*. 2011;2011:824251.

5. Baker SR. Closure of large orbital-maxillary defects with free latissimus dorsi myocutaneous flaps. *Head Neck Surg*. 1984;6:828–835.

6. Korfage A, Schoen PJ, Raghoobar GM, et al. Five-year follow-up of oral functioning and quality of life in patients with oral cancer with implant-retained mandibular overdentures. *Head Neck*. 2011;33:831–839.

7. Bianchi B, Ferri A, Ferrari S, Copelli C, Boni P, Sesenna E. Iliac crest free flap for maxillary reconstruction. *J Oral Maxillofac Surg*. 2010;68:2706–2713.

8. Bodard AG, Bémer J, Gourmet R, Lucas R, Coroller J, Salino S, Breton P. Dental implants and free fibula flap: 23 patients. *Rev Stomatol Chir Maxillofac*. 2011;112:e1–e4.

9. Anne-Gaëlle B, Samuel S, Julie B, Renaud L, Pierre B. Dental implant placement after mandibular reconstruction by microvascular free fibula flap: current knowledge and remaining questions. *Oral Oncol*. 2011;47:1099–1104.