

One-Year Prospective Study of 7-mm-Long Implants in the Mandible: Installation Technique and Crown/Implant Ratio of 1.5 or Less

Young-Kyun Kim, DDS, PhD^{1,2*}

Pil-Young Yun, DDS, PhD¹

Yang-Jin Yi, DDS, PhD^{2,3}

Ji-Hyun Bae, DDS, PhD⁴

Sung-Beom Kim, DDS¹

Gyo-Jin Ahn, DDS¹

This study prospectively evaluated the clinical prognoses of short implants (7-mm long) in the mandible. We investigated the clinical prognosis of short implants in 20 patients (46 implants) according to the installation technique (submerged or nonsubmerged), installation depth (5.5-mm depth, 7-mm depth), and crown/implant ratio. We investigated the marginal bone loss and peri-implant soft-tissue index 12 months after the final prosthetic delivery. Twelve months after prosthetic delivery, no statistically significant differences were observed in bone loss in relation to the type of installation technique, installation depth, or crown/implant ratio. The plaque index and pocket depth indexes were not influenced by the installation technique, installation depth, or crown/implant ratio. We observed marginal bone loss of 3.3 mm in 1 implant from the nonsubmerged group. The total 1-year success rate was 97.83%. Based on this 1-year success rate, short implants had a good clinical prognosis, regardless of the installation technique, installation depth, or crown/implant ratio.

Key Words: *implant, mandible, prognosis, short*

INTRODUCTION

The severe loss of alveolar bone associated with long-term tooth loss often limits the placement of long implants and warrants the placement of short implants.¹ The advantages of short implants are as follows:

1. The avoidance of invasive surgery, such as ridge augmentation in the posterior quadrants
2. Minimized overheating during drilling
3. Minimized potential invasion of the inferior alveolar canal in the mandible
4. Prevention of root damage in cases involving root curvatures of adjacent teeth
5. Prevention of bony perforation in the presence of an undercut or concavity

6. Clinical simplification for the surgeon due to decreased armamentarium needs, operation times, and need for bone graft materials

Recently, the prognosis of short implants has improved because of surface treatment and design modifications. Many studies have shown stable results with short implants, especially in the mandible.²⁻⁵ Short implants, however, have a higher failure rate in the maxilla than in the mandible because of the lower density of the bone in the maxilla.⁶⁻⁸ For the placement of short implants, a 2-stage submerged placement procedure is usually performed.⁹ The average healing period is 6 months for the maxilla and 3 months for the mandible. After the healing period of 6 months in the maxilla, a second surgery is performed before the maxillary prosthetic restoration can be completed. In the case of the mandible, implant placement is performed using a 1-stage, nonsubmerged method due to the dense alveolar bone and solid early fixation. In this case, a 2- to 3-month healing period is involved before the prosthetic restoration can be performed. Previous studies have reported the success rate of short implants in relation to the 1-stage or 2-stage techniques.^{9,10} Gentile et al⁹ found that 2-stage placement afforded higher success rates when short implants are placed. However, Sun et al¹⁰ reported no differences with regard to implant failure between 1-stage and 2-stage placements.

This study was performed to evaluate the 1-year clinical prognosis of short implants in the mandible according to

¹ Department of Oral and Maxillofacial Surgery, Seoul National University Bundang Hospital, Gyeonggi-do, Korea.

² Department of Dentistry and Dental Research Institute, School of Dentistry, Seoul National University, Gyeonggi-do, Korea.

³ Department of Prosthodontics, Seoul National University Bundang Hospital, Gyeonggi-do, Korea.

⁴ Department of Conservative Dentistry, Section of Dentistry, Seoul National University Bundang Hospital, Gyeonggi-do, Korea.

* Corresponding author, e-mail: kyk0505@snuh.org

DOI: 10.1563/AAID-JOI-D-13-00162

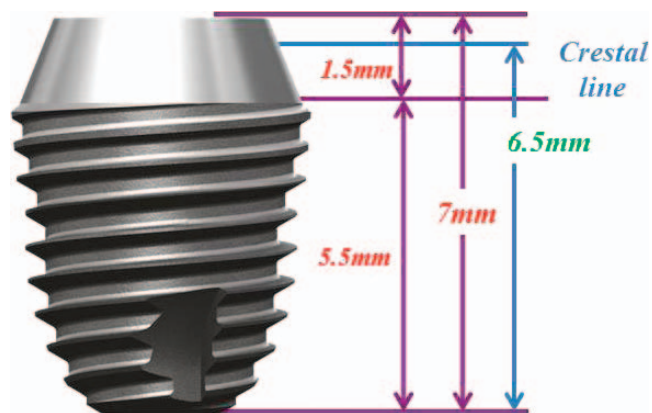


FIGURE 1. A Superline short implant of 7 mm in length.

implant installation depth (5.5 mm or 7 mm), techniques (submerged or nonsubmerged), and crown/implant (CI) ratio.

MATERIALS AND METHODS

In this study, short implants of 7 mm in length were placed in the posterior mandible where 2 adjacent teeth were lost. Implant surgery was performed at the Department of Oral and Maxillofacial Surgery, Dental Clinic, Seoul National University Bundang Hospital, from July to December 2011. One year after the final prosthetic restoration, a prospective clinical study was conducted to assess the installation technique (1-stage and 2-stage methods), CI ratio, and prognosis according to implant length. We have read the Helsinki Declaration and followed its guidelines in this investigation. The following were the inclusion and exclusion criteria for the patients involved in this study, all of whom were approved by Seoul National University Bundang Hospital's Institutional Review Board (E-1106-063-002):

Inclusion criteria

1. Age ≥ 18 years with complete jaw development
2. Good general health or controlled medical disease
3. Loss of adjacent 2 teeth in the mandibular premolar and molar areas

4. A minimum width of 6 mm for the buccolingual alveolar bone
5. A minimum available bone height of 7 mm
6. Occluding teeth (ie, opposite arch)
7. Absence of temporomandibular joint disorders or unstable occlusion
8. Confirmed motivation regarding implant treatment
9. Consent to participate in the clinical trials, with signed informed consent

Exclusion criteria

1. Pregnancy
2. Uncontrolled medical disease
3. Psychological disease or suspected psychological disorder
4. Severe periodontal disease
5. D4 bone quality
6. Cases requiring major bone grafting
7. Cases with an insertion torque of less than 30 N-cm
8. Previous ineligibility to participate in a clinical trial for ethical reasons or due to factors that may affect the results of the clinical trial
9. Other problems that make implant surgery difficult, such as bruxism or insufficient space for a prosthesis

Through this selection process, a total of 24 patients were included as study subjects, all of whom signed the agreement. However, 4 patients withdrew their consent, resulting in a final total of 20 patients.

Implant placement and prosthetic treatment

For the implant placement, 7-mm-long Superline (Dentium, Suwon, Korea) implants were selected. These implants had a tapered design, with the appropriate micro-crater and micro-pit on the surface and sand-blasted large grit and acid-etched surface treatment for excellent osseointegration capacity. The lengths of the collar and fixture thread were 1.5 mm and 5.5 mm, respectively. Implants with diameters of 4.5, 5.0, and 6.0 mm were selected according to the width of the alveolar ridge. For the length of placement, 7-mm full-length placement and 5.5-mm depth placement were selected according to the residual bone height (Figures 1 and 2).

The subjects were divided into 2 groups according to the

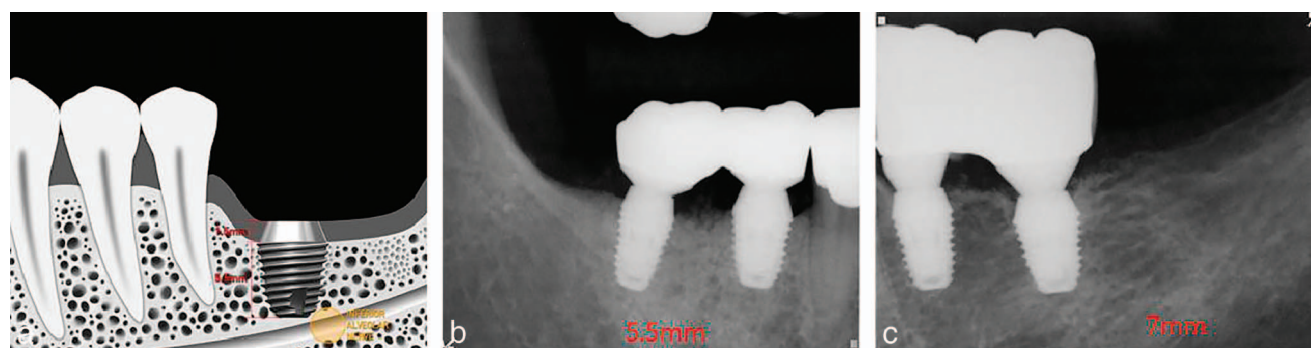

FIGURE 2. Two types of installation depths are available. (a) The height of the smooth surface collar is 1.5 mm. The length of the rough surface fixture is 5.5 mm. (b) For the 5.5-mm depth placement, the entire collar was exposed above the alveolar crest. (c) For the 7-mm full-length placement, the top of the collar coincided with the alveolar crest.

placement method and allocated randomly by the research dental hygienist as follows:

Group 1: Two-stage, submerged placement. After implant placement, a cover screw was connected, and the area was closed via suture. After 8 weeks of healing, the implant was exposed through a second surgical procedure, after which an impression was taken and a healing abutment connected. The final prosthesis was delivered 3 months later by splinting the 2 implants.

Group 2: One-stage, nonsubmerged placement. After implant placement, a healing abutment was connected and the area was closed via suture. Ten weeks later, an impression was taken without a second surgical procedure. The final prosthesis was delivered 3 months later by splinting the 2 implants.

All patients who underwent surgery took antibiotics (cephalosporin, Mesexin, Hanlim Pharm, Seoul, Korea) and a nonsteroidal anti-inflammatory drug (aclofenac, Reumel, Hanlim Pharm Co, Ltd, Seoul, Korea) starting from 1 day before surgery until 5 days after surgery. They were asked to gargle with 0.1% chlorhexidine solution (Hexamedine, Bukwang Pharm Co, Ltd, Seoul, Korea) right before surgery and were instructed to gargle 3 times a day for 5 days after surgery. The suture was removed 7 to 10 days after surgery. Primary stability was measured immediately after implant placement using an Osstell Mentor (Integration Diagnostics AB, Göteborg, Sweden), while secondary stability was measured during the second surgery or at the time of the first impression. The final prosthesis was delivered 3 months after implant placement, after which the patients' progress was monitored every 3 months. The peri-implant soft-tissue condition and marginal bone loss were measured 1 year after the installation of the final prosthesis. The implant success rate was based on the last visit to the hospital by the patient.

Implant success criteria

The implant success criteria¹¹ were as follows:

- Absence of continuous or irreversible pain, discomfort, and/or paresthesia
- Absence of recurring peri-implantitis with abscess
- Absence of mobility
- Absence of radiolucent lesion(s) around the implant
- Marginal bone loss of less than 1 mm in the first year

Gingival index

The following scale was used to determine the gingival index¹²:

- 0: Normal gingiva
- 1: Mild inflammation: slight change in color and slight edema, with no bleeding on probing
- 2: Moderate inflammation: redness, edema, and glazing, with bleeding on probing
- 3: Severe inflammation: marked redness and edema, ulceration, with tendency toward spontaneous bleeding

Plaque index

The following scale was used to determine the plaque index (PI)¹²:

- 0: No plaque in the gingival area

- 1: Film of plaque adhering to the free gingiva and the adjacent area of the tooth; the plaque may be recognized only by running a probe across the tooth surface
- 2: Moderate accumulation of soft deposits within the gingival pocket, on the gingival margin, or on an adjacent tooth surface, which can be seen by the naked eye
- 3: Abundance of soft matter within the gingival pocket or on the gingival margin and adjacent tooth surface

Pocket depth

The average value was measured after the measurement of the periodontal pocket depth on the buccal, lingual, distal, and mesial surfaces of the implant.

Width of keratinized mucosa¹³

The distance between the rim of the gingiva of the placed implant and the border of the alveolar mucosa and the attached gingiva was measured using a periodontal probe. The border area of the gingival mucosa was distinguished by colors because the keratinized gingiva is pale pink and the alveolar mucosa is dark red. The measurement method involved pulling the lips and buccal mucosa and measuring the distance between the border area of the gingival mucosa, which was recognized by the shades, and the border of gingiva meeting the teeth.

Measurement of marginal bone loss

To measure and compare marginal bone resorption around the implant, digital periapical radiographs were taken vertically from the longitudinal axis using the parallel cone technique. The marginal bone level was measured on the mesial and distal sides of the implant, and the mean of the 2 values was regarded as a representative value. The distance from the implant platform to the first bone-to-implant contact in radiographs was measured and expressed as the enlargement ratio. Marginal bone loss was calculated as the difference between values taken at the initial day of loading and values taken at 1 year of prosthetic loading. The difference was measured by setting 2 dots on the radiograph using the IMPAX (Agfa Corp, Mortsel, Belgium) program to measure the distance. The measurement was conducted by 2 dentists who did not participate in the implant treatment.

CI ratio

The CI ratio was calculated after measuring the crown length and the implant fixture in their centers in relation to the long axis of the implant. The group that had a CI ratio of <1.5 was compared with the group that had a CI ratio of ≥ 1.5 .

Statistics

Depending on the placement method, placement depth, and CI ratio, the subjects were divided as follows: group 1 (submerged) and group 2 (nonsubmerged), a 5.5-mm group and a 7-mm group, and a <1.5 group and a ≥ 1.5 group. The marginal bone loss measurements made by the 2 residents were verified statistically. An independent *t* test or the Mann-Whitney *U* test was used for the comparison of the groups divided according to peri-implant index and marginal bone loss. The univariate

TABLE 1
Summary of cases*

| Case | Age | Gender | Site | 1- or 2-Stage | Depth, mm | CI Ratio | Prognosis |
|------|-----|--------|------|------------------|--------------|-------------|-----------|
| S1 | 65 | Female | 29 | 2 | 7 | ≥1.5 | S |
| | | | 30 | 2 | 7 | ≥1.5 | S |
| | | | 20 | 2 | 7 | ≥1.5 | S |
| S2 | 61 | Female | 19 | 2 | 5.5 | ≥1.5 | S |
| | | | 30 | 2 | 5.5 | <1.5 | S |
| S3 | 74 | Male | 31 | 2 | 5.5 | <1.5 | S |
| | | | 20 | 2 | 5.5 | ≥1.5 | S |
| S4 | 71 | Female | 19 | 2 | 5.5 | ≥1.5 | F |
| | | | 30 | 2 | 5.5 | ≥1.5 | S |
| S5 | 41 | Female | 31 | 2 | 5.5 | ≥1.5 | S |
| | | | 19 | 2 | 7 | ≥1.5 | S |
| S6 | 46 | Female | 18 | 2 | 7 | <1.5 | S |
| | | | 19 | 2 | 7 | <1.5 | S |
| S7 | 77 | Male | 18 | 2 | 5.5 | <1.5 | S |
| | | | 30 | 2 | 5.5 | ≥1.5 | S |
| S8 | 60 | Male | 31 | 2 | 5.5 | <1.5 | S |
| | | | 30 | 2 | 5.5 | ≥1.5 | S |
| S9 | 40 | Female | 31 | 2 | 5.5 | ≥1.5 | S |
| | | | 20 | 2 | 7 | ≥1.5 | S |
| S10 | 70 | Female | 19 | 2 | 7 | ≥1.5 | S |
| | | | 18 | 2 | 7 | ≥1.5 | S |
| S11 | 36 | Male | 20 | 1 | 7 | ≥1.5 | S |
| | | | 19 | 1 | 5.5 | <1.5 | S |
| S12 | 69 | Male | 29 | 1 | 5.5 | ≥1.5 | S |
| | | | 30 | 1 | 5.5 | ≥1.5 | S |
| | | | 19 | 1 | 5.5 | ≥1.5 | S |
| S13 | 55 | Male | 18 | 1 | 5.5 | ≥1.5 | S |
| | | | 30 | 1 | 7 | <1.5 | S |
| S14 | 65 | Female | 31 | 1 | 5.5 | <1.5 | S |
| | | | 20 | 1 | 7 | <1.5 | S |
| S15 | 70 | Female | 19 | 1 | 7 | <1.5 | S |
| | | | 29 | 1 | 7 | ≥1.5 | S |
| S16 | 56 | Male | 30 | 1 | 7 | ≥1.5 | S |
| | | | 31 | 1 | 7 | ≥1.5 | S |
| S17 | 55 | Male | 30 | 1 | 5.5 | ≥1.5 | S |
| | | | 31 | 1 | 7 | ≥1.5 | S |
| S18 | 71 | Female | 30 | 1 | 7 | ≥1.5 | S |
| | | | 19 | 1 | 7 | ≥1.5 | S |
| S19 | 71 | Female | 20 | 1 | 7 | ≥1.5 | S |
| | | | 19 | 1 | 5.5 | ≥1.5 | S |
| S20 | 39 | Female | 21 | 1 | 5.5 | ≥1.5 | S |
| | | | 20 | 1 | 5.5 | ≥1.5 | S |
| | | | 19 | 1 | 5.5 | ≥1.5 | S |
| | | | 18 | 1 | 7 | ≥1.5 | S |

*CI indicates crown/implant; S, success; F, failure.

normality assumptions were verified with the Shapiro-Wilk test, and the Brown and Forsythe variation of Levene test statistics were used to verify the homogeneity of the variances. The Mann-Whitney *U* test was performed when these assumptions were not fulfilled. $P < .05$ was considered statistically significant. Statistical analysis was performed using SPSS 12.0 (Statistical Package for Social Sciences; SPSS, Inc, Chicago, Ill; $P < .05$).

RESULTS

A total of 46 implants were placed in 20 study subjects. Three patients received 4 implants each. The average age was 58.6

years (range, 36–77 years), and there were 8 men and 12 women. For group 1 (2-stage, submerged placement), a total of 24 implants were placed in 10 patients. For group 2 (1-stage, nonsubmerged placement), a total of 22 implants were placed in 10 patients. The primary stability of group 1 ranged from 56 to 84 instability quotient (ISQ) (mean, 75.9 ISQ), while the secondary stability ranged from 62 to 94 ISQ (mean, 82.9 ISQ). The primary stability in group 2 ranged from 55 to 87 ISQ (mean, 79.8 ISQ), while the secondary stability ranged from 75 to 86 ISQ (mean, 81.7 ISQ). There were no statistically significant differences in the primary and secondary stability ($P > .05$). A total of 25 implants were placed 5.5-mm deep, and 21 implants were placed 7-mm deep. The CI ratio measured after the delivery of maxillary prostheses was greater than or equal to 1.5 in 35 implants and less than 1.5 in 11 implants. No implant was lost during the follow-up period, although 1 implant showed marginal bone loss of 3.3 mm within 1 year of prosthetic function (Table 1). The marginal bone loss values that were measured by the 2 residents were not significantly different ($P = .711$).

1. Groups 1 and 2. There were no significant differences in the peri-implant index or marginal bone loss between the 24 implants in group 1 and the 22 implants in group 2 (Table 2).
2. Difference by installation depth. The 25 implants that were placed 5.5-mm deep and the 21 implants that were placed at a depth of 7 mm did not show significant differences, except with respect to PI and width of keratinized mucosa (Table 3).
3. Difference by CI ratio. There were no significant differences in the peri-implant index or marginal bone loss. Pocket depth, however, was different between the 2 groups, with the group with CI ratios ≥ 1.5 displaying significantly higher values than the group with CI ratios < 1.5 (Table 4).
4. Implant success rate. Cases showing severe resorption by more than 1 mm within 1 year of prosthetic function were regarded as failures. In this study, 1 implant placed in the first molar area of a male aged 74 years using the 1-stage, nonsubmerged technique was regarded as a failure because 3.3 mm of severe bone resorption was noted. The success rate of the 46 short implants (7-mm long) placed in 20 patients was 97.8%, with groups 1 and 2 showing no significant difference.

DISCUSSION

Although some authors have reported a negative prognoses of short implants, the survival and success rates of short implants have dramatically increased with recent improvements in surface treatment and design. Herrmann et al¹⁴ reported that short implants with lengths of 7 mm had a low success rate of 78.2% and attributed the failures to the short length. According to Weng et al,¹⁵ 60% of failures involved short implants with lengths shorter than or equal to 10 mm, and the accumulated success rate of short implants was much lower than that of all implants.

Recently, however, many opposing opinions have been presented. According to Maló et al,² out of 408 Brånemark implants, 7-mm implants had a 96.2% success rate, whereas 8.5-

TABLE 2

Peri-implant index and marginal bone loss of groups 1 and 2*

| Group | PI (P = .277) | GI (P = .242) | WKM (P = .058) | PD (P = .868) | Bone Loss (P = .776) |
|-------|------------------|------------------|-------------------|------------------|-------------------------|
| 1 | 1.05 | 0.5 | 1.25 | 2.70 | 0.04 |
| 2 | 0.7 | 0.2 | 2 | 2.76 | 0.16 |

*PI indicates plaque index; GI, gingival index; WKM, width of keratinized mucosa; PD, probing depth.

mm implants had a 97.1% success rate. In that study, all failures occurred before prosthesis delivery, with the major reason for failure being attributed to the application of a load on the implant healing caps installed after 1-stage placement. Similarly, in their 14-year accumulated study, Romeo et al³ reported a success rate of 97.9% for short implants and 97.1% for standard implants. In addition, marginal bone loss was not significantly different between short and standard implants. These results suggest that the prognosis of short implants has improved with improvements in surgical technique, implant surface treatment, and design.

According to Telleman et al,¹⁶ the shortest implants tend to fail in patients with partially edentulous jaws. Maxillary implants also showed much higher failures rate than mandibular implants. However, there was no difference in the failure rate of bone grafts. Smoking has been associated with a negative effect on the survival of implants. Misch et al¹ stressed the importance of the functional area of the total area of the implant. In addition, the shape and width of the implant have been shown to be more important than the length of the implant.

Some studies have reported on mechanical side effects resulting from inappropriate CI ratios. Rangert et al¹⁷ reported that marginal bone loss was inevitable because of an inappropriate CI ratio, which results in a force that is not parallel to the long axis of the tooth. On the other hand, Blanes et al¹⁸ claimed that less marginal bone loss occurred with a higher CI ratio. According to Rokni et al¹⁹ and Tawil et al,²⁰ the CI ratio did not have any effect on marginal bone loss if the occlusion was designed to be near the long axis of the implant.²⁰⁻²³ Many authors have suggested that occlusal loading is the most important factor associated with marginal bone loss. Short implants can have long-term stabilization, provided the force orientation and load distribution are favorable and the parafunction and cantilevery are controlled.

TABLE 3

Peri-implant index and marginal bone loss by installation depth†

| Depth | PI (P = .038)* | GI (P = .872) | WKM (P = .028)* | PD (P = .372) | Bone Loss (0.822) |
|--------|-------------------|------------------|--------------------|------------------|----------------------|
| 5.5 mm | 1.09* | 0.33 | 1.20* | 2.68 | 0.14 |
| 7 mm | 0.65* | 0.37 | 2.06* | 2.79 | 0.04 |

*Statistically significant.

†PI indicates plaque index; GI, gingival index; WKM, width of keratinized mucosa; PD, probing depth.

TABLE 4

Peri-implant index and marginal bone loss according to the CI ratio*

| CI Ratio | PI (P = .131) | GI (P = .080) | AG (P = .475) | PD (P = .005)* | Bone Loss (P = .899) |
|----------|------------------|------------------|------------------|-------------------|-------------------------|
| <1.5 | 0.55 | 0.00 | 1.80 | 1.41* | 0.02 |
| ≥1.5 | 1.00 | 0.45 | 1.50 | 2.79* | 0.12 |

*CI indicates crown/implant; PI, plaque index; GI, gingival index; AG, attached gingiva; PD, probing depth.

However, most studies were performed in single-implant cases. In the present study, the CI ratio did not have any significant relationship with marginal bone loss. Generally, the CI ratio is one of the most important indices that is considered when an abutment tooth is selected. For example, a removable partial denture anchored onto natural teeth may generate harmful lateral forces as a result of longer lever action. When this ratio is 0.5, clinicians can expect favorable outcomes. However, we have yet to obtain clinical guidelines for the CI ratio in implants.¹⁸ Tawil et al and Rokni et al reported that most of the implants have a CI ratio between 1.1 and 2.5. As such, in this study, the group that had a CI ratio of <1.5 was compared with the group that had a CI ratio of ≥1.5.^{20,24}

It has been reported that splinting short implants convey less stress to the bone-implant interfaces and disperse the strain more uniformly during prosthetic function.²⁵⁻²⁷ A multicenter, retrospective, 6-year case series study on short dental implants in partially edentulous areas of the posterior jaw has been performed. The authors reported a survival rate of 99.6% when implants were as placed using a 2-stage surgical approach and 98.3% when the 1-stage approach was used. The authors stressed the importance of multiple tooth implants followed by splinted prosthesis, as well as the absence of no lateral forces during prosthetic restoration and the absence of a cantilever of greater than or equal to 2 mm. Splinted implants connected with prostheses increase the functional surface area that sustains the load applied to the prostheses.²⁵

The Dentium short (7-mm length) implants used in this study, which have a tapered design, also had the appropriate micro-crater and micro-pit on their surfaces and SLA surface treatment for excellent osseointegration capacity. With its collar and fixture at 1.5 mm and 5.5 mm in length, respectively, this implant was designed to be placed in various ways at depths ranging from 5.5 to 7 mm, depending on the height of the residual bone. All of the implants used in this study received mandibular prostheses in the splinted form and showed both excellent primary and secondary stability. A survival rate of 100% and success rate of 97.83% were recorded 1 year after prosthetic loading. Based on the results of the presented study, short implants (7-mm length) may provide relatively excellent clinical outcomes, regardless of placement method, depth, and/or CI ratio.

Peri-implant tissue conditions, such as PI, gingival inflammatory index, pocket depth, and width of keratinized mucosa, are important in the long-term maintenance of the implants. Kim et al²⁸ evaluated the peri-implant tissue in nonsubmerged dental implants retrospectively. After a mean follow-up period of 30 months, the inflammatory index, PI, and width of the buccal keratinized mucosa were 0.37, 0.73, and 2.43 mm,

respectively.²⁸ In this study, similar results were observed 1 year after prosthetic loading. This current study has 2 serious limitations: the small sample size of the groups and the short observation period. As such, given the small number of samples, it was impossible to achieve statistical significance. When the groups with placement depths of 5.5 mm and 7 mm were compared, differences in relation to PI and width of keratinized mucosa did not show clinical significance. As such, various unaccounted variables may have also affected these processes. The significant increase in the pocket depth in the group with a CI ratio of greater than or equal to 1.5 may be attributable to variables such as the implant placement depth and the use of 1-stage or 2-stage installation. Schulte et al²⁹ suggested that the CI ratio guidelines associated with natural teeth should not be applied to implant restorations. As such, in this study, the rationale for separating the groups based on a CI ratio =1.5 was baseless. More statistical analysis using a larger number of study subjects is necessary to create a CI ratio guideline. In addition, a randomized prospective clinical trial is necessary to evaluate the prognosis of single and splinted restorations with short implants.

CONCLUSION

A 7-mm short implant placed in the posterior mandible had a 97.6% success rate after 1 year of prosthetic function. Submerged and nonsubmerged placements, 5.5-mm and 7-mm depth placements, and the CI ratio did not show significant differences with regard to clinical prognosis.

In cases involving insufficient residual bone in the posterior mandible, the installation of a splinting prosthesis after placement of 2 short implants with a length of 7 mm may yield stable treatment results.

ABBREVIATIONS

CI: crown/implant

PI: plaque index

REFERENCES

- Misch CE, Suzuki J, Misch-Dietsh FD, et al. A positive correlation between occlusal trauma and peri-implant bone loss-literature support. *Implant Dent*. 2005;14:108-116.
- Maló P, de Araujo Nobre M, Rangert B. Short implants placed one-stage in maxillae and mandibles: a retrospective clinical study with 1 to 9 years of follow-up. *Clin Implant Dent Relat Res*. 2007;9:15-21.
- Romeo E, Ghisolf M, Rozza R, Chapasco M, Lops D. Short (8-mm) dental implants in the rehabilitation of partial and complete edentulism: a 3 to 14 year longitudinal study. *Int J Prosthodont*. 2006;19:586-592.
- Stellingsma K, Raghoobar GM, Visser A, Vissink A, Meijer HJ. The extremely resorbed mandible, 10-year results of a randomized controlled trial on 3 treatment strategies. *Clin Oral Implants Res*. 2014;25:926-932.
- Srinivasan M, Vazquez L, Rieder P, Moraguez O, Bernard JP, Belser UC. Efficacy and predictability of short dental implants (<8 mm): a critical appraisal of the recent literature. *Int J Oral Maxillofac Implants*. 2012;27:1429-1437.
- Rocci A, Martignoni M, Gottlow J. Immediate loading of Branemark system TiUnite and machined-surface implants in the posterior mandible: a

randomized open-ended clinical trial. *Clin Implant Dent Relat Res*. 2003;5(suppl 1):57-63.

7. Glauser R, Lundgren AK, Gottlow J, et al. Immediate occlusal loading of BranemarkTiUnite implants placed predominantly in soft bone: 1-year results of a prospective clinical study. *Clin Implant Dent Relat Res*. 2003;5(suppl 1):47-56.

8. Sun HL, Huang C, Wu YR, Shi B. Failure rates of short (<10 mm) dental implants and factors influencing their failure: a systematic review. *Int J Oral Maxillofac Implants*. 2011;26:816-825.

9. Gentile MA, Chuang SK, Dodson TB. Survival estimates and risk factors for failure with 6 × 5.7 mm implants. *Int J Oral Maxillofac Implants*. 2005;20:930-937.

10. Sun HL, Huang C, Wu YR, Shi B. Failure rates of short (<10 mm) dental implants and factors influencing their failure: a systematic review. *Int J Oral Maxillofac Implants*. 2011;26:816-825.

11. Albrektsson T, Zarb GA, Worthington P, Erickson AR. The long-term efficacy of currently used dental implants: a review and proposed criteria of success. *J Oral Maxillofac Implants*. 1986;1:11-25.

12. Løe H. The gingival index, the plaque index and the retention index systems. *J Periodontol*. 1967;38(6 suppl):610-616.

13. Lang NP, Loe H. The relationship between the width of keratinized gingiva and gingival health. *J Periodontol*. 1972;43:623-627.

14. Herrmann I, Lekholm U, Holm S, Kulteje C. Evaluation of patient and implant characteristics as potential prognostic factors for oral implant failures. *Int J Oral Maxillofac Implants*. 2005;19:387-392.

15. Weng D, Jacobson Z, Tarnow D, et al. A prospective multicenter clinical trial of 3i machined-surfaced implants: results after 6 years of follow-up. *Int J Oral Maxillofac Implants*. 2003;18:417-423.

16. Telleman G, Raghoobar GM, Vissink A, et al. A systematic review of the prognosis of short (<10mm) dental implants placed in the partially edentulous patient. *J Clin Periodontol*. 2011;38:667-676.

17. Rangert BR, Sullivan RM, Jemt TM. Load factor control for implants in the posterior partially edentulous segment. *Int J Oral Maxillofac Implants*. 1997;12:360-370.

18. Blanes RJ, Bernard JP, Blanes ZM, Belser UC. A 10-year prospective study of ITI dental implants placed in the posterior region. II: influence of the crown-to-implant ratio and different prosthetic treatment modalities on crestal bone loss. *Clin Oral Implants Res*. 2007;18:707-714.

19. Rokni S, Todescan R, Watson P, Pharoach M, Adegbeh AO, Deporter D. An assessment of crown-to-root ratios with short sintered porous-surfaced implants supporting prostheses in partially edentulous patients. *Int J Oral Maxillofac Implants*. 2005;20:69-76.

20. Tawil G, Aboujaoude N, Tounan R. Influence of prosthetic parameters on the survival and complication rates of short implants. *Int J Oral Maxillofac Implants*. 2006;21:275-282.

21. Anitua E, Pinas L, Orive G. Retrospective study of short and extra-short implants placed in posterior regions: influence of crown-to-implant ratio on marginal bone loss. *Clin Implant Dent Relat Res*. 2015;17:102-110.

22. Sotto-Major BS, Senna PM, da Silva WJ, Rocha EP, Del Bel Cury AA. Influence of crown-to-implant ratio, retention system, restorative material, and occlusal loading on stress concentrations in single short implants. *Int J Oral Maxillofac Implants*. 2012;27:e13-e18.

23. Birdi H, Schulte J, Kovacs A, Weed M, Chuang SK. Crown-to-implant ratios of short-length implants. *J Oral Implantol*. 2010;36:425-433.

24. Rokni S, Todescan R, Watson P, Pharoach M, Adegbebo AO, Deporter D. An assessment of crown-to-root ratios with short sintered porous-surfaced implants supporting prostheses in partially edentulous patients. *Int J Oral Maxillofac Implants*. 2005;20:69-76.

25. Bidez MW, Misch CE. Force transfer in implant dentistry: basic concepts and principles. *J Oral Implantol*. 1992;18:264-274.

26. Misch CE, Steigenga J, Barboza E, Misch-Dietsh F, Cianciola LJ, Kazor C. Short dental implants in posterior partial edentulism: a multicenter retrospective 6-year case series study. *J Periodontol*. 2006;77:1340-1347.

27. Yilmaz B, Seidt JD, McGlumphy EA, Clelland NL. Comparison of strains for splinted and nonsplinted screw-retained prostheses on short implants. *Int J Oral Maxillofac Implants*. 2011;26:1176-1182.

28. Kim YK, Kim SG, Oh HK, et al. Evaluation of perimplant tissue in nonsubmerged dental implants: a multicenter retrospective study. *Oral Surg Oral Med Oral Pathol Oral Radiol Endod*. 2009;108:189-195.

29. Schulte J, Flores AM, Weed M. Crown-to-implant ratios of single tooth implant-supported restorations. *J Prosthet Dent*. 2007;98:1-5.