

Vertical Ridge Augmentation of Atrophic Posterior Mandible Using Platelet-Derived Growth Factor: Two Case Reports

Daniel Kuan-Te Ho, DMD, DMSc, MSc^{1*}

Martin Ming-Jen Fu, DMSc, MS²

David Minjoon Kim, DDS, DMSc³

INTRODUCTION

Vertical bone augmentation of the severely atrophic alveolar ridge remains a challenge in implant dentistry. Techniques such as onlay block graft, guided bone regeneration (GBR), distraction osteogenesis, and forced tooth eruption have been attempted by clinicians to achieve vertical bone gain on edentulous ridges.¹ Nevertheless, some of these procedures are associated with unpredictable outcomes and undesirable complications.²

As an angiogenic, chemotactic, and mitogenic factor, recombinant human platelet-derived growth factor-BB (rhPDGF-BB) has recently been used in tissue engineering to regenerate osseous structures in various clinical settings.³ RhPDGF-BB has been demonstrated in human to facilitate bone growth with either cancellous allogenic block graft or a mixture of autogenous and xenogenic grafts for the reconstruction of localized ridge defects where the adjacent alveolar ridge has minimal vertical bone loss.⁴⁻⁶ For the posterior atrophic mandible, there is only 1 case report to date in human documenting the use of rhPDGF-BB with deproteinized bovine block for 3-dimensional ridge augmentation.⁷ In the current study, we outline a different approach to achieve bone augmentation on the edentulous alveolar ridge in human without the use of block grafts. The purpose of this report is to describe the combined use of rhPDGF-BB, titanium-reinforced expanded polytetrafluoroethylene (ePTFE) membrane, and particulate allogenic/xenogenic composite bone graft for vertical ridge augmentation on a severely atrophic posterior mandible in human.

CASE REPORT

Two patients with Seibert Class III posterior mandibular alveolar ridge defects underwent bone augmentation using combination therapy.

Patient 1

A 53-year-old woman without contributory medical conditions presented with a Seibert Class III ridge defect at site No. 19. The patient stated having a failed implant removed previously at site No. 19 years ago, leaving her with a severe bony defect. Clinical and radiographic examination revealed severe loss of ridge height with crestal ridge width measured to be 1–2 mm (Figure 1a). The surgical procedure was reviewed with the patient, and consent to proceed was obtained.

One day prior to the surgery, the patient was placed on amoxicillin 500 mg 3 times a day (7-day regimen) and methylprednisolone 24 mg (Medrol Dosepak with a 6-day regimen of decreasing methylprednisolone dose). Following a midcrestal and a vertical incision on the mesiobuccal of No. 21, a full-thickness flap was raised to expose the residual alveolar ridge width clinically measured to be 1–2 mm (Figure 1b and c). On the lingual aspect, the full-thickness flap was extended beyond the mylohyoid ridge. The mental foramen was located, and careful exposure was done to prevent damage to the neurovascular tissues during periosteal releasing incision. Periosteal releasing incisions were made on both the buccal and lingual flaps to mobilize the tissue for anticipated tension-free primary closure. A releasing incision on the lingual flap was made only coronally to the mylohyoid ridge to prevent damage of rich vascular tissues at the floor of the mouth. A mixture of freeze-dried bone allograft (FDBA; Biomet 3i, Palm Beach Garden, Fla) and bovine xenograft (Bio-Oss, Geistlich, Princeton, NJ) in a ratio of 2:1 was hydrated with 0.5 mL of rhPDGF-BB (Gem 21s, Osteohealth, Shirley, NY) for 15 minutes, and blood coagulum collected from the surgical site was added to the mixture. Titanium-reinforced ePTFE membrane (Gore-Tex, GORE, Newark, Del) was trimmed to fit the surgical site and stabilized with one 1.6 × 4-mm standard fixation screw (OsteoMed, Addison, Tex) on the buccal aspect (Figure 1d). After decortication of the surgical site with No. 2 round burs, rhPDGF-BB hydrated bone graft composite was placed and covered by an ePTFE membrane. Primary flap closure was achieved with sutures (CV-7, GORE, Newark, Del). The patient was instructed to continue amoxicillin and methylprednisolone regimens and was placed on analgesics with 0.12% chlorhexidine rinse. The patient was seen 2 weeks postoperatively for suture removal. No signs of infection, exposure of the ePTFE membrane, paresthesia, or other complications were observed postoperatively. At 9 months, there was an adequate amount of bone gain clinically (Figure 2a and b). Comparison of preoperative and postoperative computerized tomography (CT)

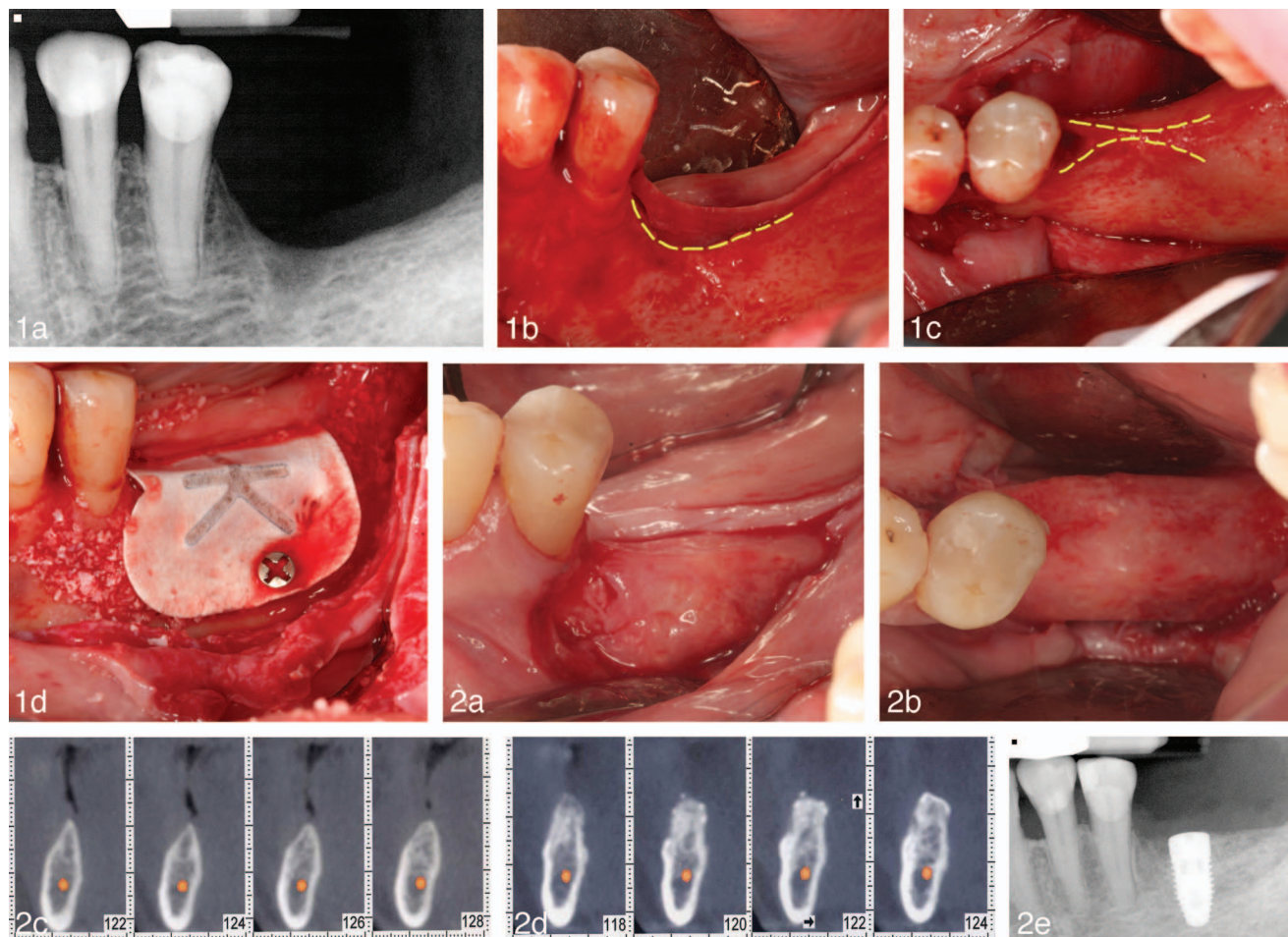
¹ Department of Periodontics, School of Dentistry, The University of Texas Health Science Center at Houston, Houston, Tex.

² Department of Oral Medicine, Infection and Immunity, Harvard School of Dental Medicine, Boston, Mass.

³ Division of Periodontology, Department of Oral Medicine, Infection and Immunity, Harvard School of Dental Medicine, Boston, Mass.

* Corresponding author, e-mail: daniel.kuan-te.ho@uth.tmc.edu

DOI: 10.1563/AAID-JOI-D-13-00179



FIGURES 1 AND 2. **FIGURE 1.** (a) Preoperative radiographic presentation of atrophic left mandible (patient 1). Preoperative buccal (b) and occlusal (c) view of Seibert Class III ridge defect upon full-thickness flap reflection. (d) Allograft/xenograft mixture and expanded polytetrafluoroethylene membrane placement over the atrophic ridge. **FIGURE 2.** Clinical evidence of significant bone gain in ridge height (a) and width (b) at 9 months (patient 1). Preoperative (c) and 9-month postoperative (d) computerized tomography scans revealing a significant amount of bone gain in height and width. (e) Placement of Nobel Replace Select 5 × 10 mm WP implant at site No. 19.

scans at site No. 19 revealed an average bone gain of 3–4 mm in height and 6–7 mm in width that was sufficient for implant placement (Figure 2c and 2d). Nobel Replace Select 5 × 10 mm WP implant (Nobel Biocare, Yorba Linda, Calif) was placed at site No. 19 (Figure 2e).

Patient 2

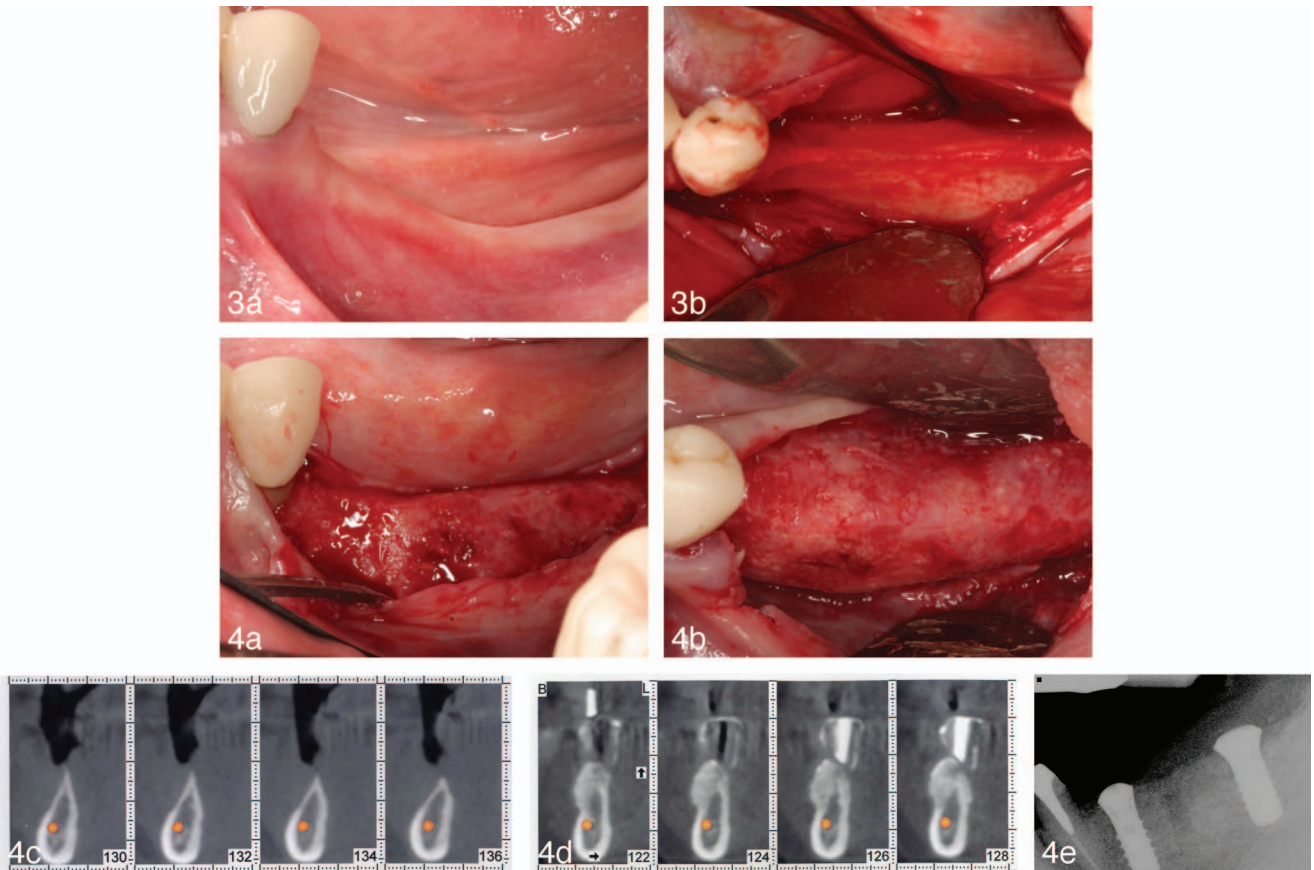
A 46-year-old woman with no significant health issues presented with a Seibert Class III ridge defect at sites No. 18, 19, and 20. These teeth were extracted more than 15 years ago due to dental caries. Clinical and radiographic evaluation showed loss of ridge height, with crestal ridge width measured to be 1 mm (Figure 3a and 3b).

This patient underwent procedures similar to those described in the previous case with regard to patient management, medications prescribed, design of surgical flap, and the use of grafting materials. The combination therapy included titanium-reinforced ePTFE membrane (Gore-Tex, GORE), a mixture of FDBA (Biomet 3i) and bovine xenograft (Bio-Oss, Geistlich) in a ratio of 2:1 hydrated with 0.5 mL of

rhPDGF-BB (Gem 21s, Osteohealth) and blood coagulum, and one 1.6 × 4-mm standard fixation screw for membrane stabilization (OsteoMed). Postoperatively, no signs of infection, exposure of the ePTFE membrane, paresthesia, or other complications were observed. At 9 months, clinical and radiographic (comparison of preoperative and postoperative CT scans) assessment at sites No. 18 and 20 demonstrated an average bone gain of 3–4 mm in height and 6–7 mm in width adequate for implant placement (Figure 4a–d). Straumann 4.8 × 10 mm WN and 4.1 × 10 mm RN SLActive implants (Straumann, Andover, Mass) were placed at sites No. 18 and 20 (Figure 4e).

DISCUSSION

The concept of tissue engineering has revolutionized the approach that researchers and clinicians take in designing alveolar reconstruction surgical procedures. As an essential part of tissue engineering, growth factors such as rhPDGF-BB have been investigated for their feasibility, safety, and efficacy in promoting tissue regeneration.^{8,9} In this report, we describe a



FIGURES 3 AND 4. FIGURE 3. (a) Preoperative clinical presentation of atrophic left mandible (patient 2). (b) Preoperative occlusal view of Seibert Class III ridge defect upon full-thickness flap reflection. **FIGURE 4.** Clinical evidence of significant bone gain in ridge height (a) and width (b) at 9 months (patient 2). Preoperative (c) and 9-month postoperative (d) computerized tomography scans revealing a significant amount of bone gain in height and width. (e) Placement of Straumann 4.8×10 mm WN and 4.1×10 mm RN SLActive implants at sites No. 18 and 20.

combination therapy to achieve successful vertical and horizontal ridge augmentation in the atrophic posterior mandible.

Here, rhPDGF-BB is used in conjunction with titanium-reinforced ePTFE membrane and an allogenic (FDBA)/xenogenic (Bio-Oss 2:1) bone composite. Over the years, application of ePTFE membrane in GBR procedures has become less favorable because of frequent membrane exposure and the need for regular patient monitoring following exposure to prevent infection.^{10,11} Exposure of the ePTFE membrane may also negatively affect the outcome of regeneration.¹² As a chemotactic, mitogenic, and angiogenic molecule, PDGF-BB promotes wound healing and tissue formation.^{13–15} Hence, we postulate that the addition of rhPDGF-BB in GBR would aid in postoperative wound healing to maintain primary tissue closure, thereby minimizing ePTFE membrane exposure and protecting underlying bone grafts. Both patients in this case report presented with optimal healing 2 weeks postoperatively, with no membrane exposure at any time point.

Neither patient in this case report presented with atrophic mandibular alveolar ridges associated with immediate extraction sockets. Human histological study indicates that active proliferation of osteogenic cells in extraction sockets is evident

4 to 8 weeks postextraction,¹⁶ and osteoprogenitor cells in the residual periodontal ligaments associated with sockets may contribute to bone regeneration following tooth extraction.¹⁷ In the present report, successful vertical ridge augmentation was performed on the chronic atrophic edentulous mandibular ridge. Our clinical outcomes demonstrate that with the combination therapy described here, vertical bone augmentation on the mandible is possible even in the absence of socket-derived osteogenic potential.

In this treatment modality, we took the advantage of the slower resorption rate of xenograft to minimize collapse of grafting materials that are sometimes evident when allografts undergo early resorption. However, unlike a previous report using deproteinized bovine bone blocks without barrier membrane in performing ridge augmentation,⁷ we took a different approach by incorporating allogenic bone granules in the bone composite (the allograft-to-xenograft ratio is 2:1). The allogenic part of this bone composite allowed for faster replacement of these particulates with concurrent new bone formation, while the xenogenic component served to maintain the space to prevent graft collapse due to its slow resorbing characteristics.^{18–21} Because of the granular nature of the bone composite, a titanium-reinforced ePTFE membrane was used to

contain graft materials to provide space maintenance. This barrier membrane created a sealed space to prevent epithelial and connective tissue cell migration that might interfere with osteogenesis.²² The titanium skeleton of the ePTFE membrane also provided physical support that allowed blood clot and graft material stabilization, which was crucial to new bone formation.²³ Tenting screws were not required in this combination therapy because the space maintenance was made possible by the structural rigidity of titanium-reinforced ePTFE membrane and the nature of the xenografts' slow resorption rate.^{20,21,23}

In summary, this combination therapy (allogenic/xenogenic bone mixture, rhPDGF-BB, and titanium-reinforced ePTFE membrane) serves as an alternative to conventional vertical ridge augmentation procedures. It does so by (1) avoiding additional surgical site(s) for autogenous block graft harvesting; (2) minimizing the exposure of titanium-reinforced membrane due to favorable wound-healing properties of rhPDGF-BB; (3) removing the need to use and manipulate titanium mesh, which at times can be time-consuming and challenging both during placement and removal after GBR procedures; and (4) eliminating the need to use tenting screws for space maintenance, which has already been provided by the titanium-reinforced membrane and the slow turnover rate of the xenograft. Moreover, clinical application of this combination therapy is relatively simple and can be less time-consuming than vertical ridge augmentation performed using other conventional techniques such as block grafts or titanium mesh.

Within the limits of this report, the combined use of rhPDGF-BB, titanium-reinforced ePTFE membrane, and allo-graft/xenograft bone composite provides an alternative augmentation technique in achieving successful vertical and horizontal bone gain at severely atrophic posterior mandible. This combination therapy has great potential for vertical ridge augmentation and should be further investigated in clinical trials.

ABBREVIATIONS

CT: computerized tomography
 ePTFE: expanded polytetrafluoroethylene
 FDBA: freeze-dried bone allograft
 GBR: guided bone regeneration
 rhPDGF-BB: recombinant human platelet-derived growth factor-BB

REFERENCES

1. McAllister BS, Haghigat K. Bone augmentation techniques. *J Periodontol.* 2007;78:377–396.
2. Rocchietta I, Fontana F, Simion M. Clinical outcomes of vertical bone augmentation to enable dental implant placement: a systematic review. *J Clin Periodontol.* 2008;35:203–215.
3. Nevins ML, Reynolds MA. Tissue engineering with recombinant human platelet-derived growth factor BB for implant site development. *Compend Contin Educ Dent.* 2011;32:18, 20–27.
4. Cardaropoli D. Vertical ridge augmentation with the use of

recombinant human platelet-derived growth factor-BB and bovine bone mineral: a case report. *Int J Periodontics Restorative Dent.* 2009;29:289–295.

5. Nevins M, Camelo M, Nevins ML, Ho DK, Schupbach P, Kim DM. Growth factor-mediated combination therapy to treat large local human alveolar ridge defects. *Int J Periodontics Restorative Dent.* 2012;32:263–271.

6. Simion M, Rocchietta I, Monforte M, Maschera E. Three-dimensional alveolar bone reconstruction with a combination of recombinant human platelet-derived growth factor BB and guided bone regeneration: a case report. *Int J Periodontics Restorative Dent.* 2008;28:239–243.

7. Simion M, Rocchietta I, Dellavia C. Three-dimensional ridge augmentation with xenograft and recombinant human platelet-derived growth factor-BB in humans: report of two cases. *Int J Periodontics Restorative Dent.* 2007;27:109–115.

8. Nevins M, Giannobile WV, McGuire MK, et al. Platelet-derived growth factor stimulates bone fill and rate of attachment level gain: results of a large multicenter randomized controlled trial. *J Periodontol.* 2005;76:2205–2215.

9. Nevins M, Kao RT, McGuire MK, et al. Platelet-derived growth factor promotes periodontal regeneration in localized osseous defects: 36-month extension results from a randomized, controlled, double-masked clinical trial. *J Periodontol.* 2013;84:456–464.

10. Verardi S, Simion M. Management of the exposure of e-PTFE membranes in guided bone regeneration. *Pract Proced Aesthet Dent.* 2007;19:111–117.

11. Simion M, Trisi P, Maglione M, Piattelli A. Bacterial penetration in vitro through GTAM membrane with and without topical chlorhexidine application: a light and scanning electron microscopic study. *J Clinical Periodontol.* 1995;22:321–331.

12. Machtei EE. The effect of membrane exposure on the outcome of regenerative procedures in humans: a meta-analysis. *J Periodontol.* 2001;72:512–516.

13. Barrientos S, Stojadinovic O, Golinko MS, Brem H, Tomic-Canic M. Growth factors and cytokines in wound healing. *Wound Repair Regen.* 2008;16:585–601.

14. Hollinger JO, Hart CE, Hirsch SN, Lynch S, Friedlaender GE. Recombinant human platelet-derived growth factor: biology and clinical applications. *J Bone Joint Surg Am.* 2008;90(suppl 1):48–54.

15. Lederle W, Stark HJ, Skobe M, Fusenig NE, Mueller MM. Platelet-derived growth factor-BB controls epithelial tumor phenotype by differential growth factor regulation in stromal cells. *Am J Pathol.* 2006;169:1767–1783.

16. Evian CI, Rosenberg ES, Coslet JG, Corn H. The osteogenic activity of bone removed from healing extraction sockets in humans. *J Periodontol.* 1982;53:81–85.

17. Devlin H, Sloan P. Early bone healing events in the human extraction socket. *Int J Oral Maxillofac Surg.* 2002;31:641–645.

18. Piattelli A, Scarano A, Corigliano M, Piattelli M. Comparison of bone regeneration with the use of mineralized and demineralized freeze-dried bone allografts: a histological and histochemical study in man. *Biomaterials.* 1996;17:1127–1131.

19. Piattelli M, Favero GA, Scarano A, Orsini G, Piattelli A. Bone reactions to anorganic bovine bone (Bio-Oss) used in sinus augmentation procedures: a histologic long-term report of 20 cases in humans. *Int J Oral Maxillofac Implants.* 1999;14:835–840.

20. Mordenfeld A, Hallman M, Johansson CB, Albrektsson T. Histological and histomorphometrical analyses of biopsies harvested 11 years after maxillary sinus floor augmentation with deproteinized bovine and autogenous bone. *Clin Oral Implants Res.* 2010;21:961–970.

21. Lambert F, Léonard A, Drion P, Sourice S, Layrolle P, Rompen E. Influence of space-filling materials in subantral bone augmentation: blood clot vs. autogenous bone chips vs. bovine hydroxyapatite. *Clin Oral Implants Res.* 2011;22:538–545.

22. Linde A, Alberius P, Dahlin C, Bjurstam K, Sundin Y. Osteopromotion: a soft-tissue exclusion principle using a membrane for bone healing and bone neogenesis. *J Periodontol.* 1993;64(11 suppl):1116–1128.

23. Jovanovic SA, Nevins M. Bone formation utilizing titanium-reinforced barrier membranes. *Int J Periodontics Restorative Dent.* 1995;15:56–69.