

Treatment of a Patient With Implant Failure and Jaw Osteonecrosis: Successful Retreatment Using Implants

Vicki C. Petropoulos, DMD, MS¹

Thomas J. Balshi, DDS, PhD²

Glenn J. Wolfinger, DMD²

Stephen F. Balshi, MBE^{2,3*}

INTRODUCTION

Currently, osteoporosis is on the rise, and is the most common disease of bone metabolism encountered in dental implant patients.¹ Approximately one-third of patients over the age of 60 are affected, with women incurring events twice as often as men.¹ Alendronate sodium (Fosamax; Merck and Co, Whitehouse Station, NJ) is a second-generation nonhormonal bisphosphonate (BP) used in oral-dose tablet form for osteopenic conditions. BPs possess a high affinity for bone inhibiting osteoclastic function and decrease bone resorption, preventing further bone loss.²

A possible complication of patients on bisphosphonates is osteonecrosis. Marx was the first who adopted the terminology to describe spontaneous or surgically induced nonhealing ulcers in the jaws that occur in patients taking bisphosphonates. This is termed bisphosphonate-induced osteonecrosis of the jaw (BONJ).³

According to the American Association of Oral and Maxillofacial Surgeons (AAOMS), the diagnosis of necrosis of the jaws induced by BP is based on the following criteria: (1) exposed bone greater than 8 weeks in duration; (2) it is induced by BP; and (3) no history of radiation therapy to the jaws.⁴ Although the initial effects of bisphosphonate therapy appear to be beneficial, with Merck & Co. reporting a 5.1% (alendronate, 70 mg/wk) mean increase in bone mineral density demonstrated over a 1-year period,⁵ the symptoms of BONJ may remain concealed for weeks or months, only to become recognizable by the presence of exposed bone in the oral cavity.⁶ Due to the common occurrence of tooth extraction, resulting in exposed bone, there exists a legitimate reason for concern and raises natural questions about alendronate's effects on dental implant osseointegration.⁷ Currently, BONJ is considered long term and irreversible, despite attempts to discontinue medication usage.⁸ Little data has been collected on oral bisphosphonate-related osteonecrosis and dental implant failure along with management of these failures. Most of the reported cases were from IV-administered BPs. In the United States, there have been over 200 reported cases of possible bisphosphonate associated

osteonecrosis of the jaw in patients taking Fosamax or Actonel (Procter and Gamble, Cincinnati, Ohio).⁹

This report discusses a patient taking oral Fosamax for 1 year and having successful implant osseointegration in the maxillary arch while after 5 years on this medication, the patient developed BONJ when implants were placed and loaded in the mandibular arch. The aim of this case study is to present the ongoing management of a patient who prophylactically utilized the bisphosphonate (Fosamax) and developed BONJ and how retreatment with dental implants can be successful following a drug hiatus.

CASE REPORT

Patient history

A 54-year-old, African American woman described as being in good general health with the exception of a precancerous lumpectomy (ductal carcinoma *in situ* cells), accompanied by radiation treatment of her breast 4 years prior, and evidence of osteopenia, was being treated with an oral dosage of 70 mg/wk bisphosphonate (Fosamax) for 1 year. She presented initially for immediate load dental implant treatment of her maxillary arch (Figures 1a and b) due to a failing fixed tooth-supported reconstruction, which was fabricated 3 years previously.

Clinical treatment

The abutment teeth in the maxillary arch were extracted (#2, 3, 6, 7, 9, 10, 11, 12, and 15) and 10 Brånemark System implants (Nobel Biocare, Yorba Linda, Calif) were placed in areas #1, 2, 5, 6, 7, 10, 11, 12, 15, and 16, following the Teeth in a Day immediate loading protocol (Figure 2).¹⁰⁻¹⁴ The maxillary implant-supported ceramo-metal prosthesis was placed without any complications or evidence of osteonecrotic activity. Approximately 4 years subsequent to the implants being placed in the maxillary arch, (the patient had been on the same dosage of Fosamax for 5 years), the patient decided to pursue similar treatment of the mandible. Insufficient endodontic restorations, extensive decay, and tooth mobility deemed a poor long-term prognosis for the existing mandibular dentition.

Mandibular treatment

The abutment teeth of the fixed dental prosthesis #22, 23, 24, 25, 26, and 27 were extracted and 6 Brånemark System implants were surgically placed in area #20, 22, 24, 25, 27, and 28 and

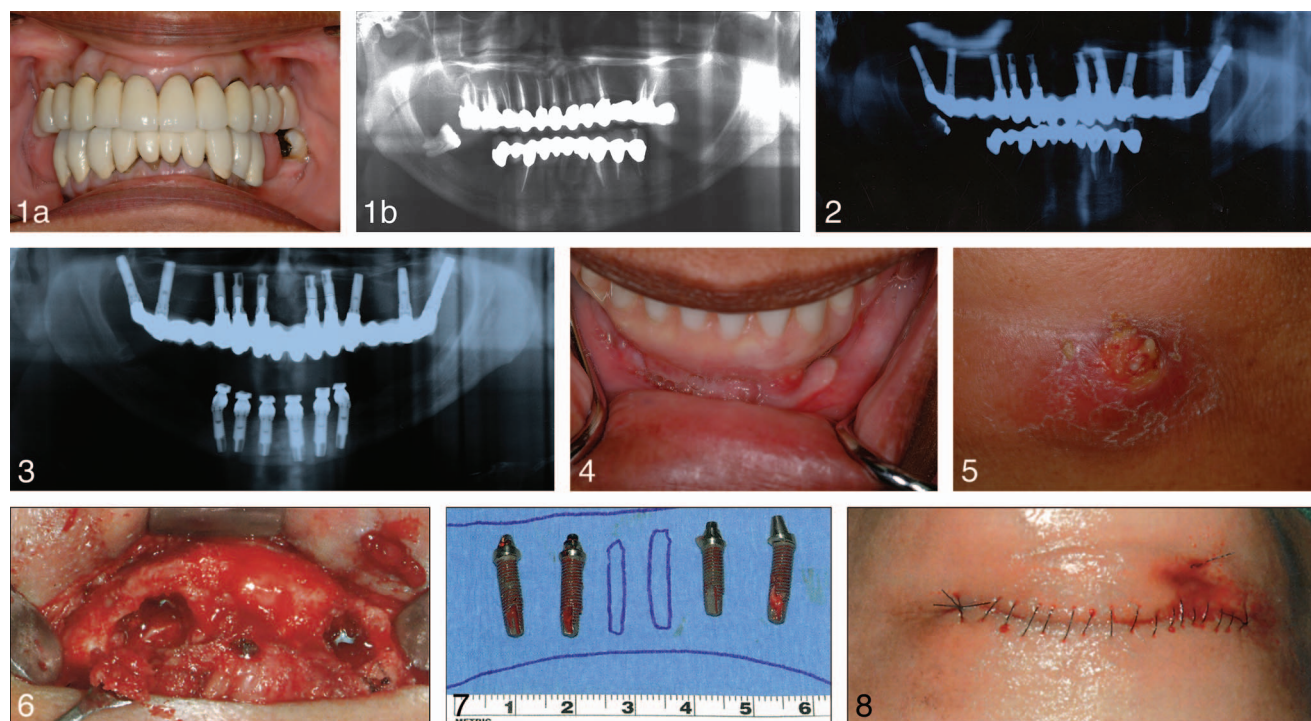
¹ Department of Preventive and Restorative Sciences, University of Pennsylvania School of Dental Medicine, Philadelphia, Penn.

² PI Dental Center, Institute for Facial Esthetics, Fort Washington, Penn.

³ CM Prosthetics, Inc, Fort Washington, Penn.

* Corresponding author, e-mail: stephen.balshi@cmprosthetics.com

DOI: 10.1563/AAID-JOI-D-13-00186



FIGURES 1–8. **FIGURE 1.** (a) Initial clinical presentation of patient with failing reconstruction. (Patient had been on oral bisphosphonates for 1 year). (b) Panoramic radiograph of initial presentation showing failing reconstruction. **FIGURE 2.** Panoramic radiograph of maxillary implant-supported reconstruction in place following Teeth in a Day immediate load protocol. **FIGURE 3.** Panoramic radiograph of 6 immediately loaded Brånemark fixtures placed following extractions (4 years following maxillary implant reconstruction; patient had been on oral bisphosphonate for 5 years). **FIGURE 4.** Ulceration in #22 area. **FIGURE 5.** Left inferior border of the mandible with purulent drainage (with permission from Quintessence). **FIGURE 6.** Open debridement of the mandible. Bone destruction, pus, granulation tissue, and apices of the dental implants were encountered (with permission from Quintessence). **FIGURE 7.** Four of the 6 implants were completely mobile and removed (with permission from Quintessence). **FIGURE 8.** Closure of the mandible after debridement (with permission from Quintessence).

immediately loaded following the Teeth in a Day protocol (Figure 3). There was no evidence of any infection from the extraction of the remaining abutment teeth. Per Teeth in A Day Protocol, the patient was on an antibiotic following the extraction of teeth #22, 23, 24, 25, 26, and 27. The patient left the surgical suite with a fully functional, all-acrylic resin screw-retained provisional prosthesis.

Postsurgical patient management

Two weeks postsurgery, the patient presented for suture removal and postoperative evaluation. The patient was experiencing pain subsequent to the surgery in proximity to the left canine. Intraoral examination confirmed an area of soft tissue, which appeared to be healing at a slower rate (Figure 4).

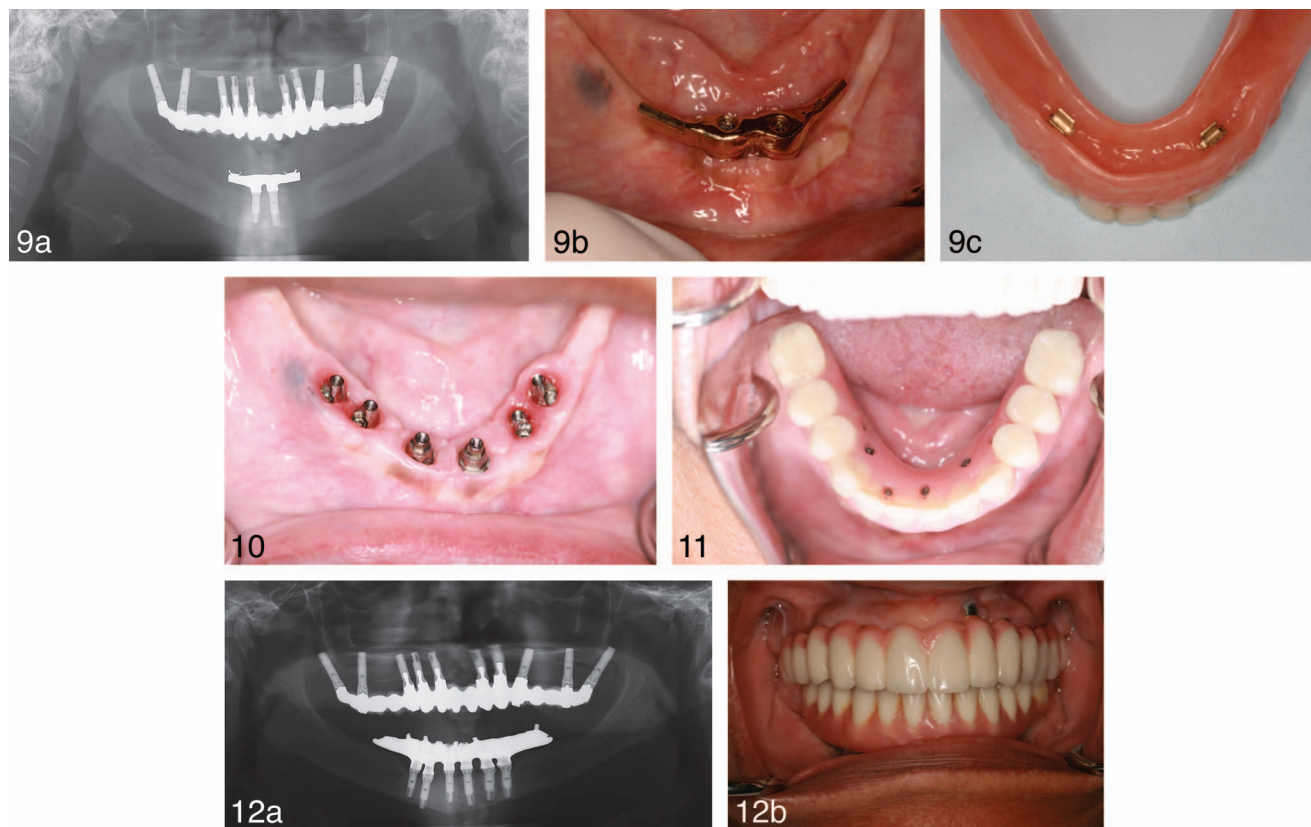
The next day, the patient returned with discomfort and submandibular swelling under her chin (lateral inferior aspect). Occlusal radiographs were taken and the patient was prescribed Keflex (Eli Lilly & Co, Vernier, Switzerland), 500 mg/d over a period of 10 days.

Over a period of 8 weeks, the patient's condition worsened. An extraoral fistula presented with discharge from the lesion on the left inferior border of the mandible (Figure 5). The patient was advised to continue her medications while on vacation and to seek local specialty services if needed. A computerized

tomography (CT) scan and a biopsy were obtained for lab assessment on fungi, anaerobic, and aerobic bacterial cultures.

CT scan data analysis revealed a massive loss of the inferior border of the mandible bilaterally, with an island of cortex in the midline. The cancellous bone appeared totally devoid around a wide perimeter surrounding the implants on both sides. On the left side, bone destruction was so significant that only minimal buccal and lingual cortical plates remained to prevent a pathologic fracture. Lab tests showed *Stenotrophomonas maltophilia* and the diagnosis was made of oral bisphosphonate-induced osteonecrosis of the mandible with a secondary osteomyelitis and foreign bodies.

The patient was administered piperacillin tazobactam combination prior to surgery since *Stenotrophomonas maltophilia* are most sensitive to this combination, 4.5 g every 8 hours for 5 days. She was referred to Jackson South Community Hospital (Miami, Florida) where the mandibular prosthesis was removed. An extraoral incision was made along the inferior border of the mandible. Granulation tissue and necrotic bone were removed (Figure 6). The last 2 posterior implants on the right and the left sides were encapsulated in granulation tissue and removed (Figure 7). The area was then irrigated with chlorhexidine (3M ESPE, St Paul, Minn) prior to closure (Figure 8). Two months later, a gold bar was fabricated (Figures 9a and b) to provide additional support for a modified mandibular overdenture prosthesis (Figure 9c) retained with the 2



FIGURES 9–12. **FIGURE 9.** (a) Panoramic radiograph of remaining 2 implants supporting removable overdenture prosthesis. (b) Intraoral view of gold bar supported by 2 fixtures. (c) Intaglio view of mandibular prosthesis with 2 Hader clip attachments. **FIGURE 10.** Four mandibular implants placed posteriorly following a 2.5-year drug hiatus. **FIGURE 11.** Final mandibular prosthesis. **FIGURE 12.** (a) Panoramic radiograph 11 years postoperative of maxillary reconstruction and 5 years of mandibular retreatment. (b) Intraoral view of maxillary and mandibular prostheses 11 and 5 years postoperative for maxillary and mandibular prostheses, respectively.

remaining anterior implants, which appeared stable. The patient was advised to discontinue her bisphosphonate medication indefinitely after consulting with her physician.

Retreatment of mandibular arch

Two and a half years following a drug hiatus from the Fosamax, the patient’s medical history was reviewed and results from a CTX (carboxy terminal collagen crosslinks) test (Quest Diagnostics Lab, Horsham, Penn) indicated 457 pg/mL, which showed that her bone healing capabilities had returned to normal levels.¹⁵ CTX levels below 100 indicate high level of risk; CTX levels between 100 and 150 indicate moderate risk; CTX levels above 150 indicate little to no risk. The patient had 4 Brånemark System implants placed in area #20, 22, 27, and 29, all of which were immediately loaded (Figure 10). The implant in area #27 was placed into the inferior cortex of the mandible to achieve high primary stability in the immediate loading protocol employed. The existing mandibular overdenture was converted into an all-acrylic resin screw-retained provisional prosthesis.

Definitive Mandibular Prosthesis

Three months following her second mandibular implant surgery, final impressions were made for a metal-resin implant fixed complete dental prosthesis which was delivered 1 month

later (Figure 11). The patient has been followed for 5 years and recall visits remain uneventful (Figures 12a and 1b). The maxillary prosthesis has been stable and held its integrity over the past 11 years.

DISCUSSION

The patient had a history of taking Fosamax (sodium alendronate) for 5 years when she presented for implant placement in the mandibular jaw. The patient met the criteria suggested by AAOMS and, from the cell culture, was diagnosed with BONJ. Few reports have investigated risk factors; however, it is suggested that risk factors such as potency of bisphosphonates, period of taking bisphosphonates, and systemic/local factors could influence the incidence of BONJ.¹⁶

Osteoporosis is a major public health threat. Since the introduction of alendronate sodium in 1995, approximately 191 million prescriptions have been distributed in the United States.¹⁷ Therefore, it is of utmost importance to assess risks, especially when patients take BPs for a long period of time. Fuggazato reported¹⁸ patients who had a history of taking oral bisphosphonate therapy for a mean period of 3.3 years had not experienced any incident of osteonecrosis following implant placement in intact ridges or tooth extractions with immediate

implant placement. Madrid and Sanz¹⁹ reported that there was no BONJ after implant placement in 217 patients who took BPs less than 5 years. From studies, it seems that there is a decreased incidence of osteonecrosis when the patient is on oral BPs for less than 5 years. In this present treatment, the patient had been taking oral BPs for 5 years, which could explain the osteonecrosis.

Marx et al²⁰ suggest using serum levels of morning fasting CTX to assess patients' risk of developing BONJ by oral administration of BPs. CTX shows the healing potential of bone as a marker of bone turnover.²⁰ Another study²¹ concurred that using the CTX serum levels may play an important role in risk assessment before oral surgery. It may be necessary to have the patient on a "drug hiatus" prior to any surgical intervention and subsequent to surgery if the patient's systemic condition allows it (as was done in this case report). Following the drug hiatus of 2.5 years, the CTX values were assessed to help in determining if retreatment of the implant placement was appropriate. The patient's CTX value in this report indicated that the risk of having BONJ was little or no risk. There is a rise in the population affected with osteoporosis and concurrently are taking BPs. The long term use of BPs should be followed closely and currently there is no consensus on the time limitation of BP usage or its long term adverse effects.²² More studies would be helpful on long-term side effects. Additionally, in an effort to establish some guidelines more studies that investigate serum CTX will be helpful as it relates to the number of years on the drug. Ideally, an alternative solution without oral implication is needed for the treatment of osteoporosis and management of osteopenia.

In conclusion, successful retreatment using dental implants after a 2.5-year drug hiatus was initiated from the time of developing BONJ, providing her with a functional and esthetic implant-supported dental prosthesis. This case report demonstrates that the effects of alendronate sodium related to BONJ are reversible.

ABBREVIATIONS

AAOMS: American Association of Oral and Maxillofacial Surgeons
 BONJ: bisphosphonate-induced osteonecrosis of the jaw
 BP: bisphosphonate
 CT: computerized tomography
 CTX: carboxy terminal collagen crosslinks

ACKNOWLEDGMENTS

We would like to acknowledge Dr Robert Marx for his contributions to this patient's care as well as Dr Richard Rasmussen. We would also like to thank the staff of the Pi Dental Center for their kind and gentle management of the patient during her treatment.

REFERENCES

1. Chacon GE, Stine EA, Larsen PE, Beck, FM, McGlumphy EA. Effect of alendronate on endosseous implant integration: an in vivo study in rabbits. *J Oral Maxillofac Surg.* 2006;64:1005–1009.
2. Licata, AA. Discovery, clinical development, and therapeutic uses of bisphosphonates. *Ann Pharmacother.* 2005;39:668–677.
3. Marx, RE. Bisphosphonate induced exposed bone (osteonecrosis/osteopetrosis) of the jaws. Risk factors, recognition, prevention and treatment. *J Oral Maxillofac Surg.* 2005;63:1567–1575.
4. Advisory Task Force on Bisphosphonate-Related Osteonecrosis of the Jaws, American Association of Oral and Maxillofacial Surgeons: American Association of Oral and Maxillofacial Surgeons position paper on bisphosphonate-related osteonecrosis of the jaws. *J Oral Maxillofac Surg.* 2007;65:369.
5. Merck & Co. Fosamax (alendronate sodium) tablets and oral solution. February 1–22, 2006.
6. Merigo E, Manfredi M, Meleti M, Corradi D, Vescovi P. Jaw bone necrosis without previous dental extractions associated with the use of bisphosphonates (pamidronate and zoledronate): a four-case report. *J Oral Pathol Med.* 2005;34:613–617.
7. Odvina CV, Zerwekh JE, Rao DS, Maalouf N, Gottschalk Pak CY. Severely suppressed bone turnover: a potential complication of alendronate therapy. *J Clin Endocrinol Metab.* 2005;90:1294–1301.
8. Kurtzman, GM, Silverstein LH, Peden J, Shatz PC. Implications of bisphosphonate use for the dentist: an introduction. *Dent Today.* 2006;25:80–85.
9. Grant BT, Amenendo C, Freeman K, Kraut R. Outcomes of placing dental implants in patients taking oral bisphosphonates: a review of 115 cases. *J Oral Maxillofac Surg.* 2008;66:223–230.
10. Balshi TJ, Wolfinger GJ. Immediate placement and implant loading for expedited patient care: a patient report. *Int J Oral Maxillofac Implants.* 2002;17:587–592.
11. Balshi TJ, Wolfinger GJ. Teeth in a day. *Implant Dent.* 2001;10:231–233.
12. Balshi, TJ, Wolfinger GJ. A new protocol for immediate functional loading of dental implants. *Dent Today.* 2001;20:60–65.
13. Petropoulos VC, Balshi TJ, Balshi SF, Wolfinger GJ. Extractions, implant placement, and immediate loading of mandibular implants: a case report of a functional fixed prosthesis in 5 hours. *Implant Dent.* 2003;12:283–290.
14. Balshi TJ, Wolfinger GJ, Wulc D, Balshi SF. A prospective analysis of immediate provisionalization of single implants. *J Prosthodont.* 2011;20:10–15.
15. Marx RE. *Oral and Intravenous Bisphosphonate-Induced Osteonecrosis of the Jaws: History, Etiology, Prevention, and Treatment.* Hanover, IL: Quintessence Publishing Co; 2007.
16. Ruggiero SL, Dodson TB, Assael LA, Landesberg R, Marx RE, Mehrota B. American Association of Oral and Maxillofacial Surgeons position paper on bisphosphonate-related osteonecrosis of the jaw: 2009 update. *J Oral Maxillofac Surg.* 2009;67:2–12.
17. Merck & Co Statement by Merck & Co, Inc. regarding Fosamax (alendronate sodium) and rare cases of osteonecrosis of the jaw. 2006:1.
18. Fuggazato PA, Lightfoot SW, Jaffin R, Kumar A. Implant placement with or without simultaneous tooth extraction in patients taking oral bisphosphonates: postoperative healing, early follow-up, and the incidence of complications in two private practices. *J Periodontol.* 2007;78:1664–1669.
19. Madrid C, Sanz M. What impact do systematically administered bisphosphonates have on oral implant therapy? A systematic review. *Clin Oral Implants Res.* 2009;20:87–95.
20. Marx RE, Chilio JE, Uloa JJ. Oral bisphosphonate induced osteonecrosis: risk factors, prediction of risk using serum CTX testing, prevention, and treatment. *J Oral Maxillofac Surg.* 2007;65:2397–2410.
21. Lazarovici TS, Mesilaty-Gross S, Vered I, et al. Serologic bone markers for predicting development of osteonecrosis of the jaw in patients receiving bisphosphonates. *J Oral Maxillofac Surg.* 2010;68:2241–2247.
22. Salari P, Abdollahi M. Long term bisphosphonate use I osteoporotic patients; a step forward, two steps back. *J Pharm Sci.* 2012;15:305–312.