

# The Role of Two Different Collagen Membranes for Dehiscence Defect Around Implants in Humans

Dong-Woon Lee, DDS, MSD<sup>1,2</sup>  
 Kyeong-Taek Kim, DDS, MSD<sup>1</sup>  
 Yon-Soo Joo, DDS<sup>1</sup>  
 Mi-Kyung Yoo, DDS, MSD<sup>1</sup>  
 Jeoung-A Yu, DDS, PhD<sup>1</sup>  
 Jae-Jun Ryu, DDS, PhD<sup>2\*</sup>

The aim of this study was to elucidate the role of 2 types of collagen membranes (cross-linked vs noncross-linked) used in conjunction with autogenous or allogenic bone followed by xenogeneic bone particles for dehiscence defect around implants in humans. Experimental groups were divided into 2 groups: Group CL (cross-linked, Ossix Plus, n = 24 implants, 16 patients) and Group NCL (noncross-linked, Bio-Gide, n = 25 implants, 18 patients). At the time of implant insertion and uncover surgery, measurements of the dehiscence bony height, width, and surface area were made. Before applying the membrane to defects, guided bone regeneration was performed. Because it is difficult to measure the degree of exposure, early exposed cases were excluded from the result analysis. The mean percentage gain of the dehiscence defect and the mean marginal bone reduction value of follow-up radiograph did not show statistically significant differences between the 2 groups. Both membranes exhibited satisfactory results on dehiscence defects. As a result, our authors concluded the success of guided bone regeneration was performed simultaneously for dehiscence defects around the implant, regardless whether collagen membranes were cross-linked or noncross-linked.

**Key Words:** cross-linked, noncross-linking, collagen membrane, dehiscence, guided bone regeneration

## INTRODUCTION

Many factors are known to influence the success of an implant. One of the most important factors is the adequacy of bone for implant placement. With respect to the guided bone regeneration (GBR) technique, the use of barrier membranes allows slower-migrating cells with osteogenic potential to repopulate the osseous defect.<sup>1</sup> Most of the commercially available non-resorbable membranes made up of expanded polytetrafluoroethylene (e-PTFE) have proven to be effective in preventing connective and epithelial tissue invasion into the healing area, and could therefore promote osteogenesis. However, the membranes could be exposed prematurely and the graft materials might become contaminated by microorganisms, leading to infections, thus hindering bone regeneration.<sup>2,3</sup> To avoid this problem, clinicians have investigated the benefits of using biodegradable membranes. Although collagen membranes have been used as barriers in GBR in order to produce significant amounts of periodontal and bone regeneration, most of the resorbable membranes begin to dissolve before bone regeneration stabilizes. Because of this characteristic of the resorbable membranes, its application in

the GBR technique for dehiscence defects is challenging.<sup>4,5</sup> In order to maintain the space, many clinicians have used additional devices such as bone grafting materials and tenting screws.<sup>6-8</sup>

Cross-linking of the collagen membranes would retard its resorption to prolong its barrier effect.<sup>9</sup> However, the efficacy of these membranes is still controversial. Friedmann et al reported that on exposure, cross-linked collagen membranes maintained more grafted bone volume than e-PTFE membranes.<sup>10</sup> In contrast, Bornstein et al reported that in animal studies, cross-linked membranes showed limited bone regeneration when compared to other collagen membranes. When these membranes were exposed early, complications associated with soft tissues increased.<sup>11</sup> There are previous studies reporting the effects of the 2 types of membranes on human dehiscence defects.<sup>12-14</sup> Additionally, we appraised the 6-month control check after fitting the prosthesis, and radiographically evaluated the maintenance of the marginal bone level.

The aim of this study was to evaluate the performance of the 2 types of collagen membranes used in conjunction with GBR for dehiscence defects around implants in humans.

## MATERIALS AND METHODS

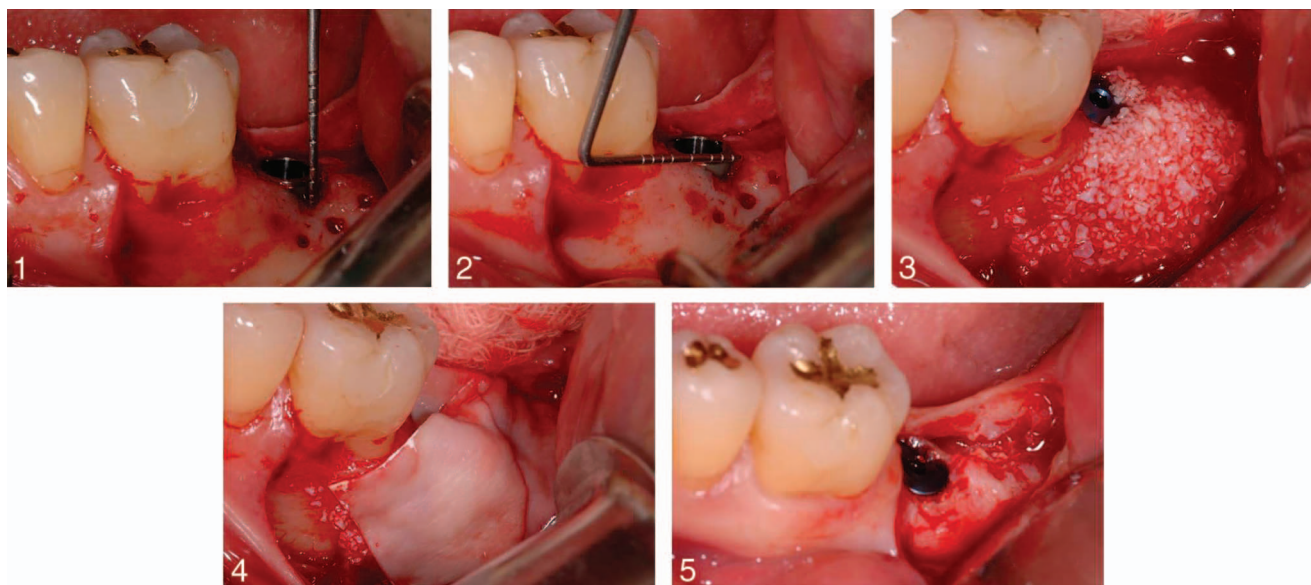
In this study, among the patients who were referred to the Department of Periodontology, Veterans Health Service Medical Center for implant placement in partially edentulous areas, the

<sup>1</sup> Department of Periodontology, Veterans Health Service Medical Center, Seoul, Korea.

<sup>2</sup> Department of Dentistry, College of Medicine, Korea University, Seoul, Korea.

\* Corresponding author, e-mail: koprosth@unitel.co.kr

DOI: 10.1563/AAID-JOI-D-13-00214



**FIGURES 1–5.** **FIGURE 1.** Measurement of the depth from the most apical aspect of the bucco-lingual crestal bone to the implant platform margin (dehiscence height). **FIGURE 2.** Measurement of the mesiodistal length of the buccal bony defect (dehiscence width). **FIGURE 3.** Bone grafting performed with autogenous or allogenic bone applied over the exposed area followed by xenogenic bone particles. **FIGURE 4.** Application of resorbable collagen membrane was performed randomly. **FIGURE 5.** At the uncovering surgery, note the newly formed buccal area.

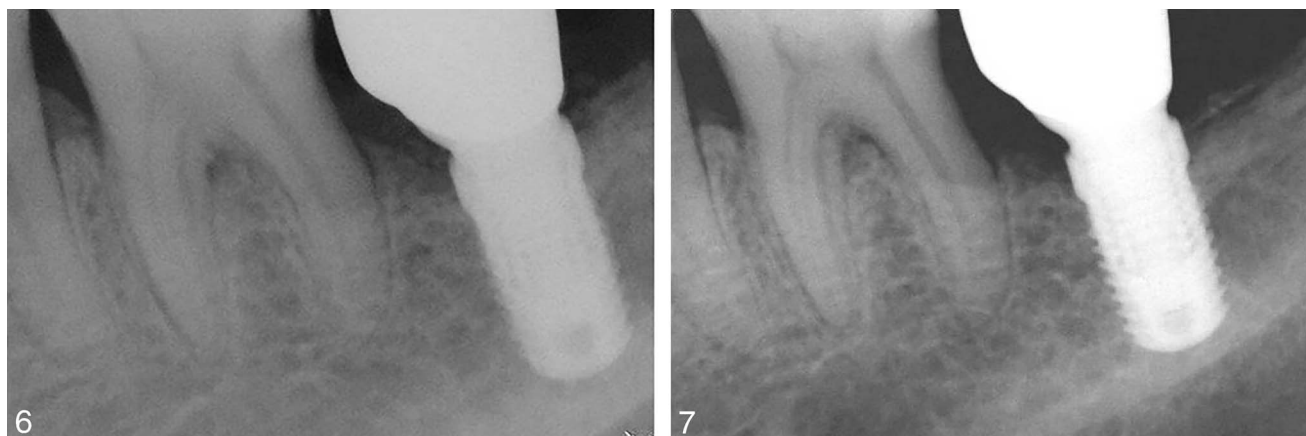
group that demanded GBR in buccal dehiscence defects along with implant placement was selected. Thirty-four patients from age 35 to 72 ( $61 \pm 7.25$ ) participated in this study. They had no systemic contraindications for implant surgery. Smokers were excluded from this study. Informed consent for participation (oral and written) was obtained from all subjects. The subjects were divided into two groups: Group CL (cross-linked, Ossix Plus,  $n = 24$  implants, 16 patients), and Group NCL (noncross-linked, Bio-Gide,  $n = 25$  implants, 18 patients). This study protocol adhered to the requirements of the Helsinki Declaration; further, this study was approved by our hospital's Institutional Review Board (BOHUN IRB No. 2013-01-033).

Pre-operative evaluation by radiographic and clinical examination revealed compromised anatomy of the local bone. Panoramic and intraoral radiographs were taken for all the subjects. When additional information was required for diagnosis, a computerized tomography (CT) scan was performed. All the surgeries were performed under local anesthesia, with midcrestal and lateral vestibular releasing incisions to reflect the mucoperiosteal flaps. Surgical stents were prepared prior to the surgery to ensure proper prosthetic restoration. The drilling was performed with a series of burs of increasing diameter, according to the surgical stent, under irrigation with sterile saline solution as per the manufacturer's recommendations. Before placement of the implants, intramarrow penetrations were performed to promote the release of growth factors on the buccal side. A standard internal type implant (Camlog, Camlog Biotechnologies AG, Wimsheim, Germany) was used throughout this study, and all implants were placed with adequate primary stability. A total of 49 dental implants was placed in 34 patients.

A periodontal probe (Williams Probe, Hu-Friedy, Chicago, Ill)

was used to measure the length of the dehiscence around the implants, as well as the defect location and dimension. At the time of implant placement, the depth from the most apical aspect of the bucco-lingual crestal bone to the implant platform margin (dehiscence height), and the mesio-distal length of the buccal bony defect (dehiscence width) were measured<sup>1</sup> (Figures 1 and 2). When several implants were placed simultaneously, their mean values were considered. The surface area of the dehiscence around the implants was computed in the same manner as in earlier studies.<sup>1,12–14</sup>

The GBR technique was applied to the buccal dehiscence defect. Autogenous or allogenic bone particles (ICB, Rocky Mountain Tissue Bank, Aurora, Colo) were applied over the exposed area followed by xenogeneic bone particles (Bio-Oss, Geistlich Phama AG, Wolhusen, Switzerland), which were resorbed relatively slowly (Figure 3). Above these layers of bone material, one of the two types of resorbable collagen membranes (Ossix Plus, Datum Dental Ltd, Telrad, Israel, or Bio-Gide, Geistlich Phama AG) was randomly used. The membranes covered the cover screw of implants at all times (Figure 4). For a tension-free primary wound closure, periosteal incisions were performed; a 5–0 nylon suture material (Blue nylon, Ailee Co, Ltd, Busan, Korea) was used for suturing and immobilizing the membranes. For chemical plaque control, patients were instructed to rinse their mouth with 0.12% chlorhexidine twice a day for 1 minute, and an antibiotic regimen was prescribed for 7 days. The sutures were removed 10 days postoperatively. During the healing period, it was difficult to measure the degree of exposure. In addition, early-exposure cases were excluded from the result analysis. The uncovering surgery was performed 4–6 months ( $5.7 \pm 2.5$ ) after the first stage surgery. The dehiscence height, width, and area at the time of the uncovering surgery were measured and calculated in the same



**FIGURES 6 AND 7.** **FIGURE 6.** Intraoral radiograph during delivery of final restoration. **FIGURE 7.** Intraoral radiographs after 6 months of prosthetic loading.

manner as in the first stage surgery (Figure 5). A statistical analysis was then performed using a software program (SPSS 12.0, SPSS Inc, Chicago, Ill). The mean values and standard deviations were calculated for each variable. The unpaired *t*-test was used for intergroup comparisons. Results were considered statistically significant ( $P < .05$ ).

Intraoral radiographs were taken during the prosthetic loading (baseline period) and the 6-month control visit using the paralleling technique. The digital caliper (PACS viewer, Lead Technologies, Charlotte, NC) was used to measure the distance from the implant-abutment junction to the peri-implant marginal bone level, which was divided into a mesial side and a distal side. We compared the bone loss level between the baseline and the 6-month control visit through radiographs (Figures 6 and 7).

## RESULTS

No complications were observed at the surgical sites except for some swelling and postoperative pain. During the uncover surgery, all grafts appeared to be fixated at the recipient site. The implants were found to be clinically immobile and were defined as osseointegrated. Table 1 describes the values of dehiscence height, width, and area at the first surgery as well as the uncover surgery.

### Group CL

At the time of suture removal, premature exposure of the membrane was seen in 2 patients (8.3%) owing to unsuccessful primary closure. Unfortunately, they had to be excluded from this study. However, there was no failure of implant installation because the operation site showed proper healing. The dehiscence height at the first stage surgery varied from 0.5 to 7.5 mm ( $3.0 \pm 1.9$ ); at the uncover surgery, it varied from 0 to 1.5 mm ( $0.2 \pm 0.5$ ). The dehiscence width at first stage surgery varied from 1 to 8 mm ( $3.9 \pm 1.3$ ); at the uncover surgery it varied from 0 to 2.5 mm ( $0.3 \pm 0.7$ ). The mean values of the marginal bone loss in radiographs between the baseline and the 6-month control visit were  $0.53 \pm 0.4$  mm on the mesial side and  $0.52 \pm 0.6$  mm on the distal side.

### Group NCL

In Group NCL, the 5 patients (13.5%) with early exposure of membranes also presented proper healing, but they were also excluded from the analysis. The dehiscence height at the first stage surgery varied from 0.5 to 6 mm ( $2.8 \pm 1.7$ ); at the uncover surgery it varied from 0 to 1 mm ( $0.4 \pm 0.3$ ). The dehiscence width at first stage surgery varied from 2 to 6 mm ( $3.8 \pm 1.2$ ); at the uncover surgery it varied from 0 to 3.5 mm ( $1.1 \pm 0.9$ ). The mean values of the marginal bone loss in radiographs between the baseline and the 6-month control visit were  $0.52 \pm 0.5$  mm on the mesial side and  $0.48 \pm 0.4$  mm on the distal side.

The difference between CL and NCL groups ( $P < .05$ ) on gains in defect height and width around implants was statistically insignificant (Table 2). Additionally, the radiographic marginal bone loss between prosthetic loading and 6 month control visit exhibited no statistically significant difference between the two groups (Table 3).

## DISCUSSION

Owing to either periodontitis or trauma, the resorption of the edentulous or partially edentulous alveolar ridge and bone loss

Dehiscence	CL*	NCL†
First-stage surgery		
Height	$3.0 \pm 1.9$	$2.8 \pm 1.7$
Width	$3.9 \pm 1.3$	$3.8 \pm 1.2$
Area	$10.5 \pm 8.6$	$9 \pm 6$
Uncover surgery		
Height	$0.2 \pm 0.5$	$0.4 \pm 0.3$
Width	$0.3 \pm 0.7$	$1.1 \pm 0.9$
Area	$0.1 \pm 0.4$	$0.5 \pm 0.7$

\*Cross-linked, Ossix Plus membrane.

†Noncross-linked, Bio-Gide membrane.

TABLE 2

Gain in the dehiscence area and height (mean values ± SD %)

Group	Gain of the Dehiscence Area	Gain of the Dehiscence Height
CL*	95.52 ± 16.37	89.69 ± 24.36
NCL†	94.01 ± 8.35	81.99 ± 16.07
P-value‡	0.842	0.908

\*Cross-linked, Ossix Plus membrane.

†Noncross-linked, Bio-Gide membrane.

‡No statistically significant difference between groups was measured via an unpaired sample t-test showing significance at  $P < .05$ .

frequently impede the placement of dental implants in an ideal position. To resolve this matter, the augmentation of the insufficient bone volume is often indicated prior to, or in conjunction with, implant placements. In many types of bone resorption, dehiscence defects cannot maintain space to resist the collapse of soft tissues during the healing process, resulting in uncertain prognosis.<sup>15</sup>

The noncross-linked collagen membrane used in Group NCL consists of Type 1 and Type 3 porcine collagen. The characteristics of this membrane are low stiffness and good biocompatibility. Hürzeler et al reported that the noncross-linked membrane maintained the structure of collagen for more than 6 months.<sup>16</sup> No signs of inflammation during wound healing appeared in this study. However, some studies reported that noncross-linked membranes have a shorter barrier ability, owing to the premature degradation of the collagen structure on unexpected wound dehiscence. Simion et al reported that exposed membranes showed significantly decreased bone regeneration (41.6% vs 96.6%).<sup>3</sup> Zitzmann et al reported that the membranes did not influence wound healing and could be dissolved rapidly when exposed.<sup>5</sup>

Another resorbable collagen membrane used in Group CL consists of purified porcine Type 1 collagen. According to manufacturers, this membrane is composed of cross-linked collagen, by using a native metabolite to maintain the functional integrity of the membrane for 6 months. Some studies have reported that such techniques produce cytotoxicity and degrade the biocompatibility of the membranes.<sup>17</sup> However, the cross-linked collagen with a native metabolite used in this study showed no cytotoxicity and maintained basic structure over a longer period.<sup>18</sup> Moreover, the cellular colonization that precedes the degradation and resorption of the collagen membrane depends on the degree of cross-linking of the membranes: the higher the degree of collagen cross-linking, the slower the degradation rate.<sup>19</sup> Therefore, it is possible to control the barrier effect of the membrane by modifying the degree of cross-linking. Moses et al reported that membranes cross-linked with ribose showed a lower degree of degradation than non-cross-linked membranes and those cross-linked with glutaldehyde.<sup>17</sup> Friedmann et al also reported that early exposed cross-linked membranes maintained more bone regeneration volume than early exposed e-PTFE.<sup>20</sup>

In contrast, some studies have reported that compared to other collagen membranes, cross-linked membranes showed

TABLE 3

Radiographic marginal bone loss (from abutment connection to peri-implant marginal bone) during 6 months loading in mm

Group	Site	
	Mesial	Distal
CL*	0.53 ± 0.46	0.52 ± 0.64
NCL†	0.52 ± 0.55	0.48 ± 0.48
P-value‡	0.418	0.92

\*Cross-linked, Ossix Plus membrane.

†Noncross-linked, Bio-Gide membrane.

‡No statistically significant difference between groups was measured via an unpaired sample t-test that showed significance at  $P < .05$ .

limited bone regeneration, and when those membranes were exposed early, soft tissue-related complications increased. Bornstein et al reported that in an animal study, cross-linked membranes showed limited bone regeneration when compared to other collagen membranes, and when those membranes were exposed early, soft tissue related complications also increased.<sup>11</sup> Becker et al also reported that cross-linked membranes demonstrated bone regeneration similar to the non-cross-linked variants, and that cross-linked membranes interfered with the wound healing process and caused soft tissue infections when exposed early.<sup>21</sup> The cross-linked collagen membranes showed slow biodegradation while the noncross-linked membranes started to lose structural integrity within 7 days. In fact, many clinicians find residues of cross-linked membranes a few months after their application.

There are limited studies reporting the effects of the two types of membranes on human dehiscence defects. Moses et al carried out experiments that were similar to this study, except for the bone grafting materials used (autogenous bone chip, bovine bone mineral, and β-tri calcium phosphate). They reported a percentage reduction of the defect area (92.2% Group CL and 94.6% Group NCL) and height (81.6 % Group CL and 85.4% Group NCL) similar to this study.<sup>22</sup> However, they did not study the period between prosthetic loading and the 6-month follow up. They computed the area by calculating that it only allowed the 2-dimensional assessment of GBR. In this study, we appraised the 6-month follow-up after mounting the prosthesis for intergroup comparisons. Although the values of marginal bone loss were not significantly different between the two groups, this study showed that a stable marginal bone was maintained for 6 months in both groups. Schwarz et al showed similar results in that the difference in length of the residual defect was statistically insignificant between the two membranes (1.5 ± 0.8 Group CL and 1.2 ± 0.6 Group NCL) in surgically performed dehiscence defects in Beagle dogs.<sup>23</sup>

During this study, most defects healed without any complications and exhibited significant bone regeneration during the uncover surgery. There were 2 cases of membrane exposure in Group CL and 5 cases in Group NCL. There are many contradicting studies on the effect of early exposure of membranes, and hence, this topic remains controversial.

In conclusion, the success of GBR was performed simulta-

neously from dehiscence defects around the implant, regardless whether collagen membranes were cross-linked or non-cross-linked.

#### ABBREVIATIONS

CL: cross-linked  
 CT: computerized tomography  
 e-PTFE: expanded polytetrafluoroethylene  
 GBR: guided bone regeneration  
 NCL: noncross-linked

#### REFERENCES

- Jovanovic SA, Spiekermann H, Richter EJ. Bone regeneration around titanium dental implants in dehiscence defect sites: a clinical study. *Int J Oral Maxillofac Implants.* 1992;7:233–245.
- De Sanctis M, Zucchelli G, Clauser C. Bacterial colonization of bioabsorbable barrier material and periodontal regeneration. *J Periodontol.* 1996;67:1193–1200.
- Simion M, Baldoni M, Rossi P, Zaffe D. A comparative study of the effectiveness of e-PTFE membranes with and without early exposure during the healing period. *Int J Periodontics Restorative Dent.* 1994;14:166–180.
- Oh TJ, Meraw SJ, Lee EJ, Giannobile WV, Wang HL. Comparative analysis of collagen membranes for the treatment of implant dehiscence defects. *Clin Oral Implants Res.* 2003;14:80–90.
- Zitzmann NU, Naef R, Scharer P. Resorbable versus nonresorbable membranes in combination with Bio-Oss for guided bone regeneration. *Int J Oral Maxillofac Implants.* 1997;12:844–852.
- Le B, Rohrer MD, Prasad HS. Screw "tent-pole" grafting technique for reconstruction of large vertical alveolar ridge defects using human mineralized allograft for implant site preparation. *J Oral Maxillofac Surg.* 2010;68:428–435.
- Misch CM. Comparison of intraoral donor sites for onlay grafting prior to implant placement. *Int J Oral Maxillofac Implants.* 1997;12:767–776.
- Wang HL, Misch C, Neiva RF. "Sandwich" bone augmentation technique: rationale and report of pilot cases. *Int J Periodontics Restorative Dent.* 2004;24:232–245.
- Brunel G, Piantoni P, Elharar F, Benque E, Marin P, Zahedi S. Regeneration of rat calvarial defects using a bioabsorbable membrane technique: influence of collagen cross-linking. *J Periodontol.* 1996;67:1342–1348.
- Friedmann A, Strietzel FP, Marezki B, Pitaru S, Bernimoulin JP. Observations on a new collagen barrier membrane in 16 consecutively treated patients. Clinical and histological findings. *J Periodontol.* 2001;72:1616–1623.
- Bornstein MM, Bosshardt D, Buser D. Effect of two different bioabsorbable collagen membranes on guided bone regeneration: a comparative histomorphometric study in the dog mandible. *J Periodontol.* 2007;78:1943–1953.
- Nemcovsky CE, Artzi Z. Comparative study of buccal dehiscence defects in immediate, delayed, and late maxillary implant placement with collagen membranes: clinical healing between placement and second-stage surgery. *J Periodontol.* 2002;73:754–761.
- Nemcovsky CE, Artzi Z, Moses O, Gelernter I. Healing of dehiscence defects at delayed-immediate implant sites primarily closed by a rotated palatal flap following extraction. *Int J Oral Maxillofac Implants.* 2000;15:550–558.
- Nemcovsky CE, Artzi Z, Moses O, Gelernter I. Healing of marginal defects at implants placed in fresh extraction sockets or after 4–6 weeks of healing. A comparative study. *Clin Oral Implants Res.* 2002;13:410–419.
- Mellonig JT, Nevins M. Guided bone regeneration of bone defects associated with implants: an evidence-based outcome assessment. *Int J Periodontics Restorative Dent.* 1995;15:168–185.
- Hurzeler MB, Kohal RJ, Naghsbandi J, et al. Evaluation of a new bioresorbable barrier to facilitate guided bone regeneration around exposed implant threads. An experimental study in the monkey. *Int J Oral Maxillofac Surg.* 1998;27:315–320.
- Moses O, Vitral D, Aboodi G, et al. Biodegradation of three different collagen membranes in the rat calvarium: a comparative study. *J Periodontol.* 2008;79:905–911.
- Klinger A, Asad R, Shapira L, Zubery Y. In vivo degradation of collagen barrier membranes exposed to the oral cavity. *Clin Oral Implants Res.* 2010;21:873–876.
- Mattson JS, McLey LL, Jabro MH. Treatment of intrabony defects with collagen membrane barriers. Case reports. *J Periodontol.* 1995;66:635–645.
- Friedmann A, Strietzel FP, Marezki B, Pitaru S, Bernimoulin JP. Histological assessment of augmented jaw bone utilizing a new collagen barrier membrane compared to a standard barrier membrane to protect a granular bone substitute material. *Clin Oral Implants Res.* 2002;13:587–594.
- Becker J, Al-Nawas B, Klein MO, Schliephake H, Terheyden H, Schwarz F. Use of a new cross-linked collagen membrane for the treatment of dehiscence-type defects at titanium implants: a prospective, randomized-controlled double-blinded clinical multicenter study. *Clin Oral Implants Res.* 2009;20:742–749.
- Moses O, Pitaru S, Artzi Z, Nemcovsky CE. Healing of dehiscence-type defects in implants placed together with different barrier membranes: a comparative clinical study. *Clin Oral Implants Res.* 2005;16:210–219.
- Schwarz F, Rothamel D, Herten M, et al. Immunohistochemical characterization of guided bone regeneration at a dehiscence-type defect using different barrier membranes: an experimental study in dogs. *Clin Oral Implants Res.* 2008;19:402–415.