

CBCT Morphologic Analysis of Edentulous Posterior Mandible for Mandibular Body Bone Graft

Jae-Min Song, DDS, MSD, PhD¹
 Jae-Yeol Lee, DDS, MSD, PhD^{1,2}
 Yong-Deok Kim, DDS, MSD, PhD^{2,3*}

INTRODUCTION

Intramembranous autogenous bone graft is the gold standard for reconstructing the alveolar bone after tooth loss or removal.^{1,2} The donor sites most often accessed for autogenous bone graft material include the mandibular symphysis, the ramus, the mandibular body, and others.^{3,4} Among these donor sites, the mandibular body offers several advantages, such as an intraoral approach for surgical access, enabling the clinician to operate in the same field as that of the recipient site; a low resorption rate and short healing period (because of its cortical characteristics); obviation of horizontal osteotomy near the root apex; and reduced risk of nerve injury.^{1,3-5}

Despite such advantages, in many cases, surgeons hesitate to use mandibular body bone (MBB) graft because of the relatively high incidence (3.9%–39%) of postoperative neurosensory disturbance occurring after third-molar removal involving the mandibular posterior region,⁶ sagittal split osteotomy,⁷ or bone graft harvest from the ramus.⁸ Especially in cases of alveolar bone resorption after tooth loss in the edentulous posterior mandible, utilizing the unilateral MBB (located directly inferior to the recipient site) as a donor site will prove efficacious.

The aim of this study was to use cone-beam computerized tomography (CBCT) to analyze anatomical data on the edentulous posterior mandible and, on that basis, to determine the safety and utility of MBB as an autogenous bone graft material.

MATERIALS AND METHODS

Study subjects

The study was conducted from March 2010 to June 2012. The subjects were 40 patients from the outpatient department of Pusan National University Dental Hospital who had undergone MBB graft. The subjects were each evaluated for number of

extracted teeth, length of edentulous period, and postoperative complications (Table 1).

Methods

Reconstitution of 3-Dimensional Images

Preoperative CBCT images were acquired using DCT pro (Vatech Co, Seoul, Korea). The scan exposure time was 24 seconds, the exposure parameters were 105 kVp and 6.5 mAs, the interval was 0.3 mm, the field of view was 19 × 20 inches, and the basic voxel size was 0.5 × 0.5 × 0.5 mm³. Before taking CBCT image, the patients wear a temporary radiographic stent that was fabricated by a vacuum-type acrylic plate after diagnostic wax-up in edentulous ridge. A metal ball 5 mm in diameter was inserted in the stent and fixed by utility wax. The images were processed to a DICOM (digital imaging and communications in medicine) 3.0 file. Horizontal section images taken parallel to the scan plane passing through the center of the metal balls (diameter: 5 mm) were obtained via Simplant (Materialise Inc, Leuven, Belgium), a 3-dimensional (3D) image analysis program (Figure 1).

Evaluation Sites and Quantitative Assessment

Measurements were performed at the center of the metal balls representing the specific proposed areas of the second premolar, first molar, and second molar as well as at the anterior border of the ramus. The vertical distance was measured parallel to the tooth axis regarded as a line between the buccal cusp tip and the root apex of the mesial tooth (Figure 1).

Measurement Parameters

The following measurement parameters were used (Figure 2):

1. Buccolingual width of alveolar bone 3 mm below alveolar crest
2. Distance from the upper aspect of the mandibular canal to the alveolar crest
3. Distance from the buccal aspect of the mandibular canal to the buccal cortex
4. Buccal cortical bone thickness 5 mm below the alveolar crest
5. Buccal cortical bone thickness at the height of the contour of the mandible
6. Buccal cortical bone thickness 5 mm above the inferior border of the mandible

¹ Biomedical Research Institute, Pusan National University Hospital, Busan, Korea.

² Department of Oral and Maxillofacial Surgery, Dental Research Institute, School of Dentistry, Pusan National University, Yangsan, Korea.

³ Institute of Translational Dental Sciences, Pusan National University, Yangsan, Korea.

* Corresponding author, e-mail: ydkimdds@pusan.ac.kr

DOI: 10.1563/AAID-JOI-D-13-00215

TABLE 1
Study subjects

Subjects	No.	Age (y)	No. of Extracted Teeth	Time of Edentulous State (y)
Men	18	53.41 ± 7.34	3.93 ± 2.02	5.62 ± 3.83
Women	22	50.0 ± 8.14	3.62 ± 1.69	8.46 ± 4.80
Total	40	52.23 ± 7.64	3.82 ± 1.87	5.88 ± 4.40

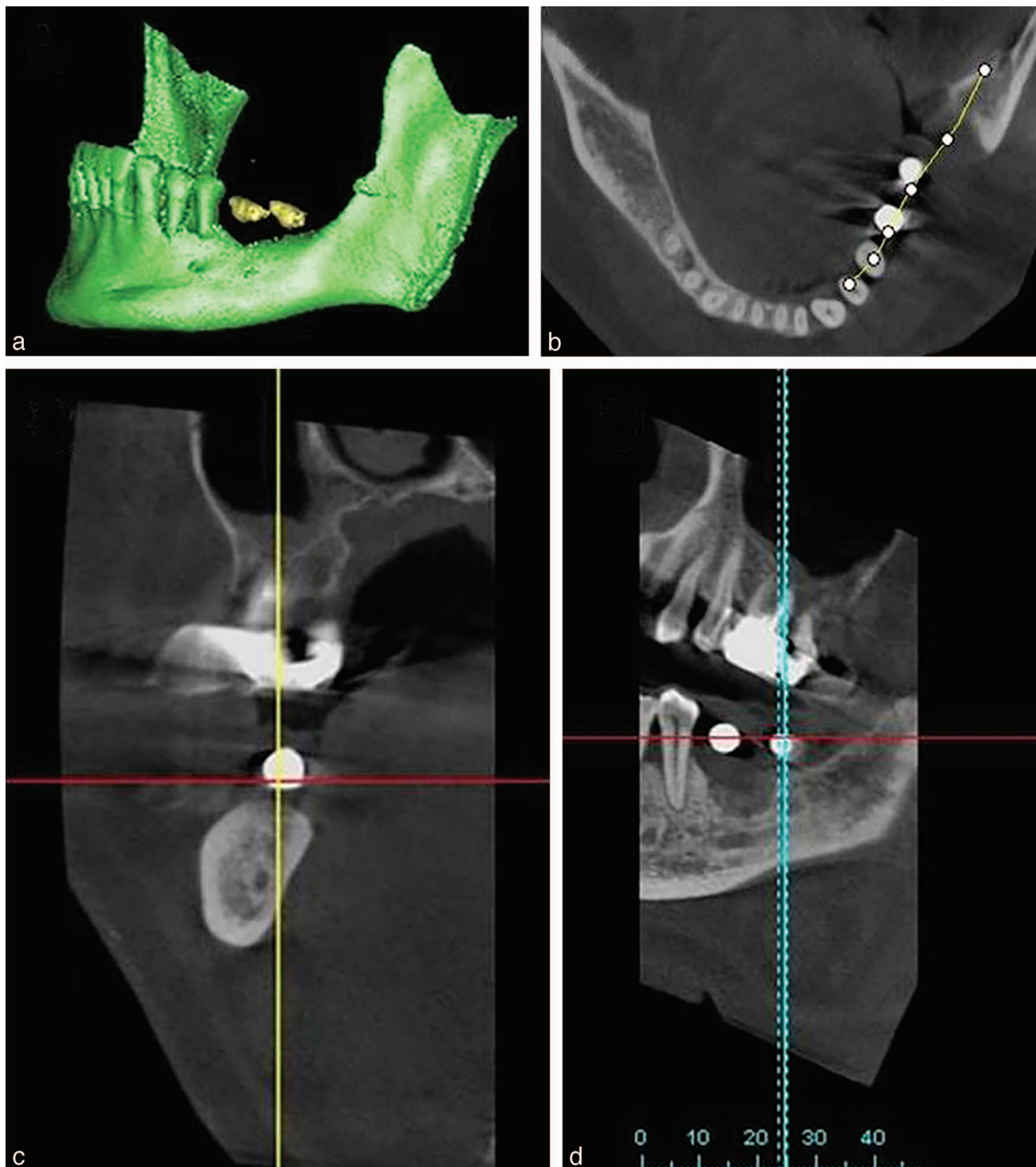


FIGURE 1. Converted images (Simplant program). (a) 3-dimensional image. (b) Axial image. (c) Cross-sectional image. (d) Panoramic image.

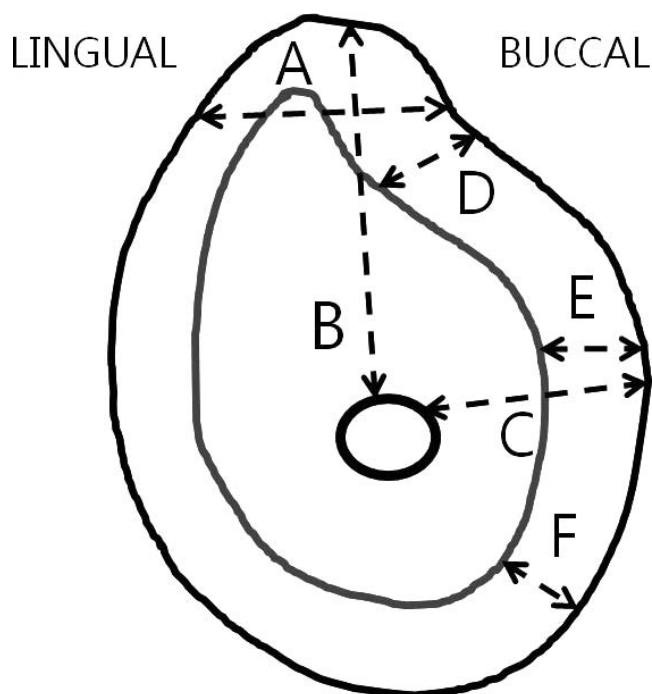


FIGURE 2. Measuring points and measurements in cross-sectional images. (A) Buccolingual width of alveolar bone 3 mm below the alveolar crest. (B) Distance from the upper aspect of the mandibular canal to the alveolar crest. (C) Distance from the buccal aspect of the mandibular canal to the buccal cortex. (D) Buccal cortical bone thickness 5 mm below the alveolar crest. (E) Buccal cortical bone thickness at the height of the contour. (F) Buccal cortical bone thickness 5 mm above the inferior border.

Statistical analysis

For each of the parameters, the mean value and standard deviation were calculated. Following a quantitative assessment of cortical bone thickness (measurement parameters 4–6), an analysis of variance (ANOVA) test was performed using SPSS version 12 (SPSS Inc, Chicago, Ill) to identify any significant differences between the sites of interest. All parameters were measured twice by one examiner, 48 hours apart, using a paired *t* test to reveal any systematic error. The paired data showed a mean difference of .0038, indicating no significant differences between the paired data or, therefore, systematic errors in the interpretation of the results.

RESULTS

The study population consisted of 18 men and 22 women with a mean age of 52.23 ± 7.64 years (men = 53.41 ± 7.34 ; women

= 50.0 ± 8.14). The mean number of teeth lost was 3.82 ± 1.87 (men = 3.93 ± 2.02 ; women = 3.62 ± 1.69), and the average length of edentulous period was 5.88 ± 4.40 years (men = 5.62 ± 3.83 years; women = 8.46 ± 4.80 years).

Buccolingual width of alveolar bone 3 mm below the alveolar crest

The buccolingual width of the alveolar bone was 6.26 ± 1.42 mm at the premolar site, 6.70 ± 1.50 mm at the first molar site, 7.51 ± 2.18 mm at the second molar site, and 10.98 ± 1.81 mm at the anterior border of the ramus (Table 2).

Vertical distance from the upper aspect of the mandibular canal to the alveolar crest

The vertical distance from upper aspect of the mandibular canal to the alveolar crest was 13.26 ± 3.15 mm at the premolar site, 12.67 ± 3.17 mm at the first molar site, 11.26 ± 3.61 mm at the second molar site, and 10.82 ± 3.30 mm at the anterior border of the ramus (Table 2).

Transverse distance from the buccal aspect of the mandibular canal to the buccal cortex

The transverse distance from the buccal aspect of the mandibular canal to the buccal cortex was 2.50 ± 0.57 mm at the premolar site, 4.31 ± 1.06 mm at the first molar site, 5.51 ± 1.22 mm at the second molar site, and 6.28 ± 1.15 mm at the anterior border of the ramus (Table 2).

Buccal cortical bone thickness

Buccal cortical bone thickness was measured at the following locations: 5 mm below the alveolar crest, level of the mandibular height of the contour, and 5 mm above the inferior border of the mandible (Tables 3 and 4). The thickness 5 mm below the alveolar crest was 1.89 ± 0.48 mm at the premolar site, 2.08 ± 0.68 mm at the first molar site, 2.64 ± 0.93 mm at the second molar site, and 3.52 ± 1.02 mm at the anterior border of the ramus. The thickness at the level of the mandibular height of the contour was 1.96 ± 0.41 mm at the premolar site, 2.29 ± 0.52 mm at the first molar site, 2.51 ± 0.67 mm at the second molar site, and 2.59 ± 0.65 mm at the anterior border of the ramus. The thickness measured 5 mm above the inferior border of the mandible was 2.28 ± 0.50 mm at the premolar site, 2.41 ± 0.51 mm at the first molar site, 2.46 ± 0.62 mm at the second molar site, and 2.62 ± 0.61 mm at the anterior border of the ramus.

An ANOVA was used to test for the statistically significant differences among the buccal cortical bone thicknesses at the

TABLE 2

Summary of measurements

	Premolar (n = 20)	First Molar (n = 32)	Second Molar (n = 37)	Ramus (n = 38)
Buccolingual width of alveolar bone 3 mm below alveolar crest	6.26 ± 1.42	6.70 ± 1.50	7.51 ± 2.18	10.98 ± 1.81
Distance from the upper aspect of the mandibular canal to the alveolar crest	13.26 ± 3.15	12.67 ± 3.17	11.26 ± 3.61	10.82 ± 3.30
Distance from the buccal aspect of the mandibular canal to the buccal cortex	2.50 ± 0.57	4.31 ± 1.06	5.51 ± 1.22	6.28 ± 1.15

TABLE 3

Summary of buccal cortical bone thicknesses

	Premolar (n = 20)	First Molar (n = 32)	Second Molar (n = 37)	Ramus (n = 38)
Buccal cortical bone thickness 5 mm below the alveolar crest	1.89 ± 0.48	2.08 ± 0.68	2.64 ± 0.93	3.52 ± 1.02
Buccal cortical bone thickness at the height of the contour	1.96 ± 0.41	2.29 ± 0.52	2.51 ± 0.67	2.59 ± 0.65
Buccal cortical bone thickness 5 mm above the inferior border	2.28 ± 0.50	2.41 ± 0.51	2.46 ± 0.62	2.62 ± 0.61

different sites. The results indicated that at the premolar site, the thickness was significantly different from those 5 mm below the alveolar crest and 5 mm above the inferior border of the mandible ($P < .05$). At the molar site, no statistically significant differences were observed. By contrast, the buccal cortical bone thickness at the anterior border of the ramus was significantly higher 5 mm below the alveolar crest than at the other 2 sites ($P < .05$).

As for postoperative complications, one patient among the 40 showed paresthesia.

DISCUSSION

In this study, the MBB was used as an intraoral donor site for reconstructing the edentulous posterior mandible (Figure 3). Anatomical data on the edentulous posterior mandible is the key to safe and efficient harvesting of an autogenous bone graft from the mandibular body and, thereby, avoiding complications, including neurosensory disturbances involving the inferior alveolar nerve. Such data, however, remains limited despite its importance. The present study, therefore, employed preoperative CBCT with a 3D imaging program for the purposes of an anatomical analysis of the edentulous posterior mandible.

The buccolingual width of the alveolar bone was 6.26 ± 1.42 mm at the premolar site, 6.70 ± 1.50 mm at the first molar site, 7.51 ± 2.18 mm at the second molar site, and 10.98 ± 1.81 mm at the anterior border of the ramus. Carlsson and Persson⁹ have shown that alveolar ridge resorption occurs at about 4 mm in the first year and 0.5 mm per year along with continuous, progressive resorption for 5 years. In the present study, the mean duration of tooth loss was 5.88 ± 4.40 years. Based on these data, clinicians should consider the diameter and position of implant fixtures and the extent of ridge resorption in determining whether autogenous bone veneering should be planned for the atrophic mandible.

The mean vertical distance from the mandibular canal to the alveolar crest was 13.26 mm at the premolar site and 10.82 mm at the anterior border of the ramus. Such a decrease in distance posteriorly indicates that, in the posterior portion of the mandible, the mandibular canal runs obliquely downward and forward. Tallgren et al¹⁰ reported that the height of the residual ridge following tooth loss decreases by 0.5 mm per year and does so continuously, typically resulting in a 6.8-mm reduction 5 years after tooth loss. In consideration of such alveolar ridge height reduction with respect to postextraction time duration and measurements at the different sites obtained in the present study, surgeons can decide whether to perform a particular length of onlay bone graft for placement of implant fixtures.

The transverse distance from the buccal aspect of the mandibular canal to the buccal cortical bone increased posteriorly, which confirms that the inferior alveolar nerve is located more buccally as it runs forward. Several studies have reported that neurosensory deficit is correlated with the distance from the mandibular canal to the buccal cortex of the mandible. Tomas,¹¹ in a radiographic mandible study, found no evidence of cancellous bone in 19.5% of cases. Ylikontiola et al¹² evaluated panoramic radiographs and CT scans of 20 patients who had received bilateral sagittal split osteotomy; they reported that among the 8 patients in which the cancellous bone was 2 mm or less, 7 patients had neurosensory disturbance. Yamamoto et al¹³ also assessed preoperative CT scans of 20 patients who underwent bilateral sagittal split osteotomy and found a definite increase in the incidence of nerve injury when the distance from the mandibular canal to the buccal cortex was 0.8 mm or less. The present study's numerical values, derived by subtracting the thickness of the buccal cortex from the mandibular foramen to the buccal cortex, were 0.61 mm at the premolar site, 1.41 mm at the first molar site, 3.00 mm at the second molar site, and 3.69 mm at the anterior border of the ramus. This result guarantees that the surgeon can harvest the bone graft safely in the area posterior to the molar.

We also measured the thickness of the buccal cortex at 3 different sites: 5 mm below the alveolar crest, at the level of the mandibular height of the contour, and 5 mm above the inferior border of the mandible.¹⁴ Mandibular cortex thickness has been measured by several authors.¹⁵⁻¹⁹ Miyamoto et al¹⁵ reported 2.2 mm as the mean thickness of the cortex of the complete edentulous mandible. Katranji et al¹⁶ examined edentulous human cadavers and found cortical bone thicknesses of 1.78 ± 0.74 mm at the premolar site, 2.06 ± 0.69 mm at the first molar site, and 2.06 ± 0.69 mm at the second molar site. Also, Leong et al¹⁷ reported 2.43 ± 0.75 mm for the first

TABLE 4

Analysis of variance test of buccal cortical bone thickness

	Premolar (n = 20)	First Molar (n = 32)	Second Molar (n = 37)	Ramus (n = 38)
D E	.050	.317	.749	.000**
E F	.001*	.068	.585	.000*
E F	.379	.709	.963	.631

D indicates buccal cortical bone thickness 5 mm below the alveolar crest; E, buccal cortical bone thickness at the height of the contour; F, buccal cortical bone thickness 5 mm above the inferior border.

*Significant difference between D and F.

**Significant difference between D and E.

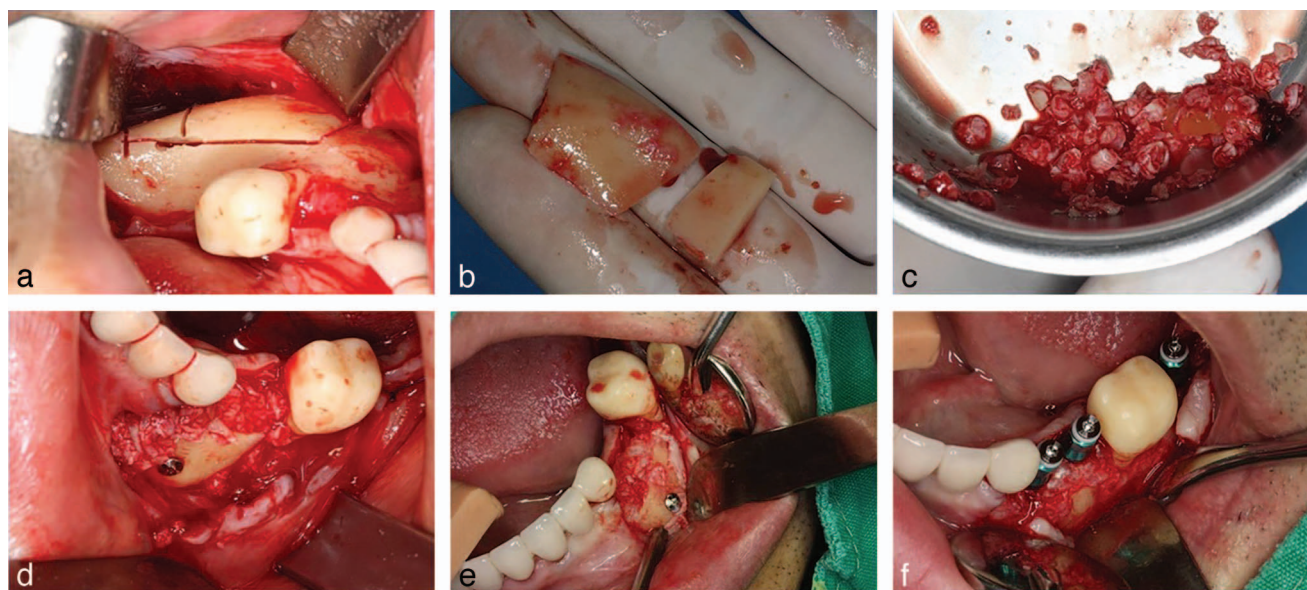


FIGURE 3. Clinical photographs of the procedure of mandibular body bone graft for atrophic mandible. (a–c) Harvesting of mandibular body bone and particulated bone using bone mill. (d) Augmented atrophic site. (e and f) After a healing period of 4 months, implants were installed on the grafted site.

molars, 2.88 ± 0.80 mm for the second molars, and 2.26 ± 0.36 mm for the ramus area in edentulous mandibular posterior sextants. Similarly, the present data showed that the thickness at the level of the mandibular height of the contour was 1.96 ± 0.41 mm at the premolar site, 2.29 ± 0.52 mm at the first molar site, 2.51 ± 0.67 mm at the second molar site, and 3.88 ± 1.16 mm at the anterior border of the ramus. The consistency between our results and those derived from other studies, with the exception of the ramus area, is an acceptable 2–3 mm. The relatively large ramus-area difference between the present result and that of Leong et al¹⁷ can be explained by the different measurement sites. Whereas we measured thickness in the more posterior region, particularly the anterior border of the ramus, Leong and colleagues assessed the thickness in the retromolar area.

On the sagittal sections, the thickness of the buccal cortex at 3 distinct molar sites (upper, middle, lower part) showed no significant differences. At the premolar site, the buccal cortex 5 mm below the alveolar crest was thinner than that 5 mm above the inferior border of the mandible, and the difference was statistically significant. At the anterior border of the ramus, the buccal cortex 5 mm below the alveolar crest was wider than that at the other sites, and the difference, again, was statistically significant. Thus, it can be established that at the premolar site, the buccal cortex of the alveolar bone, in which bone resorption after tooth loss has initiated, can be thinner than the cortex surrounding the mental foramen. Moreover, the actual figure, <2 mm, makes the buccal cortex of the alveolar bone an unsuitable donor site for bone grafts. In consideration of the anatomical morphology of the mandible, we can tentatively confirm that at the anterior border of the ramus, the site 5 mm below the alveolar crest (the upper portion of the mandible) has sufficient cortical bone. Accordingly, by extending the boundary of the osteotomy line beyond the ramus area,

more than 20–25 mm of block bone, including the molar site, can be harvested.

The outcomes of the present study demonstrate that cortical bone 2 mm in thickness and 20–25 mm in width can be successfully obtained from the edentulous posterior mandible, and that patients with severe bone loss who are candidates for iliac bone graft can be treated by MBB graft under local anesthesia. The most common complications of MBB graft are neurosensory disturbances. In this study, only one patient experienced neurotmesis. In radiographics, the patient's inferior alveolar nerve was positioned buccally and the cortical bone was thinner than that of other patients. Before the procedure, it will be necessary to identify the position of the inferior alveolar nerve buccolingually using dental CT. With the exception of 1 patient, no one suffered paresthesia. Besides neurosensory disturbance, patients' cosmetic concerns about a lack of volumetric support due to the loss of cortical bone, or discomfort upon palpation, need to be considered as well. However, in the present investigation, none of the patients complained of any symptoms during the postoperative follow-up at 6 months to 1 year (Figure 4). Nevertheless, such issues demand further investigation, observation, and research.

CONCLUSIONS

Assessment of the preoperative CBCT data of patients who had received an MBB graft was conducted with the Simplant program, specifically for anatomical analysis of the atrophic mandible and verification of the utility of the MBB graft. The results of the analysis of sagittal section images suggested the following.

1. The buccolingual width of the alveolar bone increased posteriorly by 6.26 ± 1.42 mm at the premolar site, $6.70 \pm$

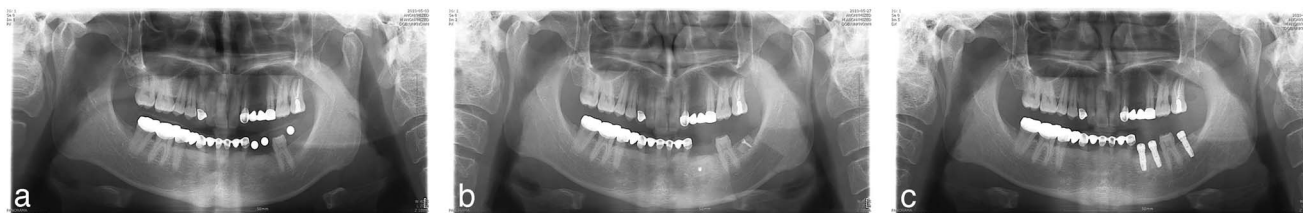

FIGURE 4. Postoperative change of the mandibular body bone donor site. (a) Preoperative assessment for atrophic mandible. (b) Mandibular body bone was harvested and augmented from the same side, postoperative pod 1 day. (c) After installation of implants, pod 4 months.

- 1.50 mm at the first molar site, 7.51 ± 2.18 mm at the second molar site, and 10.98 ± 1.81 mm at the anterior border of the ramus (actual values).
- The vertical distance from the upper aspect of the mandibular canal to the alveolar crest decreased posteriorly by 13.26 ± 3.15 mm at the premolar site, 12.67 ± 3.17 mm at the first molar site, 11.26 ± 3.61 mm at the second molar site, and 10.82 ± 3.30 mm at the anterior border of the ramus (actual values).
 - The transverse distance from the buccal aspect of the mandibular canal to the buccal cortical bone was 2.50 ± 0.57 mm at the premolar site, 4.31 ± 1.06 mm at the first molar site, 5.51 ± 1.22 mm at the second molar site, and 6.28 ± 1.15 mm at the anterior border of the ramus (actual values).
 - Measurements of the buccal cortical bone thickness indicated that the premolar site is not suitable for a bone graft donor site but that cortical bone of more than 2 mm thickness and 20–25 mm width can be harvested from areas posterior to it.
 - Despite a patient’s atrophic mandible, a surgeon can gain an amount of cortical bone sufficient for the bone graft; additionally, by calculating the distance from the nerve canal using preoperative CBCT data and a 3D imaging program, the safety of this surgical procedure can be improved.

ABBREVIATIONS

- 3D: 3-dimensional
 ANOVA: analysis of variance
 CBCT: cone-beam computerized tomography
 CT: computerized tomography
 MBB: mandibular body bone

REFERENCES

- D’Addona A, Nowzari H. Intramembranous autogenous osseous transplants in aesthetic treatment of alveolar atrophy. *Periodontol* 2000. 2001;27:148–161.
- Boyne PJ, Cole MD, Stringer D, et al. A technique for osseous

restoration of deficient edentulous maxillary ridge. *J Oral Maxillofac Surg*. 1985;43:87–91.

- Misch CM. Comparison of intraoral donor sites for onlay grafting prior to implant placement. *Int J Oral Maxillofac Implants*. 1997;2:767–776.
- Williamson RA. Rehabilitation of the resorbed maxilla and mandible using autogenous bone grafts and osseointegrated implants. *Int J Oral Maxillofac Implants*. 1996;11:476–488.
- Aalam AA. Mandibular cortical bone grafts. Part 1: anatomy, healing process, and influencing factors. *Compend Contin Educ Dent*. 2007;28:206–212.
- Bataineh AB. Sensory nerve impairment following mandibular third molar surgery. *J Oral Maxillofac Surg*. 2001;59:1012–1017.
- Westermarck A, Bystedt H, von Konow L. Inferior alveolar nerve function after mandibular osteotomies. *Br J Oral Maxillofac Surg*. 1998;36:425–428.
- Silva FMS, Cortez AVL, Moreira RWF, et al. Complications of intraoral donor site for bone grafting prior to implant placement. *Implant Dent*. 2006; 15:420–426.
- Carlsson GE, Persson G. Morphologic changes of the mandible after extraction and wearing of dentures. *Odontol Revy*. 1967;18(1):27–54.
- Tallgren A, Lang BR, Walker GF, et al. Roentgen cephalometric analysis of ridge resorption and changes in jaw and occlusal relationships in immediate complete denture wearers. *J Oral Rehabil*. 1980;7(1):77–94.
- Tomas F. Position of the mandibular canal. *Int J Oral Maxillofac Surg*. 1987;16:65–69.
- Ylikontti L, Moberg K, Huuomoni S, et al. Comparison of three radiographic methods used to locate the mandibular canal in buccolingual direction before sagittal osteotomy. *Oral Surg Oral Med Oral Pathol Oral Radiol Endod*. 2001;93:736–742.
- Yamamoto R, Nakamura A, Ohno K, et al. Relationship of the mandibular canal to the lateral cortex of the mandibular ramus as a risk factor in the development of neurosensory disturbance after bilateral sagittal split osteotomy. *J Oral Maxillofac Surg*. 2002;60:490–495.
- Smith BR, Raichel JL, Waite DE, et al. Mandibular anatomy as it relates to rigid fixation of the sagittal ramus split osteotomy. *J Oral Maxillofac Surg*. 1991;49:222–226.
- Miyamoto I, Tsuboi Y, Wada E, et al. Influence of cortical bone thickness and implant length on implant stability at the time of surgery—clinical, prospective, biomechanical, and imaging study. *Bone*. 2005;37:776–780.
- Katranji A, Misch K, Wang HL. Cortical bone thickness in dentate and edentulous human cadaver. *J Periodontol*. 2007;78:874–878.
- Leong DJM, Li J, Moreno I, et al. Distance between external cortical bone and mandibular canal for harvesting ramus graft: a human cadaver study. *J Periodontol*. 2010;81:239–243.
- Carter TB, Frost DE, Tucker M, et al. Cortical thickness in human mandible: clinical relevance to the sagittal split ramus osteotomy. *Int J Adult Orthodon Orthognath Surg*. 1991;6:257–260.
- Deguchi T, Nasu M, Murakami K, et al. Quantitative evaluation of cortical bone thickness with computed tomographic scanning for orthognathic implants. *Am J Orthod Dentofacial Orthop*. 2006;129:721.e7–721.e12.