

Concealed Jiggling Effect: A Novel Risk Factor for Complications of Implant-Supported Fixed Partial Denture

Ryu Nakajima, DDS, PhD¹
 Kenji Maekawa, DDS, PhD¹
 Wataru Sonoyama, DDS, PhD¹
 Akihiro Ueda, DT²
 Takuo Kuboki, DDS, PhD^{1*}

INTRODUCTION

Numerous reports have identified risk factors for biological and technical complications of an implant-supported prosthesis (ISP).¹⁻⁴ A major concern when planning an ISP is to achieve an optimal occlusal balance between normal dentition and implants, mainly because of mobility difference. Teeth with a healthy periodontal condition can move 25–100 μm ,⁵ whereas osseointegrated implants can move only 10 μm in the apical direction.⁶ Therefore, unification of implant and natural tooth has been discouraged.⁷

In order to decrease stress on ISPs, there is agreement that the occlusal scheme should be designed to decrease cuspal interferences, centralize forces along the long axis, and minimize lateral forces.⁸ Accomplishment of such a balanced occlusion is usually not problematic when the remaining dentition presents in a favorable condition and when ISPs replace a small edentulous area. However, when the periodontal condition is suboptimal, occlusal overloading forces are a major factor involved in tooth and ISP complications, and further meticulous occlusal adjustment is recommended to prevent future complications.

Additionally, parafunctional habits, such as clenching and sleep bruxism (tooth grinding) have also been reported to be significant aggravating factors associated with complications of ISPs.^{9,10} Although there is no definitive treatment to manage such parafunctions, current approaches focus on protecting teeth or prosthesis by intraoral occlusal stabilization splints (OSSs). However, some patients are reluctant to use an OSS because it feels uncomfortable during sleep.

In this article, we present a case in which no abnormal tooth mobility could be identified at initial clinical examination, but subsequent follow-up returns revealed that the patient presented a dramatic tooth mobility during laterotrusion under extreme clenching force. Because of this particular habit, we experienced successive complications of temporary and permanent ISPs. Because the tooth mobility was not detected at

the initial clinical examination, we propose calling such phenomenon a “concealed jiggling effect.” In addition, we propose a definition and diagnostic criteria for this effect and point to it as a novel risk factor for complications of ISP.

CASE DESCRIPTION

A 67-year-old male patient was referred to Okayama University Hospital for periodontal treatment at the Department of Periodontics and Endodontics in April 2004. The patient had severe periodontal disease, and, after extraction of hopeless teeth and completion of periodontal treatment, he was referred to the Department of Fixed Prosthodontic in February 2007 for oral implant rehabilitation. As a routine clinical practice, a complete clinical history, intraoral examination, and preoperative examination were performed. Additionally, informed consent was obtained before implant surgery. Figure 1 shows the patient's preoperative intraoral condition, and Figure 2 shows the preoperative panoramic radiographic image. The patient presented no medical or surgical contraindication for implant placement. Remarkable occlusal wear could be observed in the remained teeth, which led us to suspect a tooth-grinding habit, despite the patient's denial.

TREATMENT

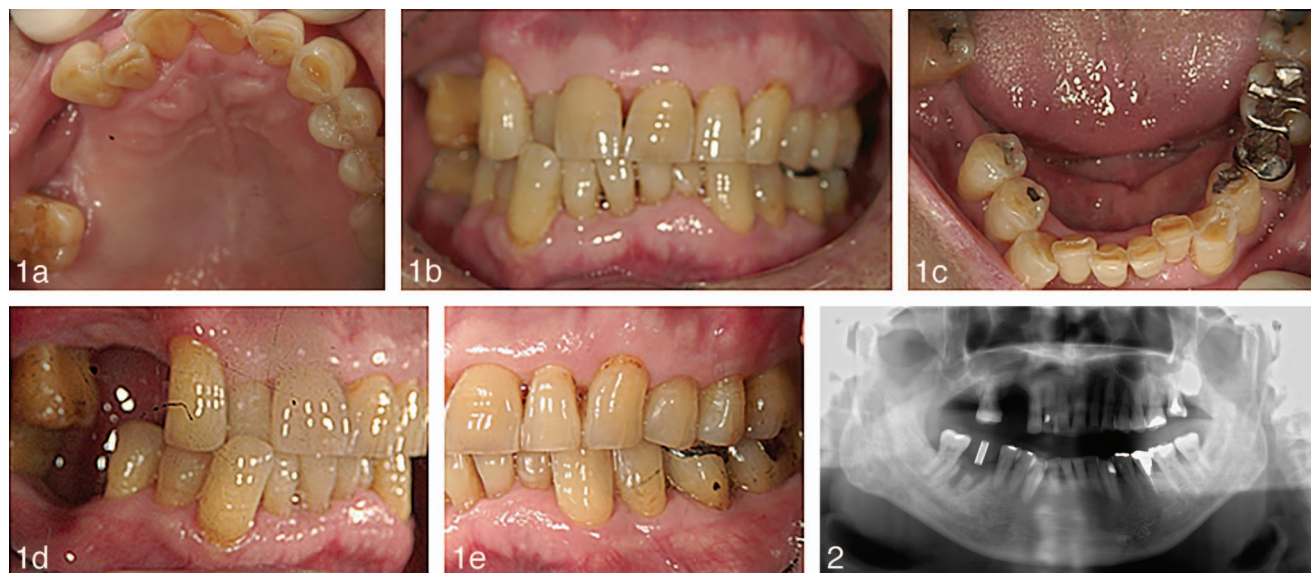
The computed tomographic images (Figure 3) show that bone volume at the surgical zone of the right maxillary first premolar and right mandibular molar sites presented sufficient width and length to accommodate a narrow platform (NP) implant ($\text{Ø}3.3 \times 11.5$ mm Brånemark Mk III TiUnite, Nobel Biocare, Sweden) and regular platform (RP) implant ($\text{Ø}3.75 \times 11.5$ mm Brånemark Mk III TiUnite, Nobel Biocare), respectively. However, vertical bone between the alveolar crest and sinus floor was 3 mm high at the right maxillary sinus area corresponding to the second premolar. Thus, the sinus augmentation procedure was carried out in March 2007, and implants were surgically placed at the right mandible molar region in May 2008, followed by the second-stage surgery in August 2008, and installation of a screw-retained provisional restoration using a Temporary Abutment Engaging (Nobel Biocare) in October 2008.

Regarding the right maxillary premolar region, implants (first premolar: $\text{Ø}3.3 \times 11.5$ mm NP; second premolar: $\text{Ø}3.75 \times 7$ mm RP) were placed in March 2009, and provisional

¹ Department of Oral Rehabilitation and Regenerative Medicine, Okayama University Graduate School of Medicine, Dentistry, and Pharmaceutical Sciences, Okayama, Japan.

² Dental Laboratories, Hospital Medical Technology Part, Okayama University Hospital, Okayama, Japan.

* Corresponding author, e-mail: kuboki@md.okayama-u.ac.jp
 DOI: 10.1563/AAID-JOI-D-13-00216



FIGURES 1 AND 2. FIGURE 1. Intraoral view of the preoperative condition: occlusal wear of remaining teeth, which was suspected to be caused by the patient’s teeth-grinding habit, as nocturnal bruxism was observed. (a) Maxillary occlusal view. (b) Frontal view. (c) Mandibular occlusal view. (d) Right lateral view. (e) Left lateral view. **FIGURE 2.** Panoramic radiographs of the preoperative condition. Moderate to severe bone loss was observed in all remaining teeth.

restorations were cemented with a Temporary Abutment Non-Engaging (Nobel Biocare) in November 2009 after a second-stage surgery was performed in October 2009.

Repeated technical complications of implant-supported prostheses

After installation of provisional restorations, numerous technical complications occurred at the right maxillary and mandibular implant regions. At the mandibular molar region, peri-implant mucositis was observed 9 months after installation of the provisional restoration because of screw loosening. The provisional restoration (35 Ncm) was tightly torqued, and more detailed occlusal adjustment was then performed. However, screw loosening reoccurred after 14 months, and the provisional restoration was reconnected for the third time (35 Ncm). Finally, no complications were observed at this region for almost 2 years.

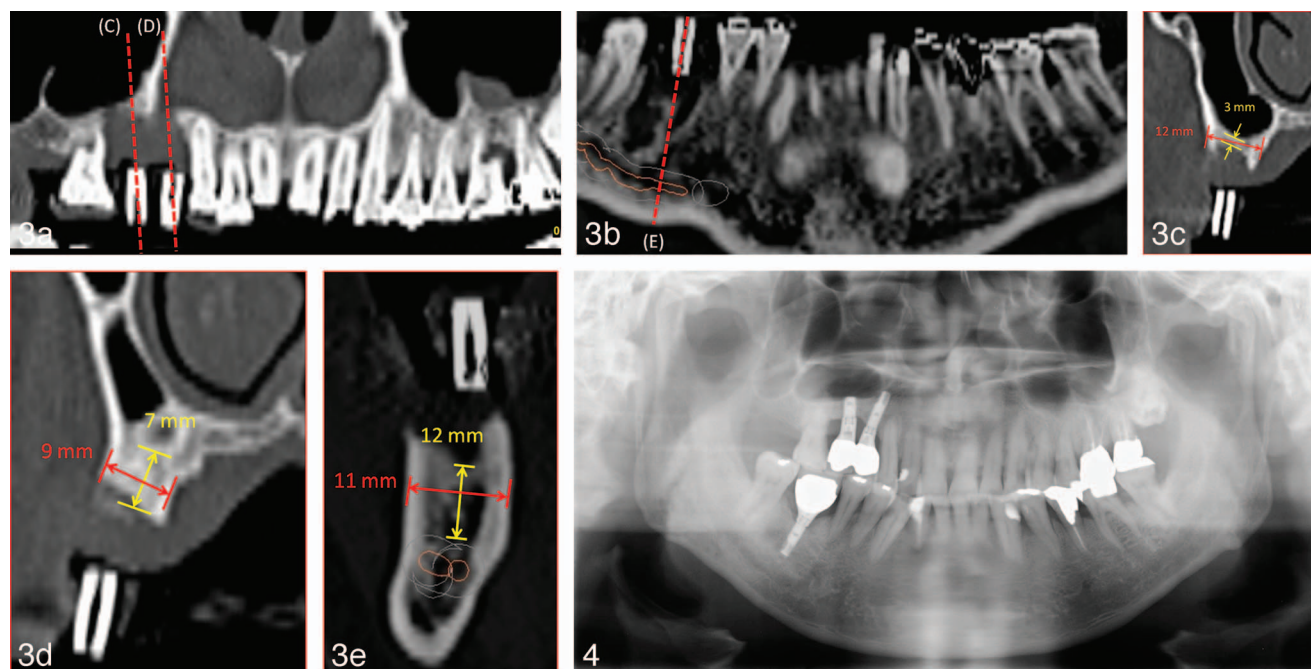
Regarding the right maxillary premolar region, a good course was observed after installation of the screw-retained provisional restorations; therefore, we decided to proceed to the final restorations, which were designed to be interconnected and cemented. We decided to use connected crowns corresponding to the upper right premolars because of the small bone volume around the implants and to achieve a better biting force. Final individualized computer-aided design/computer-aided manufacturing (CAD/CAM) abutments (NobelProcera Abutment Titanium, Nobel Biocare) were then placed and torqued (first premolar region: 20 Ncm; second premolar region: 35 Ncm), and fit accuracy was confirmed clinically and by periapical radiographs. Screw access channels were then sealed with cotton, and provisional restorations fabricated with self-curing resin were cemented onto these abutments using Hy-Bond Temporary Cement Hard (Shofu, Kyoto, Japan) in June

2010. However, 1 week after cementation, the provisional restorations lost their retention. At the same time, provisional restoration placed at the mandibular molar region disconnected 4 consecutive times, despite meticulous occlusal adjustments.

In July 2010, the final individualized CAD/CAM abutment (NobelProcera Abutment Titanium, Nobel Biocare) was connected to the implant fixture at the right mandibular molar region at 35 Ncm, and porcelain fused to metal crowns were cemented to abutments with Hy-Bond Temporary Cement Hard (Shofu). We opted for cemented crowns to avoid any fracture to ISPs due to overloading forces. In other words, it would be preferable to have the cemented crowns disconnected rather than having them broken down.

Final suprastructures at the maxillary implant region were designed as cemented connected crowns. Precise adjustment of occlusal and proximal tooth contact was carried out as follows. At the intercuspal position, occlusal adjustment was performed to obtain centered contact with narrow occlusal tables and flat cusps.¹¹ Occlusal contact was adjusted to obtain equal contact force between tooth-tooth and implant-tooth. During lateral excursions to the right side, group function with canine and premolars were used. Interproximal contact between implant-adjacent teeth was adjusted to a distance of about 70~90 μm, determined by contact gauges (YDM Co, Tokyo, Japan). Suprastructures were cemented with Hy-Bond Temporary Cement Hard (Shofu).

One month after insertion, the final suprastructures and crowns on the right maxillary premolar regions lost their retention; therefore, we did a surface treatment with sandblast (50 μm alumina particles) at the internal surface of the crowns and at the surface of the titanium abutment, and cemented the



FIGURES 3 AND 4. FIGURE 3. Computed tomographic examination at treatment planning. Sagittal slices indicated that bone volume at the surgical zone of the right maxillary first premolar and right mandibular molar sites presented with sufficient width and length to place implant fixtures. However, the vertical bone volume between the alveolar crest and sinus floor was 3 mm at the right maxillary sinus regions of second premolar site. (a) Maxillary coronal view. (b) Mandibular coronal view. (c) Sagittal view of tooth #15. (d) Sagittal view of tooth #14. (e) Sagittal view of tooth #46. **FIGURE 4.** Panoramic radiographs 1 year after installation of implant suprastructures.

crowns with a stronger temporary cement, Hy-Bond Carbo Cement (Shofu).

Nevertheless, loss of retention of the crowns reoccurred soon after the previous reinstallation. We then performed additional occlusal adjustments during lateral excursion to the right side and at the proximal contact between the implant crown and adjacent natural teeth in order to obtain a slightly loose contact. Finally, we cemented with adhesive resin cement (Super-Bond C&B, Sun Medical, Nagoya, Japan).

The right mandibular molar region also experienced an abutment screw loosening though there was no loss of retention of the crown. Thus, we decided to prepare an access hole on the occlusal surface of the crown to reconnect the abutment. Thereafter, a night-use OSS was prescribed; however, the patient could not tolerate the uncomfortable feeling and refused to use it. Currently, careful follow-up is being conducted to monitor these unfavorable conditions (Figures 4 and 5).

DISCUSSION

In this present case, meticulous occlusal adjustments were performed; more specifically, only canines and premolars were set as guiding teeth during lateral excursion to avoid any lateral forces on the ISPs. As a routine practice, occlusal adjustment during lateral movement was performed under a normal biting condition. However, this patient presented pathological teeth mobility at laterotrusive movements under abnormal clenching

force, which we identified as the cause of the successive technical complications.

As this case was unique, we termed the condition the “concealed jiggling effect” and defined it as abnormal tooth mobility that is not detected during routine clinical examination but observed only during laterotrusion under abnormal clenching force. Such abnormal tooth mobility is associated with harmful occlusal forces that eventually lead to the ISPs overloading and successive complications.

We also suggest that concealed jiggling effect is a novel risk factor for complications of ISPs, and propose the following diagnostic criteria: (1) dentition is mainly composed of natural teeth, (2) mobility of remaining teeth are within physiological range, (3) remaining teeth exhibit abnormal mobility during laterotrusion under intensive clenching force. Finally, we alert clinicians of the necessity to consider these factors when planning an implant treatment for partially edentulous patients as to avoid continuous complications and distress to the patient and the treating doctor.

ABBREVIATIONS

ISP: implant-support prosthesis
 NP: narrow platform
 OSS: occlusal stabilization splint
 RP: regular platform

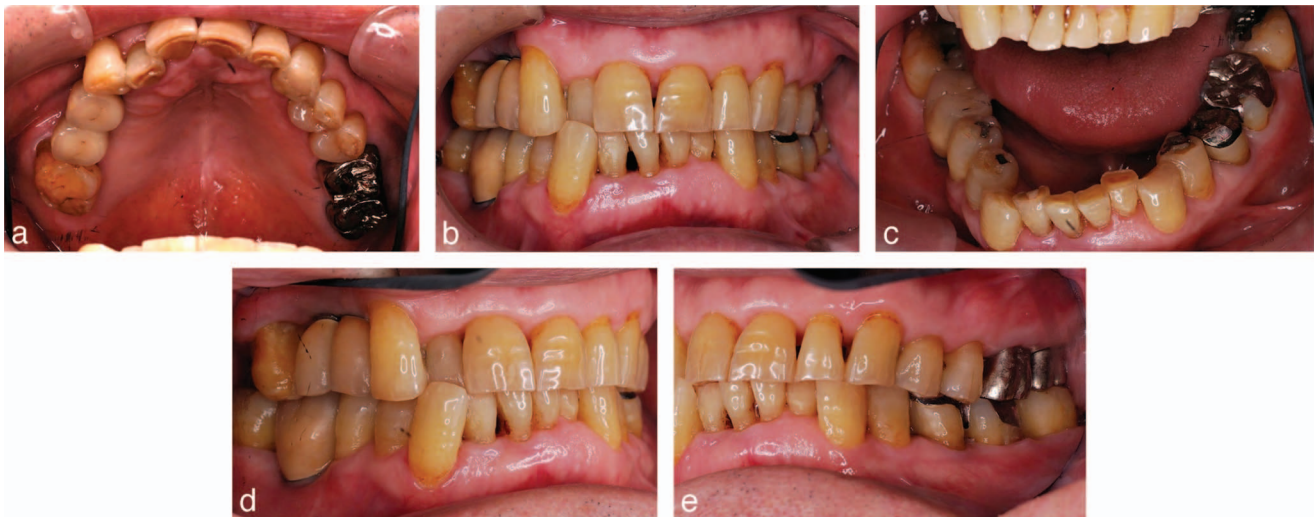


FIGURE 5. Intraoral view 1 year after installation of implant suprastructures. (a) Maxillary occlusal view. (b) Frontal view. (c) Mandibular occlusal view. (d) Right lateral view. (e) Left lateral view.

REFERENCES

1. Pjetursson BE, Tan K, Lang NP, et al. A systematic review of the survival and complication rates of fixed partial dentures (FPDs) after an observation period of at least 5 years. *Clin Oral Implants Res.* 2004;15:625–642.
2. Brägger U, Karoussis I, Persson R, et al. Technical and biological complications/failures with single crowns and fixed partial dentures on implants: a 10-year prospective cohort study. *Clin Oral Implants Res.* 2005;16:326–334.
3. Kreissl ME, Gerds T, Muche R, et al. Technical complications of implant-supported fixed partial dentures in partially edentulous cases after an average observation period of 5 years. *Clin Oral Implants Res.* 2007;18:720–726.
4. Noda K, Arakawa H, Maekawa K, et al. Identification of risk factors for fracture of veneering materials and screw loosening of implant-supported fixed partial dentures in partially edentulous cases. *J Oral Rehabil.* 2013;40:214–220.
5. Nyman SR, Lang NP. Tooth mobility and the biological rationale for splinting teeth. *Periodontol 2000.* 1994;4:15–22.
6. Sekine H, Komiyama Y, Hotta H, et al. Mobility characteristics and tactile sensitivity of osseointegrated fixture-supporting systems. In: van

- Steenberghe D, ed. *Tissue Integration in Oral and Maxillofacial Reconstruction.* Amsterdam: Excerpta Medica, Elsevier Co; 1986:326–339.
7. Ericsson I, Lekholm U, Brånemark PI, et al. A clinical evaluation of fixed-bridge restorations supported by the combination of teeth and osseointegrated titanium implants. *J Clin Periodontol.* 1986;13:307–312.
8. Wood MR, Vermilyea SG; Committee on Research in Fixed Prosthodontics of the Academy of Fixed Prosthodontics. A review of selected dental literature on evidence-based treatment planning for dental implants: report of the Committee on Research in Fixed Prosthodontics of the Academy of Fixed Prosthodontics. *J Prosthet Dent.* 2004;92:447–462.
9. Brägger U, Aeschlimann S, Burgin W, et al. Biological and technical complications and failures with fixed partial dentures (FPD) on implants and teeth after four to five years of function. *Clin Oral Implants Res.* 2001;12:26–34.
10. De Boever AL, Keersmaekers K, Vanmaele G, et al. Prosthetic complications in fixed endosseous implant-borne reconstructions after an observations period of at least 40 months. *J Oral Rehabil.* 2006;33:833–839.
11. Kim Y, Oh TJ, Misch CE, et al. Occlusal considerations in implant therapy: clinical guidelines with biomechanical rationale. *Clin Oral Implants Res.* 2005;16:26–35.