

# Oral Pyogenic Granuloma Associated With a Dental Implant Treated With an Er:YAG Laser: A Case Report

Alper Kaya, DDS, PhD<sup>3\*</sup>  
Faysal Ugurlu, DDS, PhD<sup>2</sup>  
Bilal Basel, DDS<sup>2</sup>  
Cem B. Sener, DDS, PhD<sup>1</sup>

## INTRODUCTION

A pyogenic granuloma is a reactive inflammatory hyperplasia that occurs most commonly on the skin and oral mucosa. The term *inflammatory hyperplasia* is used to describe a large range of nodular growths of the oral mucosa that comprise inflamed fibrous and granulation tissues histologically. It includes fibrous inflammatory hyperplasia, palatal papillary hyperplasia, giant cell granuloma, pregnancy epulis, and pyogenic granuloma.<sup>1</sup> Pyogenic granulomas occur mostly on the mucosa of females with high steroid hormone levels, and it is generally believed that female sex hormones play an important role in their pathogenesis.<sup>2</sup> This tumorlike growth of the oral cavity is frequently located surrounding the anterior teeth. It often arises in response to stimuli such as low-grade local irritation trauma, hormonal factors, or certain drugs. Clinically, pyogenic granulomas begin as small, red papules that grow rapidly and range in size from a few millimeters to several centimeters. These lesions can also present as asymptomatic, pedunculated, raspberry-like nodules, which become ulcerated due to secondary trauma.<sup>1-3</sup> Gingival hyperplasia, mucositis, and peri-implantitis are among the soft-tissue complications associated with dental implants.<sup>4</sup> The mechanisms that lead to the development of these reactive lesions associated with dental implants have not been elucidated fully. We describe a case of pyogenic granuloma related to a dental implant treated with an Er:YAG laser. To the best of our knowledge, this is the fourth reported case associated with a dental implant and the first treated with an Er:YAG laser.

## CASE REPORT

A 34-year-old man who had undergone bone grafting, alveolar distraction osteogenesis, dental implants, and ceramic crowns 7 years earlier at our institution was referred back with complaints of bleeding and mucosal hyperplasia around the implants (Figure 1). On examination, an exophytic, 2 × 1.5-cm

nodular lesion with a smooth, shiny surface was observed on the gingiva of the implant placed in the upper left central position (Figure 2a). The implant was stable clinically. A resorption gap between the implants and 2 mm of horizontal bone loss were observed radiographically (Figure 2b).

Although the patient's oral hygiene was optimal, with no microbial plaque accumulation or associated trauma, initial periodontal therapy was performed before the surgical therapy. After a 3-week healing period, the lesion was excised with an Er:YAG laser in contact with bone (3 W, 25 Hz, VLP mode) under local anesthesia. A sulcular incision was made, and a mucoperiosteal flap was elevated. The implant surfaces were then decontaminated with the Er:YAG laser in noncontact mode (1.5 W, 15 Hz, SP mode; Figure 2c). Bleeding was controlled, and the flap was sutured. There were no postoperative complications.

The removed tissue was fixed in 10% formalin and embedded in paraffin. The histopathological diagnosis was pyogenic granuloma. Histological sections were stained with hematoxylin-eosin or eosin alone, to facilitate the detection of potential metal particles. Histologic examination showed an ulcerated nodule consisting of a delicate connective tissue stroma containing numerous blood vessels with plump endothelial cells, intermingled with abundant polymorphonuclear lymphocytes. The capillaries showed a radiating pattern extending toward the surface. Besides the ulceration, the epithelium was slightly hyperplastic. The deep part of particule was fibrous and contained large blood vessels often surrounded by dense infiltration of chronic lymphoplasmacyte (Figure 2d). These features were consistent with the diagnosis of pyogenic granuloma. At the 2-year follow-up, no recurrence was observed, and the implant was stable (Figure 3). This article discusses the benefits of using Er:YAG lasers to treat benign soft-tissue lesions around dental implants, such as pyogenic granulomas.

## DISCUSSION

An oral pyogenic granuloma is an infrequent peri-implant complication of soft tissue, with only 3 cases reported in the international literature.<sup>5-7</sup> To the best of our knowledge, this is the fourth reported case and the first treated with an Er:YAG laser.

The soft tissues around dental implants are important for long-term implant success. Peri-implant complications include dehiscence, fistula, mucositis, gingival inflammation with

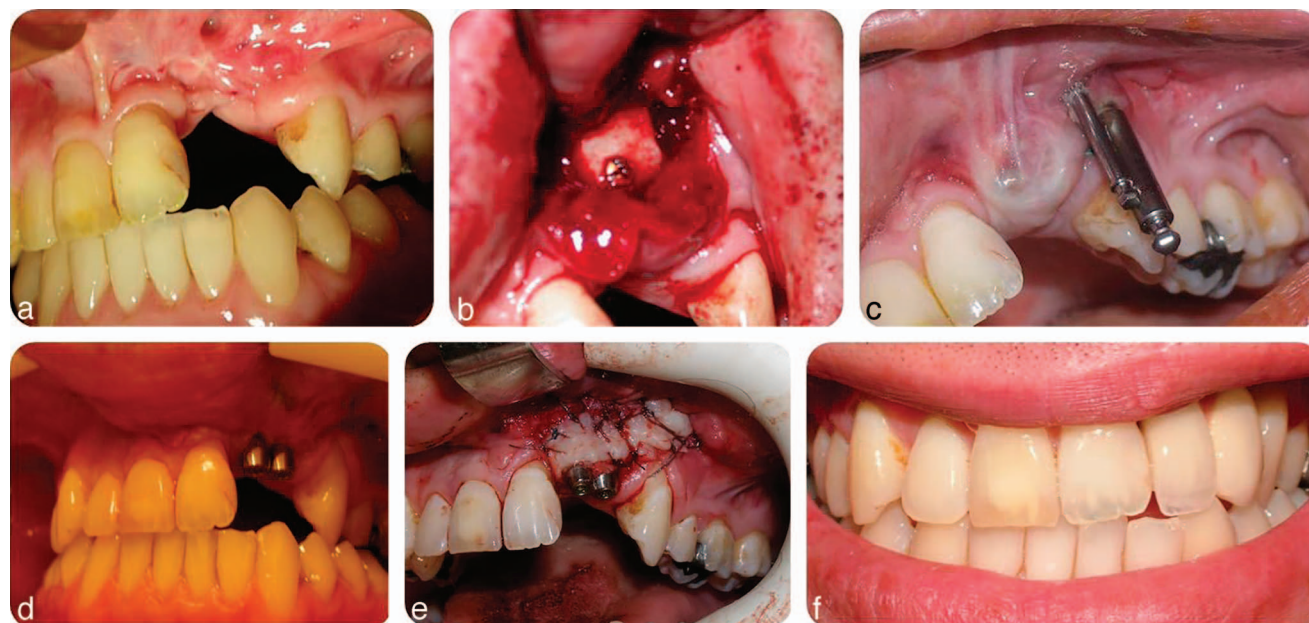
<sup>1</sup> Dicle University, Dentistry Faculty, Department of Oral and Maxillofacial Surgery, Diyarbakir, Turkey.

<sup>2</sup> Marmara University, Dentistry Faculty, Department of Oral and Maxillofacial Surgery, Istanbul, Turkey.

<sup>3</sup> College of Dental Sciences, RAK Medical & Health Sciences University, Ras Al Khaimah, UAE.

\*Corresponding author, e-mail: drkayaalper@gmail.com

DOI: 10.1563/AAID-JOI-D-13-00251



**FIGURE 1.** (a) Patient with unilateral lip and palatal cleft. (b) The cleft area was grafted with an autogenous block graft, which was harvested from the mandibular retromolar region. (c) The defect was augmented vertically by alveolar distraction osteogenesis. (d) Two dental implants were placed. (e) The buccal region was grafted with keratinized gingival tissue. (f) Metal-supported porcelain restorations were constructed and adapted to the implants.

hyperplasia, and peri-implantitis. Gingivitis and gingival hyperplasia are the most common (30%) soft-tissue complications associated with dental implants.<sup>8,9</sup> Reported cases of gingival hyperplasia around dental implants include phenytoin-induced hyperplasia<sup>10</sup> and a case of allergy to titanium abutments.<sup>11</sup> A few articles on peripheral giant cell granulomas associated with dental implants have also been published. These peri-implant complications can result from poor oral hygiene, an inappropriate choice of abutments, healing caps that are too short or too close to each other, the presence of dead spaces under the suprastructure, and a lack of attached mucosa, caused by loose abutment screws or framework misfits.<sup>12,13</sup> It is important to choose a healing cap that matches the size of the implant used. An ill-fitting cap might lead to the development of a reactive gingival lesion, such as an oral pyogenic granuloma, which in turn might jeopardize implant survival.

Clinically, a pyogenic granuloma is usually a smooth or lobulated exophytic lesion with a pedunculated or sessile base. They range in size from a few millimeters to several centimeters, but rarely exceed 2.5 cm. Many grow rapidly and can cause significant bone loss. Our patient's lesion was 2 × 1.5 cm and had caused significant bone loss around the implant. According to the patient, it grew in 3 months.

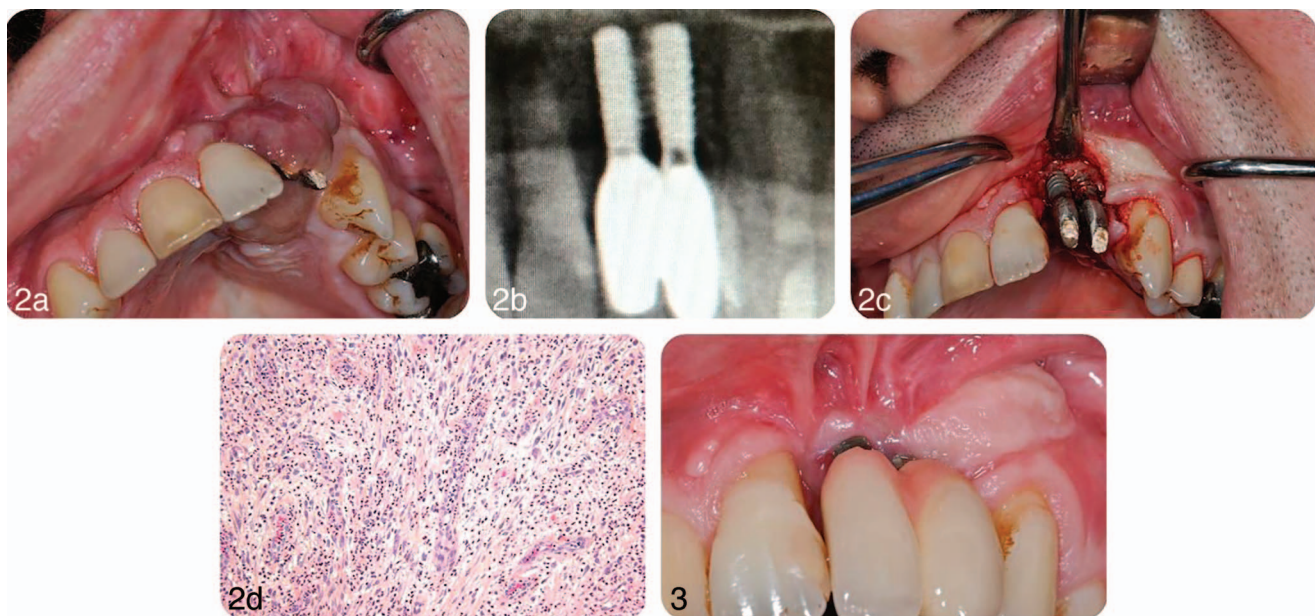
In dental practice, pure titanium is the metal most often in direct contact with host tissues. *In vivo*, no metal or alloy is completely inert. Corrosion is one possible cause of implant failure after initial success; with the release of ions/particles into the biological milieu, the released metal ions/particles can be confined locally or migrate systemically.<sup>14,15</sup>

Macrophages loaded with titanium particles have been detected in the peri-implant tissues of human failed dental implants, and their presence has been interpreted as an indicator of corrosion. Numerous case reports have described

histological evidence of an inflammatory response and the presence of metallic ions/particles in the tissues adjacent to orthopedic prostheses of titanium or titanium-based alloys.<sup>16</sup> Olmedo et al<sup>5</sup> observed abundant metal particles, either free or phagocytosed by macrophages, on microscopic examination of a reactive lesion removed from around a dental implant. In our case, no metal-like particles were observed histopathologically. Ozden et al<sup>17</sup> and Cloutier et al<sup>18</sup> suggested that bone loss causes exposure of the rough portion of the implant neck, which in turn exerts a chronic irritative effect on the attached gum. Studies have suggested that metal corrosion can affect the close contact between the implant and bone tissue. Metal particles can be ingested by macrophages, stimulating the release of cytokines that contribute to bone reabsorption by activating osteoclasts. In addition to increasing bone reabsorption, these particles can suppress osteoblast function, reducing bone formation and contributing to osteolysis.<sup>16,19</sup> The bone loss observed in our case might have been associated with corrosion.

A pyogenic granuloma can be treated after making the correct diagnosis. It is a benign lesion; therefore, surgical excision is the treatment of choice. Other surgical modalities used to treat pyogenic granulomas include cryosurgery using either liquid nitrogen spray or a cryoprobe, an electric scalpel, or cryosurgery.<sup>20</sup> Other methods include cauterization with silver nitrate, sclerotherapy with sodium tetradecyl sulfate and monoethanolamine oleate,<sup>21</sup> ligation, absolute ethanol injection,<sup>22</sup> Nd:YAG and CO<sub>2</sub> lasers,<sup>23</sup> shave excision, and laser photocoagulation.<sup>24</sup>

Lasers have been used to remove pyogenic granulomas successfully and have the advantages of causing minimal pain and invasiveness, with no need for suturing or packing.<sup>25</sup> CO<sub>2</sub> and Nd:YAG lasers have been used to excise intraoral lesions,



**FIGURES 2 AND 3. FIGURE 2.** (a) The lesion 2 × 1.5 cm in diameter was around the implants on both vestibular and palatal gingiva. (b) Radiographic examination showed a resorption gap between the implants and 2 mm of horizontal bone loss. (c) The lesion was excised, and decontamination was performed with the Er:YAG laser. (d) Microscopic examination showed an ulcerated granulation tissue containing several capillaries intermingled with numerous neutrophils (hematoxylin and eosin, original magnification ×20). **FIGURE 3.** After 2-year follow-up, no recurrence was observed.

such as hemangiomas, lymphangiomas, squamous papillomas, lichen planus, focal melanosis, and pyogenic granulomas. Healing occurs within a few days. In addition, the laser depolarizes nerves, reducing postoperative pain, and it destroys many bacteria and viruses that potentially cause infection. Reduced postoperative discomfort, edema, scarring, and shrinkage have all been associated with laser use.<sup>24</sup> White et al<sup>26</sup> reported that CO<sub>2</sub> and Nd:YAG laser excision was successful and well tolerated by patients, with no adverse effects. Meffert et al<sup>27</sup> used a flash lamp pulsed dye laser on a mass of granulation tissue and concluded that the tissue responded well to a series of treatments. Diode lasers give excellent results in cutaneous pyogenic granulomas, with only minimal pigmentary and textural complications. Gonzales et al<sup>28</sup> proposed that the treatment of pyogenic granulomas with a 585-nm pulsed dye laser is a safe, effective, and reasonable alternative to conventional therapy, with no postoperative complications or persistent pigmentary changes or scarring. We achieved complete resolution of this lesion with an Er:YAG laser, without complications. Careful management of the lesion also helps to prevent its recurrence, when excised with its base and all of the causative factors have been removed. Nevertheless, extended follow-up is needed because the recurrence rate for treated pyogenic granulomas is 16%.

Hernandez et al<sup>29</sup> also advocated polishing the implant surface with an abrasive paste. In our case, to avoid a peri-implant reactive lesion, we decontaminated the exposed implant surface using the Er:YAG laser. There was no scarring or recurrence at the 2-year follow-up. Hence, an Er:YAG laser appears to be a good therapeutic option for intraoral pyogenic granulomas. It is advisable to eliminate all irritating factors associated with such lesions to prevent their recurrence. These

include plaque, calculus, cement particles, the prosthesis, and ultimately the dental implant if its continued presence hinders the elimination of the associated lesion.

#### REFERENCES

1. Eversole LR. *Clinical Outline of Oral Pathology: Diagnosis and Treatment*. 3rd ed. Hamilton, Canada: BC Decker; 2002.
2. Bhaskar SN, Jacoway JR. Pyogenic granuloma—clinical features, incidence, histology, and result of treatment: report of 242 cases, *J Oral Surg*. 1966;24:391–398.
3. Parikh K, Shah P, Shah M. Pyogenic granuloma: a report of three cases. *J Dent Sci*. 2011;2:53–55.
4. Lang NP, Wilson TG, Corbet EF. Biological complications with dental implants: their prevention, diagnosis and treatment. *Clin Oral Implants Res*. 2000;1:146–155.
5. Olmedo DG, Paparella ML, Brandizzi D, Cabrini RL. Reactive lesions of periimplant mucosa associated with titanium dental implants: a report of 2 cases. *Int J Oral Maxillofac Surg*. 2010;39:503–507.
6. Etöz AO, Soylu E, Kılıç K, Günhan O, Akçay H, Alkan A. A reactive lesion (pyogenic granuloma) associated with dental implant: a case report. *J Oral Implantol*. 2013;39:733–736.
7. Ivan D, Michel R, Tommaso L. Occurrence of a pyogenic granuloma in relation to a dental implant. *J Oral Maxillofac Surg*. 2010;68:1874–1876.
8. Goodacre CJ, Kan JY, Rungcharassaeng K. Clinical complications of osseointegrated implants. *J Prosthet Dent*. 1999;81:537–552.
9. Tolman DE, Laney WR. Tissue-integrated prosthesis complications. *Int J Oral Maxillofac Implants*. 1992;7:477–484.
10. Chee WW, Jansen CE. Phenytoin hyperplasia occurring in relation to titanium implants: a clinical report. *Int J Oral Maxillofac Implants*. 1994; 9: 107–109.
11. Mitchell DL, Synnott SA, Van Der creek JA. Tissue reaction involving an intraoral skin graft and CP titanium abutments: a clinical report. *Int J Oral Maxillofac Implants*. 1990; 5:79–84.
12. Bischof M, Nedir R, Lombardi T. Peripheral giant cell granuloma associated with a dental implant. *Int J Oral Maxillofac Implants*. 2004; 19: 295–299.
13. Hirschberg A, Kozlovsky A, Schwartz-Arad D. Peripheral giant cell

- granuloma associated with dental implants. *J Periodontol.* 2003;74:1381–1384.
14. Olmedo D, Fernandez MM, Guglielmotti MB, Cabrini RL. Macrophages related to failed dental implants. *Implant Dent.* 2003;12:75–80.
  15. Olmedo DG, Cabrini RL, Duffo G, Guglielmotti MB. Local effect of titanium corrosion: an experimental study in rats. *Int J Oral Maxillofac Surg.* 2008;37:1032–1038.
  16. Jacobs JJ, Gilbert JL, Urban RM. Current concepts review: corrosion of metal orthopaedic implants. *J Bone Joint Surg Am.* 1998;80:268–282.
  17. Ozden FO, Ozden B, Kurt M, Gunduz K, Gunhan O. Peripheral giant cell granuloma associated with dental implants: a rare case report. *Int J Oral Maxillofac Implants.* 2009;24:1153–1156.
  18. Cloutier M, Makepeace C, Carmichael R, Sandor G. An analysis of peripheral giant cell granuloma associated with dental implant treatment. *Oral Surg Oral Med Oral Pathol Oral Radiol Endod.* 2007;103:618–622.
  19. Adya N, Alam M, Ravindranath T, Mubeen A, Saluja B. Corrosion in titanium dental implants: literature review. *J Indian Prosthodont Soc.* 2005;5:126–131.
  20. Gupta R, Gupta S. Cryo-therapy in granuloma pyogenicum. *Indian J Dermatol Venereol Leprol.* 2007;73:141.
  21. Matsumoto K, Nakanishi H, Seike T. Treatment of pyogenic granuloma with sclerosing agents. *Dermatol Surg.* 2001;27:521–523.
  22. Ichimiya M, Yoshikawa K, Hamamoto Y, Muto M. Successful treatment of pyogenic granuloma with injection of absolute alcohol. *J Dermatol.* 2001;31:342–344.
  23. Raulin C, Greve B, Hammes S. The combined continuous-wave/pulsed carbon dioxide laser for treatment of pyogenic granuloma. *Arch Dermatol.* 2002;138:33–37.
  24. Kirschner RE, Low DW. Treatment of pyogenic granuloma by shave excision and laser photocoagulation. *Plast Reconstr Surg.* 1999;104:1346–1369.
  25. Shenoy SS, Dinkar AD. Pyogenic granuloma associated with bone loss in a eight year old child: a case report. *J Indian Soc Pedod Prev Dent.* 2006;24:201–203.
  26. White JM, Chaudhry SI, Kudler JJ. Nd:YAG and CO<sub>2</sub> laser therapy of oral mucosal lesions. *J Clin Laser Med Surg.* 1998;16:299–304.
  27. Meffert JJ, Cagna DR, Meffert RM. Treatment of oral granulation tissue with the flashlamp pulsed dye laser. *Dermatol Surg.* 1998; 24:845–848.
  28. Gonzales S, Vibhagool C, Falo LD, Momtaz KT, Grevelink J, Gonzalez E. Treatment of pyogenic granulomas with the 585 nm pulsed dye laser. *J Am Acad Dermatol.* 1996;35:428–431.
  29. Hernandez G, Lopez-Pintor RM, Torres J, De Vicente JC. Clinical outcome of peri-implant peripheral giant cell granuloma: a report of three cases. *J Periodontol.* 2009;80:1184–1191.