

# Relative Skeletal Effects in Different Sites of the Mandible With the Proximal Tibia During Ovariectomy and the Subsequent Estrogen Treatment

Hao Liu, MS<sup>1</sup>  
 Kai Gao, MS<sup>2</sup>  
 Hong Lin, PhD<sup>3</sup>  
 Yu Zhang, MD<sup>4</sup>  
 Binbin Li, PhD<sup>5\*</sup>

## INTRODUCTION

The host bone mass is critical to oral implantation success, especially in the case of osteoporosis. How we choose the adequate implanted site for an osteoporosis patient is an issue necessary to evaluate. In addition, whether the mandibular and systemic bone loss is positively associated has been hypothesized for many years.<sup>1,2</sup> Despite most experts' consent that osteoporosis could be a risk factor for the progression of oral disease,<sup>3</sup> the precise relationship of bone quality between the mandible and the systemic bone remains largely unknown. Several studies have proposed that the mandible bone mineral density (BMD) and the systemic BMD seemed to have no relation or, at most, a very weak relation.<sup>4,5</sup> However, these ideas cannot fully explain the fact that some subjects with osteoporosis presented with the greater progression of mandibular bone loss and reduced osseointegration than did those with no osteoporosis.<sup>6</sup>

Having reviewed the literature, we find that the detection sites of the mandible are different among the reports because there is no criteria for site choice of the mandible due to its irregular shape.<sup>7-9</sup> Specific skeletal mandible sites are related to different functional properties. Is it possible that some changes are missed if the mandible is analyzed as a whole? Therefore, it is worthy to reevaluate the association between the mandible and the systemic bone mass by separately analyzing each part of the mandible surrounding each mandibular molar—in which the dental clinicians are actually interested—especially for oral

implantists to choose the appropriate surgical sites for osteoporosis patients.

In an attempt to realize the relationship between the mandible and the systemic bone mass and to optimize a potent site on the mandible, we explored and compared the effect of estrogen deficiency and the following estrogen treatment on the mandible and the proximal tibia in adult rats, based on the microtomographic analysis and the biomechanical data.

## MATERIALS AND METHODS

### *Animals and administration procedure*

Thirty adult female Sprague-Dawley rats (weighing 210 g  $\pm$  9 g) were randomly divided into 3 groups with 10 rats each group:

1. Sham: sham surgery;
2. OVX: bilaterally ovariectomized;
3. OVX-E: treated with 10  $\mu$ g/kg estradiol subcutaneously once every two days after ovariectomy.

Three months later, the mice were sacrificed. The left mandible and the proximal tibia from each animal were thoroughly removed and used for biomechanical analyses. The right mandible and the proximal tibia were used for microtomographic measurements.

### *Microtomographic measurement*

The microtomography of the mandible and the proximal tibia were performed with a voxel size of 10.34  $\mu$ m with a SIEMENS MM Gantry LG CT camera scanner (Siemens, Munich, Germany). The trabecular parts of the tibia were separated with semi-automatically drawn contours. For the mandible, the volume of interest (VOI) was drawn using a slice-based method (Figure 1a).

The microstructural indices were calculated directly from the VOI. Total volume (TV) was the volume of the whole sample scanned. Bone volume (BV) and bone surface (BS) were determined using tetrahedrons corresponding to the enclosed volume of the triangulated surface. BV/TV and BS/BV were used to normalize the sizes of the samples. Mean trabecular

<sup>1</sup> Central Laboratory, Peking University School and Hospital of Stomatology, Beijing, PR China.

<sup>2</sup> Key Laboratory of Human Diseases Comparative Medicine, Ministry of Health, Beijing, PR China; Institute of Laboratory Animal Science, Chinese Academy of Medical Sciences & Comparative Medicine Centre, Peking Union Medical College, Beijing, PR China.

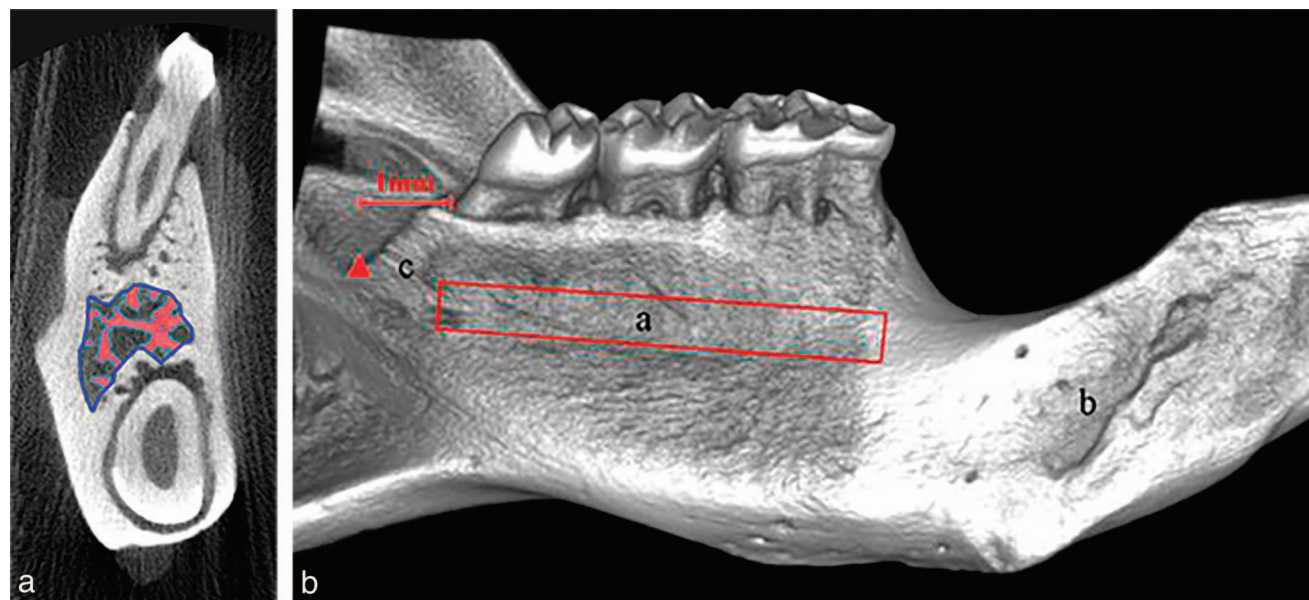
<sup>3</sup> Department of Dental Materials, Peking University School and Hospital of Stomatology, Beijing, PR China.

<sup>4</sup> Department of Oral Implantology, Peking University School and Hospital of Stomatology, Beijing, PR China.

<sup>5</sup> Department of Oral Pathology, Peking University School and Hospital of Stomatology, Beijing, PR China.

\* Corresponding Author, e-mail: kqlibinbin@aliyun.com

DOI: 10.1563/AAID-JOI-D-13-00255



**FIGURE 1.** A microcomputed tomography scan of a cross-section of the mandible (a) and three-dimensional reconstruction (b). (a) The blue line represents volume of interest. The red area reveals the trabecular bone in the mandible. (b) a: The basal bone below the molars, one of the biomechanical tested area; b: the incisor alveolar; c: the site 1 mm behind the third mandibular molar, another site for biomechanical analysis.

thickness (Tb.Th.) was calculated from the local thickness at each voxel, representing the trabecular meshwork. Trabecular number (Tb.N.) was determined by taking the inverse of the mean distance between the middle axes of the structure. Trabecular separation (Tb.Sp.) was calculated from the direct thickness of the nonbone parts.

For determining BMD, the motif that contains 6 cylinders of different density was scanned in the same condition of the samples. The VOI (as with the microtomography) of the 4 cylinders that had high density was drawn in contours. The resulting linear equation was  $BMD = 9.1313 (VOI) - 8518 (R^2 = 1)$ . The 4 mean values were used in the linear regression formula that comes with microcomputed tomography (microCT).

### Biomechanical testing

The 3-point bend testing was performed at the plunger speed of 1.0 mm/min using a computer-controlled mechanical testing machine (Instron 4302, Instron, Norwood, Mass). The load-deformation curves were recorded during the bending process.

The tested area of the tibia was the secondary spongiosa of the proximal end with 3 mm sample space. The tested area of

the mandible included 2 sites with 1.5 mm space: (1) the basal bone below the molars in the mandible of the tongue side, which microCT had scanned; and (2) 1 mm behind the third mandibular molar (Figure 1b).

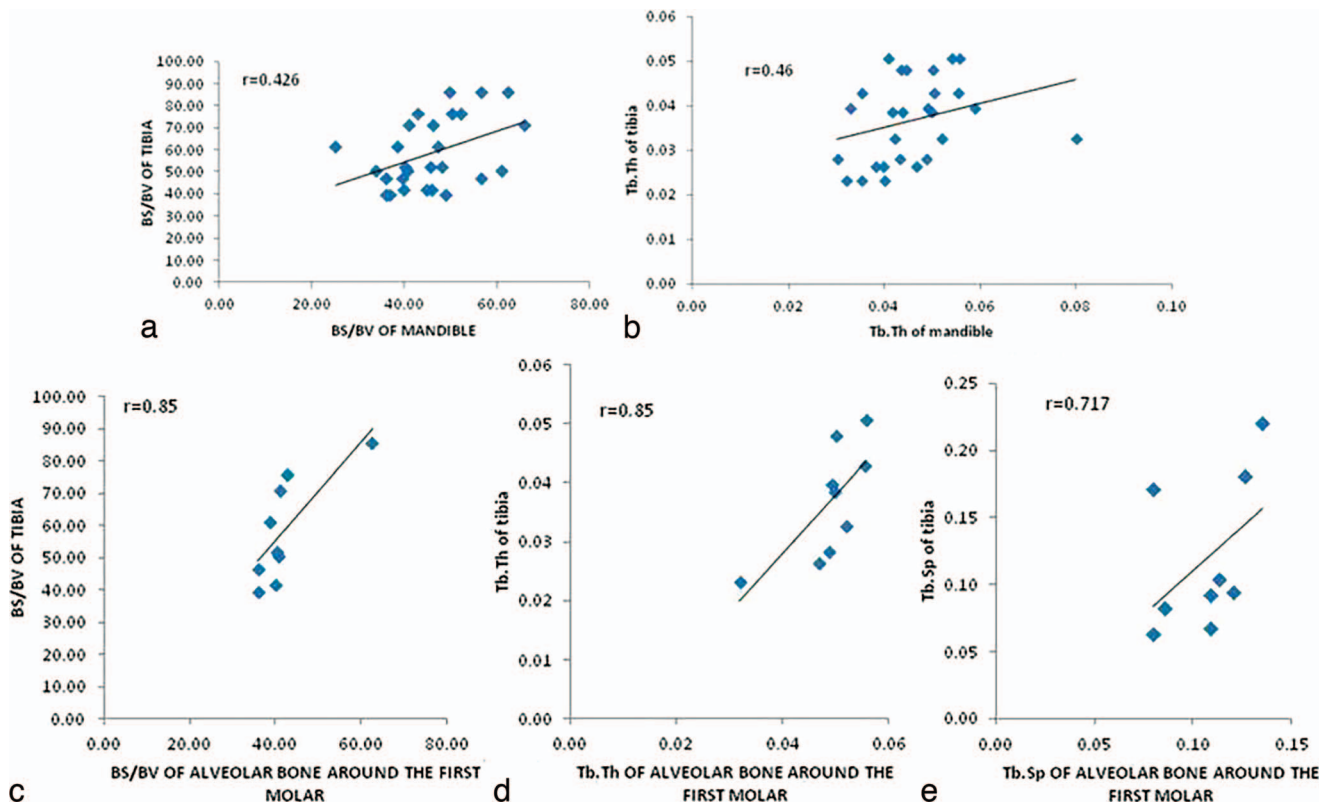
The maximum load (N) is the value of the load when the bone fractured. Stiffness (N/mm) was calculated as the slope of the linear portion of the load-deformation curve.<sup>10</sup> Energy to ultimate load (mJ) was computed as the areas under the load-deforming curves. Young's modulus (MPa) was computed from the initial slope of the stress-strain curve.

### Statistical analysis

Statistical analysis involved the use of SPSS v13.0 for Windows (SPSS Inc, Chicago, Ill). All values are reported as means  $\pm$  SD. Significant differences were estimated by one-way ANOVA followed by the Student–Newman–Keuls test. An LSD postdoc assay was used when the equal variances were assumed; otherwise, a Tamhane's T2 test was used. The correlations between the mandible and the tibia were estimated by bivariate correlation analysis.  $P < 0.05$  was considered statistically significant.

| Group | BV/TV (%)          | BS/BV (%)           | Tb.Th. (mm)       | Tb.N. (1/mm)        | Tb.Sp. (mm)         | CWT (mm)          |
|-------|--------------------|---------------------|-------------------|---------------------|---------------------|-------------------|
| Sham  | 0.304 $\pm$ 0.075  | 57.772 $\pm$ 11.336 | 0.035 $\pm$ 0.006 | 8.553 $\pm$ 1.092   | 0.083 $\pm$ 0.017   | 0.413 $\pm$ 0.080 |
| OVX   | 0.141 $\pm$ 0.052* | 69.455 $\pm$ 20.362 | 0.031 $\pm$ 0.011 | 4.544 $\pm$ 0.438** | 0.191 $\pm$ 0.026** | 0.443 $\pm$ 0.029 |
| OVX-E | 0.343 $\pm$ 0.076† | 47.508 $\pm$ 12.017 | 0.044 $\pm$ 0.010 | 7.925 $\pm$ 1.135‡  | 0.084 $\pm$ 0.018‡  | 0.473 $\pm$ 0.006 |

§Data are expressed as mean  $\pm$  SD. Comparisons of data between estradiol treatment, ovariectomy, and control group were evaluated by one-way ANOVA followed by the Student–Newman–Keuls test. \* $P < 0.05$ , \*\* $P < 0.01$ , compared with Sham group; † $P < 0.05$ , ‡ $P < 0.01$ , compared with OVX group. BV indicates blood volume; TV, total volume; BS, bone surface; Tb.Th., trabecular thickness; Tb.N., trabecular number; Tb.Sp., trabecular separation; OVX, bilaterally ovariectomized; OVX-E, treated with 10 lg/kg estradiol subcutaneously once every 2 days after ovariectomy.



**FIGURE 2.** Positive correlations between the overall/tooth-specific mandible and the proximal tibia in trabecular bone structural parameters measured by microcomputed tomography. (a) Bone surface/bone volume (BS/BV) and (b) Trabecular thickness (Tb.Th.) between the mandible and the proximal tibia. (c) BS/BV, (d) Tb.Th., and (e) Trabecular separation (Tb.Sp.) between the mandible around the mandibular–first-molar, and the proximal tibia.

**RESULTS**

**Microtomography**

BV/TV and Tb.N of the proximal tibia in OVX group decreased dramatically ( $P < 0.05$ ,  $P < 0.01$ , respectively), and Tb.Sp increased significantly 3 months after ovariectomy compared with Sham group ( $P < 0.01$ ), which suggested the success of osteoporosis modeling compared with the Sham group. After estradiol treatment, BV/TV and Tb.N. of the proximal tibia increased ( $P < 0.05$ ,  $P < 0.01$ , respectively), and Tb.Sp. decreased significantly ( $P < 0.01$ ) (Table 1).

BS/BV and Tb.Th. had a positive correlation between the mandible and the tibia ( $r = 0.426$ ,  $0.46$ ,  $P < 0.05$ , respectively)

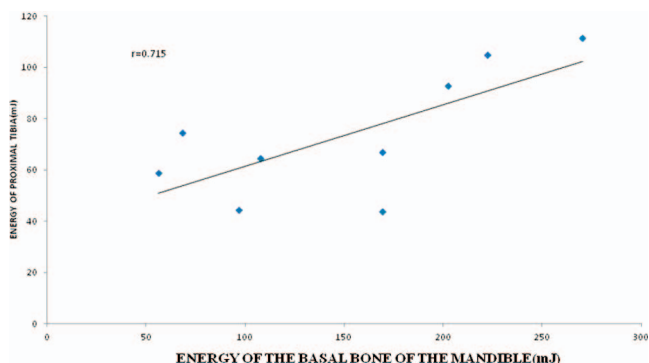
(Figure 2a and b). The mandible around mandibular first molar showed a significant relation with the proximal tibia in BS/BV ( $r = 0.85$ ,  $P < 0.01$ ), Tb.Th. ( $r = 0.85$ ,  $P < 0.01$ ), and Tb.Sp. ( $r = 0.717$ ,  $P < 0.05$ ) (Figure 2c, d, and e). There were no significant correlations between the tibia and the mandible around the mandibular second or third molars (data not shown).

**BMD measured by microCT**

BMD in the tibia reduced significantly after ovariectomy compared with Sham group ( $P < 0.01$ ). It improved after

| Group | Mandible BMD (g/cm <sup>2</sup> ) | Proximal tibia (g/cm <sup>2</sup> ) |
|-------|-----------------------------------|-------------------------------------|
| Sham  | 1.303 ± 0.007                     | 1.289 ± 0.035                       |
| OVX   | 1.241 ± 0.074                     | 1.187 ± 0.024*                      |
| OVX-E | 1.317 ± 0.013                     | 1.256 ± 0.012†                      |

†Data are reported as means ± SD. \*\* $P < 0.01$ , compared with Sham group; † $P < 0.05$ , compared with the OVX group. OVX indicates bilaterally ovariectomized; OVX-E, treated with 10 lg/kg estradiol subcutaneously once every 2 days after ovariectomy.



**FIGURE 3.** Significant correlation of the biomechanical strength between the basal bone of the mandible and the proximal tibia.

TABLE 3

The biomechanical strength of the basal bone below the molars of the mandible in a 3-point bending test†

| Group | Maximal load (N) | Stiffness (N/mm) | Energy to ultimate load (mJ) | Young's modulus (Gpa) |
|-------|------------------|------------------|------------------------------|-----------------------|
| Sham  | 321.69 ± 82.29   | 251.32 ± 64.29   | 214.09 ± 51.56               | 725.32 ± 167.12       |
| OVX   | 180.08 ± 9.65*   | 140.69 ± 7.54*   | 124.72 ± 39.01               | 525.70 ± 161.97       |
| OVX-E | 201.59 ± 34.69*  | 157.49 ± 27.10*  | 115.68 ± 92.54               | 570.40 ± 45.43        |

†Data are expressed as mean ± SD. Comparisons of data between estradiol treatment, ovariectomy, and control group were evaluated by one-way ANOVA. \* $P < 0.05$ , compared with the Sham group. OVX indicates bilaterally ovariectomized; OVX-E, treated with 10 lg/kg estradiol subcutaneously once every 2 days after ovariectomy.

estriol treatment compared with OVX group ( $P < 0.05$ ). Slight differences were found in mandible BMD, but no significance existed (Table 2). No correlations in BMD were found between the mandible and the tibia.

### Biomechanical properties

As for the basal bone below the molars of the mandible, the maximal load and the stiffness declined significantly in OVX and OVX-E rats compared with Sham group ( $P < 0.05$ , respectively), but the latter were a little higher than that of the former (Table 3). There was a significant correlation of the biomechanical strength between the basal bone below molars of mandible and the proximal tibia. ( $r = 0.715$ ,  $P < 0.05$ , Figure 3). No differences were found in the site of 1 mm behind the mandibular third molar (data not shown).

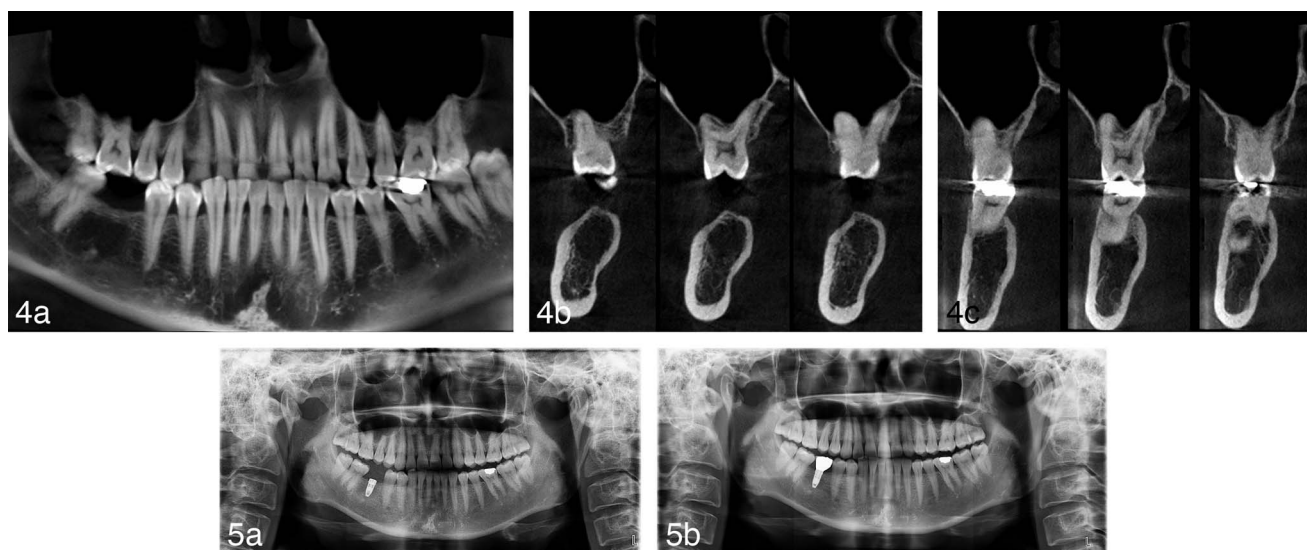
### DISCUSSION

We assessed bone mass of the mandible and the tibia through 3 levels: cancellous and cortical bone structure, BMD, and biomechanical measurement. These results suggested a positive correlation of tibial bone microstructure and the mechan-

ical feature with specific skeletal sites of the mandible. Evaluated by BMD, bone micro-architecture and biomechanical properties, bone mass could be together well determined.

In the present study, BS/BV and Tb.Th. were the most sensitive parameters. Yang et al<sup>11</sup> suggested that there were significant positive correlations between the mandible and the tibia for Tb.Th. and the structure model index. We also demonstrated the same results, but the correlated index was slightly different from that of Yang et al. We found a correlation between BS/BV, Tb.Th., and Tb.Sp. in the mandible around the mandibular first molar and the tibia; however, the cortical bone parameters of the mandible and the tibia experienced no change after the ovariectomy or estrogen treatment, which was in contrast to what had been shown by Yang et al.<sup>12</sup>

We further obtained detailed data regarding the mandible around the first, second, and third mandibular molar. It was clear that the microtomographic parameters for the mandibular first molar had the best correlation with the proximal tibia. These findings were supported by Tanaka.<sup>13</sup> The mechanism of the findings may be due to rat molars erupting normally, exactly like human molars, in contrast to rat incisors that erupt continuously and contain a lifelong-active stem cell population.<sup>14</sup>



**FIGURES 4 AND 5.** **FIGURE 4.** The panoramic view (a) and the sagittal views of the cone beam computerized tomography images showed very low bone density and HU values in both regions of the right first molar (b) and the left first molar (c). **FIGURE 5.** Panoramic radiographs at the time of the first operation (a) and (b) at the time of the crown delivery 6 months after the first operation.

TABLE 4

The bone density scanning of a patient's lumbar spine\*

| Region | Area (cm <sup>2</sup> ) | BMC (g) | BMD (g/cm <sup>2</sup> ) | T-score | Z-score |
|--------|-------------------------|---------|--------------------------|---------|---------|
| L1     | 13.63                   | 11.39   | 0.836                    | -1.4    | -1.1    |
| L2     | 14.98                   | 13.45   | 0.898                    | -1.2    | -0.8    |
| L3     | 16.68                   | 14.91   | 0.893                    | -1.7    | -1.3    |
| L4     | 18.14                   | 16.64   | 0.917                    | -1.3    | -0.9    |
| Total  | 63.43                   | 56.39   | 0.889                    | -1.4    | -1.1    |

\*Total BMD CV 1.0%, ACF = 1.029, BCF = 0.992, TH = 6.839. WHO classification: osteopenia. Fracture risk: increased. BMD indicates bone mineral density.

The present biomechanical testing demonstrated a significant reduction in maximal load and stiffness in OVX rats. The estradiol treatment elevated the 2 indexes significantly. We put forward the proposition that there was correlation between biomechanical strength in the basal bone below the mandibular molars and the proximal tibia. The choices of detected sites were dependent on the morphological traits and mechanical loadings during mastication by the mandible. It was shown that the basal bone below the molars of the mandible may be more sensitive than the site located 1 mm behind the third mandibular molar.

Interestingly, we found the phenomenon of such correlation between the mandibular bone and the skeleton not infrequent in our daily clinical work. We present here a case as follows: A 43-year-old Chinese woman presented with a complaint of missing the mandibular right first molar. She had the tooth extracted due to severe caries 1 year prior. Her past medical history was unremarkable. She had not any assessment of osteoporosis. The cone-beam computerized tomography examination revealed very low bone density in the regions of the mandibular first molars (Figure 4). Therefore, we advised her to do DXA examination of her lumbar spine. The T-score was -1.4 and the Z-score was -1.1 (Table 4). Her BMD results suggested that she was in an osteopenia state. The patient underwent placement of a NobleSpeedy Replace implant (Nobel Biocare AB, Zürich, Switzerland). The insertion torque was less than 15 Ncm, and the implant was treated submerged. After 4 months of healing, the implant was uncovered, and a healing abutment was connected. A Procera all-ceramic crown was delivered till the 6th month after the first operation (Figure 5).

#### ABBREVIATIONS

BMD: bone mineral density  
 BS: bone surface  
 BV: bone volume  
 microCT: microcomputed tomography  
 OVX: bilaterally ovariectomized  
 OVX-E: treated with 10 µg/kg estradiol subcutaneously once every 2 days after ovariectomy

Tb.N.: trabecular number  
 Tb.Sp.: trabecular separation  
 Tb.Th.: trabecular thickness  
 TV: total volume  
 VOI: volume of interest

#### REFERENCES

1. Wactawski-Wende J, Hausmann E, Hovey K, Trevisan M, Grossi S, Genco RJ. The association between osteoporosis and alveolar crestal height in postmenopausal women. *J Periodontol.* 2005;76:2116-2124.
2. Johnson RB, Gilbert JA, Cooper RC, et al. Effect of estrogen deficiency on skeletal and alveolar bone density in sheep. *Periodontol.* 2002; 73:383-391.
3. Makker A, Singh MM, Mishra G, Singh BP, Jain GK, Jadhav S. Relationship between bone turnover biomarkers, mandibular bone mineral density, and systemic skeletal bone mineral density in premenopausal and postmenopausal Indian women. *Menopause.* 2012;19:642-649.
4. Slaidina A, Soboleva U, Daukste I, Zvaigzne A, Lejnicks A. Postmenopausal osteoporosis and tooth loss. *Stomatologija.* 2011;13:92-95.
5. Ozola B, Slaidina A, Laurina L, Soboleva U, Lejnicks A. The influence of bone mineral density and body mass index on resorption of edentulous jaws. *Stomatologija.* 2011;13:19-24.
6. Geurs NC. Osteoporosis and periodontal disease. *Periodontol.* 2000. 2007;44:29-43.
7. Moriya Y, Ito K, Murai S. Effects of experimental osteoporosis on alveolar bone loss in rats. *J Oral Sci.* 1998;40:171-175.
8. Tanaka M, Toyooka E, Kohno S, Ozawa H, Ejiri S. Long-term changes in trabecular structure of aged rat alveolar bone after ovariectomy. *Oral Surg Oral Med Oral Pathol Oral Radiol Endod.* 2003;95:495-502.
9. Shoji K, Elsubeihi ES, Heersche JN. Effects of ovariectomy on turnover of alveolar bone in the healed extraction socket in rat edentulous mandible. *Arch Oral Biol.* 2011;56:114-120.
10. Huang TH, Lin SC, Chang FL, Hsieh SS, Liu SH, Yang RS. Effects of different exercise modes on mineralization, structure, and biomechanical properties of growing bone. *J Appl Physiol.* 2003;95:300-307.
11. Yang J, Pham SM, Crabbe DL. Effects of oestrogen deficiency on rat mandibular and tibial microarchitecture. *Dentomaxillofac Radiol.* 2003;32: 247-251.
12. Yang J, Farnell D, Devlin H, Horner K, Graham J. The effect of ovariectomy on mandibular cortical thickness in the rat. *J Dent.* 2005;33:123-129.
13. Tanaka M, Ejiri S, Toyooka E, Kohno S, Ozawa H. Effects of ovariectomy on trabecular structures of rat alveolar bone. *J Periodontol Res.* 2002;37:161-165.
14. Wise GE, Grier RL IV, Lumpkin SJ, Zhang Q. Effects of dexamethasone on tooth eruption in rats: differences in incisor and molar eruption. *Clin Anat.* 2001;14:204-209.