

A 5-Year Implant Follow-Up in Maxillary and Mandibular Horizontal Osseous Onlay Grafts and Native Bone

Carolina Sbordone, MD¹
 Paolo Toti, BSc, DDS²
 Ranieri Martuscelli, MD, DDS^{1*}
 Franco Guidetti, MD³
 Ludovico Sbordone, MD, DDS⁴
 Luca Ramaglia, MD, DDS¹

The purpose of this study is to analyze marginal bone levels (MBLs) around dental implants positioned in the upper and lower jaw with or without horizontal onlay grafting procedures, and to survey implant survival with a follow-up of 5 years. Seventeen patients were surveyed in the present retrospective chart review. A total of 27 dental implants positioned in pristine bone and 21 in horizontally grafted bone were enrolled. MBLs were recorded for 4 aspects during a radiologic survey of 5 years. Significant differences were searched for among times and surgical procedures with paired and unpaired comparison tests, respectively, and survival rates were calculated for the 2 groups. In the maxilla, no statistically-significant differences between pristine and augmented groups were obtained; the time comparisons for pristine implants showed an affection of *palatal*, *mesial*, and *distal* sides, whereas the resorption around implants placed into horizontally grafted bone of anterior maxilla seemed to be limited just to *buccal* and *distal* aspects. Comparisons with the pristine horizontal procedure revealed that just the buccal sides were involved. The analysis of time comparisons attested to a continuous alveolar bone remodeling during the entire time of the survey for the pristine group. Given the extremely unfavorable resorption at the buccal aspect of the augmented areas, clinicians should reserve dental implant positioning into horizontal bone graft to selected patients, in whom it may represent one of the last opportunities of rehabilitation with a fixed prosthesis.

Key Words: *autologous bone graft, marginal bone resorption, dental implants, horizontal augmentation techniques, bone remodeling*

INTRODUCTION

When residual bone volume is not adequate for prosthetic rehabilitation through osseointegrated dental implants, a bone augmentation is required. Among the different surgical procedures for prosthetic rehabilitation,¹⁻⁵ a nonvascularized autogenous grafting procedure for alveolar bone augmentation is a reliable and well-established technique, which is capable of yielding a high implant survival rate (93.4–94.4%), as obtained from long-term surveys.⁶⁻¹⁰

It had generally been proven that peri-implant marginal bone remodeling is very exiguous for dental implants placed in pristine bone.^{11,12}

Nevertheless, evidence-based results describing marginal bone loss for reconstructed alveolar bone by horizontal autogenous grafting procedure have been scanty. As described

in a recent review by Esposito,¹³ the 2 trials evaluating aspects for horizontal bone augmentation had sample sizes, which were too small to provide any reliable evidence, whereas several trials regarding vertical ridge augmentation have been conducted. A few studies regarding horizontal augmentation procedures have been performed, but using different grafting materials and generally having a short observation time.¹⁴⁻¹⁷

In the planning of dental implant placements in reconstructed alveolar bone with autografts, the unfavorable resorption in the 4 peri-implant aspects (as seen by means of 3-dimensional analysis), which could jeopardize implant survival, should be considered.

The primary aim of this retrospective chart review is to evaluate long-term marginal linear remodeling of bone around dental implants over time (at the 1-, 3-, and 5-year follow-up) for both implants in pristine bone and in horizontally-augmented bone; then to compare linear bone remodeling around dental implants placed in pristine bone of the maxilla and mandible versus that recorded for horizontally-augmented areas.

The secondary aim is to investigate the survival of dental implants in the pristine bone and augmented groups.

Patients and Methods

Seventeen patients were treated from January 2000 to December 2006. The patients' personal information, such as

¹ Department of Neurosciences, Reproductive and Odontostomatological Sciences, School of Medicine, University of Naples "Federico II," Napoli, Italy.

² Private Practice, Camaiore (Lucca), Italy.

³ Complex Operating Unit of Maxillo-Facial Surgery, Azienda Ospedaliero-Universitaria Pisana, Pisa, Italy.

⁴ Department of Medicine and Surgery, School of Medicine, University of Salerno, Baronissi (Salerno), Italy.

* Corresponding author, e-mail: rmartuscelli@libero.it

DOI: 10.1563/AAID-JOI-D-13-00278

age (years), gender, and that relating to the type of grafting and implant procedure (augmentation with autogenous bone, and number, location, and size of dental implants), subsequent surgical procedures, and the numbers and time points of performed CT scans, were reviewed.

The patient group consisted of 8 women and 9 men, ranging in age from 37.5 to 74.2 years (mean 53.4 ± 9.6 years). All patients were partially-edentulous with severe alveolar crest atrophy. Edentulous areas resulted from tooth loss, mainly due to periodontal disease or trauma.

Inclusion criteria: (1) functional rehabilitation with fixed prosthetic restoration supported by dental implants placed in the upper or lower jaw in pristine- or augmented-alveolar crestal area with horizontally-positioned autogenous bone; (2) a complete set of computerized tomography (CT) scan data, obtained for the graft area before the bone augmentation procedure, and then for all patients at the following time-points: before dental implant placement (T_0) and at 1- (T_1), 3- (T_2), and 5-years (T_3) after dental implant insertion.

Exclusion criteria: (1) patients subjected to surgical treatments different from that described above; (2) irradiated subjects; (3) patients who had received bone resection as part of an oncological treatment; and (4) intravenous and or oral bisphosphonate therapy.¹⁸

This is a retrospective chart review, so the criteria for the enrollment of patients could possibly generate a bias. For a tilted dental implant, the real vertical bone resorption of the alveolar ridge could be less extensive than the MBLs measured along the direction of the implant.

The present retrospective chart review was exempt from IRB approval, and was approved by the Scientific Ethics Committee of the University of Pisa (Ethical Approval Form 2626/2008, Protocol Number 58183).

Surgery

Surgeries were performed as already reported by Sbordone et al.^{8,19} Bone for augmentation procedures from the mandibular chin or ramus^{20–24} was harvested using rotary instruments and reciprocating saw, or by using a piezoelectric bone surgery device, whereas autogenous material from the iliac crest was obtained according to well-established techniques.^{25–29}

Sites with a residual alveolar crest width of less than 6 mm³⁰ and a height of less than 7 mm³¹ were deemed to require onlay graft augmentation. Onlay grafts were executed, where needed, via horizontal autogenous bone block grafting as already described.^{8,19,32} Appropriate antibiotic and analgesic anti-inflammatory therapy was performed for all patients. Three to five months³³ following reconstructive surgery, titanium dental implants (root-form, rough-surface) were inserted into the grafted areas, as well as in the pristine bone. All patients were given fixed prosthetic restorations with metal ceramic crowns and bridges, either cemented over a custom metal abutment or via a UCLA-type abutment, 6 months after implant placement. A “platform-switched” restoration was never employed.

Radiographic examination and variables

Following the standard treatment protocol, all patients were subjected to preoperative CT scans (high-speed double

detector CT scanner; General Electric Medical System, Milwaukee, Wis; and high-speed multislice 64-detector spiral CT scanner, Aquilion, Toshiba Europa Medical System, Zoetermeer, The Netherlands) of the grafted area before surgical treatment. Then, before dental implant placement, for the grafted- or ungrafted-sites, CT scans were acquired at (T_0), and then again at 1 (T_1), 3 (T_2), and 5 years (T_3) after implant insertion. Assessment of the CT scans included identifying the position of the dental implant apex. The marginal-bone heights were measured on cross-section views for the buccal and palatal aspects, and on Panorex views for the mesial and distal ones. Measurements were performed parallel to the long axis of the studied implant, and at a distance of 0.5 mm buccally and palatally, and a distance of 0.5 mm mesially and distally from the peri-implant outline, with the apex of each dental implant used as the axis origin.⁸ All measurements were rounded to the nearest decimal.

Variables were divided as follows: those which were converted into numerical measurements, allowing a numerical value to be obtained by clinicians, and those which were defined as dependent variables, which were used to classify patients into a finite number of subgroups. The measurements were made by a single investigator, who was not involved in the treatment of the patients.

The outcome variables obtained from the clinicians' numerical measurements are described in the following sections.

- Marginal bone levels (MBLs) were evaluated for all 4 aspects (the buccal [*b*MBL], palatal [*p*MBL], mesial [*m*MBL], and distal [*d*MBL] sides) by subtracting the implant length from the crestal bone height. Because the implant base had been initially positioned at the marginal bone level, this could be used as a point of reference. MBLs were measured at T_1 , T_2 , and T_3 .
- Clinical probing depth (CPD) was evaluated at the 5-year follow-up (T_3) for all 4 aspects (buccal [*b*CPD], palatal [*p*CPD], mesial [*m*CPD], and distal [*d*CPD] sides) with a 15-mm UNC periodontal probe (CP 15 UNC; Hu Friedy, Chicago, Ill, USA), and the measurements were performed to the nearest millimeter.
- Probing attachment level (PAL) was evaluated at the 5-year follow-up (T_3) for all 4 aspects (buccal [*b*PAL], palatal [*p*PAL], mesial [*m*PAL], and distal [*d*PAL] sides) with a 15-mm UNC periodontal probe (CP 15 UNC; Hu Friedy, Chicago, Ill, USA), and the measurements were performed to the nearest millimeter.

All patients were clinically examined 12 months after implant placement, and then twice for the rest of the follow-up period of 5 years, as is depicted in the postoperative maintenance program. Clinical probing depth (CPD) and probing attachment level (PAL) were recorded at T_3 .

A survived implant was defined as being immobile, and free from peri-implant radiolucency, infection, or neurologic disorder,³⁴ and without associated pain, either spontaneous or upon application of a torque of 10 to 20 Ncm.³⁵ In addition, the implant had to allow for placement of a functional fixed prosthesis.³⁶

The dependent variables were:

TABLE 1
Distribution of the overall and enrolled dental implants (diameter and length).

Implant length (mm)	Maxilla						Mandible					
	Overall implants			Enrolled implants			Overall implants			Enrolled implants		
	∅ (mm)			∅ (mm)			∅ (mm)			∅ (mm)		
	3.75	4.10	5.00	3.75	4.10	5.00	3.75	4.10	5.00	3.75	4.10	5.00
Grafted bone												
10	2			1			8		1	0		0
11	7(2)	9	1	2	4	1	6	5		1	4	
13	3	2		1	2		6	3	1	1	1	1
15	1			1			3	5		0	1	
Pristine bone												
8							1	1(1)				
10	2			2			8		1(1)	4		
11	1	3	1		3		3	1		2		
13	7	8	4	4	3	1	5	1	1	3		1
15			1			1	1	1	1	1	1	1

*No. of failures listed in parentheses.

- Type of procedure employed: dental implants placed in pristine bone (P) and in augmented areas with horizontal procedure (H);
- Gender: male (M) or female (F);
- Diameter: (∅: 3.75, 4.10 or 5.00 mm) of implants placed in patients;
- Length (*len*: 10, 11.5 and 13) of implants placed in patients

Statistical analysis

All patient-related data were entered into a database (Database Toolbox, MatLab 7.13.0, The MathWorks, Natick, Mass), allowing for calculations to be performed automatically. Statistical analyses were performed using a statistical tools package (Statistics Toolbox, MatLab 7.13.0, The MathWorks).

Dental implants were grouped according to the area of placement (anterior or posterior) and to the surgical procedure employed (in pristine bone, and after horizontal augmentation). In the comparison tests, to overcome differences between multiple dental implants in the same area, 1 implant per quadrant was randomly selected.³⁷

Normal distribution for each numerical variable was carried out and confirmed by the Lilliefors test. For each of the variables, differences attributable to explanatory factors among the groups were analyzed using multi-way analysis of variance. For all the 4 dependent variables, significances in the $\binom{4}{2}$ 2-factor interactions were looked for. Multiple comparison tests with Tukey's honestly significant difference criterion were applied to the search in significant paired comparisons in the subgroups. For a more conservative analysis, *P*-values were obtained for each significant pair-wise comparison by the Wilcoxon signed rank test for matched samples, and by the Wilcoxon rank sum test for unmatched data. Spearman correlation (r_s) was used to assess the strength of the bivariate association between MBLs and either CPD or CAL variables.

All measurements in the text and tables are described as mean and standard deviations, $\bar{m} \pm \text{std}$. In the figures, distributions have been depicted by whiskers plot. A life table analysis, describing biennial- and cumulative-survival rates (SR

and CSR, respectively) for implants placed in pristine and augmented areas, and 95% confidence intervals (CIs) were calculated, as per Eckert.³⁸

The effect of the sample size was determined with a power analysis by using a 0.05 significance level and a power of 0.9 (Statistics Toolbox, MatLab 7.13.0, The MathWorks), based on mean and standard deviation values, for the outcome variables obtained. The level of statistical significance was set at 0.05 for pair comparison analyses, whereas a value of 0.01 was set for correlation analyses.

RESULTS

Seventeen patients, affected by local bone atrophy, required fixed prosthesis rehabilitation by means of osseointegrated dental implants. Numbers and sizes of the inserted dental implants, with or without bone grafting reconstruction, are shown in Table 1, both for the maxilla and mandible. A total of 28 autogenous blocks were grafted: 9 in 7 maxillae, and 19 in 10 mandibles. Twenty-five and 38 dental implants were then positioned in maxillary- and mandibular-reconstructed areas, respectively. Fifty-two were positioned in pristine bone (27 in the maxilla and 25 in the mandible). There was no sign of nerve damage exhibited postoperatively by any of the patients.³⁴ Regarding dental implants enrolled for statistical comparisons, implants belonging to pristine groups were 14 and 13 in the maxilla and mandible, respectively; 12 dental implants were placed in 7 maxillae (8 blocks), whereas 9 were positioned in 8 horizontal mandibular blocks in 5 mandibles (Table 2).

Peri-implant radiographic bone remodeling and clinical probing measurements

Table 3 and Figure 1 report the data on the remodeling of the peri-implant coronal bone, measured for all aspects at the 3 follow-up times (T_1 , T_2 and T_3). Table 4 shows the mean and standard deviations of the significant compared linear measurements and their respective significance. Data were

TABLE 2

Demographic descriptive analysis of data: age, gender, smoking habit, and number and area (A, anterior; P, posterior) of the enrolled dental implants with height of residual bone (in millimeters) when grafting procedure was required

Patient#	Age (yrs)	Gender	Smoking habits	No. and area of enrolled maxillary implants	Implant in bone	Residual bone thickness (mm)	No. and area of enrolled mandibular implants	Implant in bone	Residual bone thickness (mm)
1	58.7	F	N	2 AP	grafted	3.6			
2	58.7	F	Y	2 AP	grafted	4.9	2 AP	grafted	3.4
3	37.8	M	N	2 AP	pristine		2 AP	pristine	
4	49.0	M	Y				2 AP	grafted	4.9
5	62.2	F	Y	1 P	grafted	2.3	1 P	pristine	3.5
6	51.1	M	Y	2 AP	pristine		2 AP	pristine	
7	54.6	F	N	2 AP	grafted	3.7			
8	41.3	M	N	2 AP	grafted	3.7	1 P	pristine	
9	74.1	F	N				1 P	pristine	
10	56.4	M	N	2 AP	pristine		2 AP	pristine	
11	50.3	F	Y	1 P	grafted	3.1			
12	55	F	N	2 AP	pristine				
13	45.9	M	N	2 AP	pristine		2 AP	grafted	2.9
14	63.3	M	N	2 AP	pristine				
15	51.1	M	Y	2 AP	grafted	3.1	1 P	pristine	
16	37.5	F	Y				1 P	pristine	
17	61.1	M	N	2 AP	pristine		2 AP	grafted	2.2
							2 AP	pristine	

compared searching for differences between procedures (horizontal and pristine) and times.

For maxillary data, no significant differences were discovered between the pristine and horizontal bone grafting procedures, whereas, for each procedure, statistically significant results were obtained when comparing times. In the maxillary pristine group, differences were recorded for the mean distance between the implant base and the alveolar crest, or marginal bone level (MBL), between T_1 and further follow-up times (T_2 and T_3) for the palatal aspect, both in anterior and posterior areas (P as .0039, .0098 and .0137), as well as for the mesial and distal aspects, although here only in posterior regions (P as 9.8×10^{-4} and 0.0244). For the horizontal procedure group in the

maxilla, MBLs showed significant differences between T_1 and T_3 for the buccal and distal aspects only in the anterior areas (P as .0391 and .0195).

Instead, regarding the mandibular data, few significant differences were discovered between procedures and times. In the pristine group, differences at a statistically-significant level were obtained comparing, for the anterior areas, the buccal values of MBL among the times (T_1 vs T_2 , with a P of .0313, and T_2 vs T_3 , with a P of .0156), whereas for anterior m MBLs and posterior p MBLs, differences were obtained between T_1 and T_2 (P of .0469 for both comparisons). Regarding significant differences found among surgical procedures, a difference was discovered only between the

TABLE 3

Descriptive analysis of maxillary- and mandibular-data: linear measurements of coronal vertical bone level (MBL) around dental implant (buccal b -, palatal p -, mesial m -, and distal d -) in augmented- and pristine-sites for the 3 time points considered: at 1-, 3-, and 5-year of survey

Variables	Size	b MBL	b MBL	b MBL	p MBL	p MBL	p MBL	m MBL	m MBL	m MBL	d MBL	d MBL	d MBL
		T_1	T_2	T_3	T_1	T_2	T_3	T_1	T_2	T_3	T_1	T_2	T_3
Times													
Maxilla													
Horizontal procedure	13	-5.0 ± 1.9	-5.7 ± 1.3	-6.1 ± 1.4	-3.3 ± 1.6	-3.7 ± 1.8	-3.7 ± 1.6	-2.5 ± 1.4	-3.4 ± 3.0	-3.0 ± 1.2	-2.8 ± 1.1	-2.6 ± 1.3	-3.7 ± 1.5
		-5.4 (2.5)	-5.6 (2.1)	-6.1 (2.2)	-2.8 (2.7)	-3.3 (3.5)	-3.2 (2.5)	-2.2 (1.6)	-2.7 (1.4)	-2.8 (1.5)	-3.0 (1.8)	-2.7 (1.3)	-3.6 (2.0)
Pristine procedure	14	-4.7 ± 1.6	-4.6 ± 0.7	-5.2 ± 1.8	-2.6 ± 0.8	-3.5 ± 0.4	-3.5 ± 0.9	-2.1 ± 1.5	-3.1 ± 0.5	-2.8 ± 1.1	-2.3 ± 1.1	-3.0 ± 0.7	-3.1 ± 1.2
		-4.8 (1.7)	-4.7 (1.1)	-5.0 (3.0)	-2.8 (1.3)	-3.4 (0.5)	-3.5 (1.6)	-1.6 (1.6)	-3.0 (0.4)	-2.9 (1.6)	-2.0 (1.8)	-3.0 (0.8)	-3.1 (1.0)
Mandible													
Horizontal procedure	9	-6.6 ± 2.3	-6.9 ± 1.0	-7.5 ± 3.2	-2.0 ± 1.4	-3.0 ± 0.8	-1.9 ± 1.3	-2.6 ± 1.4	-4.3 ± 0.8	-2.9 ± 1.3	-3.0 ± 0.9	-3.4 ± 1.6	-2.8 ± 1.5
		-6.8 (3.2)	-7.2 (1.2)	-7.4 (4.5)	-1.9 (1.3)	-3.3 (1.2)	-2.2 (1.4)	-2.1 (2.1)	-4.3 (0.9)	-3.1 (2.1)	-3.1 (1.1)	-3.0 (1.8)	-3.0 (1.8)
Pristine procedure	13	-3.4 ± 2.3	-4.5 ± 2.1	-4.1 ± 1.9	-1.8 ± 1.9	-2.5 ± 1.9	-2.4 ± 1.8	-2.5 ± 2.1	-2.9 ± 2.0	-2.1 ± 1.1	-2.6 ± 2.2	-3.1 ± 2.0	-2.2 ± 1.4
		-3.7 (3.0)	-4.0 (1.5)	-4.2 (2.2)	-1.5 (3.0)	-1.9 (2.4)	-2.1 (2.5)	-2.1 (2.4)	-2.6 (1.6)	-2.1 (1.1)	-2.5 (2.6)	-2.6 (1.8)	-2.0 (1.2)

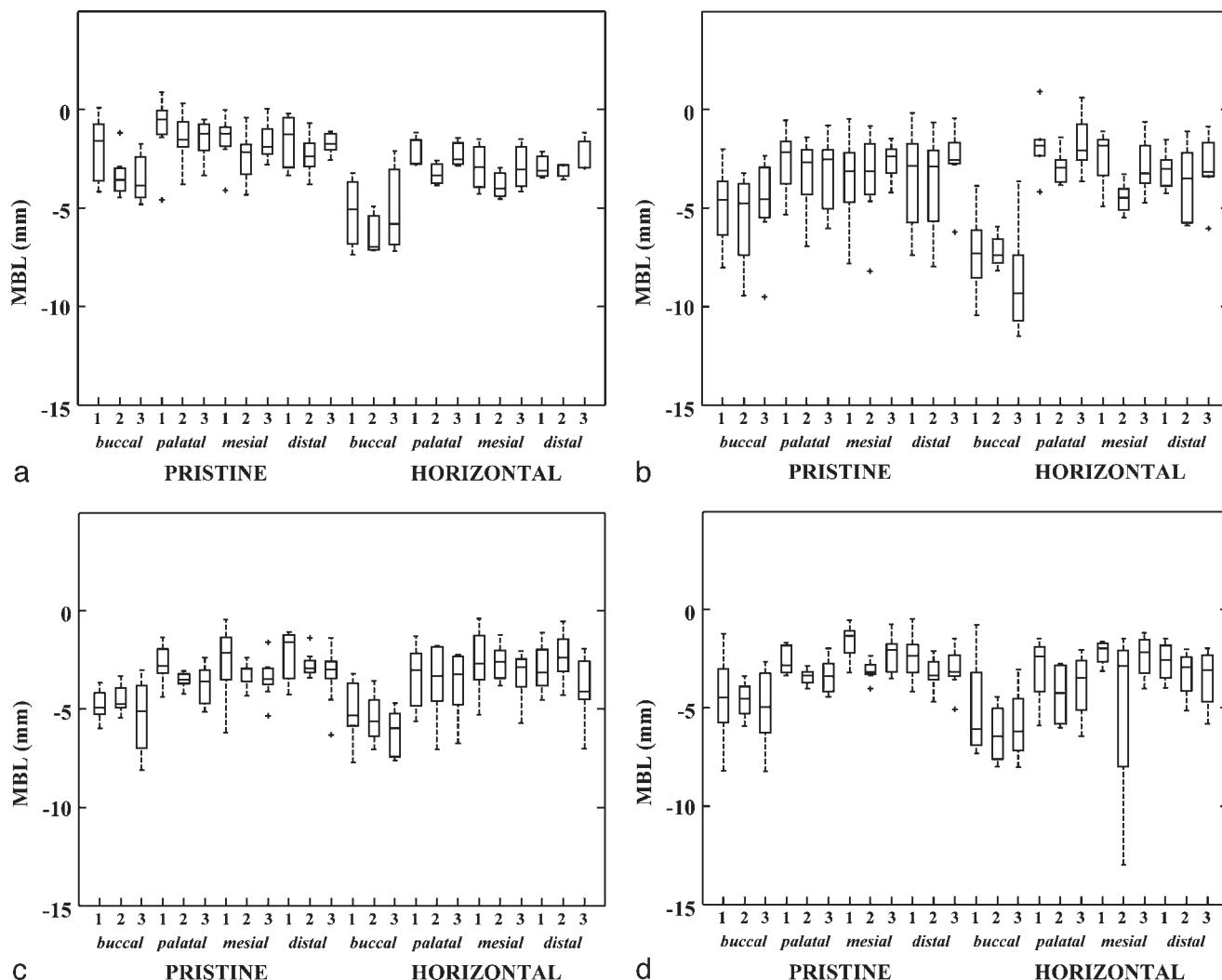


FIGURE 1. Linear distance between the remodeled alveolar crest and the implant base, or marginal bone level (MBL), at 1 year (1), 3 years (2) and 5 years (3) after implant insertion for pristine and horizontal procedure in (a) anterior mandible; (b) posterior mandible; (c) anterior maxilla; (d) posterior maxilla. Box-and-whiskers plot, in which the box line represents the lower quartile, median, and upper quartile values, while the whisker lines include the rest of the data. Outliers were data with values beyond the ends of the whiskers.

pristine- and horizontal-groups concerning MBL at the buccal aspect in the anterior area and at time T₂ (with *P* of .0167).

Clinical measurements of clinical probing depth (CPD) and clinical attachment level (CAL) at the 5-year follow-up are shown in Table 5, but no statistically significant correlations were observed between MBLs and any of the clinical measurements (Table 5).

Clinical survival of implants

Two failures were documented in the pristine group from the first to the third year of the survey in male patients, yielding an overall cumulative survival rate (CSR) of 96.2% (CI, 90.9% to 100%) at the 5-year follow-up. Of the 63 implants placed in grafted areas, 2 failed before the first time point of the follow-up in a female patient, resulting in an overall 5-year CSR of 96.8% (CI, 92.5% to 100%). Table 6 shows the relevant data for the upper and lower arch. Note that for maxillary pristine bone and for mandibular grafted bone, all 65 dental implants

survived up to the 60-month follow-up examination, thereby yielding a CSR of 100% at 5 years. The success, as per Albrektsson,³⁴ of dental implants placed via the 2 procedures appeared quite low, but an exact calculation was nonessential for the present purpose; moreover, the number of the enrolled implants for which a radiological bone resorption was attained was very poor.

DISCUSSION

Although the present data seem to confirm the reliability of the procedures described in the paper, the results in terms of resorption, around implants in pristine and in augmented bone, should be examined with great attention. Throughout the present analysis of maxillary data, no significant differences were recorded between pristine- and horizontal-procedures, probably due to the limited size of the sample. The pristine maxillary group seemed to show, comparing T₁ to further

TABLE 4

Overall discovered significant pair-wise comparisons by the Wilcoxon signed rank test for matched samples (*) and by the Wilcoxon rank sum test for unmatched data (†): only significant P-values were showed. Each aspect analyzed is shown in coupled factors, the area (anterior or posterior) and either the time of follow-up (T₁, T₂, T₃) or the surgical procedures applied (horizontal and pristine), and either the compared times (Time A and B, for paired data) or procedures (A and B, for unpaired data), with the calculated P-value and respective variable means and standard deviations and the estimated effect size for analyzed comparisons

Outcome Variable	Coupled interacting factors	Time or procedure A	Time or procedure B	A	B	P-value Wilcoxon tests	Estimated effect size
Results for linear model in the maxilla							
pMBL	pristine anterior	T ₁	T ₃	- 2.7 ± 1.0	- 3.8 ± 1.0	0.0039*	11
pMBL	pristine posterior	T ₁	T ₂	- 2.6 ± 0.7	- 3.4 ± 0.4	0.0098*	8
pMBL	pristine posterior	T ₁	T ₃	- 2.6 ± 0.7	- 3.3 ± 0.9	0.0137*	17
mMBL	pristine posterior	T ₁	T ₂	- 1.7 ± 0.8	- 3.1 ± 0.5	9.8 × 10 ⁻⁴ *	5
dMBL	pristine posterior	T ₁	T ₂	- 2.4 ± 1.1	- 3.2 ± 0.7	0.0244*	17
bMBL	horizontal anterior	T ₁	T ₃	- 5.0 ± 1.5	- 6.2 ± 1.2	0.0391*	16
dMBL	horizontal anterior	T ₁	T ₃	- 2.9 ± 1.1	- 3.8 ± 1.6	0.0195*	27
Results for linear model in the mandible							
bMBL	pristine anterior	T ₁	T ₂	- 2.0 ± 1.6	- 3.4 ± 1.1	0.0313*	13
bMBL	pristine anterior	T ₁	T ₃	- 2.0 ± 1.6	- 3.6 ± 1.2	0.0156*	11
mMBL	pristine anterior	T ₁	T ₂	- 1.5 ± 1.3	- 2.4 ± 1.3	0.0469*	24
pMBL	pristine posterior	T ₁	T ₂	- 2.7 ± 1.6	- 3.4 ± 1.9	0.0469*	69
bMBL	T ₂ anterior	pristine	horizontal	- 3.4 ± 1.1	- 6.4 ± 1.3	0.0167†	5

times, a widespread resorption, primarily in the posterior area, in which the *palatal*, *mesial*, and *distal* sides were affected. Resorption around implants placed into horizontally-grafted bone of the anterior maxilla seemed to be limited to just the *buccal* and *distal* sides. Moreover, bMBL at the fifth year of follow-up appeared quite negatively remodeled, showing a value of -6.2 ± 1.2 mm, that was different at a statistically significant level from that of the first year, which was -5.0 ± 1.5 mm with a *P* of .0391, indicating that the resorption phenomenon seemed, indeed, mostly to occur in the first year.

These results confirmed the data found in the literature coming from identical long-time surveys; after onlay bone grafting in the posterior maxilla, the analysis of the postoperative behavior, after dental implant insertion, led to an estimated mean reduction of the residual bone height very close to 40% at the 5-year point of the survey;³⁹ the present data would lead us to presume that an onlay block bone, when it is grafted to increase the horizontal dimension, is more susceptible to remodeling, especially in the buccal side, and specifically in the present patient sample, mainly in the maxillary augmented area.

Again, a general and overall bone remodeling was not verified for the horizontal procedure in the mandible, in which, as reported for both arches, comparisons with the pristine procedure showed that only the buccal sides were involved. The analysis of time comparisons revealed that only the pristine group seemed to show a continuous alveolar bone remodeling

over the course of the entire survey. Although the highest value of bone remodeling among significant comparisons was -3.6 ± 1.2 mm, which is the marginal bone level of the buccal side of the anterior mandible at the fifth year of the survey, the remaining significant time comparisons were between T₁ and T₂. Meanwhile, in the pristine group, bone resorption seemed to be extended till the third year of follow-up. The lack of significance regarding time comparisons for mandibular augmented alveolar crest MBLs was probably due to a very wide peri-implant bone resorption during the first year after dental implant insertion, as is shown by the marked values expressed in Table 3 and in Figure 1.

For long-term surveys found in the literature on marginal bone loss in the mandible, data related to augmented alveolar crest is very scant; in those studies describing marginal bone loss, only implants placed in pristine bone were considered, yielding a crestal bone loss at mesial and distal implant sites ranging from 0 to 5.3.¹² Moreover, changes in a pooled mean marginal bone level, irrespective of the arches, ranged from 0.24 mm to 0.75 mm over 5 years for the 3 different brands of dental implants examined, although notwithstanding the weight of this meta-analysis, no surgical augmentation was considered, and no distinction among different aspects was investigated.¹¹ No conclusive results were shown regarding either clinical probing depth (CPD) or probing attachment level (PAL) when they were compared to MBLs.

TABLE 5

Measurements of clinical probing depth, CPD, and clinical attachment level, CAL, at the 5-year follow-up. Spearman r_s correlation coefficients between either CPDs or CALs and respective overall values of marginal bone levels for augmented or pristine areas in the upper and lower arched. No statistically-significant data at 0.01 level (2-tailed)

	CPDs (mm)				CALs (mm)			
	Buccal	Palatal	Mesial	Distal	Buccal	Palatal	Mesial	Distal
Maxilla								
Analysis at 5th year								
Horizontal procedure								
Clinical probing	1.3 ± 0.6	2.2 ± 1.3	2.0 ± 1.2	2.2 ± 0.9	2.4 ± 1.0	2.4 ± 1.4	2.3 ± 1.0	2.3 ± 1.0
Correlation coefficient (r_s)	-0.865	-0.1830	-0.0611	0.1270	-0.1371	-0.4286	0.1913	-0.2692
Significance (two-tailed)	0.7788	-0.5496	0.8427	0.6794	0.6552	0.1439	0.5313	0.3738
Pristine procedure								
Clinical probing	2.6 ± 1.4	3.5 ± 2.2	2.7 ± 2.3	2.8 ± 2.0	3.3 ± 1.3	3.9 ± 2.1	3.5 ± 1.9	3.6 ± 1.8
Correlation coefficient (r_s)	0.3477	-0.1650	-0.1652	0.2343	0.0357	-0.1832	-0.0096	-0.2189
Significance (two-tailed)	0.1331	0.4871	0.4865	0.3201	0.8811	0.4394	0.9678	0.3539
Mandible								
Analysis at 5th year								
Horizontal procedure								
Clinical probing	1.2 ± 0.4	2.0 ± 1.6	2.2 ± 2.2	2.3 ± 1.7	2.8 ± 1.1	1.4 ± 1.0	1.9 ± 0.8	2.3 ± 1.5
Correlation coefficient (r_s)	0.5175	0.0990	0.06208	0.6588	0.873	0.2202	0.3385	0.4547
Significance (two-tailed)	0.2222	0.8135	0.0866	0.0656	0.3466	0.5873	0.3698	0.2193
Pristine procedure								
Clinical probing	1.9 ± 1.2	1.7 ± 1.5	2.8 ± 1.7	2.6 ± 1.8	2.4 ± 1.7	2.6 ± 1.6	2.6 ± 1.7	3.0 ± 2.3
Correlation coefficient (r_s)	-0.4873	0.5702	-0.0045	-0.1353	0.0045	0.3893	-0.1358	-0.1475
Significance (two-tailed)	0.0772	0.0333	0.9878	0.6447	0.9879	0.1688	0.6435	0.6148

The reliability and consistency of present implant survival in pristine bone, summarized by the CSR value of 96.2% (CI, 90.9% to 100%) at the 5-year follow-up, was demonstrated by the similarity in CSR to that reported by Eckert, which was 96% (CI, 93% to 98%).³⁸ The cumulative survival rate for grafted areas (5-year CSR), which reached 96.8% (CI, 92.5% to 100%), was very close to the mean survival rate of 93.4% (range, 80% to 100%) of implants placed in reconstructed maxillae with a staged approach, reported by Chiapasco,⁶ and to the value of 94.4% (CI, 89.0% to 99.9%), obtained in the review paper of Lambert,

for rough surface implants placed in grafted bone, but only for the upper arch.⁷

The value of the estimated effect of the size of the sample was, on average, less than 19 for the 12 paired-comparisons discovered, and this data confirmed resulting statistical significances. It is likely that with an increase in the sample size of up to 50 subjects, significant differences would be revealed between the two procedures.

The restricted sample size was one of the main limitations of the study; moreover, due to its retrospective nature, neither

TABLE 6

Life table analysis of survival of the overall 115 implants, 52 positioned in the maxilla, and 63 implants inserted in the mandible

Bone type/Interval (y)	Implants at start of interval	Dropouts	Implants at risk	Failures during interval	Survival rate (%)	Cumulative survival rate (%)	CI (%)
Maxilla							
Pristine bone							
0-1	27	0	27	0	100	100	-
1-3	27	0	27	0	100	100	-
3-5	27	0	27	0	100	100	-
Grafted bone							
0-1	25	0	25	2	92	92	81.4-100
1-3	23	0	23	0	100	92	81.4-100
3-5	23	0	23	0	100	92	81.4-100
Mandible							
Pristine bone							
0-1	25	0	25	0	100	100	-
1-3	25	0	25	2	92	92	81.4-100
3-5	23	0	23	0	100	92	81.4-100
Grafted bone							
0-1	38	0	38	0	100	100	-
1-3	38	0	38	0	100	100	-
3-5	38	0	38	0	100	100	-

a masked nor a randomized prior selection of patients was applied. Then, notwithstanding the standardized acquisition of radiological or clinical data, the accuracy of the analysis was highly influenced by the level of expertise of the researchers. An advantageous feature of the present retrospective chart review was the long-term survey based on CT scans that allowed for analysis of the four aspects around placed dental implants. Confirmation of these current findings and the speculations advanced will, in any event, require longer periods of observation, and, moreover, a higher number of enrolled implants.

CONCLUSION

Clinicians planning placement of dental implants for fixed prosthesis in reconstructed alveolar bone with horizontal autografts should consider the extremely unfavorable resorption at the buccal aspect of the augmented area. Notwithstanding the fact that the loss of buccal marginal bone level did not appear to jeopardize implant survival, which seemed most likely due to the less intensive bone remodeling of the remaining three aspects, the authors suggest reserving dental implant positioning into horizontal bone grafts as a treatment for a select minority of patients in whom it may represent one of the last opportunities of rehabilitation with a fixed prosthesis.

ABBREVIATIONS

CAL: clinical attachment level
 CI: confidence interval
 CPD: clinical probing depth
 CSR: cumulative survival rate
 CT: computerized tomography
 MBL: marginal bone level
 PAL: probing attachment level
 SR: biennial survival rate

ACKNOWLEDGMENTS

Clinical data were collected by the group composed by Prof. Ludovico Sbordone, MD, DDS; Dr. Franco Guidetti, MD; Dr. Giovan Battista Menchini Fabris, DDS (former research fellow of the Department of Surgery, University of Pisa/ U.O.C. Odontostomatology and Implantology A.O.U.P.); and Dr. Paolo Toti BSc, DDS. The present study has been supported in part through the Ministero dell'Istruzione, Università e Ricerca Scientifica (MIUR Italian Dept. of Education, University and Scientific Research) PRIN 2008 2008K4XXF8_02 (CUP G51J10000030001) to Prof. Ludovico Sbordone, and 2008K4XXF8_03 (CUP E61J100000200001) to Prof. Ranieri Martuscelli.

REFERENCES

1. Hirsch JM, Brånemark PI. Fixture stability and nerve function after transposition and lateralization of the inferior alveolar nerve and fixture installation. *Br J Oral Maxillofac Surg.* 1995;33:276–281.

2. Pogrel MA, Podlesh S, Anthony JP, Alexander J. A comparison of vascularized and nonvascularized bone grafts for reconstruction of mandibular continuity defects. *J Oral Maxillofac Surg.* 1997;55:1200–1206.
3. Foster RD, Anthony JP, Sharma A, Pogrel MA. Vascularized bone flaps versus nonvascularized bone grafts for mandibular reconstruction: an outcome analysis of primary bone union and osseous implant success. *Head Neck.* 1999;21:66–71.
4. Stellingsma K, Raghoebar GM, Meijer HJ, Stegenga B. The extremely resorbed mandible: a comparative prospective study of 2-year results with 3 treatment strategy. *Int J Oral Maxillofac Implants.* 2004;19:563–577.
5. Srinivasan M, Vazquez L, Rieder P, Moraguez O, Bernard JP, Belser UC. Efficacy and predictability of short dental implants (<8 mm): a critical appraisal of the recent literature. *Int J Oral Maxillofac Implants.* 2012;27:1429–1437.
6. Chiapasco M, Casentini P, Zaniboni M. Bone augmentation procedures in implant dentistry. *Int J Oral Maxillofac Implants.* 2009;24:237–259.
7. Lambert FE, Weber HP, Susarla SM, Belser UC, Gallucci GO. Descriptive analysis of implant and prosthodontic survival rates with fixed implant-supported rehabilitations in the edentulous maxilla. *J Periodontol.* 2009;80:1220–1230.
8. Sbordone L, Toti P, Menchini-Fabris GB, Sbordone C, Guidetti F. Implant survival in maxillary and mandibular osseous onlay grafts and native bone: a 3-year clinical and computerized tomographic follow-up. *Int J Oral Maxillofac Implants.* 2009;24:695–703.
9. Sbordone L, Levin L, Guidetti F, Sbordone C, Glikman A, Schwartz-Arad D. Apical and marginal bone alterations around implants in maxillary sinus augmentation grafted with autogenous bone or bovine bone material and simultaneous or delayed dental implant positioning. *Clin Oral Implants Res.* 2011;22:485–491.
10. Sbordone C, Toti P, Guidetti F, Califano L, Pannone G, Sbordone L. Volumetric changes after sinus augmentation using blocks of autogenous iliac bone or freeze-dried allogeneic bone. A non-randomized study. *J Craniomaxillofac Surg.* 2014;42:113–118.
11. Laurell L, Lundgren D. Marginal bone level changes at dental implants after 5 years in function: a meta-analysis. *Clin Implant Dent Relat Res.* 2011;13:19–28.
12. Ueda T, Kremer U, Katsoulis J, Mericske-Stern R. Long-term results of mandibular implants supporting on overdenture: implant survival, failure, and crestal bone level changes. *Int J Oral Maxillofac Implants.* 2011;26:365–372.
13. Esposito M, Grusovin MG, Felice P, Karatzopoulos G, Worthington HV, Coulthard P. Interventions for replacing missing teeth: horizontal and vertical bone augmentation techniques for dental implant treatment. *Cochrane Database Syst Rev.* 2009;4:CD003607.
14. von Arx T, Buser D. Horizontal ridge augmentation using autogenous block grafts and the guided bone regeneration technique with collagen membranes: a clinical study with 42 patients. *Clin Oral Impl Res.* 2006;17:359–366.
15. Pelo S, Boniello R, Gasparini G, Longobardi G, Amoroso PF. Horizontal and vertical ridge augmentation for implant placement in the aesthetic zone. *Int J Oral Maxillofac Surg.* 2007;36:944–948.
16. Boronat A, Carrillo C, Penarrocha M, Penarrocha M. Dental implants placed simultaneously with bone grafts in horizontal defects: a clinical retrospective study with 37 patients. *Int J Oral Maxillofac Implants.* 2010;25:189–196.
17. Urban I, Nagursky H, Lozada JL. Horizontal ridge augmentation with resorbable membrane and particulate autogenous bone with or without anorganic bovine bone-derived mineral: a prospective case series in 22 patients. *Int J Oral Maxillofac Implants.* 2011;26:404–414.
18. Toti P, Sbordone C, Martuscelli R, Califano L, Ramaglia L, Sbordone L. Gene clustering analysis in human osteoporosis disease and modifications of the jawbone. *Arch Oral Biol.* 2013;58:912–929.
19. Sbordone C, Toti P, Guidetti F, Califano L, Santoro A, Sbordone L. Volume changes of iliac crest autogenous bone grafts after vertical and horizontal alveolar ridge augmentation of atrophic maxillas and mandibles: a 6-year computerized tomographic follow-up. *J Oral Maxillofac Surg.* 2012;70:2559–2565.
20. Misch CM. Comparison of intraoral donor sites for onlay grafting prior to implant placement. *Int J Oral Maxillofac Implants.* 1997;12:767–776.
21. Balaji SM. Management of deficient anterior maxillary alveolus with mandibular parasymphseal bone graft for implants. *Implant Dent.* 2002;11:363–369.
22. Claverio J, Lundgren S. Ramus or chin grafts for maxillary sinus inlay

and local onlay augmentation: comparison of donor site morbidity and complications. *Clin Implant Dent Relat Res.* 2003;5:154–160.

23. Sbordone L, Menchini-Fabris GB, Toti P, Sbordone C, Califano L, Guidetti F. Clinical survey of neurosensory side-effects of mandibular parasymphseal bone harvesting. *Int J Oral Maxillofac Surg.* 2009;38:139–145.

24. Sbordone C, Toti P, Guidetti F, Martuscelli R, Califano L, Sbordone L. Healing of donor defect after mandibular parasymphseal block harvesting: A 6-year computerized tomographic follow-up. *J Craniomaxillofac Surg.* 2012;40:421–426.

25. Grillon GL, Gunther SF, Connole PW. A new technique of obtaining iliac bone graft. *J Oral Maxillofac Surg.* 1984;42:172–176.

26. Kalk WWI, Raghoebar GM, Jansma J, Boering G. Morbidity From Iliac Crest Bone Harvesting. *J Oral Maxillofac Surg.* 1996;54:1424–1429.

27. Sbordone C, Toti P, Guidetti F, Califano L, Bufo P, Sbordone L. Volume changes of autogenous bone after sinus lifting and grafting procedures: A 6-year computerized tomographic follow-up. *J Craniomaxillofac Surg.* 2013;41:235–241.

28. Sbordone C, Toti P, Ramaglia L, Guidetti F, Sbordone L, Martuscelli R. A 5-year clinical and computerized tomographic implant follow-up in sinus-lifted maxillae and native bone. *Clin Oral Implants Res.* 2014;25:1056–1064.

29. Sbordone C, Sbordone L, Toti P, Martuscelli R, Califano L, Guidetti F. Volume changes of grafted autogenous bone in sinus augmentation procedure. *J Oral Maxillofac Surg.* 2011;69:1633–1641.

30. Keller EE. Reconstruction of the severely atrophic edentulous mandible with endosseous implants: a 10-year longitudinal study. *J Oral Maxillofac Surg.* 1995;53:305–320.

31. Bell RB, Blakey GH, White RP, Hillebrand DG, Molina A. Staged reconstruction of the severely atrophic mandible with autogenous bone graft and endosteal implants. *J Oral Maxillofac Surg.* 2002;60:1135–1141.

32. Triplett RG, Schow SR. Autologous bone grafts and endosseous implants: complementary technique. *J Oral Maxillofac Surg.* 1996;54:486–494.

33. Sethi A, Kaus T. Ridge augmentation using mandibular block bone grafts: preliminary results of an ongoing prospective study. *Int J Oral Maxillofac Implants.* 2001;16:378–388.

34. Albrektsson T, Zarb G, Worthington P, Eriksson AR. The long term efficacy of currently used dental implants: a review and proposed criteria of success. *Int J Oral Maxillofac Implants.* 1986;1:11–25.

35. Smedberg JI, Johansson P, Ekenback J, Wannfors D. Implants and sinus-inlay graft in a 1-stage procedure in severely atrophied maxillae: prosthodontic aspects in a 3-year follow-up study. *Int J Oral Maxillofac Implants.* 2001;16: 668–674.

36. Smith DE, Zarb GA. Criteria for success of osseointegrated endosseous implants. *J Prosthet Dent.* 1989;62:567–572.

37. Herrmann I, Lekholm U, Holm S, Kultje C. Evaluation of patient and implant characteristics as potential prognostic factors for oral implant failures. *Int J Oral Maxillofac Implants.* 2005;20:220–230.

38. Eckert SE, Choi YG, Sanchez AR, Koka S. Comparison of dental implant systems: quality of clinical evidence and prediction of 5-year survival. *Int J Oral Maxillofac Implants.* 2005;20:406–415.

39. Wiltfang J, Schultze-Mosgau S, Nkenke E, Thorwarth M, Neukam FW, Schlegel KA. Onlay augmentation versus sinuslift procedure in the treatment of the severely resorbed maxilla: a 5-year comparative longitudinal study. *Int J Oral Maxillofac Surg.* 2005;34:885–889.