

# Effect of Recombinant Human Growth Hormone on Osseointegration of Titanium Implants: A Histologic and Biomechanical Study in Rabbits

Marcelo Emir Requia Abreu, DDS, MS, PhD<sup>1</sup>  
 Renato Valiati, DDS, MS, PhD<sup>2</sup>  
 Roberto Hubler, MS, PhD<sup>3</sup>  
 Aury Nunes Moraes, DVM<sup>4</sup>  
 Fernando Antonini, DDS, MS<sup>5\*</sup>  
 Henrique do Couto de Oliveira, DDS, MS<sup>5</sup>  
 Rogério Miranda Pagnoncelli, DDS, MS, PhD<sup>5</sup>

To evaluate the action of recombinant human growth hormone (rhGH) on osseointegration of titanium implants in rabbits. Fourteen adult New Zealand rabbits, aged 30 weeks, were used in the study, and randomly divided into 2 groups. In each animal, 2 (2.2 mm × 6 mm) pure titanium implants were placed in the left tibia. In one group (test group), 1 IU (0.3 mg) of rhGH as a lyophilized powder was applied to each osteotomy site prior to implant placement. Only titanium implants were placed in osteotomy sites of the other group (control). Animals were humanely killed at 14 and 42 days after surgery, and samples were then prepared for histologic analysis and biomechanical test. The biomechanical test showed tensile pull-out stress values of 33.88 N/cm<sup>2</sup> for controls and 59.26 N/cm<sup>2</sup> for the rhGH group at 14 days and 25.99 N/cm<sup>2</sup> and 29.69 N/cm<sup>2</sup> for the control and the test group, respectively, at 42 days. Scanning electron microscope analysis showed more uniform and abundant bone tissue in contact with the implants for the test group at 14 days, and no differences between groups at 42 days. Furthermore, histologic analysis also showed accelerated bone repair in 14 days and a more advanced stage of bone remodeling for the rhGH-treated group when compared to controls after 42 days of repair. Such results show that the topical use of rhGH induces new bone formation in the early stages of bone repair and hence accelerates osseointegration of titanium dental implants.

**Key Words:** growth hormone, osseointegration, bone repair

## INTRODUCTION

Replacement of lost teeth has been successfully achieved with the use of bone-anchored implant-retained prosthesis. The time to achieve complete osseointegration and its quality, however, has been associated with many features such as implant surface, bone quality at the recipient site, and systemic factors such as endocrine actions.<sup>1,2</sup>

Some research has sought to investigate the role of growth factors (GFs) in bone physiology, which are endogenous proteins capable of activating receptors on cell surfaces directly involved in bone tissue regeneration. GFs include growth hormone (GH), insulin-like growth factor (IGF-1 and -2),

fibroblast growth factor (FGF-2), melatonin, parathyroid hormone (PTH), calcitonin, and morphogenetic and osteogenic proteins, among others.<sup>3-8</sup> In oral implantology, GFs seem to be particularly suitable for accelerating bone repair and enhancing bone implant osseointegration and/or bone graft incorporation in poor quality or deficient bone situations.<sup>2</sup>

GH is a water-soluble endogenous protein that acts as a regulator of postnatal bone growth and as an agent for bone remodeling. This hormone acts on osteoclasts and, most prominently, on osteoblasts. An overall anabolic effect on skeletal tissue is therefore theoretically possible.<sup>3-10</sup> GH is synthesized by the anterior pituitary gland, and its secretion or inhibition is regulated by a feedback loop mediated by GFs, such as IGF-1, sex steroids, and nutritional status. GH is distributed systemically from the anterior pituitary throughout the body and is known to degrade inside body tissues and peripheral circulation. The hormone is then rapidly excreted by the kidneys and liver, remaining in the blood for a short period of time.<sup>9,10</sup> Moreover, GH effects are mediated directly by membrane-bound GH receptors of most body cells or indirectly by increased IGF-1 synthesis by the liver. The hormone secretion is not constant and occurs by liberation spurs, mostly

<sup>1</sup> Private practice, Porto Alegre, Brazil.

<sup>2</sup> Universidade do Planalto Catarinense, Lages, Brazil.

<sup>3</sup> Department of Physics, Pontifícia Universidade Católica do Rio Grande do Sul, Porto Alegre, Brazil.

<sup>4</sup> School of Veterinary Medicine, Universidade do Estado de Santa Catarina, Lages, Brazil.

<sup>5</sup> Oral and Maxillofacial Surgery Department, Pontifícia Universidade Católica do Rio Grande do Sul, Porto Alegre, Brazil.

\* Corresponding author, e-mail: fernando.antonini@acad.pucrs.br

DOI: 10.1563/AAID-JOI-D-13-00306

at night. GH secretion is a lifelong process, with peak secretion during puberty and a marked decrease after the age of 60.<sup>9,10</sup>

GH affects the function of most body cells, directly increasing intracellular metabolism and thus promoting whole-body growth. GH acts on protein synthesis, multiplication and differentiation of certain specific cell types, such as bone-forming cells and immature muscle cells.<sup>8,10</sup> In bone tissue, GH promotes increased protein deposition by chondrocytes and osteoblasts, increased rate of mitosis, and conversion of chondrocytes into osteoblasts.<sup>3-5,9,10</sup> In this context, GH has been used experimentally to stimulate bone healing, either by topical application in bone defects aiming to obtain osteoinductive paracrine and/or autocrine effects, or by parenteral administration aiming at endocrine actions. However, few studies have investigated the effects of GH on the healing of bone fractures<sup>5,11-15</sup> and on the osseointegration process of titanium implants.<sup>16-25</sup>

The aim of this study was to evaluate the effects of topical application of recombinant human growth hormone (rhGH) on osseointegration of titanium implants in rabbits at 14 and 42 days following implant placement.

## MATERIALS AND METHODS

### *Animal model and implantation*

Fourteen adult New Zealand male rabbits aged approximately 30 weeks old and randomly divided in 2 groups were used in this study. Animals were kept in individual cages and received a standard diet of 180 g of rabbit food (Nutricoeelho PURINE, Nestle Purina PetCare Company, Paulínia, SP, Brazil) and given filtered drinking water ad libitum throughout the entire experimental phase. All interventions were approved by the Animal Care Committee and Ethics in Research Committee of Catholic University of Rio Grande do Sul, Brazil (protocol 10/00165). The study was conducted under the supervision of the Veterinary Medicine Department of Santa Catarina State University, Brazil (protocol 13810). National Institutes of Health guidelines for animal care (NIH Publication 85-23 REV. 1985) were followed.

Mean body weight was 3.281 kg in the rhGH-treated group of animals and 2.735 kg in the control group. Preanesthesia medication (4 mg/kg acepromazine and 0.2 mg/kg butorphanol) was administered intramuscularly before intravenous induction of anesthesia with 50 mg/kg ketamine (Dopalen, Vetbrands Animal Health, Jacareí, SP, Brazil) and 0.5 mg/kg diazepam (Rompun, Bayer SA, São Paulo, SP, Brazil). All animals received intramuscular injection of broad-spectrum antibiotic—amoxicillin 20 mg/kg and clavulanate potassium 5 mg/kg combination—as perioperative antibiotic prophylaxis. After anesthetic induction, the animals were placed in a supine position and the medial portion of the left tibia was shaved. Using a sterile technique, the surgical sites were brushed using povidone-iodine solution (PVPI Asteriodine Dye, Medical Products Ltd, Aster, Sorocaba, SP, Brazil), and the operative fields were isolated by disposable sterile drapes. Prior to surgical incisions, 0.6 mL of 2% lidocaine solution containing 1:100 000 diluted epinephrine (DFL, Rio de Janeiro, Brazil) was administered via local infiltration to induce anesthesia and

hemostasis. A medial approach was performed through a linear incision in the medial portion of the tibia, using a number 15 scalpel blade (Free Bac, Embramac, São Paulo, SP, Brazil), starting 1.5 cm distal to the tibio-femoral joint and extending 3 cm distally. The incision was made through skin and subcutaneous tissue, followed by blunt dissection of the underlying flexor muscle. After dissection and retraction of the muscle, the underlying fascia and periosteum were incised, providing adequate access to the posterior-medial tibia.

Two titanium cylindrical implants (2.2 mm in diameter and 6 mm in length), specially designed for the study, were placed in the tibia plateau 16 mm apart from each other. The implant surface had been roughened by means of atmospheric plasma-sprayed titanium coating. Such process for implant surface preparation was previously described by Renz et al.<sup>26</sup> Implant sites were surgically drilled using a 2-mm diameter bur (Colosso, Itu, Brazil) rotated at 637 rpm to perforate through the cortical bone. The site was enlarged and deepened to the planned diameter and depth by using a 2.2-mm diameter drill (Straumann, Basel, Switzerland). The depth of the perforation was standardized to 4 mm for a 6-mm long implant, leaving 2 mm of the implant in supracrestal position in order to allow and facilitate subsequent biomechanical tests. The entire procedure was performed under copious irrigation with 0.9% saline solution (sodium chloride solution 0.9%, Sanobiol Laboratory, São Paulo, SP, Brazil).

Prior to implant placement a layer of 1 IU (0.3 mg) of rhGH as a lyophilized powder (Saizen, Serono Laboratories, Aubonne, Switzerland) was applied to each osteotomy site in all animals comprising the test group. Nothing besides the titanium implant was placed into the osteotomy sites created in animals comprising the control group.

Considering that implants in both groups and placement of the rhGH powder in the control group were successfully performed, the surgical field was then sutured in a layered fashion using 3-0 resorbable polyglactin 910 and 4-0 non-resorbable nylon suture (Ethicon 6.0, Johnson & Johnson Co, New Brunswick, NJ). The animals were then allowed to recover in their individual cages for a 7-day period in order to restrict postoperative movement of the tibia. During the same period, antibiotic regimen was kept by adding the medication to the water supplied to the animals in order to prevent infections. The animals also received oral ketoprofen (10 mg/kg) in the water for 3 days for postoperative analgesia. Animals were evaluated twice daily, and surgical wounds were inspected daily throughout the experimental period. Skin sutures were removed 10 days after the surgeries.

### *Sacrifice and specimen preparation*

Eight animals were humanely killed 14 days postoperatively (4 animals in the control group [group A] and 4 animals in the rhGH-treated group [group B]) and 6 animals were humanely killed 42 days after surgery (3 animals in the control group [group C] and 3 animals in the rhGH-treated group [group D]). The animals were killed by intravenous administration of sodium thiopental and circulatory arrest was induced with potassium chloride. Two animals were excluded from the study (1 animal in group A and another in group B) due to fractures in the implant zone, leaving 3 animals in each group (A, B, C, D)

for biomechanical and histologic tests. Next, the animals had the operated tibia disarticulated and soft tissues were dissected from the tibial bone. Excised samples were then labeled and fixed in 10% neutral buffered formalin (formaldehyde 10% PA, ChemcolIndústria e Comércio Ltda, Campinas, SP, Brazil).

#### **Biomechanical testing and scanning electron microscope analysis**

One implant from each group (A, B, C, D) was subjected to biomechanical testing (tensile pull-out test). The tibiae were embedded in unsaturated polyester resin (Resapol 10-249, Reichhold Co, Durham, NC), keeping the extraosseous portion of the implant exposed. Specimens were then mounted on a testing machine (EMIC DL-2000, EMIC, São José dos Pinhais, PR, Brazil). The test consisted of measuring the mechanical strength required to extrude the implant from the tibia. Measurements were made using a load cell of 500 N and a constant strain rate of 1 mm/min. The tensile load was applied until a complete detachment of the implant from the bone was achieved. The stress-strain curve was recorded and the energy values were calculated based on the resulting curve.

After the implants were detached from the tibia by the tensile pull-out test and biomechanical measures completed, the bone tissue that remained attached to the implants was subjected to qualitative analysis using a scanning electron microscope (SEM; Philips XL30 FEG-SEM, Philips, Eindhoven, Netherlands). Implants were linearly arranged along their long axis and randomly placed into slots for image acquisition at a magnification of  $\times 50$ ,  $\times 100$ ,  $\times 200$ , and  $\times 500$ .

#### **Histologic evaluation**

Two samples from each group (A, B, C, D) were submitted to histologic analysis of peri-implant newly formed bone. Implants were removed by decalcification of the tibia using 50% formic acid solution (PA formic acid, ChemcolIndústria e Comércio Ltda, Campinas, SP, Brazil) and 20% sodium citrate (20% sodium citrate bp ChemcolIndústria e Comércio Ltda) for 60 days, replacing the solution every 48 hours. Four implants were removed from the tibia by the biomechanical testing carried out previously. Peri-implant bone was then dehydrated by immersing the specimens in 50%, 70%, 90%, and 96% ethyl alcohol solution and absolute alcohol afterwards. The pieces were kept in ethyl alcohol for 3 hours in each concentration and for 24 hours in absolute alcohol (alcohol ethyl 99.5% PA, ChemcolIndústria e Comércio Ltda). The pieces were next placed in xylene (ChemcolIndústria e Comercio Ltda) for 2 hours and then embedded in paraffin (Paraplast Tissue Embedding Media, McCormick Scientific, St Louis, Mo) for sectioning. Sections were cut parallel to the longitudinal axis of the peri-implant site in medio-lateral direction, resulting in 4 sections per sample. Each section was ground down to an approximate thickness of 10  $\mu\text{m}$  and stained with hematoxylin-eosin. Sections were observed under a light microscope (Olympus BX60, Olympus Co, Tokyo, Japan) at a magnification of  $\times 20$  to  $\times 60$ . A qualitative histologic description of the peri-implant tissue was performed. All analyses were performed by the same investigator who was blinded with regard to which group each sample belonged.

#### **Reflection light microscopic evaluation**

Furthermore, 2 samples from each group (A, B, C, D) were dehydrated in a graded series of alcohols and then infiltrated and embedded in unsaturated polyester resin (Resapol 10-249). Sections were cut across at the center of implants parallel to their longitudinal axis in medio-lateral direction. Specimens were then polished with ascending grades of sandpaper 80- to 2000- grit until the surface appeared flat and smooth. Such technique of sample preparation for reflected light microscopy was able to preserve the mineral content of tissues and hence allowed a qualitative analysis of the bone-implant interface. The samples were observed under a light microscope at a magnification of  $\times 20$  to  $\times 60$  (Olympus BX60, Olympus Co).

### **RESULTS**

#### **Clinical data**

All animals tolerated the surgical procedure under general anesthesia. Two animals were excluded from the study immediately after the 14th day due to postoperative tibia fracture along the implant site. Moreover, the rabbit excluded from group B (rhGH-treated) presented a tumor-like fibro-osseous lesion covering both implants, hindering the identification of implants and the origin of the fracture. In group A (control), a slightly displaced fracture line surrounded by granulation tissue could be observed. All other rabbits appeared healthy throughout the entire experiment. In both groups, a slight increase in mean body weight was observed: from 3.281 kg preoperatively to 3.433 kg on the day of sacrifice in the rhGH-treated group and from 2.735 kg to 3.056 kg in the control group. Differences in body weight were not significantly different for either preoperative or postoperative measurements in both groups.

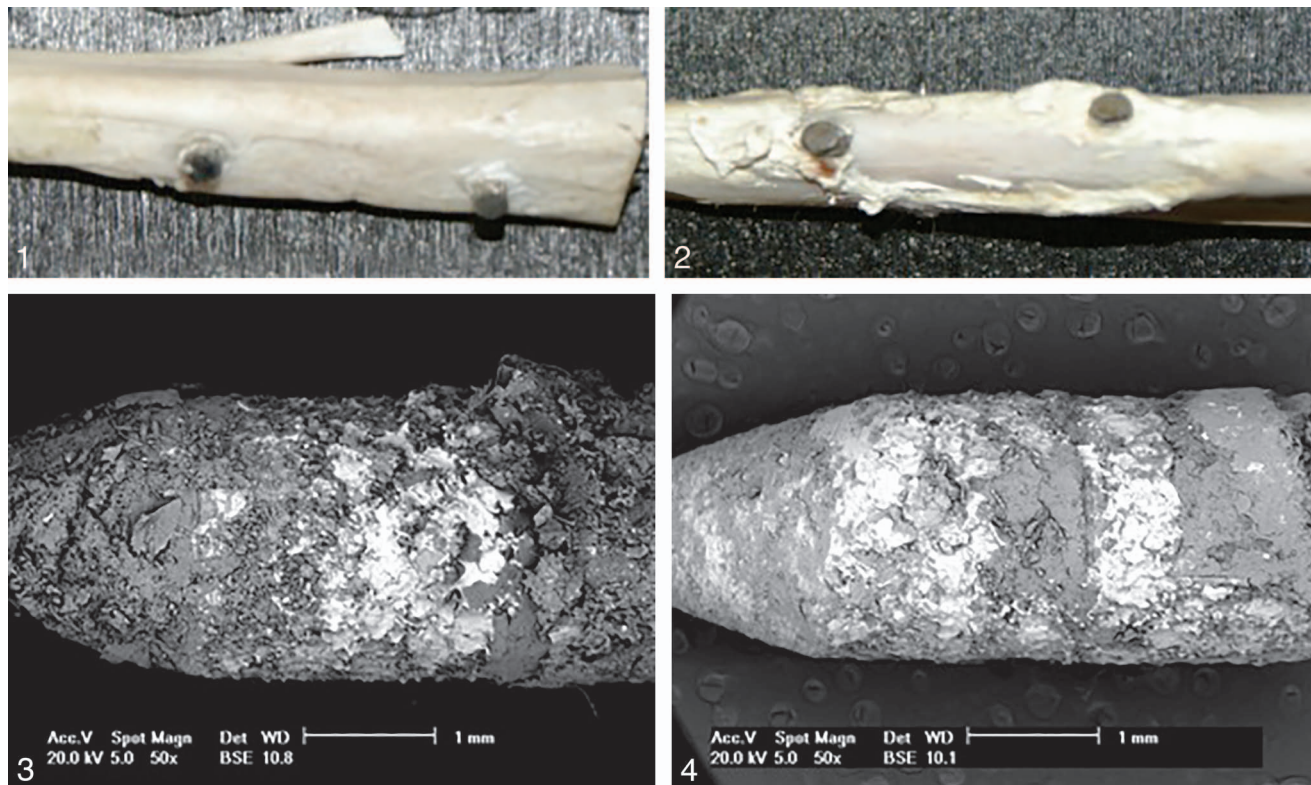
#### **Macroscopic analysis**

Some macroscopic differences were observed between the rhGH-treated and control samples obtained from tibia assessed 14 days postoperatively. While the bone repair in group A was uneventful and apparently normal (Figure 1), the rhGH-treated specimens showed a type of cortical bone reaction of irregular appearance and distribution, with new bone growing along the supraosseous portion of the implants and also along the lateral surface of the tibia (Figure 2). At 42 days, the callus had a regular appearance, and it was difficult to distinguish native from new bone.

#### **Biomechanical testing and SEM findings**

In both killing time periods, the rhGH-treated group showed ultimate stress to detachment values higher than the control group, as follows: 33.88 N/cm<sup>2</sup> for controls (group A) and 59.26 N/cm<sup>2</sup> for rhGH-treated group (group B) at 14 days; and 25.99 N/cm<sup>2</sup> for controls (group C) and 29.69 N/cm<sup>2</sup> for rhGH-treated animals (group D) after 42 days. Both groups showed higher values 14 days postoperatively.

SEM analysis of the surface of the implants revealed that 14 days postoperatively, group B presented a uniform and



**FIGURES 1–4.** Macroscopic view of 2 tibiae obtained from rabbits sacrificed at 14 days. **FIGURE 1.** Control group A. **FIGURE 2.** Recombinant human growth hormone (rhGH)-treated group B. **FIGURES 3 AND 4.** Scanning electron microscopy at 14 days. Bright area corresponds to metal and the gray area to calcified tissue. **FIGURE 3.** rhGH-treated group. **FIGURE 4.** Control group.

abundant bone tissue attached to the implant, including their apical portion, achieving the intramedullary portion of the tibia (Figure 3); while group A demonstrated initial stage of osseointegration (Figure 4). At 42 days, there were no qualitative differences between groups C and D in relation to bone tissue adhering to the implant surface as both groups showed more mature bone in contact with the implant surface.

**Histologic analysis**

Qualitative results from histologic analysis are described in the Table.

At 14 days post operation, group A showed marked histologic features of proliferative healing phase, with intense neovascularization around the peri-implant bone. After 2 weeks, group B demonstrated histologic characteristics of more advanced peri-implant bone repair, showing new bone formation and a moderate amount of new blood vessels indicating that bone healing had achieved the remodeling phase. After 42 days, both groups showed similar characteristics of peri-implant bone remodeling, with minimal connective tissue present. However, at 42 days post operation, the rhGH-treated group seemed to be in a more advanced stage of bone remodeling when compared to the control group.

**Reflection light microscopy**

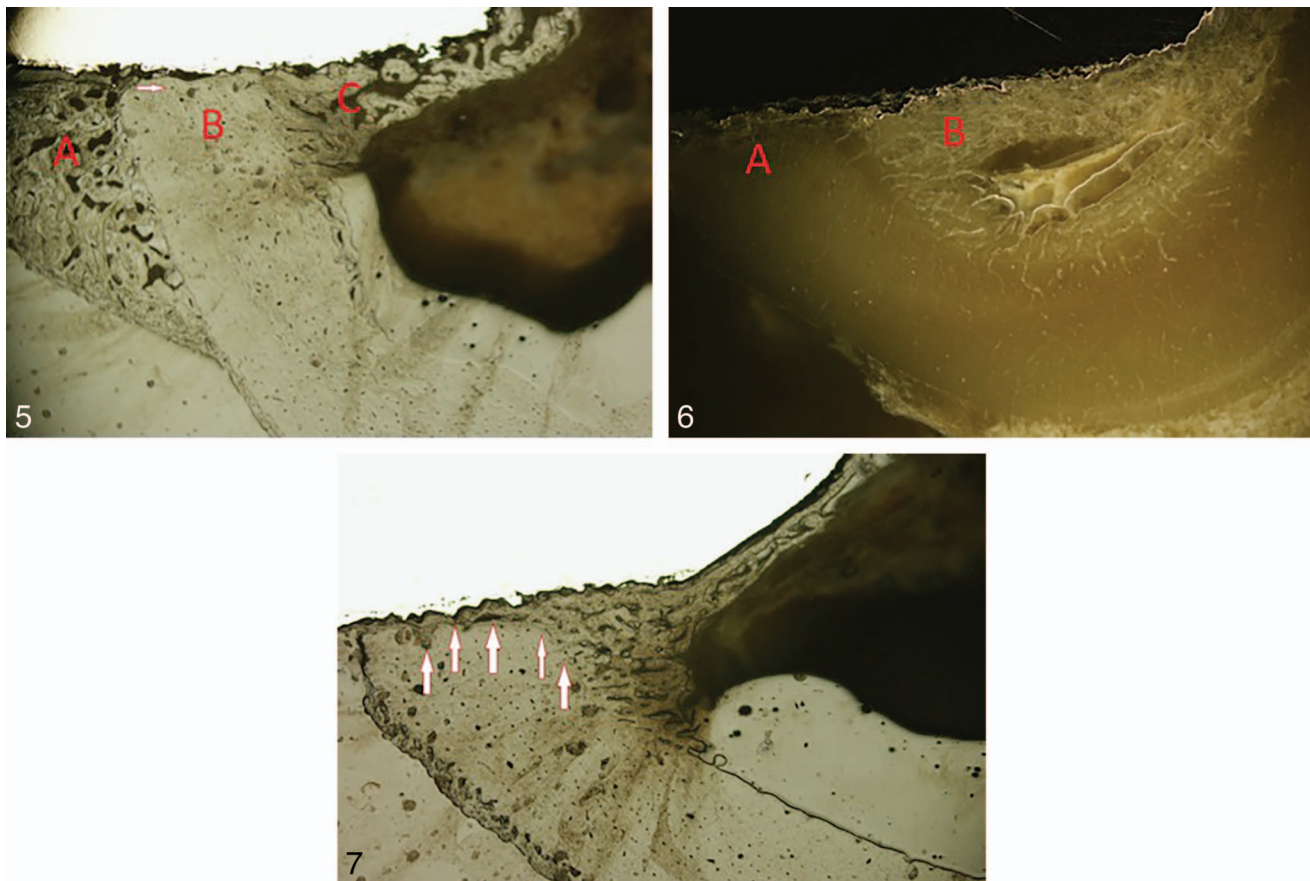
The analysis of samples embedded in polyester resin and submitted to reflection light microscopy confirmed the histo-

logic findings. At 14 days, implants placed in combination with rhGH (group B) showed newly formed bone with lamellar features in contact with the implant, in addition to significant intramedullary bone growth. Figures 5 and 6 show significant bone formation localized above the tibia native bone level in the rhGH-treated group at day 14, demonstrating the cortical reaction microscopically. In comparison, the control group (group A) showed immature newly formed bone in contact

TABLE			
Results from qualitative histologic analysis*†			
Groups	New Bone Formation	Neovascularization	Connective Tissue
14 Postoperative days			
Control group A (n = 4)	4+	9+	1+
rhGH-treated group B (n = 4)†	11+	5+	1+
42 Postoperative days			
Control group C (n = 4)	5+	5+	0
rhGH-treated group D (n = 4)†	5+	3+	0

\*Qualitative values are represented by the sum of all values + obtained for each sample. The criteria used to evaluate slides individually were as follows: 0 absent, + mild, ++ moderate, and +++ strong.

†rhGH indicates recombinant human growth hormone.



**FIGURES 5–7. FIGURES 5 AND 6.** Reflection light microscopy of peri-implant bone area around an rhGH-treated implant at 14 days (original magnification  $\times 20$ ). **FIGURE 5.** Bright field illumination. (A) Cortical reaction. (B) Newly formed lamellar bone. (C) Bone marrow and the arrow indicates Haversian canal. **FIGURE 6.** Dark field illumination. (A) Intimate bone-to-implant contact. (B) Endosteal bone formation. **FIGURE 7.** Bright field illumination of peri-implant bone area around a control implant at 14 days (original magnification  $\times 20$ ). Arrows indicate a boundary between immature newly formed bone in contact with the implant and lamellar bone.

with the implant and slight intramedullary bone formation 14 days after surgery (Figure 7).

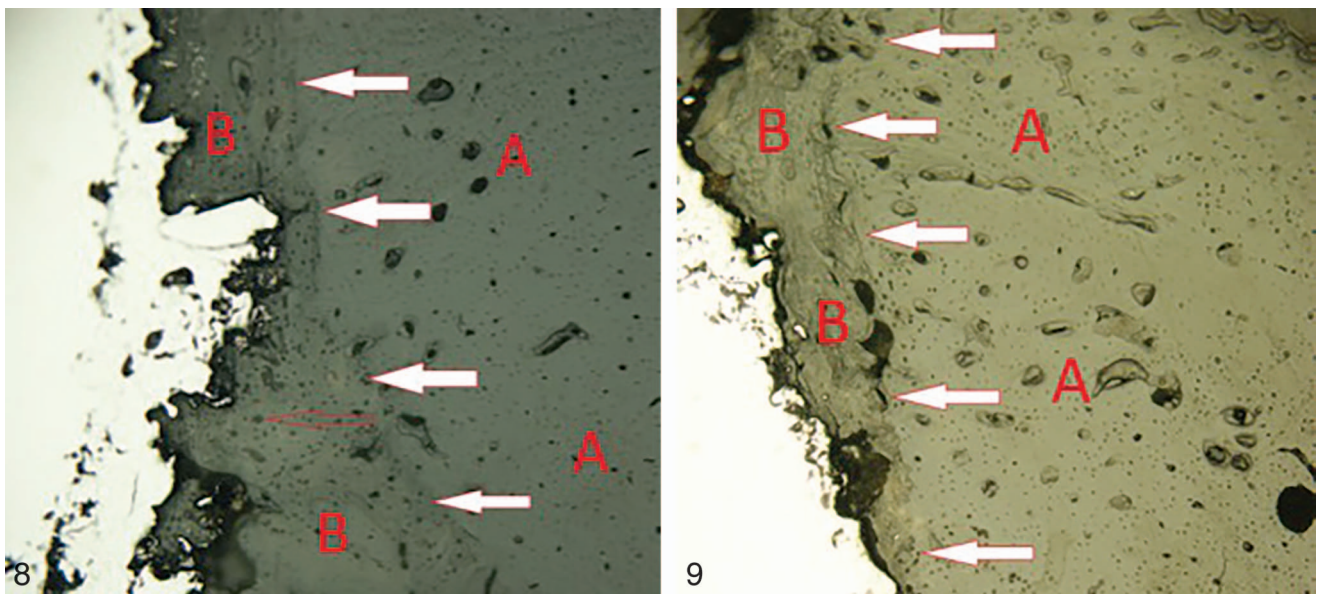
Furthermore, at 42 days after surgery, the rhGH-treated group (group D) showed peri-implant bone tissue featuring lamellar formation and significant bone-to-implant contact, including bone growing into cavities in the implant surface. In the control group (group C), on the other hand, peri-implant bone still showed some characteristics of immature bone tissue and lower bone-to-implant contact than the rhGH-treated group (Figures 8 and 9).

#### DISCUSSION

Treatment for severe bone loss by local administration of various growth factors such as bone morphogenetic proteins (BMPs), transforming growth factor b1 (TGF-b1), IGF-I, FGFs, and platelet-derived growth factors (PDGFs) has been investigated in experimental and clinical studies.<sup>4,16</sup> However, only a few products have regulatory approval and commercial success. Thus, each growth factor plays a unique role in different phases of the bone repair process. Lynch et al<sup>16</sup> assessed the effects of a combination of IGF-1 and PDGF on the osseointegration of titanium implants in dog mandibles and observed a significant

increase of new bone in contact with the implant surface and greater percentage of new bone fill in peri-implant spaces in PDGF-B/IGF-I treated sites compared with controls. In another study, significant increase in bone-to-implant contact and peri-implant space filled with new bone was documented after topical application of the same GFs in implant sites.<sup>18</sup>

Recombinant growth hormone (rGH) has proved to be useful in bone healing as well. Reported enhancement of bone repair and dental implant osseointegration when rGH is used topically or systemically has been confirmed in the early stages of bone repair by several authors.<sup>19–24</sup> However, in later stages of bone healing, in general, no significant differences have been observed in implant osseointegration after a single topical application of rhGH.<sup>12,20,21,23,25</sup> Raschke et al<sup>12</sup> assessed the endocrine effect of daily injections of homologous recombinant porcine growth hormone (r-pGH) in the healing of segmental bone defects in tibia of adult minipigs. Bone density was increased in the treatment group ( $P < .05$ ), with no differences in mineral content between groups. Biomechanical testing was shown to be 70% higher in torsional failure load and 83% higher in torsional stiffness in the treatment group ( $P < .05$ ) as well. The authors concluded that r-pGH stimulates bone repair, resulting in increased mechanical strength and stiffness of the



**FIGURES 8 AND 9.** Light microscopy at 42 days (bright field illumination in  $\times 40$  magnification). (A) Original bone. (B) Newly formed bone. Filled arrows indicate the boundary between original and newly formed bone, and hollow arrows indicate the Haversian system. **FIGURE 8.** rhGH-treated group. Peri-implant area showing mature newly formed bone with lamellar features. **FIGURE 9.** Control group. Peri-implant area showing maturing newly formed bone.

initial bone callus. In another study, daily injections of rhGH resulted in significantly higher values of implant stability, detected by resonance frequency analysis 14 and 56 days after implant insertion in rabbit tibiae. Moreover, blood tests showed development of anti-rhGH antibodies after 28 days. The authors concluded that rhGH plays a role in the early stages of the osseointegration process and due to antibody formation, the study failed to demonstrate whether this effect can remain in the long term.<sup>19</sup> Tresguerres et al<sup>20</sup> assessed whether local administration of rhGH in implants sites would induce quantitative and qualitative changes of peri-implant bone reaction around titanium sheets placed in the tibiae of osteoporotic rabbits. The authors found that local administration of rhGH during the surgical placement of titanium sheets enhances periosteal and transcortical reaction as well as mineralization of osteoid tissue after 14 days without increasing bone resorption. Moreover, bone-to-implant contact in weeks 2 and 6 was shown to be significantly greater in the rhGH group ( $P < .05$ ) in other studies published by the same group of authors.<sup>21,22</sup> Gómez-Moreno et al<sup>23</sup> revealed that GH-treated sites showed significant ( $P < .0001$ ) increases in the perimeter of bone that was in direct contact with implants, total peri-implant bone area, and new bone formation in comparison with control implants 14 days after treatment. The authors confirmed that GH enhances new bone formation around titanium implants in the early stages of healing. Muñoz et al<sup>24</sup> observed that a single topical application of rhGH and melatonin significantly increased bone-to-implant contact and the peri-implant bone area in dogs at 14 days, but no significant differences could be seen between groups after 35 and 56 days. The results of the present study showed similar findings. The use of rhGH as an osteoinductive agent in implant sites proved to play a role in implant osseointegration as rhGH

showed signs of accelerated bone repair when compared to controls, mainly for the first 2 weeks of healing. After 42 days, the histologic analysis and reflected light microscopy of specimens revealed rhGH-treated samples with newly formed bone showing lamellar features, whereas in the controls the peri-implant tissue was still undergoing maturation. These observations coupled with less neovascularization noticed in the rhGH-treated group in both postoperative observation periods confirm that rhGH accelerates bone healing. A suitable explanation for a more significant effect of rhGH in the early stages of bone healing was suggested by Stenport et al,<sup>19</sup> who demonstrated antibody development in rabbits 4 weeks after rhGH treatment. On the other hand, Bail et al<sup>14</sup> conducted a study in which minipigs received a daily injection of homologous r-pGH, and reported that bone repair stimulation by this hormone reached later stages of bone healing and was also more significant at 42 days than at 14 days postoperatively. However, when a single topical application of rhGH is employed, the rhGH effect lasts only from application to degradation, and is therefore less likely to promote long-term stimulation. This concept explains why the present study and many others that have employed a single topical application of rhGH could not observe an osteoinductive effect of rhGH in later stages of bone healing.<sup>21,23,25</sup>

Moreover, many authors have reported that the osteoinduction effect associated with rhGH accelerates bone repair without changing the microstructural characteristics of the tissue.<sup>12,13,19</sup> Such findings allow the safe use of rhGH in bone reconstruction without the risk of causing a little vascularized tissue prone to bone necrosis or any other condition that jeopardizes bone repair.<sup>27-29</sup> Owing to the specimen resin-embedding technique developed for this study, the preservation of the microstructural characteristics of the peri-implant

bone tissue could be clearly demonstrated. Such technique preserved the inorganic matrix of bone and allowed the observation of the tissue by reflection light microscopy, which also demonstrated accelerated results in the rhGH-treated group, showing more mature newly formed bone and more significant intramedullary bone growth when compared to the control group for both observation periods.

Furthermore, this study also demonstrated increased periosteal and endosteal reactions promoted by rhGH, with new bone growing along the supraosseous portion of implants and significant new bone formation in the peri-implant intramedullary portion of the tibia. Such findings have also been observed previously by Tresguerres et al<sup>20-22</sup> as mentioned above. This effect occurs due to the osteoinductive capacity of rhGH, which acts on undifferentiated mesenchymal cells present in the periosteum and endosteum and causes a transcortical reaction that results in a type of callus composed of immature bone tissue, which is present in the first 2 postoperative weeks and is then later remodeled. Transcortical reaction may be clinically important, increasing initial implant stability and providing a better prognosis, especially in areas of poor bone quality. As a result, biomechanical testing revealed higher tensile strength of rhGH-treated implants at 14 days postoperatively. Such results may be associated with the transcortical and endosteal reactions observed in this group.

Regarding both animals excluded from the study due to bone fracture along the implant site, the animal excluded from group B (rhGH-treated) showed a tumor-like fibro-osseous lesion around the fracture line that could not be observed on the other animals excluded from group A (control). One may suggest that this overreaction of tissues surrounding the fractured region results from rhGH use, which supposedly acts not only on bone tissue but also locally on soft tissue overlying the tibia.

It remains to be established whether the mechanism of action of GH occurs directly by its local action on the tissue or its effect is mediated by IGF-1. Although the relative roles of GH and IGF-1 are controversial, they have shared concomitant actions in several cases.<sup>9,10</sup> It has been recently accepted that GH may be secreted by various types of cells, including osteoblasts, and that this hormone has not only endocrine effects but also autocrine and paracrine effects.<sup>22,25</sup> The results obtained in the present research by topical application of rhGH corroborate with the potential local action of rhGH.

The endocrine secretion of GH occurs by hypothalamic hormone-mediated feedback loops, requiring prolonged and multifactorial stimulation.<sup>9</sup> However, a single topical application of rhGH into the bone defect prepared to receive titanium implants can stimulate bone repair mainly by autocrine and paracrine actions.<sup>22-25</sup> rhGH activates local osteogenic cells triggering intense and accelerated new bone formation, thus explaining the results observed in the present study.

Early new bone formation is important for implant osseointegration and success of dental implant treatment.<sup>2,3</sup> This study clearly demonstrated the ability of rhGH to accelerate new bone formation and its maturation. Thus, rhGH is likely to be a useful adjuvant in oral implantology, particularly in the treatment of patients with poor bone quality and

postmenopausal women or elderly people with low endogenous GH secretion.

Although GH is a physiologic hormone that has been widely used in therapy for many years, its misuse may cause deleterious effects to the patient, such as metabolic ketosis, hepatic steatosis, increased insulin resistance, and acromegaly.<sup>3,9,10</sup> Therefore, clinical studies are suitable to confirm the advantages of such therapy and hence allow the use rhGH safely and effectively to accelerate oral rehabilitation with dental implants.

## CONCLUSION

Given all macroscopic and microscopic findings observed in this study, as well as biomechanical tests results, and with respect to the limitations of the study, it was concluded that intraoperative topical use of rhGH induced peri-implant new bone formation without change to the bone microstructure. Moreover, such hormone accelerated and increased new bone formation in the early stages of bone healing. However, it remains unclear whether rhGH could maintain its osteoinductive effects or would be ineffective in later stages of bone healing. Studies involving slow and sustained release of rhGH into the bone defect are warranted to clarify this issue.

## ABBREVIATIONS

BMP: bone morphogenetic protein  
 FGF: fibroblast growth factor  
 GF: growth factor  
 GH: growth hormone  
 IGF: insulin-like growth factor  
 PDGF: platelet-derived growth factor  
 PTH: parathyroid hormone  
 rGH: recombinant growth hormone  
 rhGH: recombinant human growth hormone  
 r-pGH: recombinant porcine growth hormone  
 SEM: scanning electron microscope  
 TGF- $\beta$ 1: transforming growth factor  $\beta$ 1

## REFERENCES

1. Belser UC, Schmid B, Higginbottom F, Buser D. Outcome analysis of implant restorations located in the anterior maxilla: a review of the recent literature. *Int J Oral Maxillofac Implants.* 2004;19(suppl):30-42.
2. Le Ghéhenec L, Soueidan A, Layrolle P, Amouriq Y. Surface treatment of titanium dental implants for rapid osseointegration. *Dent Mater.* 2007;23:844-854.
3. Ohlsson C, Bengtsson B, Isaksson OG, Andreassen TT, Słotweg MC. Growth hormone and bone. *Endocr Rev.* 1998;1:55-79.
4. Eriksen EF, Kassem M, Langdahl B. Growth hormone, insulin-like growth factors and bone remodeling. *Eur J Clin Invest.* 1996;26:252-234.
5. Simpson AH, Mills L, Noble B. The role of growth factors and related agents in accelerating fracture healing. *J Bone Joint Surg Br.* 2006;88:701-705.
6. Guicheux J, Gauthier O, Aguado E, et al. Growth hormone-loaded macroporous calcium phosphate ceramic: in vitro biopharmaceutical characterization and preliminary in vivo study. *J Biomed Mater Res.* 1998;40:560-566.
7. Takechi M, Tatehara S, Satamura K, Fujisawa K, Nagayama M. Effect

of FGF-2 and melatonin on implant bone healing: a histomorphometric study. *J Mater Sci Mater Med*. 2008;19:2949–2952.

8. Ziegler J, Anger D, Krummenauer F, Breitig D, Fickert S, Guenther KP. Biological activity of recombinant human growth factors released from biocompatible bone implants. *J Biomed Mater Res A*. 2008;86:89–97.

9. Guyton AC, Hall JE. *Textbook of Medical Physiology*. 11th ed. Philadelphia, Pa: Saunders; 2006.

10. Goldman L, Ausiello D. *Cecil Medicine*. 23 ed. Philadelphia, Pa: Saunders Elsevier; 2008.

11. Darryl LM, Brent WE, Gregory DB, et al. Radiographic, densitometric, and biomechanical effects of recombinant canine somatotropin in an unstable osteotomy gap model of bone healing in dogs. *Vet Surg*. 1998;27:85–93.

12. Raschke M, Kolbeck S, Bail HJ, et al. Homologous growth hormone accelerates healing on segmental bone defects. *Bone*. 2001;29:368–373.

13. Bail HJ, Raschke MJ, Kolbeck S, et al. Recombinant species-specific growth hormone increases hard callus formation in distraction osteogenesis. *Bone*. 2002;30:117–124.

14. Bail H, Klein P, Kolbeck S, et al. Systemic application of growth hormone enhances the early healing phase of osteochondral defects—a preliminary study in micropigs. *Bone*. 2003;32:457–467.

15. Kolbeck S, Bail H, Schmidmaier G, et al. Homologous growth hormone accelerates bone healing—a biomechanical and histological study. *Bone*. 2003;33:628–637.

16. Lynch SE, Buser D, Hernandez RA, et al. Effects of the platelet-derived growth factor/insulin-like growth factor-I combination on bone regeneration around titanium dental implants. Results of a pilot study in beagle dogs. *J Periodontol*. 1991;62:710–716.

17. Becker W, Lynch SE, Lekholm U, et al. A comparison of PTFE membranes alone or in combination with platelet-derived growth factors and insulin-like factor-I or demineralized freeze-dried bone in promoting bone formation around immediate extraction socket implants. *J Periodontol*. 1992;63:929–940.

18. Stefani CM, Machado MA, Sallum EA, Sallum AW, Toledo S, Nociti FH Jr. Platelet-derived growth factor/insulin-like growth factor-1 combination and bone regeneration around implants placed into extraction sockets: a histometric study in dogs. *Implant Dent*. 2000;9:126–131.

19. Stenport VF, Olsson B, Morberg P, Tornell J, Johansson CB. Systemically administered human growth hormone improves initial implant stability: an experimental study in the rabbit. *Clin Implant Dent Relat Res*. 2001;3:135–141.

20. Tresguerres IF, Clemente C, Donado M, et al. Local administration of growth hormone enhances periimplant bone reaction in an osteoporotic rabbit model. *Clin Oral Implants Res*. 2002;13:631–636.

21. Tresguerres IF, Alobera MA, Baca R, Tresguerres JA. Histologic, morphometric, and densitometric study of peri-implant bone in rabbits with local administration of growth hormone. *Int J Oral Maxillofac Implants*. 2005;20:193–202.

22. Tresguerres IF, Blanco L, Clement C, Tresguerres JA. Effects of local administration of growth hormone in peri-implant bone: an experimental study with implants in rabbit tibiae. *Int J Oral Maxillofac Implants*. 2003;18:807–811.

23. Gómez-Moreno G, Cutando A, Arana C, et al. The effects of growth hormone on the initial bone formation around implants. *Int J Oral Maxillofac Implants*. 2009;24:1068–1073.

24. Muñoz F, López-Peña M, Miño N, Gómez-Moreno G, Guardia J, Cutando A. Topical application of melatonin and growth hormone accelerates bone healing around dental implants in dogs. *Clin Implant Dent Relat Res*. 2012;14:226–235.

25. Calvo-Guirado JL, Mate-Sanchez J, Delgado-Ruiz R, et al. Effects of growth hormone on initial bone formation around dental implants: a dog study. *Clin Oral Implants Res*. 2011;22:587–593.

26. Renz RP, Cunha A, Wantowski G, Blando E, Hubler R. Osseointegration evaluation of treated surfaces of titanium implants applying tensile pull out test. *J Dent Clin Res*. 2007;3:149–157.

27. Atalay B, Yalcin S, Emes Y, et al. Bisphosphonate-related osteonecrosis: laser-assisted surgical treatment or conventional surgery? *Lasers Med Sci*. 2011;26:815–823.

28. Urade M, Tanaka N, Furusawa K, et al. Nationwide survey for bisphosphonate-related osteonecrosis of the jaws in Japan. *J Oral Maxillofac Surg*. 2011;69:e364–e371.

29. Brock G, Barker K, Butterworth CJ, Rogers S. Practical considerations for treatment of patients taking bisphosphonate medications: an update. *Dent Update*. 2011;38:313–318.