

Assessment of the Anterior Loop of the Mental Nerve Using Cone Beam Computerized Tomography Scan

Chun-I Lu, DDS, MSD^{1*}
 John Won, DDS, MS¹
 Aladdin Al-Ardah, DDS, MS¹
 Ruben Santana, DDS, MSD¹
 Dwight Rice, DDS²
 Jaime Lozada, DMD¹

The purpose of this study is to use cone-beam computerized tomography (CBCT) scans with oblique-transverse reconstruction modality to measure and compare the anterior loop length (AnLL) of the mental nerve between gender and age groups and to compare the difference between the right and left sides. Sixty-one female and 61 male CBCT scans were randomly selected for each age group: 21–40, 41–60, and 61–80 years. Both right- and left-side AnLLs were measured in each subject using i-CATVision software to measure AnLLs on the oblique transverse plane using multiplanar reconstruction. The anterior loop was identified in 85.2% of cases, with the mean AnLL of the 366 subjects (732 hemimandibles) being 1.46 ± 1.25 mm with no statistically significant difference between right and left sides or between different gender groups. However, the mean AnLL in the 21–40 year group (1.89 ± 1.35 mm) was larger than the AnLL in the 41–60 year group (1.35 ± 1.19 mm) and the 61–80 year group (1.13 ± 1.08 mm). In conclusion, when placing implants in close proximity to mental foramina, caution is recommended to avoid injury to the inferior alveolar nerve. No fixed distance anteriorly from the mental foramen should be considered safe. Using CBCT scans with the oblique-transverse method to accurately identify and measure the AnLL is of utmost importance in avoiding and protecting its integrity.

Key Words: cone-beam computed tomography, mental foramen, mental nerve, anterior loop length, dental implant

INTRODUCTION

Surgery in the anterior mandible such as implant placement in the interforaminal area or chin grafting may damage the anterior loop of the mental nerve, resulting in neurosensory disturbances. During surgery, surgeons usually expose the mental foramen to visualize the position of the mental nerve. However, without knowing the anterior loop length, surgeons have a high risk of violating the anterior loop, when present.

Preoperative radiographic examination aids in developing a comprehensive treatment plan for patients who need dental implant surgery. It helps determine the proper size, location, and angulation for each dental implant as well as the number of implants to be placed.^{1,2} Some authors claim that 2-dimensional (2D) radiographs are sufficient for presurgical implant planning³; however, others believe there is a need for additional cross-sectional imaging.^{4–6} Recently, it has been recommended that cross-sectional imaging be used for the assessment of all dental implant sites and that cone-beam computerized tomography (CT) is the imaging method of choice for gaining this information.⁴

When planning to place implants in the mandible, one of the most important anatomic landmarks is the mandibular canal, in which the inferior alveolar nerve passes through and continues anteriorly as the mental nerve, exiting at the mental foramen. The mental nerve may have an anterior loop, which is described in *Sicher's Oral Anatomy*.⁷ The anterior loop is described as "the mental canal which rises from the mandibular canal and runs outward, upward and backward to open at the mental foramen." The location of the most distal implants in the interforaminal area when planning an implant-supported fixed complete denture is determined by the position of the mental foramen and the anterior loop of the mental neurovascular bundle.^{8–10} To place the implant closest to the mental foramen with concern on the anterior loop is the key factor for increasing the A-P spread and reducing distal cantilever.^{11,12} However, complications of surgical trauma to the mental nerve can result in neurosensory disturbances and altered sensation of the lower lip and chin after implant placement.¹³

Clinically, the anterior loop cannot be seen but can be detected in panoramic radiographs, cone beam computerized tomography (CBCT), spiral CT, and magnetic resonance imaging. However, in the study by Arzouman et al,¹⁴ the authors concluded that significantly fewer loops were detected in panoramic radiographs as compared with anatomic assessment. Also, significantly shorter anterior loops were identified in panoramic radiographs than when direct measurements were made. Moreover, Kuzmanovic et al¹⁰ showed that 50% of the radiographically observed anterior loops of the mental

¹ Advanced Education in Implant Dentistry, Department of Restorative Dentistry, Loma Linda University, Loma Linda, Calif.

² Department of Oral Diagnosis, Radiology & Pathology, Loma Linda University, Loma Linda, Calif.

* Corresponding author, e-mail: chunilu1106@gmail.com

DOI: 10.1563/AAID-JOI-D-13-00346

canal were misinterpreted by observers with panoramic radiography, and 62% of the anatomically identified loops were not observed radiographically. They concluded that panoramic radiographs are unreliable and have high incidences of false-positives and false-negatives in identifying the anterior loop.

Spiral CT and CBCT have also been used for measuring anterior loops in the literature and tend to be more reliable. Kaya et al¹⁵ showed spiral CT scans demonstrated a higher prevalence of mental loops than panoramic radiographs. Uchida et al¹⁶ compared the CBCT and anatomic measurements and concluded that the average length of the anterior loop was 2.2 ± 0.8 mm using CBCT, and no significant differences were found between CBCT and anatomic measurements.

Ngeow et al¹⁷ investigated the visualization of the anterior loop in "different age-groups and genders" using panoramic radiographs, but this study did not facilitate CBCT scans. Different methods of measuring the anterior loop length (AnLL) on CBCT scans were described in the literature. In one study, a software program was used to draw tracing lines of the mental nerve to measure the length of the loop.¹⁸ Some studies measured by counting the first and last cross-sectional 0.5-mm-thick slices after identifying the anterior loop and mental foramen. However, Kaya et al¹⁵ stated that assessing a tomographic cross-sectional cut for the location of the mandibular or mental canals was difficult. In the present study, we presented a simpler method using i-CATVision software to locate the mental foramen and anterior loop on a single oblique transverse view and measure the length of the anterior loop.

The objective of this study is to measure and compare the AnLL of the mental nerve between gender and age groups and to compare the difference between the right and left sides using CBCT. The null hypothesis is that according to the analysis of CBCT scans, age, gender, and right versus left sides have no influence on the anterior loop length.

MATERIALS AND METHODS

To estimate the proper sample size for evaluating the difference between groups, StatSoft STATISTICA (power analysis software) with an α of .05 and 2-tailed *t* test of significance was used. An estimation was made that 176 participants in each gender group and a total of 352 participants would provide 80% power for detecting a small-to-medium effect size ($r = .3$) in the relationship between AnLL and gender. After setting $\alpha = .05$, root mean square standardized effect = 0.2, the 1-way analysis of variance (ANOVA) test of significance was used to make a prior estimate that 122 participants in each age group (3 groups) and a total of 366 participants would provide 80% power in the relationship between AnLL and age groups. Combining the results above, 61 women and 61 men in each age group, with a total of 366 participants, were used in the study.

Sixty-one female and 61 male patients were randomly selected for each age group (21–40, 41–60, and 61–80 years) from existing Loma Linda University CBCT scans. All CBCT scans were taken by I-CAT Cone-Beam 3D Dental Imaging System Model (Imaging Sciences International, Hatfield, Penn) under 6-

or 13-cm field of view, 20 seconds scan time, and 0.4-mm voxel size. Both right- and left-side AnLLs were measured in each subject. I-CATVision software (Croall Radiography Inc, version 1.8.1.10) was used to measure the AnLL by using multiplanar reconstruction. Multiplanar reconstruction allows images to be created from the original axial plane in either the coronal, sagittal, or oblique plane.

First, the axial cut in the sagittal plane was adjusted to identify the best view of the mental foramen in the axial plane (Figure 1).

Second, the axial plane was rotated until the sagittal cut was parallel to the buccal plate in the area of the mental foramen. Meanwhile, the coronal cut in the axial plane was adjusted to identify the best view of the mental foramen in the coronal plane (Figure 2).

Third, the coronal plane was enlarged, and an oblique cut that passed through the center of the mental foramen was made to create an oblique plane, which allowed visualization of the mental foramen and anterior loop at the same time (Figures 3 and 4). Fourth, this view was enlarged so that measurements could be made to the nearest 0.4 mm (Figure 4). Fifth, a line (line 1) was drawn parallel to the buccal plate, and another line (line 2) was made perpendicular to line 1, which passed through the most anterior point of the anterior loop. (It could be the origin of the incisive canal or the most anterior point of the mental loop curvature.) AnLL was measured from the most anterior point of the mental foramen to line 2 (Figure 4). When the anterior loop was not present or the origin of the incisive canal was located posterior to the mental foramen, negative values were recorded.

Statistical analysis

Two examiners were involved in the study. Each examiner measured AnLL on both sides of the patient 3 different times. Intra- and Interexaminer reliability were tested by using SPSS intraclass correlation coefficient (Cronbach's alpha value $>.8$ means optimal agreement, $>.9$ means excellent agreement). The prevalence of the anterior loop (when AnLL > 0 mm) was calculated. After calculating the mean and standard deviation, the independent *t* test was used to compare AnLL between gender groups. A paired *t* test was used to compare AnLL between the right and left sides. One-way ANOVA was used to compare AnLL among the 3 age groups. The α level of all the statistic tests was set as .05.

RESULTS

All measurements were collected for intra- and interexaminer reliability tests. A Cronbach's alpha value of .954 and .976 was obtained in the first and second examiner, showing an excellent agreement. An intraclass correlation coefficient of .904 was obtained comparing 2 examiners, showing excellent agreements as well.

The measurements of the AnLL comparing the right and left side in different gender and age groups are listed in Tables 1–4. The anterior loop was present (length >0 mm) in 624 of 732 hemimandibles (prevalence = 85.2%). The AnLL of the 366 subjects (732 hemimandibles) was 1.46 ± 1.25 mm. The

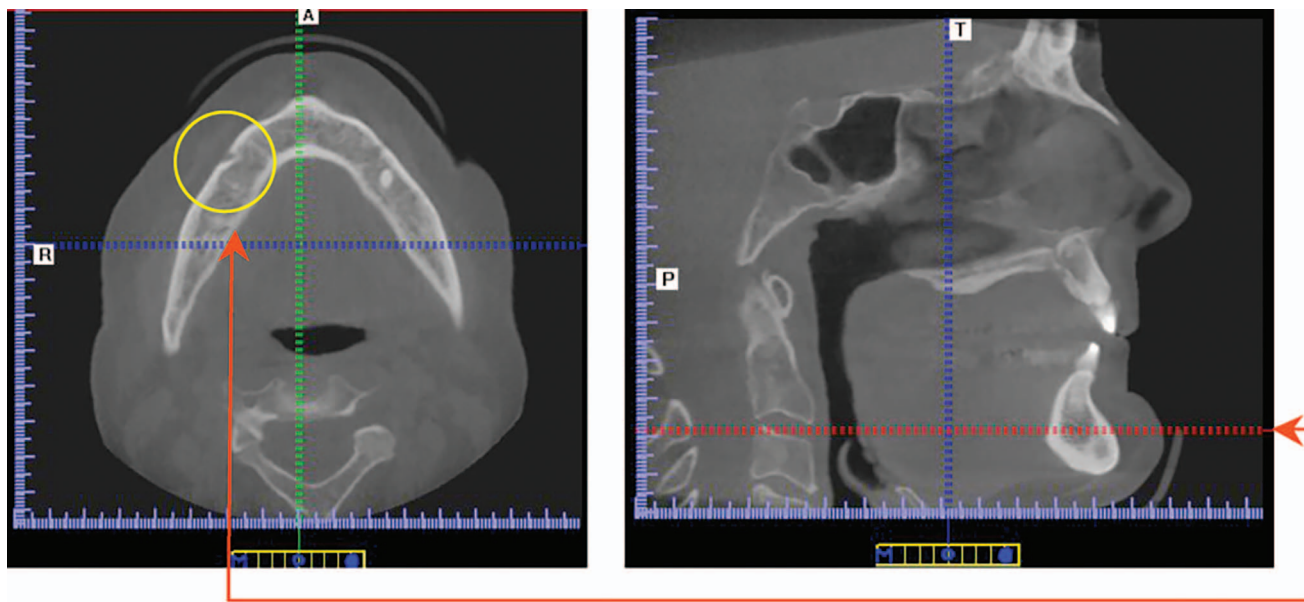


FIGURE 1. How to move the axial cut (red bar) in the sagittal plane until the best view of mental foramen (yellow circle) is attained in the axial plane.

maximal and minimal AnLL were 6.67 mm and -2.87 mm (Figures 5 and 6). The mean AnLL on the right side was 1.47 ± 1.39 mm and on the left side was 1.44 ± 1.39 mm. There was no statistical significance between groups. The mean AnLL was 1.51 ± 1.24 mm for men and 1.40 ± 1.26 mm for women, and no statistically significant differences were found.

Among the age groups, 1-way ANOVA statistical analysis showed a significant difference between groups ($P = .000$). Both post hoc tests, Bonferroni and Scheffé test, showed the AnLL of the 21–40 year group was significantly different from groups 41–60 and 61–80 years. The mean AnLL in the 21–40 year group (1.89 ± 1.35 mm) was larger than the AnLL in the 41–60 year group (1.35 ± 1.19 mm) and 61–80 year group (1.13 ± 1.08 mm).

DISCUSSION

In the literature, the average measurements of the AnLL varied. The mean AnLL varied from 0.1 mm¹⁹ to 6.92 mm.²⁰ The reason that the results varied might be due to different diagnostic tools (cadavers, dry skulls, 2D radiographs, and 3D radiographs) different population, (different age, gender, race, dental status), different methods of measuring (direct measurements using probe, calipers), or different methods of interpreting the radiographs. In our study, the mean AnLL of the 366 subjects on CBCT scans (732 hemimandibles) was 1.46 ± 1.25 mm. This corresponded with most of the cadaver studies that used direct measurements. Solar et al²¹ found that the mean AnLL was 1 mm and ranged from 0.5 to 5 mm, Kuzmanovic et al¹⁰ found the mean AnLL was 1.2 mm, and Uchida et al²² found it was 1.5 mm. All of these were cadaver studies.

Studies by Arzouman et al,¹⁴ Kaya et al,¹⁵ and Misch and Crawford²³ found mean AnLLs of 3.45 mm, 3.75 mm, and 5 mm, respectively. A possible reason for these average AnLLs compared with those of the current study could be the fact

that the previous investigators used 2D radiographs as the measuring tools. Kuzmanovic et al¹⁰ concluded that panoramic radiographs are unreliable and have high incidences of false-positives and false-negatives in identifying the anterior loop. They found that radiographic length of the anterior loop of the mental canal can be measured only in radiographs in which the entire course of the mental canal is visualized, from the mandibular canal through the mental foramen (type I, or continuous type; Yosue and Brooks classification²⁴). We applied this concept on the 3D CBCT scans. We think that the most accurate way to measure the anterior loop is when the mandibular canal, the anterior loop, the incisive canal, and the mental foramen can be continuously visualized in the same view.

Cone beam computed tomography was introduced in the early 2000s with its great decrease in dose compared with the conventional CT.^{25–27} Poeschl et al²⁸ found that CBCT was as accurate as conventional multislice CT with regard to its use in image-guided implant surgery. Al-Ekrish and Ekram²⁹ stated that the mean of the CBCT absolute errors was even smaller than that of the multi-detector CT absolute errors for the overall data, as well as for the site-specific data. Moreover, Santana et al³⁰ and Uchida et al¹⁶ stated there was no statistically significant difference on the AnLL between anatomic measurements from cadavers and measurements obtained from CBCT images. Although CBCT had been proven to be accurate, studies using CBCT to analyze the average length of the anterior loop still showed contrasting results from 0.89 mm³¹ to 6.92 mm.²⁰ We found that the methods of measuring the AnLL on CBCT were different. Rosa et al³² determined the mental loop length on panoramic views from CBCT scans, which made it similar to studies using panoramic radiographs. Chen et al²⁰ mentioned that they reconstructed part of the panoramic view along the inferior alveolar nerve canal, but no reference point of measuring the loop was found. Apostolakis and Brown³¹

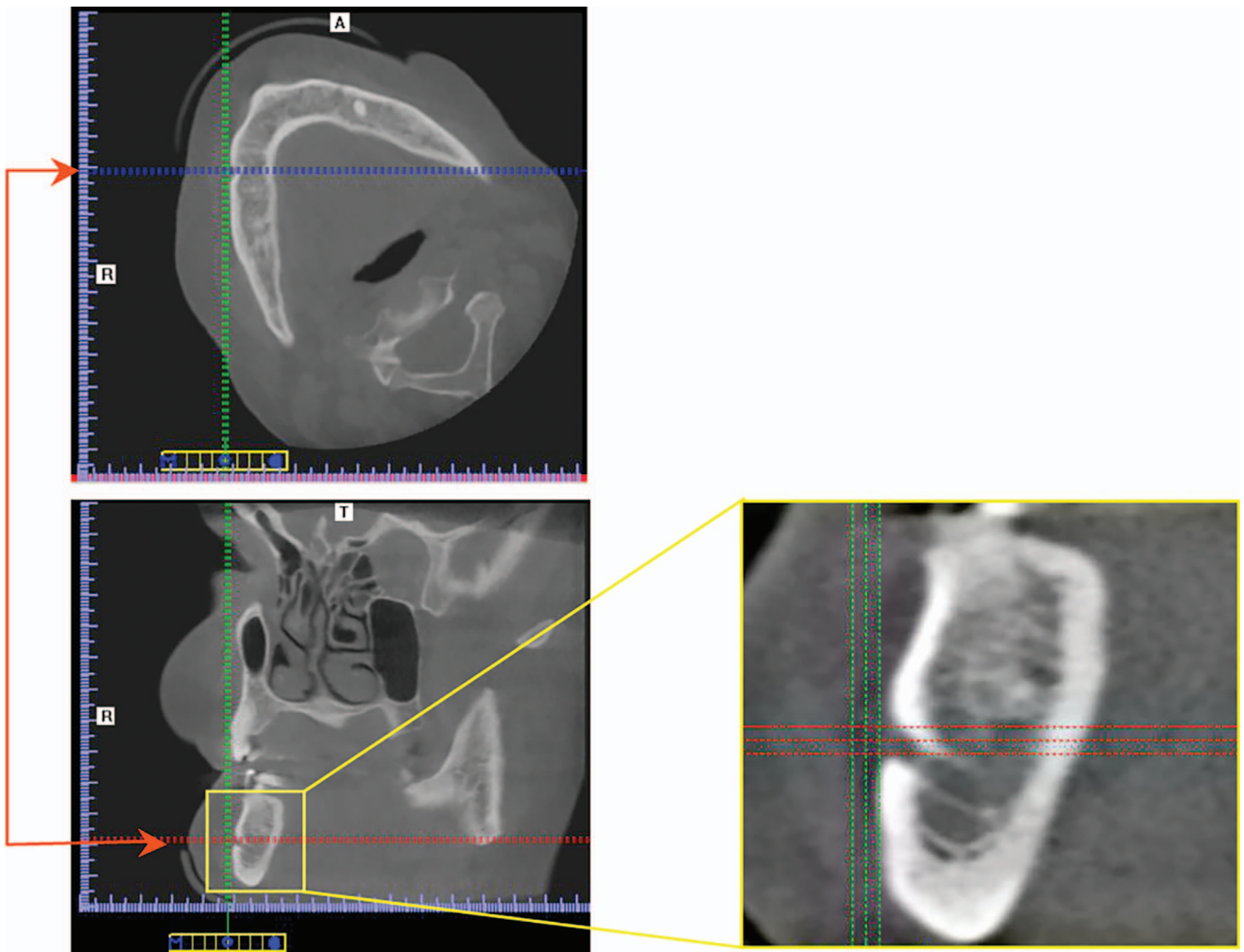
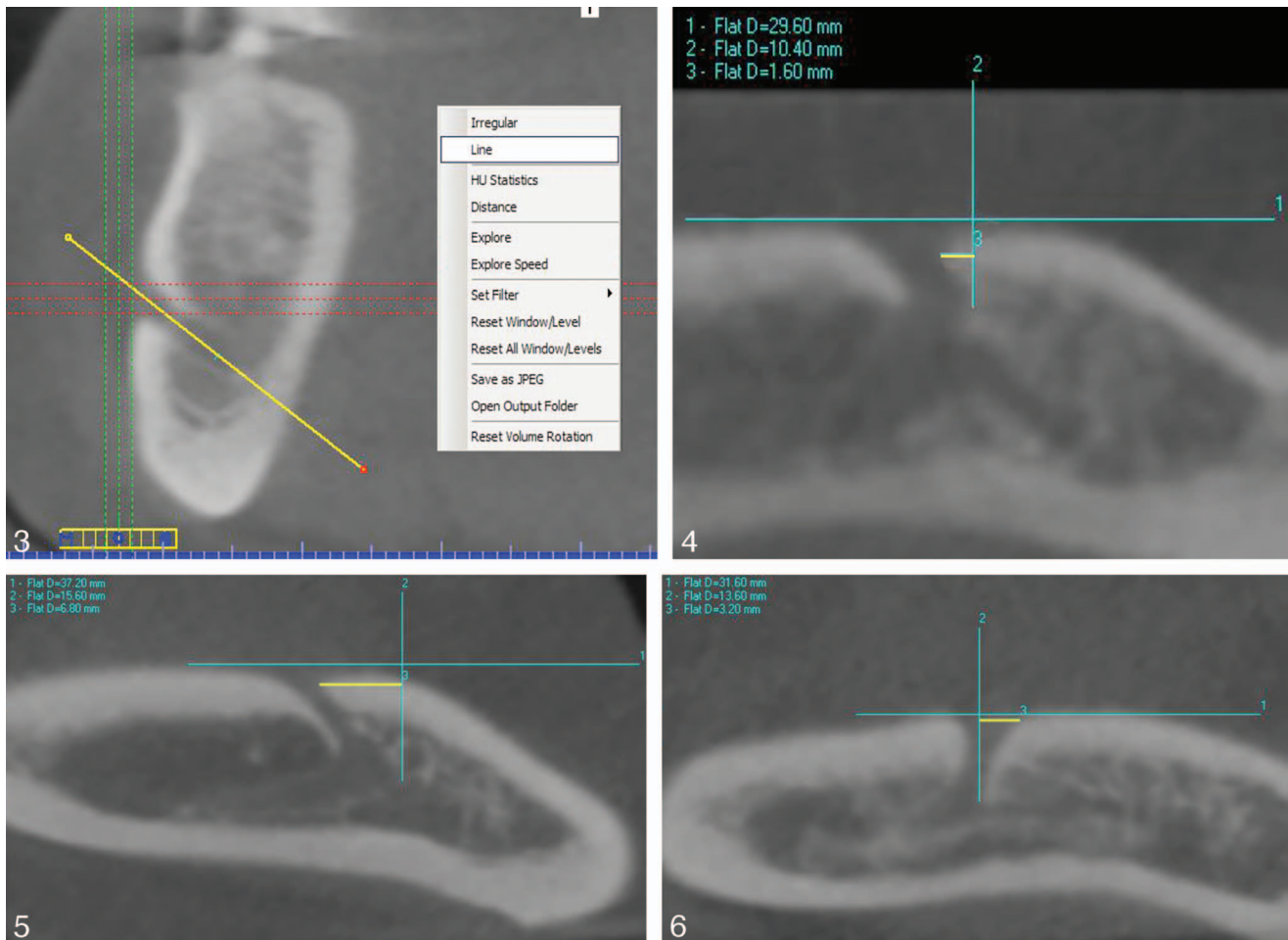


FIGURE 2. Axial plane that is rotated until the sagittal cut (green bar) is parallel to the buccal plate in the area of the mental foramen, and the coronal cut (blue bar) in the axial plane that is adjusted until the best view of the mental foramen (yellow square) is attained in the coronal plane.

counted the 0.3-mm vertical cross-section slices to evaluate the length of the loop, and we found it difficult to identify the most anterior part of the mental nerve on the cross-section views, especially when the bone density was poor.¹⁵ The method we used in our study was to locate the mental foramen and anterior loop on a single oblique transverse view. We believed that once the mandibular canal, the anterior loop, the incisive canal, and the mental foramen could be simultaneously visualized in the same view, the measurement would be more accurate. The presence of the anterior loop of mental nerve was defined as any part of the mental nerve located mesial (or anterior) to the mental foramen. In the present study, 85.2% prevalence of the loop was noted. This result was similar to the study of Neiva et al,³³ who found 88% of anterior loop in skulls using a probe, and Kieser et al,³⁴ who found 84% in cadavers. The reason that some studies showed a low prevalence (7% to 55%)^{10,32,35,36} might be the difficulty of clearly identifying the most anterior portion of the mental nerve. One disadvantage in the present study is that a medium-resolution CBCT with a scan time of 20 seconds and 0.4-mm voxel size was used. Higher-resolution scans with a scan time of 40 seconds and 0.25-mm

voxel size might lead to a clearer image and decrease the errors of measurements. However, both intra- and interexaminer reliability were analyzed in our study, and the statistic result showed an excellent agreement. This result confirmed that the oblique transverse method was a simple and reliable way to measure the anterior loop on a CBCT scan.

Studies that have analyzed the anterior mental loop in cadavers tend to consist of populations with greater age and small sample sizes. Power analysis guided us to collect at least 61 patients in each group, with a total of 366 patients. To the best of our knowledge, this study consisted of the largest sample size of all studies to report on this topic. In the present study, equal subject numbers of different genders with a wide age range from 21 to 80 years were included. The statistical analysis showed that there was no difference between the right and left side or between genders. Uchida et al^{16,22} showed no difference between sides, but a larger AnLL was found in men. In our study, we had 5 times more subjects than the previous study, and men showed a mean AnLL of 1.51 mm, which is slightly larger than that of women (1.40 mm) but statistically not significant. Moreover, we found that the AnLL of the 21–40



FIGURES 3–6. **FIGURE 3.** How to make an oblique cut using the function “line” to gain an ideal oblique view (Figure 4). (The cut is adjusted to pass through the center of the mental foramen in the coronal plane and meanwhile to obtain the best view of the anterior loop in the oblique plane.) **FIGURE 4.** Mental foramen, anterior loop of the mental nerve, and bifurcation at the same view. Line 1 is parallel to the buccal plate. Line 2 is perpendicular to line 1 and passes through the most anterior point of the anterior loop. (In this case, it is the part of the mental nerve, not the origin of the incisive canal.) Line 3 (yellow) shows the measurement of the anterior loop length. **FIGURE 5.** Example of the measurement (line 3: 6.8 mm) of the maximal anterior loop length. The average of all measurements (6.8, 6.8, 6, 6.4, 6.8, 7.2 mm) was 6.67 mm. **FIGURE 6.** Example of the measurement (line 3: –3.2 mm) of the minimal anterior loop length. The average of all measurements (–3.2, –3.2, –3.2, –2.8, –2.4, –2.4 mm) was –2.87 mm.

TABLE 1

Prevalence and measurements of the anterior loop length of the mental nerve comparing the right and left sides

	Prevalence, %	Min, mm	Max, mm	Mean ± SD, mm
Right	85.8	–2.40	6.67	1.47 ± 1.39
Left	84.7	–2.87	5.27	1.44 ± 1.39
Paired <i>t</i> test (* <i>P</i> < .05)				.639
Total	85.2	–2.87	6.67	1.46 ± 1.25

TABLE 2

Prevalence and measurements of the anterior loop length of the mental nerve comparing different genders

	Prevalence, %	Min, mm	Max, mm	Mean ± SD, mm
Male	85.5	–2.87	6.67	1.51 ± 1.24
Female	85.0	–2.47	6.40	1.40 ± 1.26
Independent <i>t</i> test (* <i>P</i> < .05)				.379

TABLE 3

Prevalence and measurements of the anterior loop length of the mental nerve comparing different age groups

	Prevalence, %	Min, mm	Max, mm	Mean \pm SD, mm
Age 21–40 y	89.3	–2.87	6.67	1.89 \pm 1.35
Age 41–60 y	83.2	–2.40	6.00	1.35 \pm 1.19
Age 61–80 y	83.2	–2.20	6.60	1.13 \pm 1.08
One-way ANOVA (* <i>P</i> < .05)				.000*

year age group was significant larger than the 41–60 and 61–80 year groups. This is also consistent with Uchida et al²² and Ngeow et al,¹⁷ who indicated that the frequency of the anterior loops decreases with age. In 1986, Gershenson et al³⁷ described that with loss of teeth and bone resorption, the mental foramen moves upward closer to the alveolar border. The mental nerve emerged from the mental foramen closer to or at the alveolar border, according to the degree of resorption. Therefore, when teeth are lost, bone resorption occurs, the mental foramen gets closer to the anterior part of the mental loop, and the AnLL decreases. Meanwhile, we found 3.28% of posterior edentulous in the age 21–40 year group, 20.08% in the 41–60 year group, and 27.87% in the 61–80 year group (Table 5). The mean AnLLs of the dentate and edentulous side were 1.55 mm and 1.00 mm, respectively. Therefore, we believe that when the age increases, the number of posteriorly edentulous mandibles increases, the bone resorption increases, and the AnLL and prevalence decrease.

Complications of surgical trauma or pressure on the mental nerve can result in neurosensory disturbances and altered sensation of the lower lip and chin after implant placement.^{13,38,39} Ellies and Hawker⁴⁰ reported a retrospective analysis of a multicenter study. They found altered sensation of the mandibular alveolar nerve in 36% of patients after 2 weeks and 13% after 1 year. It has been suggested in the literature that the most distal aspect of an implant should be at least 1 mm,¹⁹ 4 mm,¹⁰ or 6 mm²¹ anterior to the foramen to avoid injuring the inferior alveolar and/or mental nerves during an osteotomy based on findings of the prevalence and extent of the anterior loop of the mental nerve. In the present study, the largest AnLL was 6.67 mm. Moreover, the longest loop in the literature was reported by Neiva et al,³³ being 11 mm, followed by Uchida et al¹⁶ with a length of 9 mm. For these cases, following the 1-, 4-, or 6-mm rule would lead us to injure the nerve when placing implants in close proximity to the mental foramina.

On the other hand, if we place every implant 6 mm anterior to the mental foramen, we limit the interforaminal space available for implant placement. The range of the AnLL found in our study is –2.87 mm to 6.67 mm. No studies in the literature

have calculated the negative value when the anterior loop was not present. However, Kieser et al³⁴ in 2002 described 5 patterns of emergence of the human mental nerve. Type 1, referred to as a posterior directed emergence, type 2 an anterior directed emergence, type 3 a right-angled pattern of emergence, type 4 to multiple foramina, and type 5 to the alveolus had resorbed, and no evaluation was possible. It is also important to recognize type 2 of mental nerve (for which the anterior loop has a negative value) because the surgeon can place the implant closer to the mental foramen and even posterior to the mental foramen. In the treatment of mandibular arch involving the interforaminal area, a full arch implant-supported restoration involving 4 to 5 implants is a good viable option. To place the implant closest to the mental foramen with concern on the anterior loop is the key factor for increasing the A-P spread and reducing distal cantilever.^{11,12} In addition, placing implants in mandibular partially dentate patients involving premolar and molar areas, the mental neurovascular bundle is usually the critical reference point during treatment planning. Therefore, the precise location of the mental loop must be identified using proper radiographic techniques before surgery. We recommended using the oblique transverse reconstruction modality on CBCT to accurately locate and measure the AnLL prior to the implant surgery.

CONCLUSION

After evaluating 366 CBCT scans of patients:

1. Of the scans, 85.2% revealed the presence of an anterior loop of the mental nerve.
2. A wide range of measurements existed for the AnLL, ranging from –2.87 mm to 6.67 mm, with a mean of 1.46 mm.
3. No statistically significant differences were found between the left- and right-side measurements or between genders, but the 21–40 year age group had a significantly larger AnLL than ages 41–60 and 61–80 years.

When placing implants in close proximity to the mental

TABLE 4

Post hoc statistical analysis comparing different age groups

	Bonferroni Test (* <i>P</i> < .05)	Scheffé test (* <i>P</i> < .05)
Age 21–40 y vs 41–60 y	.002*	.003*
Age 21–40 y vs 61–80 y	.000*	.000*
Age 41–60 y vs 61–80 y	.521	.396

TABLE 5

Posteriorly edentulous hemimandibles in each age group

	Dentate	Posteriorly Edentulous
Age 21–40 y	236 (96.72%)	8 (3.28%)
Age 41–60 y	195 (79.92%)	49 (20.08%)
Age 61–80 y	176 (72.13%)	68 (27.87%)

foramina, caution is recommended to avoid injury to the mental nerve and its neurovascular bundle. The anterior loop of the mental nerve becomes a critical surgical reference point during treatment planning. Because of the wide range of the AnLL observed in our study, no fixed distance mesially or anteriorly from the mental foramen should be considered to be a "safe" distance without the use of 3D imaging. Analyzing CBCT scans using the method described in this article can be a useful tool for avoiding implant surgical complications.

ABBREVIATIONS

2D: 2-dimensional
 3D: 3-dimensional
 AnLL: anterior loop length
 ANOVA: analysis of variance
 A-P spread: anterior-posterior spread
 CBCT: cone-beam computerized tomography
 CT: computerized tomography
 MDCT: multi-detector computed tomography
 RMSSE: root mean square standardized effect

ACKNOWLEDGMENT

The authors would like to thank Ashish Sharma, the residents, and faculty members at Advanced Education in Implant Dentistry, Loma Linda University School of Dentistry, for their involvement in the study and Ching-Ho Leu and Udochukwu Oyoyo for their assistance with the statistical analysis.

REFERENCES

- Misch CE. Diagnostic imaging and techniques. In: *Contemporary Implant Dentistry*. 3rd ed. St Louis, Mo: Mosby; 38–67.
- Harris D, Buser D, Dula K, et al. E.A.O. guidelines of the use of diagnostic imaging in implant dentistry: a consensus workshop organized by the European Association for Osseointegration in Trinity College Dublin. *Clin Oral Implants Res*. 2002;14:464–471.
- Frei C, Buser D, Dula K. Study on the necessity for cross-section imaging of the posterior mandible for treatment planning of standard cases in implant dentistry. *Clin Oral Implants Res*. 2004;15:490–497.
- Tyndall DA, Price JB, Tetradis S, Ganz SD, Hildebolt C, Scarfe WC; American Academy of Oral and Maxillofacial Radiology. Position statement of the American Academy of Oral and Maxillofacial Radiology on selection criteria for the use of radiology in dental implantology with emphasis on cone beam computed tomography. *Oral Surg Oral Med Oral Pathol Oral Radiol*. 2012;113:817–826.
- Reddy MS, Mayfield-Donahoo T, Vandervan FJ, Jeffcoat MK. A comparison of the diagnostic advantages of panoramic radiography and computed tomography scanning for placement of root form dental implants. *Clin Oral Implants Res*. 1994;5:229–238
- Schropp L, Wenzel A, Kostopoulos L. Impact of conventional tomography on prediction of the appropriate implant size. *Oral Surg Oral Med Oral Pathol*. 2001;92:458–463.
- DuBrul EL. *Sicher's Oral Anatomy*. 7th ed. St Louis, Mosby; 1980:449–450
- Mardinger O, Chaushu G, Arensburg B, Taicher S, Kaffel. Anterior loop of the mental canal: an anatomical-radiologic study. *Implant Dent*. 2000;9:120–123.
- Serhal CB, Steenberghe DV, Quirynen M, Jacobs R. Localization of the mandibular canal using conventional spiral tomography: a human cadaver study. *Clin Oral Implants Res*. 2001;12:230–236.
- Kuzmanovic DV, Payne AGT, Kieser JA, Dias GJ. Anterior loop of the

mental nerve: a morphological and radiographic study. *Clin Oral Implants Res*. 2003;14:464–471.

- English CE. Critical A-P spread. *Implant Soc*. 1990;1(1):2–3.
- Rangert B, Jemt T, Jörneus L. Forces and moments on Branemark implants. *Int J Oral Maxillofac Implants*. 1989;4:241–247.
- Kraut RA, Chahal O. Management of patients with trigeminal nerve injuries after mandibular implant placement. *J Am Dent Assoc*. 2002;133:1351–1354.
- Arzouman MJ, Otis L, Kipnis V, Levine D. Observations of the anterior loop of the inferior alveolar canal. *Int J Oral Maxillofac Implants*. 1993;8:295–300.
- Kaya Y, Sencimen M, Sahin S, Okcu KM, Dogan N, Bahcecitapar M. Retrospective radiographic evaluation of the anterior loop of the mental nerve: comparison between panoramic radiography and spiral computerized tomography. *Int J Oral Maxillofac Implants*. 2008;23:919–925.
- Uchida Y, Noguchi N, Goto M, et al. Measurement of anterior loop length for the mandibular canal and diameter of the mandibular incisive canal to avoid nerve damage when installing endosseous implants in the interforaminal region: a second attempt introducing cone beam computed tomography. *J Oral Maxillofac Surg*. 2009;67:744–750.
- Ngeow WC, Dionysius DD, Ishak H, Nambiar P. A radiographic study on the visualization of the anterior loop in dentate subjects of different age groups. *J Oral Sci*. 2009;51:231–237.
- Gerlach NL, Meijer GJ, Maal TJ, et al. Reproducibility of 3 different tracing methods based on cone beam computed tomography in determining the anatomical position of the mandibular canal. *J Oral Maxillofac Surg*. 2010;68:811–817.
- Bavitz JB, Harn SD, Hansen CA, Lang M. An anatomical study of mental neurovascular bundle-implant relationships. *Int J Oral Maxillofac Implants*. 1993;8:563–567.
- Chen JC, Lin LM, Geist JR, Chen JY, Chen CH, Chen YK. A retrospective comparison of the location and diameter of the inferior alveolar canal at the mental foramen and length of the anterior loop between American and Taiwanese cohorts using CBCT. *Surg Radiol Anat*. 2013;35:11–18.
- Solar P, Ulm C, Frey G, et al. A classification of the intraosseous path of the mental nerve. *Int J Oral Maxillofac Implants*. 1994;9:339–344.
- Uchida Y, Yamashita Y, Goto M, Hanihara T. Measurement of anterior loop length for the mandibular canal and diameter of the mandibular incisive canal to avoid nerve damage when installing endosseous implants in the interforaminal region. *J Oral Maxillofac Surg*. 2007;65:1772–1779.
- Misch CE, Crawford EA. Predictable mandibular nerve location—a clinical zone of safety. *Int J Oral Implantol*. 1990;7:9–17
- Yosue T, Brooks SL. The appearance of mental foramina on panoramic radiographs. I. Evaluation of patients. *Oral Surg Oral Med Oral Pathol*. 1989;68:360–364.
- Sukovic P. Cone beam computed tomography in craniofacial imaging. *Orthod Craniofac Res*. 2003;6(suppl 1):31–36.
- Clark DE, Danforth RA, Barnes RW, Burtch ML. Radiation absorbed from dental implant radiography: a comparison of linear tomography, CT scan, and panoramic and intra-oral techniques. *J Oral Implantol*. 1990;16:156–164.
- Tsiklakis K, Donta C, Gavala S, Karayianni K, Kamenopoulou V, Hourdakis CJ. Dose reduction in maxillofacial imaging using low dose cone beam CT. *Eur J Radiol*. 2005;56:413–417.
- Poeschl PW, Schmidt N, Guevara-Rojas G, et al. Comparison of cone-beam and conventional multislice computed tomography for image-guided dental implant planning. *Clin Oral Investig*. 2013;17:317–324.
- Al-Ekrish AA, Ekram M. A comparative study of the accuracy and reliability of multidetector computed tomography and cone beam computed tomography in the assessment of dental implant site dimensions. *Dentomaxillofac Radiol*. 2011;40:67–75.
- Santana RR, Lozada J, Kleinman A, Al-Ardah A, Herford A, Chen JW. Accuracy of cone beam computerized tomography and a three-dimensional stereolithographic model in identifying the anterior loop of the mental nerve: a study on cadavers. *J Oral Implantol*. 2012;38:668–676.
- Apostolakis D, Brown JE. The anterior loop of the inferior alveolar nerve: prevalence, measurement of its length and a recommendation for interforaminal implant installation based on cone beam CT imaging. *Clin Oral Implants Res*. 2012;23:1022–1030.
- Rosa MB, Sotto-Maior BS, Machado Vde C, Francischone CE. Retrospective study of the anterior loop of the inferior alveolar nerve and

the incisive canal using cone beam computed tomography. *Int J Oral Maxillofac Implants.* 2013;28:388–392.

33. Neiva RF, Gapski R, Wang HL. Morphometric analysis of implant-related anatomy in Caucasian skulls. *J Periodontol.* 2004;75:1061–1067.

34. Kieser J, Kuzmanovic D, Payne A, Dennison J, Herbison P. Patterns of emergence of the human mental nerve. *Arch Oral Biol.* 2002;47:743–747.

35. Jacobs R, Mraiwa N, vanSteenberghe D, Gijbels F, Quirynen M. Appearance, location, course, and morphology of the mandibular incisive canal: an assessment on spiral CT scan. *Dentomaxillofac Radiol.* 2002;31:322–327.

36. Watanabe H, Mohammad Abdul M, Kurabayashi T, Aoki H.

Mandible size and morphology determined with CT on a premise of dental implant operation. *Surg Radiol Anat.* 2010;32:343–349.

37. Gershenson A, Nathan H, Luchansky E. Mental foramen and mental nerve: changes with age. *Acta Anat (Basel).* 1986;126:21–28.

38. Walton JN. Altered sensation associated with implants in the anterior mandible: a prospective study. *J Prosthet Dent.* 2000;83:443–449.

39. Wismeijer D, van Waas MA, Vermeeren JI, Kalk W. Patients' perception of sensory disturbances of the mental nerve before and after implant surgery: a prospective study of 110 patients. *Br J Oral Maxillofac Surg.* 1997;35:254–259.

40. Ellies LG, Hawker PB. The prevalence of altered sensation associated with implant surgery. *Int J Oral Maxillofac Implants.* 1993;8:674–679.