

# Widening Keratinized Tissue Using Modified Free Gingival Graft

Jun-Beom Park, DDS, MSD, PhD

**T**he need for keratinized tissue around endosseous implants is controversial. Longitudinal clinical studies have failed to reveal major differences in the progression of lesions around implants placed in sites with or without keratinized mucosa.<sup>1</sup> However, increasing the width of keratinized tissue may benefit peri-implant tissue health, including reduced plaque accumulation and mucosal inflammation.<sup>2</sup>

The free gingival graft (FGG) is one of the most common and predictable methods for augmenting gingival tissue dimensions.<sup>3</sup> The use of FGG has some limitations because it requires an additional wound in the palatal area and success depends on the amount of donor tissue.<sup>4</sup>

There have been many attempts to overcome the donor tissue limitations and reduce pain at the donor site. The strip technique may maximize the area of gingival grafting and minimize trauma,<sup>5,6</sup> and the expanded mesh graft method covers a larger area by stretching graft material.<sup>7</sup>

In this case report, the modified FGG technique increased keratinized tissue using less donor tissue by placing the graft material as apically as possible and leaving the periosteum coronal to the graft exposed.

## CASE PRESENTATION

A 46-year-old woman seeking treatment for missing teeth was referred to the Department of Prosthodontics. The patient had a noncontributory medical history and was not taking any medications associated with a compromised bone-healing response. Clinical and radiographic examinations revealed that the lower right premolar, first molar, and second molars were missing (Figures 1a through c). The mean width of keratinized tissue on the buccal side was <1 mm. Consulting with the patient on the treatment period and possible complications led to a plan for dental implants and both soft and hard tissue grafts. The patient received detailed explanation of the procedure and provided informed consent. An acrylic stent with a Marquis periodontal probe (Hu-Friedy, Chicago, Ill) was used to make the measurements, including the vertical dimension of keratinized tissue.

Preoperative vertical dimension was the distance from the most apical keratinized tissue to the most coronal keratinized tissue, as the graft was placed as apically as possible and some portion of periosteum remained exposed. The dimensional

changes in the width of keratinized tissue were considered shrinkage of the graft.

Immediately before the procedure, the patient rinsed for 2 minutes with a 0.12% chlorhexidine digluconate solution (Hexamedine, Bukwang, Seoul, Korea). After an injection of 2% lidocaine with 1:100 000 epinephrine local anesthetic, we placed a releasing incision between the mucogingival junction and the marginal tissue. A partial-thickness flap was reflected as close to the periosteum as possible to create the bed preparation. The FGG (length 15 mm × height 4.5 mm) originated from the right palate in the molar area (Figure 2a). The graft was trimmed to a uniform thickness of approximately 1.00 mm. Absorbable sutures positioned the raised partial-thickness flap apically and secured it to the periosteum (Vicryl, Johnson and Johnson Medical Inc, Arlington, Tex) with simple interrupted sutures. The graft was placed as apically as possible on the firm periosteal bed with the connective tissue side against the periosteum, leaving an average of 3.5 mm of the periosteum exposed (Figure 2b). Sutures (Vicryl) stabilized the graft, and routine postoperative instructions ensued. The patient was placed on amoxicillin 500 mg 3 times per day for 5 days, aceclofenac 100 mg twice per day for 5 days, and chlorhexidine digluconate 0.12% 3 times per day for 4 weeks. The patient was asked not to chew or brush the surgical area for the first 4 weeks postoperatively.

Eight days after surgery, the remaining sutures were removed. The grafted area was carefully cleaned with a 0.12% chlorhexidine solution. The width of keratinized tissue at postoperative day 8 was 8.0 mm (Figure 2c). No major postoperative problems developed, and the patient reported minimal pain. The patient received oral hygiene instructions and was shown how to achieve a roll-stroke brushing technique. The patient was seen regularly to monitor healing and plaque control.

Six weeks later, three implants (AVANA, Osstem, Seoul, Korea) were placed after elevating the full-thickness flap (Figures 3a and b). The buccal surface and marginal voids were grafted with bovine anorganic hydroxyapatite (Bio-Oss, Geistlich Pharma AG, Wolhusen, Switzerland). The remaining sutures were removed 2 weeks after implant installation, which was 8 weeks after the FGG surgery (Figure 3c). The evaluation 6 months after surgery showed a stable 5.0 mm of keratinized tissue on the buccal side (Figures 4a and b). The values of the vertical and horizontal dimensions of keratinized tissue and the shrinkage of the graft material are shown in the Table.

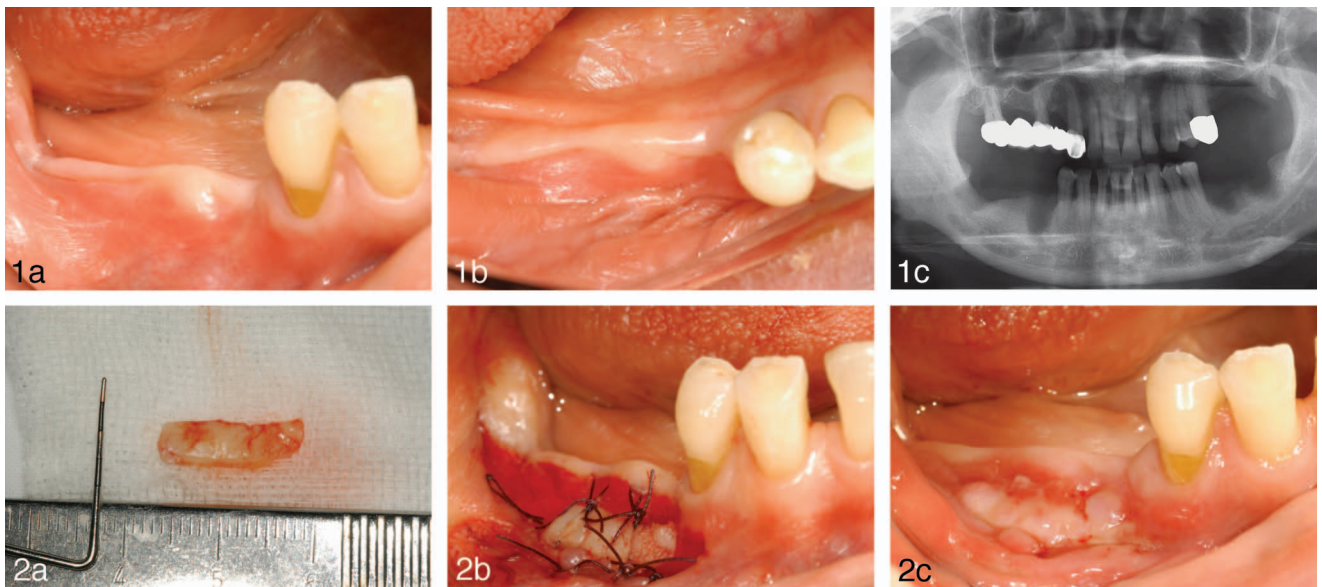
## DISCUSSION

In this case report, the modified FGG technique was used to increase keratinized tissue. Keratinized tissue increases the

Department of Periodontics, College of Medicine, The Catholic University of Korea, Seoul, Republic of Korea.

Corresponding author, e-mail: jbaasoonis@yahoo.co.kr

DOI: 10.1563/aaid-joi-D-13-00353



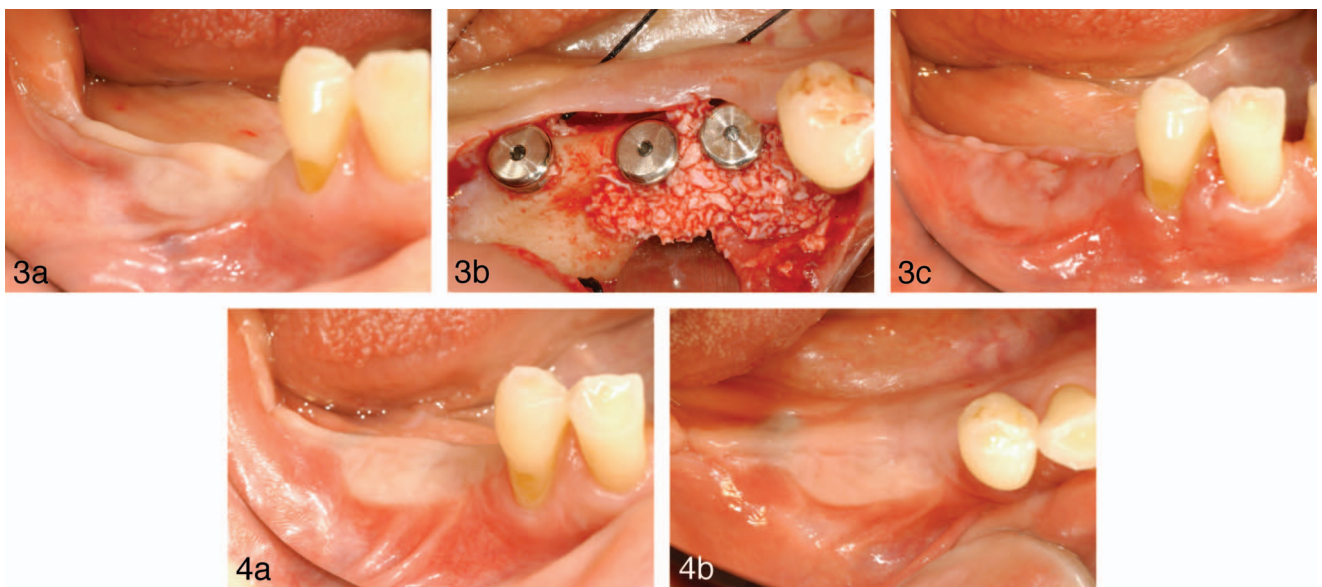
**FIGURES 1 AND 2.** **FIGURE 1.** (a) Clinical photograph taken at the initial visit. (b) Occlusal view showing minimal keratinized tissue on the buccal side. (c) Radiograph taken at the initial visit. **FIGURE 2.** (a) The free gingival graft (length 15 mm  $\times$  height 4.5 mm) was obtained from the palate. (b) Sutures secured the graft to the periosteum. (c) An 8-day postoperative buccal view showing increased keratinized tissue.

resistance of the periodontium, stabilizes the gingival margin position, and dissipates some physiological forces exerted by the muscular fibers of the alveolar mucosa onto the gingival tissues.<sup>7</sup> A certain minimum thickness of peri-implant mucosa may be required to avoid bone resorption, and marginal tissue thickness may be another critical determinant of future bone loss.<sup>8</sup>

Some authors have used monkeys to study the healing of free soft tissue grafts placed entirely on a connective tissue

recipient bed. They reported that the tissue maturation phase was 11 to 42 days.<sup>9,10</sup> Implant installation was performed 6 weeks after the FGG procedure to provide adequate healing time.<sup>11</sup> In this study, implants were placed using a full-thickness flap 6 weeks after the modified FGG procedure.

A recent report described use of the modified, apically repositioned flap to increase the apico-coronal dimension of keratinized tissue over multiple adjacent teeth.<sup>12</sup> This technique



**FIGURES 3 AND 4.** **FIGURE 3.** (a) Photograph taken just before implant installation, 6 weeks after free gingival graft (FGG) surgery. (b) Three implants were placed, and the buccal surface and marginal voids were grafted with bovine anorganic hydroxyapatite. (c) The remaining sutures were removed 2 weeks after implant installation, which was 8 weeks after FGG surgery. **FIGURE 4.** (a) Buccal view 6 months after FGG surgery. (b) Occlusal view 6 months after FGG surgery showing stable result.

TABLE  
The value of vertical and horizontal dimension of keratinized tissue and the shrinkage of the graft material

		8 Days	6 Weeks	8 Weeks	26 Weeks
Length (mm)	Vertical	8.0	7.0	7.0	5.0
	Horizontal	14.0	12.0	12.0	11.0
Shrinkage (%)	Vertical	11.2	22.2	22.2	44.4
	Horizontal	6.7	20.0	20.0	26.7

is limited by the amount of attached gingiva (a minimum of 0.5 mm and a maximum of 2.0 mm), and the mean increase of keratinized tissue was 2 mm.

Shrinkage of the FGG is a well-known clinical phenomenon, and overcorrection is needed.<sup>13</sup> In this case, the preoperative vertical dimension was the distance from the most apical keratinized tissue to the most coronal keratinized tissue because the graft was placed as apically as possible, and some portion of periosteum was left exposed. The dimensional changes in the size of the width of keratinized tissue were considered shrinkage of the graft. Previous report showed that 24.8% of contractions were noticed at 6 months.<sup>13</sup> Orsini et al<sup>14</sup> used free connective tissue and reported a 37.2% mean shrinkage of the graft at 6 months. The case report found 44.4% of vertical shrinkage during a 26-week interval.

Even though the shrinkage was greater than that measured by other authors,<sup>13,14</sup> the results seem promising considering the similarity of the increase of keratinized tissue to the original graft size at the final examination. This may be because the exposed periosteum was healed with keratinized tissue. In this report, shrinkage occurred throughout the study period with linear pattern  $R^2 = 0.98$ , which suggests that the rate of shrinkage after FGG may be similar irrespective of additional surgeries.

**CONCLUSION**

In this case report, the graft material was placed as apically as possible and the periosteum coronal to the graft was left partially exposed. The exposed periosteum healed with keratinized tissue. A wider segment of keratinized tissue can be obtained with less donor tissue using this modified technique.

**ABBREVIATION**

FGG: free gingival graft

**ACKNOWLEDGMENT**

The research was supported by Basic Science Research Program through the National Research Foundation of Korea (NRF)

funded by the Ministry of Science, Information, and Communication Technology & Future Planning (NRF-2014R1A1A1003106).

**REFERENCES**

1. Salvi GE, Lang NP. Diagnostic parameters for monitoring peri-implant conditions. *Int J Oral Maxillofac Implants.* 2004;19(suppl):116-127.
2. Brito C, Tenenbaum HC, Wong BK, Schmitt C, Nogueira-Filho G. Is keratinized mucosa indispensable to maintain peri-implant health? A systematic review of the literature. *J Biomed Mater Res B Appl Biomater.* 2013;102:643-659.
3. Basegmez C, Ersanli S, Demirel K, Bolukbasi N, Yalcin S. The comparison of two techniques to increase the amount of peri-implant attached mucosa: free gingival grafts versus vestibuloplasty. One-year results from a randomised controlled trial. *Eur J Oral Implantol.* 2012;5:139-145.
4. Wei PC, Laurell L, Lingen MW, Geivelis M. Acellular dermal matrix allografts to achieve increased attached gingiva. Part 2. A histological comparative study. *J Periodontol.* 2002;73:257-265.
5. Han TJ, Klokkevold PR, Takei HH. Strip gingival autograft used to correct mucogingival problems around implants. *Int J Periodontics Restorative Dent.* 1995;15:404-411.
6. Han TJ, Takei HH, Carranza FA. The strip gingival autograft technique. *Int J Periodontics Restorative Dent.* 1993;13:180-187.
7. Cetiner D, Bodur A, Uraz A. Expanded mesh connective tissue graft for the treatment of multiple gingival recessions. *J Periodontol.* 2004;75:1167-1172.
8. Berglundh T, Lindhe J. Dimension of the periimplant mucosa. Biological width revisited. *J Clin Periodontol.* 1996;23:971-973.
9. Nobuto T, Imai H, Yamaoka A. Microvascularization of the free gingival autograft. *J Periodontol.* 1988;59:639-646.
10. Oliver RC, Loe H, Karring T. Microscopic evaluation of the healing and revascularization of free gingival grafts. *J Periodontol Res.* 1968;3:84-95.
11. Maynard JG Jr. Coronal positioning of a previously placed autogenous gingival graft. *J Periodontol.* 1977;48:151-155.
12. Carnio J, Camargo PM, Passanezi E. Increasing the apico-coronal dimension of attached gingiva using the modified apically repositioned flap technique: a case series with a 6-month follow-up. *J Periodontol.* 2007;78:1825-1830.
13. Hatipoglu H, Keceli HG, Guncu GN, Sengun D, Tozum TF. Vertical and horizontal dimensional evaluation of free gingival grafts in the anterior mandible: a case report series. *Clin Oral Investig.* 2007;11:107-113.
14. Orsini M, Orsini G, Benlloch D, Aranda JJ, Lazaro P, Sanz M. Esthetic and dimensional evaluation of free connective tissue grafts in prosthetically treated patients: a 1-year clinical study. *J Periodontol.* 2004;75:470-477.