

# Anatomic Analysis of the Maxillary Sinus: Preliminary Morphologic Comparison of Animal Models (Pig, Lamb, and Human)

Roberto Garrido-Serrano, BDS<sup>1</sup>  
Francisco Azcárate-Velázquez, BDS<sup>1</sup>  
Pablo Núñez-Arcos, BDS<sup>2</sup>  
Francisco Marmesat-Guerrero, BDS<sup>2</sup>  
Raquel Castillo-Oyagüe, BDS<sup>1</sup>  
José Luis Gutiérrez-Pérez, BDS<sup>1</sup>  
Daniel Torres-Lagares, BDS<sup>1\*</sup>

## INTRODUCTION

**A**dvanced maxillary atrophy and associated sinus hyperpneumatization present major challenges to implant rehabilitation.

The surgical procedure known as sinus lift or augmentation was developed in order to resolve this issue.<sup>1-3</sup>

Boyne and James in 1980, and later Tatum, in 1986, described this technique using a modified Caldwell-Luc approach, accessing the sinus through the lateral side, and detaching and lifting the Schneiderian membrane without damaging it so as to obtain more space for placing implants without contributing to damage to the membrane or maxillary sinus.<sup>1-3</sup>

Since then, several variations and modifications of this technique have been developed, with approaches through the alveolar ridge or atraumatic or closed lifts, with osteotomes. Over time, sinus lifts have become virtually routine surgical procedures and are frequently performed in dental practice, with a continuously increasing number of practicing oral surgeons.<sup>1,4,5</sup>

As with any other procedure, sinus lifts require practical training and a knowledge base. Animal models, serving as low-cost biologic models, have always been used for practicing surgical techniques. Authors have used several different animal models, including sheep,<sup>6</sup> rabbits,<sup>7,8</sup> goats,<sup>9</sup> and monkeys.<sup>10,11</sup>

However, until now, very few studies have compared the anatomic morphology of different animal species in order to determine which is best for learning sinus lift techniques.<sup>6</sup>

The aim of this study was to determine whether sufficient anatomic similarity existed between lamb and pig animal models and which provided the strongest similarity to human anatomic structures in the maxillary sinus region in order to identify which model would serve best as a tool with which to learn the surgical sinus lift technique. We also sought to determine which animal model provides the strongest similarities to human anatomic structures in the maxillary sinus region.

## MATERIALS AND METHODS

Our study was carried out in the Department of Odontology of the University of Seville, with the collaboration of the Radisur 3D Radiological Centre (Seville, Spain).

We analyzed 9 skulls, 3 each belonging to pigs, lambs, and humans.

Our inclusion criteria for lamb and pig samples were: fresh heads from adult animals (within 24 hours of the animal's sacrifice) in order to minimize possible postmortem anatomic changes. All of the specimens obtained for this study were from animals humanely killed for commercial purposes in a local slaughterhouse, complying with all European Union regulations. For humans, we reviewed cone-beam computerized tomography images that were taken for reasons other than our study purposes; and in all cases, the patients had no sinus abnormalities. In addition, samples in which the sinus came into contact with edentulous sections were excluded in order to avoid any possible bias in our measurements due to sinus hyperpneumatization.

The acquisition of our study images was done by cone-beam computerized tomography produced by a KODAK 9500 device (Carestream Health Inc, Rochester, NY), at 90kVp and 10mA. The voxel size was 0.3 mm and the analysis involved 0.3-mm slices.

Three-dimensional (3D) reconstructions of the Digital Imaging and Communications in Medicine (DICOM) images were produced using KODAK Dental Imaging Software, v.2.2 (Carestream Health Inc) (Figure 1).

Metric analysis of the sinus morphology of each species was performed, based on identifying structures in the 3D tomography reconstructions using a series of anatomic points (Figure 2a and b).

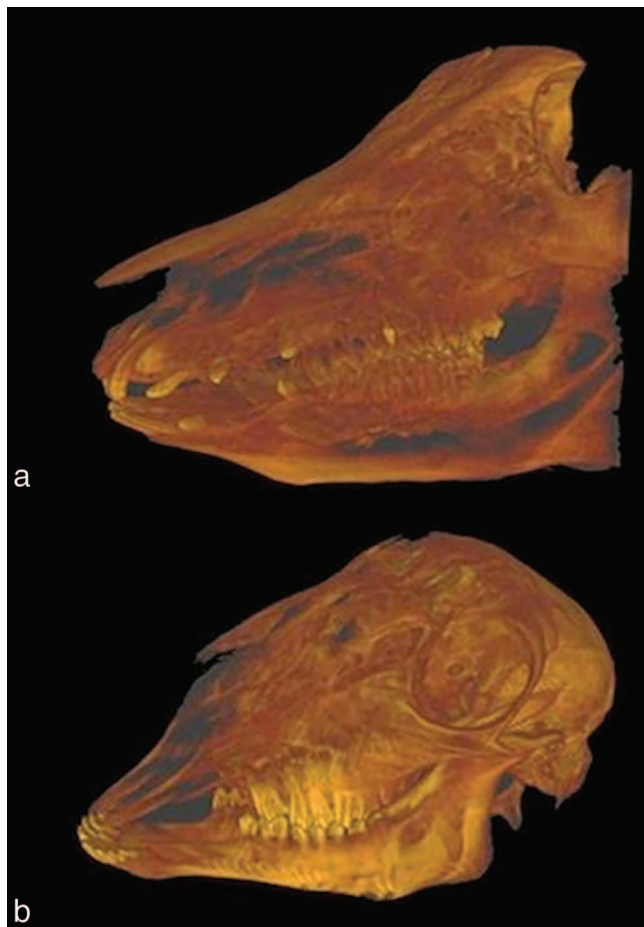
These points were: (1) MSx (medial maxillary sinus), in an anterior view, the point closest to the medial line; (2) LSx (lateral maxillary sinus), in an anterior view, the most lateral point, or farthest from the medial line; (3) PSx (posterior maxillary sinus), in a lateral view, from an anteroposterior approach, the most posterior point of the sinus; (4) ASx (anterior maxillary sinus), in a lateral view, from an anteroposterior approach, the most anterior point of the sinus; (5)

<sup>1</sup> Hospital Universitario Virgen del Rocío, Seville, Spain.

<sup>2</sup> Radisur 3D, Seville, Spain.

\* Corresponding author, e-mail: daniel@us.es

DOI: 10.1563/AAID-JOI-D-13-00363



**FIGURE 1.** Images obtained from 3-dimensional reconstructions of computerized tomography scans using KODAK Dental Imaging Software v.2.2. (a) Pig. (b) Lamb.

CrSx (cranial maxillary sinus), in lateral and anterior views, the most cranial, highest point of the sinus; (6) CaSx (caudal maxillary sinus), in lateral and anterior views, the most caudal, lowest point of the sinus; (7) Wsx (maxillary sinus window), estimated central point of the area where the sinus window would be created in the case of a sinus lift (this point is not represented by any numeric value, but rather refers to a positional reference point); (8) CrWsx (cranial maxillary sinus, window area), in lateral and anterior views, the most cranial, highest point of the area where a sinus window would be created; (9) CaWsx (caudal maxillary sinus, window area), in lateral and anterior views, the most caudal, lowest point of the area where a sinus window would be created; (10) CoWsx (external cortical, window area), in anterior view, at the level of the Wsx, the external cortical bone; and (11) PoWsx (occlusal plane sinus, window area), in anterior view, at the level of the Wsx, the midpoint of the occlusal molar side from and vestibulo-lingual approach.

From these points, we determined the following linear measurements: (1) anteroposterior sinus length (APL) ASx-PSx: linear distance between the farthest anterior and posterior points of the maxillary sinus; (2) medial-lateral sinus width

(MLW) MSx-LSx: linear distance between the farthest medial and farthest lateral points of the sinus; (3) cranial-caudal sinus height (CCH) CrSx-CaSx: linear distance between the farthest cranial and farthest caudal points of the maxillary sinus; (4) cranial-caudal sinus height in window area (CCHW) CrWsx-CaWsx: linear distance between the most cranial and most caudal points at the level of the sinus lift window; (5) cortical width (CW) CoSx: width of the cortical bone at the lateral wall of the sinus, in the window area; and (6) distance from the floor of the sinus to the occlusal plane (DFOP) CaWsx-PoWsx: linear distance between the most caudal point at the sinus floor in the window area and the medial point of the occlusal side of the molar (in relation to the window area).

We recorded all results in a file for descriptive statistical analysis using SPSS software v.11.0 (SPSS, Chicago, Ill). We compared mean values between groups for each variable using analysis of variance (ANOVA) and Bonferroni post-hoc analyses. Statistical significance was set at  $P < .05$ .

In order to evaluate similarity between anatomic models based on the number of significantly different linear measurements observed between humans, lambs, and pigs, we used the following classification system for anatomic similarity between species in the maxillary sinus: (1) very similar: no statistically significant differences were observed between groups in any of the different measurements; (2) similar: 1 measurement was found to be significantly different between species; (3) somewhat similar: 2 measurements were significantly different; and (4) incomparable: 3 or more measurements were significantly different.

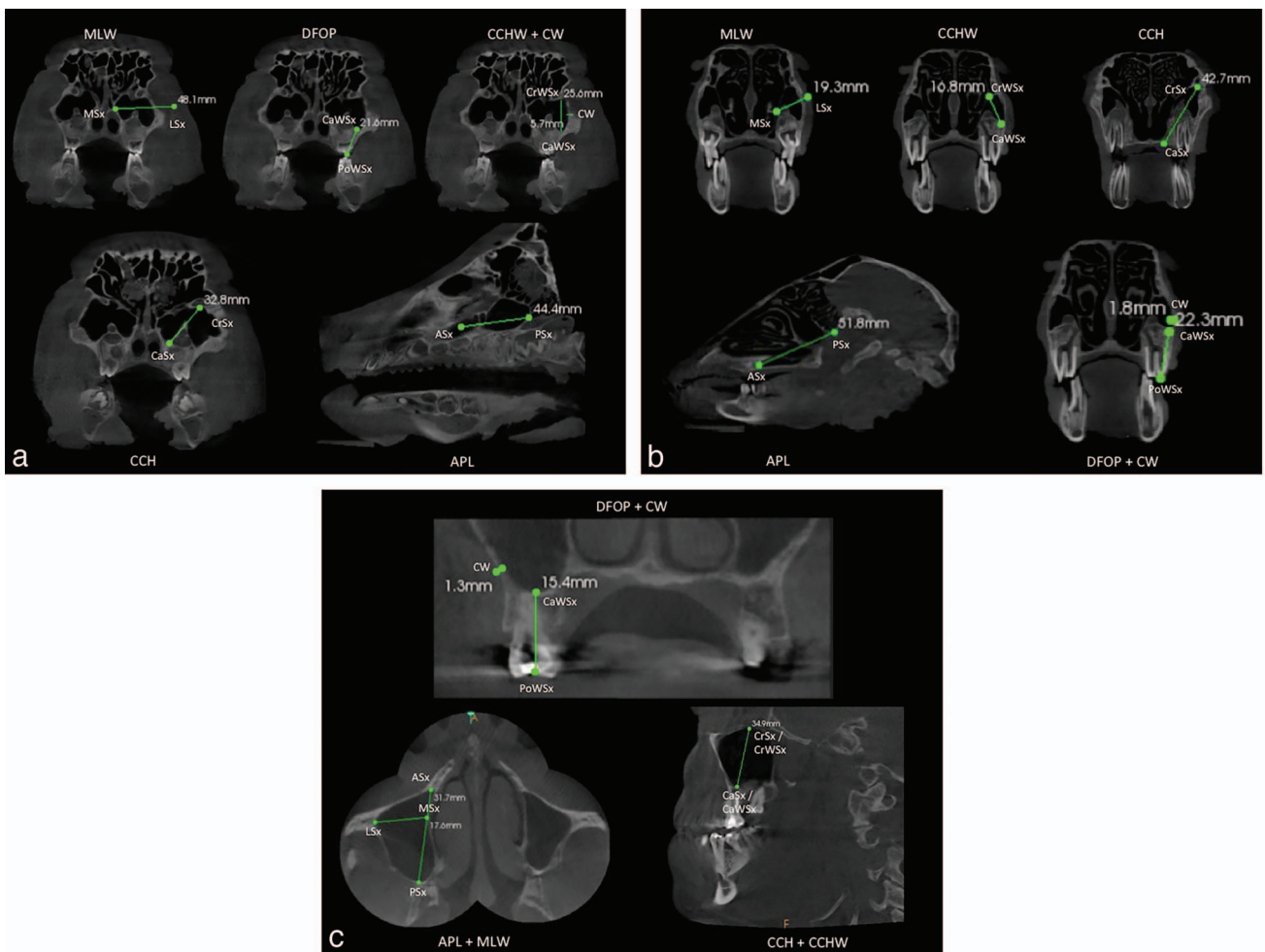
## RESULTS

The results from the different measurements are summarized in the Table. Both pigs and lambs had larger mean APL values than humans:  $45.13 \pm 2.2$  mm and  $43.76 \pm 6.9$  mm vs  $34.66 \pm 3.6$  mm, respectively. Lamb MLW values were very similar to humans:  $18.93 \pm 1.0$  mm vs  $21.16 \pm 3.1$  mm, but the same could not be said of pigs:  $45.13 \pm 3.0$  mm. Human CCHW values were greater than in both lambs and pigs, though they were more similar to pigs:  $35.80 \pm 2.1$  mm vs  $17.03 \pm 3.2$  mm and  $29.93 \pm 4.0$  mm, respectively.

Mean CW values were higher for lambs and pigs than for humans:  $2.63 \pm 0.7$  mm and  $5.16 \pm 0.6$  mm vs  $1.60 \pm 0.3$  mm. The same was observed for DFOP values:  $25.76 \pm 3.1$  mm and  $23.00 \pm 2.1$  mm vs  $17.60 \pm 2.1$  mm.

Following the procedure described in the Materials & Methods section, we performed statistical analysis of our results, and the significant differences found are summarized in the Table.

According to the classification system described in the Materials and Methods section, lambs would be classified as "similar" (1 significant difference found between lamb and human measurements, precisely on the DFOP values), whereas pigs would be classified as "somewhat similar" (2 significant differences observed between pig and human values, on both CW and MLW values). Finally, lambs and pigs, having 3 significant differences between them (CW, MLW, and CCHW), are "incomparable" species.



**FIGURE 2.** Measurements obtained for (a) pigs, (b) lambs, and (c) humans. Please note that values such as LSx, ASx, CrWsx, CaWsx, CoWsx, or PoWsx are marked in a slice of the tomography different of the one shown. This is because the image shows the lineal measurements, and because these lines join points located in different slices, it is impossible to show the actual position of every anatomic point.

TABLE						
Values (in mm) obtained from the different measurements*†						
Measurement	APL	MLW	CCH	CCHW	CW	DFOP
<b>Human</b>						
Global	34.66 ± 3.6	21.16 ± 3.1 <sup>f</sup>	35.80 ± 2.1	35.80 ± 2.1	1.60 ± 0.3 <sup>c</sup>	17.60 ± 2.1 <sup>a</sup>
1	31.7	17.6	34.3	34.3	1.3	15.4
2	38.7	23.1	38.2	38.2	1.9	19.5
3	33.6	22.8	34.9	34.9	1.6	17.9
<b>Pig</b>						
Global	45.13 ± 2.2	45.13 ± 3.0 <sup>d,f</sup>	39.33 ± 7.5	29.93 ± 4.0 <sup>d</sup>	5.16 ± 0.6 <sup>b,c</sup>	23.00 ± 2.1
1	44.4	48.1	32.8	25.6	5.7	21.6
2	45.4	42.0	37.6	33.5	4.5	22.0
3	41.1	45.3	47.6	30.7	5.3	25.4
<b>Lamb</b>						
Global	43.76 ± 6.9	18.93 ± 1.0 <sup>e</sup>	39.40 ± 2.8	17.03 ± 3.2 <sup>e</sup>	2.63 ± 0.7 <sup>b</sup>	25.76 ± 3.1 <sup>a</sup>
1	51.8	19.3	42.7	16.8	1.8	22.3
2	39.0	19.7	37.7	13.9	3.3	28.2
3	40.5	17.8	37.8	20.4	2.8	26.8

\*APL indicates anteroposterior sinus length; MLW, medial-lateral sinus width; CCH, cranial-caudal sinus height; CCHW, cranial-caudal sinus height in window area; CW, cortical width; and DFOP, distance from the floor of the sinus to the occlusal plane.

†Paired letters in parentheses (a through f) identify values with statistically significant differences ( $P < .05$ ).

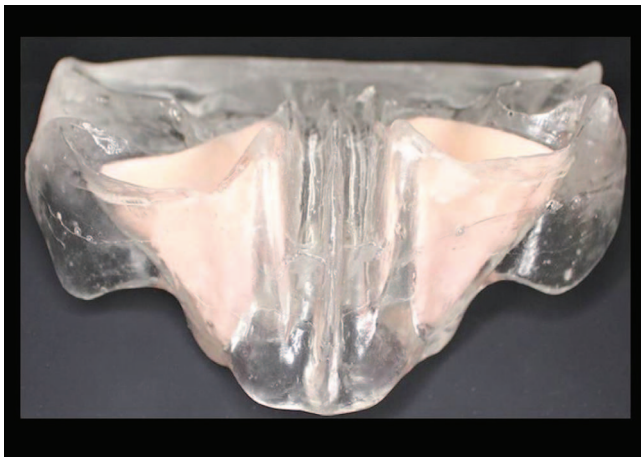

FIGURE 3. Inorganic model for training in sinus lift techniques.

### DISCUSSION

The need to develop surgical skills, as well as to use in vivo material and/or novel techniques, makes animal models essential teaching tools.<sup>5,10,12,13</sup>

However, inorganic models specifically designed for the development of surgical skills present an alternative to animal models. Among them, there are models specifically designed for training in sinus lifts (Figure 3).

These inorganic models provide better visibility of the target structures, which are presented in schematic form in addition to the lifelike 3D view, thus greatly facilitating the recognition of these structures and simplifying the surgical procedure. This can be seen as an advantage and disadvantage, since while it does simplify the task, it places the training simulation in a context that deviates from the true surgical environment and does not properly show the biologic reality of the situation in which a multitude of anatomic structures are clustered within a very small working space, with severely reduced visibility. As such, we believe that while inorganic models can be of great service, especially in the initial stages of the learning process, they must be supplemented with animal models in order to situate the training process within a biological environment that much more closely mirrors the reality of daily practice.<sup>14,15,16</sup>

Pearce et al<sup>17</sup> compared pigs, lambs, goats, dogs, and rabbits as models for testing implant integration and determined that from among these animals, dogs had the most similar physiology to the human one.

From studies such as those by Hanisch et al<sup>18</sup> and Kirker-Head et al,<sup>10</sup> we know that primates have the closest similarities to humans. The clinical study by Hanisch et al<sup>18</sup> examined healthy adult cynomolgus monkeys (*Macaca fascicularis*), which are non-hominid primates. However, the use of these animals for experiments is regulated very strictly, making access to primates very difficult. Additionally, obtaining and maintaining these animals is very costly.<sup>10,18</sup>

Wang et al<sup>19</sup> pointed out the importance of the miniature pig as an animal for medical experiments, and performed a study describing the possible applications with this animal

model and made anatomic comparisons with other species. This study affirmed that the maxillofacial region of the miniature pig is similar to humans in terms of anatomy, development, physiology, and pathology. Similarly, the use of miniature pigs as animal models confers economic and ethical advantages over using other species such as primates or human cadavers.

Estaca et al<sup>5</sup> determined that pigs and lambs provided good study models, although the surgical approach for a sinus lift procedure is completely different from that of humans, given the need for extra-oral access.

In pigs, the maxillary sinus is between the maxillary and the zygomatic bones and consists of 2 subcavities, cranial and caudal, which tend to have a varying number of septae. There is also a nasomaxillary opening similar to the ostium in the human sinus.<sup>11</sup>

In ruminant mammals, the sinus is located between the maxilla, the zygomatic bone, and the bulla lacrimalis. These animals also have a nasal-sinus opening that connects the nasal cavities with the antral cavity.<sup>11</sup>

When discussing animal models destined for teaching purposes, one important factor to consider is the ease of obtaining and manipulating samples, along with the costs for each species, leading to a cost-benefit analysis between the different options.

Our data suggest that both lambs and pigs provide animal models with excellent cost-benefit ratios as teaching material for the surgical technique of sinus lift. It also suggests that, between the 2 species, lambs have a greater anatomic similarity to humans when comparing the maxillary sinus, with a classification of "similar," whereas pigs were classified as "somewhat similar."

Pigs had a lower quantitative similarity to humans than lambs (only 1 significantly different measurement for lambs compared to 2 for pigs). Furthermore, the categories in which these differences occurred were of qualitative importance, such as the window area CW in our study (a measurement that is of capital importance when preparing a training model for practicing the sinus lift window), in which pigs were significantly different from humans, whereas lambs were not. As such, there is an important qualitative difference between these 2 animals when comparing them for use as training models.

In addition, if we compare pigs against lambs, lambs are much easier to manage because of their smaller size, compared to the large and heavy head of pigs.

### CONCLUSION

Based on our results, from among the possible choices that are easily accessible, lambs appear to be the animal model of choice to train students in the sinus lift technique because of the anatomic similarity to humans.

Further studies should include other animal species with a greater theoretical similarity to humans, such as primates, in order to quantify the benefit of using these animal models against the previously mentioned drawbacks in their use for training purposes.

## ABBREVIATIONS

APL: anteroposterior sinus length  
 ASx: anterior maxillary sinus  
 CaSx: caudal maxillary sinus  
 CaWsx: caudal maxillary sinus, window area  
 CCH: cranial-caudal sinus height  
 CCHW: cranial-caudal sinus height in window area  
 CoSx: width of the cortical bone at the lateral wall of the sinus, in the window area  
 CoWsx: external cortical, window area  
 CrSx: cranial maxillary sinus  
 CrWsx: cranial maxillary sinus, window area  
 CW: cortical width  
 DFOP: distance from the floor of the sinus to the occlusal plane  
 LSx: lateral maxillary sinus  
 MLW: medial-lateral sinus width  
 MSx: medial maxillary sinus  
 PoWsx: occlusal plane sinus, window area  
 PSx: posterior maxillary sinus  
 Wsx: maxillary sinus window

## REFERENCES

- Misch CE. Maxillary sinus augmentation for endosteal implants: organized alternative treatment plans. *Int J Oral Implantol*. 1987;4:49–58.
- Boyne PJ, James RA. Grafting of the maxillary sinus floor with autogenous marrow and bone. *J Oral Surg*. 1980;38:613–616.
- Tatum H Jr. Maxillary and sinus implant reconstructions. *Dent Clin North Am*. 1986;30:207–229.
- Troedhan AC, Kurrek A, Wainwright M, Jank S. Hydrodynamic ultrasonic sinus floor elevation—an experimental study in sheep. *J Oral Maxillofac Surg*. 2010;68:1125–1130.
- Estaca E, Cabezas J, Usón J, Sánchez-Margallo F, Morell E, Latorre R. Maxillary sinus-floor elevation: an animal model. *Clin Oral Implants Res*. 2008;19:1044–1048.
- Jakse N, Tangl S, Gilli R, et al. Influence of PRP on autogenous sinus grafts. An experimental study on sheep. *Clin Oral Implants Res*. 2003;14:578–583.
- Riecke B, Heiland M, Hothan A, Morlock M, Amling M, Blake FA. Primary implant stability after maxillary sinus augmentation with autogenous mesenchymal stem cells: a biomechanical evaluation in rabbits. *Clin Oral Implants Res*. 2011;22:1242–1246.
- Watanabe K, Niimi A, Ueda M. Autogenous bone grafts in the rabbit maxillary sinus. *Oral Surg Oral Med Oral Pathol Oral Radiol Endod*. 1999;88:26–32.
- Bravetti P, Membre H, Marchal L, Jankowski R. Histologic changes in the sinus membrane after maxillary sinus augmentation in goats. *J Oral Maxillofac Surg*. 1998;56:1170–1176.
- Kirker-Head CA, Nevins M, Palmer R, Nevins ML, Schelling SH. A new animal model for maxillary sinus floor augmentation: evaluation parameters. *Int J Oral Maxillofac Implants*. 1997;12:403–411.
- Schummer A, Nickel R, Seiferle E. *The Viscera of the Domestic Mammals*. 2nd ed. Berlin, Germany: Verlag Paul Parey; 1978:88–92.
- Kim HJ, Yoon HR, Kim KD, et al. Personal-computer-based three-dimensional reconstruction and simulation of maxillary sinus. *Surg Radiol Anat*. 2003;24:393–399.
- Troedhan AC, Kurrek A, Wainwright M, Jank S. Hydrodynamic ultrasonic sinus floor elevation—an experimental study in sheep. *J Oral Maxillofac Surg*. 2010;68:1125–1130.
- Seoane J, López-Niño J, Tomás I, González-Mosquera A, Seoane-Romero J, Varela-Centelles P. Simulation for training in sinus floor elevation: new surgical bench model. *Med Oral Patol Oral Cir Bucal*. 2012;17:e605–e609.
- Ghiabi E, Taylor KL. Teaching methods and surgical training in North American graduate periodontics programs: exploring the landscape. *J Dent Educ*. 2010;74:618–627.
- Gargallo JU, Rubio EA, Pérez JL, Torres-Lagares D, Vázquez CC. New dental simulator for microsurgical training preliminary overview. *Med Oral Patol Oral Cir Bucal*. 2007;11:E582–E584.
- Pearce AI, Richards RG, Milz S, Schneider E, Pearce SG. Animal models for implant biomaterial research in bone: a review. *Eur Cell Mater*. 2007;13:1–10.
- Hanisch O, Tatakis DN, Rohrer MD, Wöhrle PS, Wozney JM, Wikesjö UM. Bone formation and osseointegration stimulated by rhBMP-2 following subantral augmentation procedures in nonhuman primates. *Int J Oral Maxillofac Implants*. 1997;12:785–792.
- Wang S, Liu Y, Fang D, Shi S. The miniature pig: a useful large animal model for dental and orofacial research. *Oral Dis*. 2007;13:530–537.