

Comprehensive Comparison of the 5-Year Results of All-on-4 Mandibular Implant Systems With Acrylic and Ceramic Suprastructures

Mustafa Ayna, DDS, MSc, PhD^{1*}
 Aydin Gülses, DDS, PhD²
 Yahya Açil, Prof Dr³

The objective of the present study was to evaluate the comprehensive 5-year results of fixed mandibular dentures fabricated from metal-acrylic or metal-ceramics according to the All-on-4 protocol. Twenty-seven patients who received immediately loaded All-on-4 fixed mandibular dentures in 2006 were included in the study, and they were evaluated up to 5 years after denture integration. Endpoints were chosen in accordance with the 2007 Pisa consensus and included bone resorption, the Oral Health Impact Profile (OHIP), the sulcus fluid flow rate (SFFR), and prosthodontic complications. The initial situation in both groups was largely identical. Bone loss remained under 2 mm after 5 years in all implants and showed no group difference. The SFFR showed a gradual increase in both groups, and acrylic-bearing implants showed a substantially and significantly higher flow rate from the third year onward. The subjective improvement as expressed by the OHIP score was immediate and dramatic, and it showed no group differences. All acrylic restorations showed some extent of abrasion, and veneer fractures occurred in 4 patients (28.6%). Besides a single fracture of a fixation screw, there were no prosthetic complications in patients with ceramic suprastructures. According to bone loss and subjective outcome, acrylic and ceramic suprastructures appeared to be equivalent after 5 years; however, sulcus flow and prosthodontic complications suggest that the economic advantage of acrylic dentures may be specious. The rational choice of implant suprastructures requires comprehensive, long-term observation. Short-term economic benefits might be cancelled out in the long term.

Key Words: dental implants, immediate loading, mandible; fixed denture, treatment outcome

INTRODUCTION

Dental implants have evolved into an established and routinely performed modality for the replacement of missing teeth, and the published results suggest an almost flawless outcome in terms of esthetics and function.¹⁻³

However, the available evidence for the real-world success rate of implant-based reconstructions is inadequate,⁴ especially in the assessment of long-term functional and esthetic survival. Moreover, it is no longer meaningful to draw conclusions from uncomplicated clinical cases (eg, mandibular single-tooth replacement in a healthy, young nonsmoker) and apply them to more complex initial situations.

One such situation is the implant-based integration of fixed dentures, an emerging modality for the rehabilitation of edentulous arches with promising long-term results.⁵⁻⁷ There

are a multitude of surgical and prosthodontic concepts for this modality, employing different numbers of implants (2, 4, or 6), implant inclinations and suprastructures, and there is currently no generally accepted guideline as to the best choice of methods. A very important prognostic criterion for implant-based fixed dentures is the angular and geometric accuracy of the suprastructure; if this fails, nonphysiologic load transmission into the bone occurs, and the bone-implant interface can be seriously and ultimately fatally compromised.⁸⁻¹⁰

Contemporary success criteria for dental implants include pain or discomfort, mobility, bone loss, and exudation. Therefore, the inclusion of pertinent objective outcome parameters is a paramount prerequisite for valid follow-up studies of dental implants.¹¹

Bone loss—a crucial factor for long-term implant success—is a time-dependent process, and it therefore requires an extended observation period to be reliably implemented as a criterion for implant success.^{5,12-14} The most current definition of “success” in terms of bone loss is “less than 2 mm loss since implant insertion”¹¹; obviously, the fulfillment of this criterion is much easier when the implant is in situ for less than 1 year, which is the case in the majority of outcome studies in implantology. For short-term trials, the success criterion according to Albrektsson and Zarb,¹⁵ which is less than 0.2 mm per year, is more meaningful. Substantial disagreement

¹ Private practice in general dentistry and implantology, Duisburg-Zentrum, Germany.

² Center for Dentistry and Oral Health, Mevki Military Hospital, Ankara, Turkey.

³ Department of Oral and Maxillofacial Surgery, Christian-Albrechts-University, Kiel, Germany.

* Corresponding author, e-mail: praxis@dr-ayna.de

DOI: 10.1563/AAID-JOI-D-14-00016

notwithstanding, an observation period of 5 or more years is desirable for an outcome assessment that complies with the contemporary success criteria,¹⁶ and indeed the 2007 Pisa consensus¹¹ is the more strict outcome measurement from 10 years of observation onwards.

A relatively recent development for the rehabilitation of edentulous arches with immediate loading is the All-on-4 concept, originally introduced for Brånemark implants by Maló and co-workers.^{17,18} A special feature of this system is the presence of tilted distal implants; this method facilitates the preservation of critical anatomic structures (foramen mentale and sinus maxillaris) and avoids the transitional period of implant systems with delayed loading.¹⁸⁻²²

In principle, the All-on-4 concept allows for 2 different types of suprastructures, fabricated from either ceramics or acrylic. Because of the marked difference in cost (laboratory costs in Germany are approximately €1600 [acrylic] vs €5100 [ceramics]), a comparative evaluation of both methods is of major interest. In the present study, patients who received ceramics or acrylic suprastructures, respectively, were compared after an observation period of at least 5 years, employing objective and contemporary outcome criteria according to the 2007 Pisa consensus.¹¹

MATERIALS AND METHODS

Patients

Between January 1 and May 31, 2006, patients with edentulous mandibles, in whom the integration of an implant-based fixed denture was planned, were screened for participation in the trial and underwent thorough anamnesis and clinical examination. According to the medical history and records of the patients, edentulism was the main consequence of their advanced periodontal diseases. In order to participate, patients had to fulfill the following criteria:

- atrophy of the edentulous mandible with the rehabilitation option of All-on-4 concept;
- opposing natural dentition or implant-based prosthesis;
- an interforaminal bone width ≥ 5 mm, and bone height ≥ 8 mm; and
- completely healed, at least 6 months postextraction socket(s).

The exclusion criteria were as follows:

- general systemic contraindications against implant surgery (psychiatric disorders, pregnancy, metabolic bone diseases, etc);
- the presence of systemic diseases that may jeopardize the success of implant integration (uncontrolled diabetes, osteoporosis, etc);
- the use of drugs that may negatively affect the osseointegration process (bisphosphonates, corticosteroids, etc);
- active inflammation or neighboring pathologies in the areas intended for implant placement;
- radiation therapy to the head and/or neck region in the preceding 12 months;
- requirement of bone augmentation during implant placement;

- clinically significant parafunctions; and
- poor oral hygiene and/or compliance.

Eligible patients were informed orally and in writing about the goals and the duration of the study (observation period of 5 years) and the pertinent risks and benefits of the procedure and of the respective suprastructures. After receiving this information, 29 patients, receiving a total of 116 implants, declared written informed consent to participate.

The patients were assigned to the different suprastructure groups (ceramics/acrylic) according to their own choice after comprehensive informed consent; the main decision criterion was the substantial difference in price.

Surgical methods

All patients received 4 Nobel Speedy implants according to the All-on-4 protocol¹⁷⁻¹⁹ and the implant manufacturer's guidelines in terms of angulation of the distal implant. Implant sizes were 4×13 mm mesial and 4×15 mm distal, the longer distal implants providing bicortical anchoring. All implants were immediately loaded within 24 hours.

The implants were placed with the Elcomed SA-310 surgical unit (W&H Deutschland, Laufen, Germany). The workflow is shown in Figure 1.

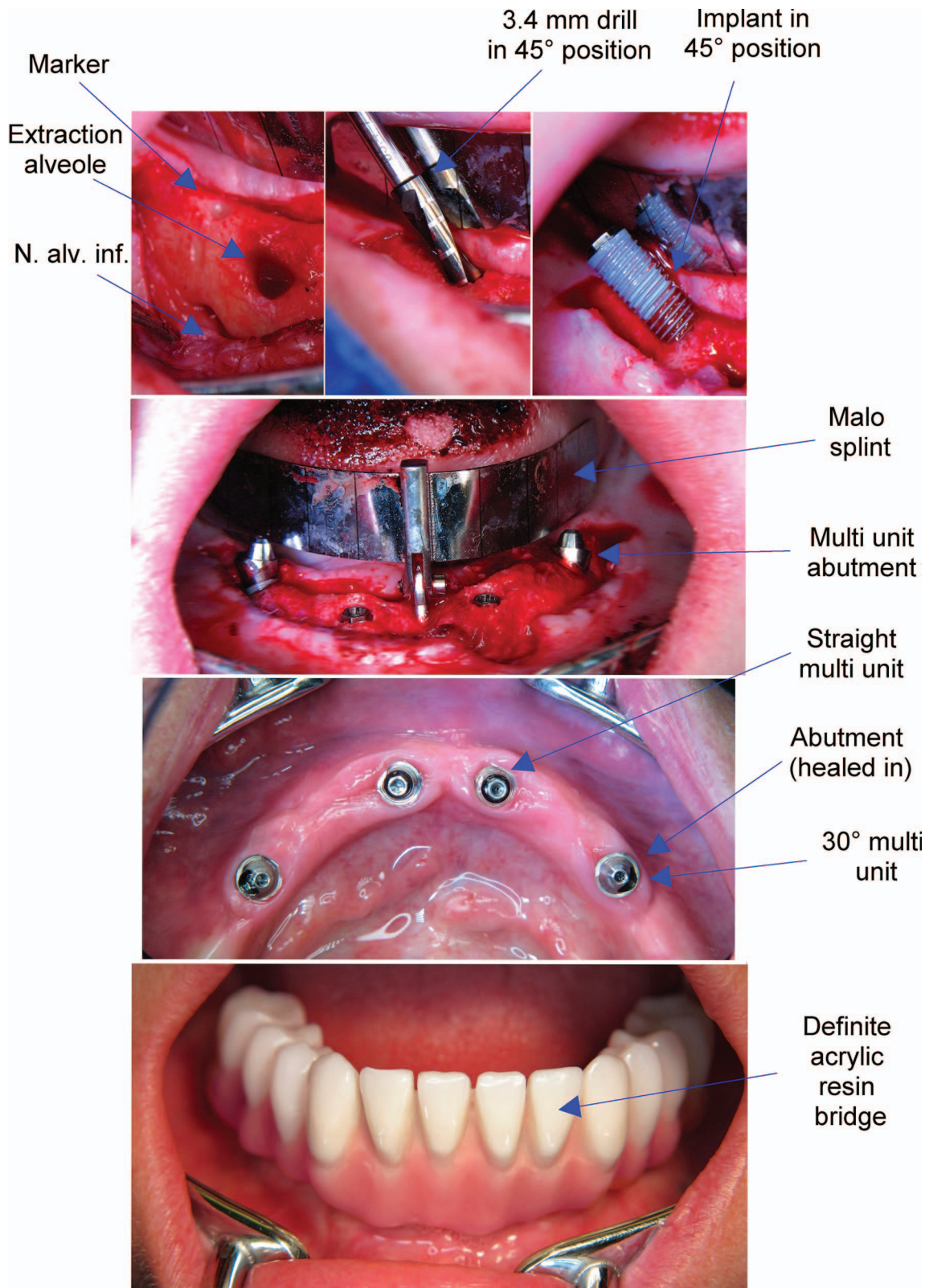
The insertion torque was slightly but significantly higher in the acrylic group in regions 32, 42, and 35 ($P < .05$). Moreover, the straight implants (region 32 and 42) were inserted with significantly less torque than the angulated implants in region 35 and 45 ($P < .0001$, Table 1). The manufacturer-recommended threshold of 35 N was met or exceeded in all implants (Table 1).

All procedures were performed by the same dental surgeon (M.A.) under local anesthesia. After a meticulous examination, all patients received careful oral hygiene instructions and a professional tooth cleaning before the actual surgery.

Outcome parameters

Reassessments were performed over a total observation period of 5 years after surgery. These assessments included the following parameters:

- **Bone resorption:** Radiographic examinations took place immediately after implant insertion as well as after 1 and 5 years; more frequent examinations were forgone to avoid unnecessary radiation exposure. Bone crest levels around the implants were measured with a standard right-angle parallel technique, based on single digital X rays.^{23,24} The radiographs were scanned at 600 dpi (Trophy RVG UI USB Sensor, KODAK 5.0 software, Carestream, Stuttgart, Germany), and image analysis software was used to assess bone level (UTHSCSA Image Tool version 3.00 for Windows, University of Texas Health Science Center, San Antonio, Tex) (Figure 2). The software was calibrated for every image using the length and diameter of the implant as the known distance; the linear distance between implant neck and the most coronal bone-to-implant contact at the mesial and distal aspect was measured for each implant, and bone loss was calculated using the bone level immediately after implantation as the reference.



Downloaded from <http://meridian.allenpress.com/joi/article-pdf/41/6/675/2040287/aaid-joi-d-14-00016.pdf> by guest on 30 April 2025

FIGURE 1. Workflow. Socket preparation and implant insertion (above), situs with inserted implants (center above), abutments after healing-in (center below), and integrated suprastructure (below).

TABLE 1
Demographics and baseline data

Criterion	Total	Acrylic Resin	Ceramics
Patients, n (%)	27	14 (51.9)	13 (48.1)
Male/female, n (%)	8/19 (29.6/70.4)	4/10 (28.6/71.4)	4/9 (30.8/69.2)
Age, y†	43–77 (64.4 ± 10.8)	43–72 (56.4 ± 8.8)**	64–77 (73.0 ± 3.9)**
Smoking status, n (%)			
Non-smoker	25 (92.6)	13 (92.9)	12 (92.3)
Smoker	2 (7.4)	1 (7.1)	1 (7.7)
Bruxism, n (%)			
No bruxism	25 (92.6)	12 (85.7)	13 (100.0)
Bruxism	2 (7.4)	2 (14.3)	
Insertion torque, N†	***	***	***
Region 32	40–58 (50.3 ± 4.0)	40–58 (51.4 ± 5.1)*	45–52 (49.1 ± 1.8)*
Region 42	44–57 (51.3 ± 4.0)	44–57 (52.6 ± 4.6)*	45–55 (49.8 ± 2.8)*
Region 35	64–80 (68.9 ± 3.3)	65–80 (70.6 ± 3.6)*	64–69 (67.2 ± 1.7)*
Region 45	64–76 (69.0 ± 3.0)	64–76 (70.0 ± 3.7)	65–70 (68.1 ± 1.7)

†Range (mean ± SD), group comparisons: *P < .05 and **P < .01, comparison of region 32 vs 35 and 42 vs 45, ***P < .0001.

- *Occlusal forces*: Pressure-sensitive film and the appendant software (Dental Prescale 50H type R and Software FDP-8018E, Fuji Photo Film Co, Tokyo, Japan) were used to measure and evaluate occlusal forces. The occlusal force measurements were performed before implantation with the conventional dentures, 1 week after integration of the immediate bridge, 1 week after integration of the definite bridge, and upon final follow-up after 5 years.
- *Oral Health Impact Profile (OHIP)*: The impact of the reconstruction on quality of life was assessed with the OHIP,²⁵ a very common instrument for the assessment of subjective treatment outcome in dentistry, particularly for implant-based fixed dentures.^{26–29} In the present study, the German version of the OHIP 14³⁰ was employed before surgery, immediately after implantation, 6 months after denture integration, and 5 years after denture integration. The OHIP addresses 14 items in 7 domains (functional limitation, physical pain, psychological discomfort, physical disability, psychological disability, social disability, and

- handicap) with a 5-point verbal rating scale ranging from “never” (coded 0) to “very often” (coded 4). Therefore, low point scores represent a high quality of life.
- *Periodontal probing depth (PPD) and bleeding on probing (BOP)*: A full-mouth examination (UNC-15 periodontal probe, Hu-Friedy, Rotterdam, Netherlands) was conducted, and PPD and BOP were assessed according to established standard procedures. PPD was measured in mm at 6 peri-implant sites (mesiobuccal, buccal, distobuccal, mesiolingual, lingual, and distolingual), and bleeding was recorded at 4r sites (buccal, mesial, lingual, and distal). The deepest pocket was employed for analysis, and any bleeding on probing was recorded as “yes.”
- *Sulcus fluid flow rate (SFFR)*: The SFFR measured with the Periotron (Oraflow Inc, New York, NY) was used to quantify the peri-implant tissue reaction as expressed by exudation 1, 2, 3, 4, and 5 years after implant insertion.³¹ Two strips were employed for each implant, and 2 experienced investigators were calibrated prior to the actual assessment. The validity

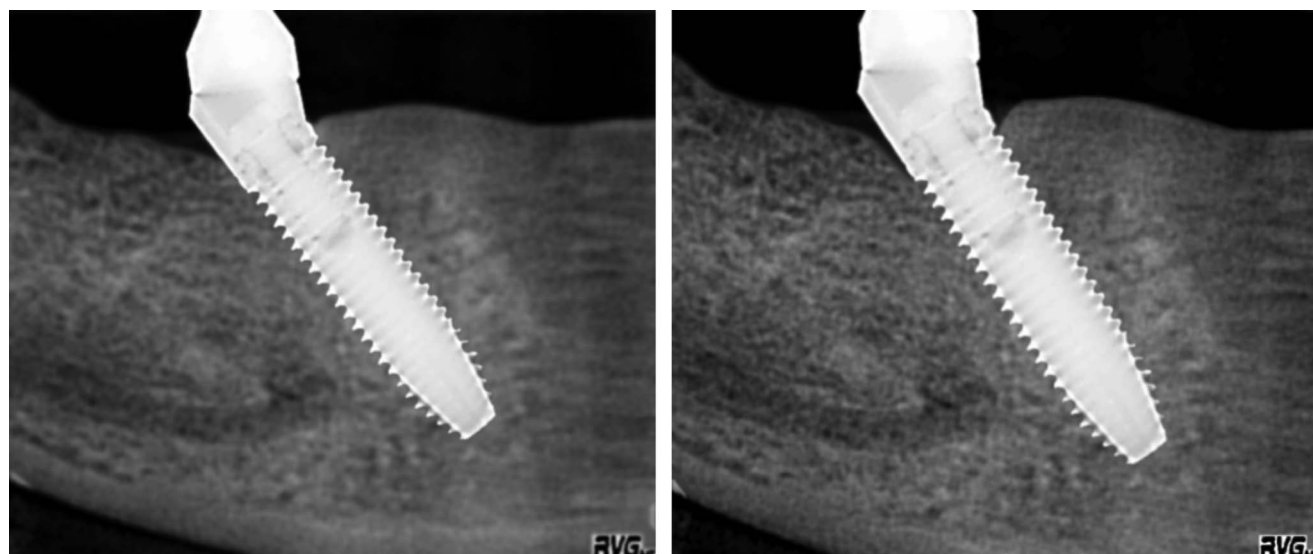


FIGURE 2. Bone loss measurement.

TABLE 2

Criterion	Peri-implant bone loss (mm) after 1 and 5 years of function†		
	Total	Acrylic Resin	Ceramics
Bone loss in region 32	*	*	*
After 1 y	0.2–0.7 (0.47 ± 0.14)	0.3–0.7 (0.51 ± 0.12)	0.2–0.7 (0.42 ± 0.14)
After 5 y	0.5–1.0 (0.78 ± 0.10)	0.7–1.0 (0.81 ± 0.09)	0.5–0.9 (0.75 ± 0.11)
Bone loss in region 35	*	*	*
After 1 y	0.7–1.1 (0.89 ± 0.11)	0.8–1.0 (0.88 ± 0.07)	0.7–1.1 (0.89 ± 0.15)
After 5 y	1.0–1.5 (1.24 ± 0.13)	1.0–1.5 (1.26 ± 0.13)	1.1–1.5 (1.23 ± 0.13)
Bone loss in region 42	*	*	*
After 1 y	0.2–0.7 (0.52 ± 0.11)	0.4–0.7 (0.51 ± 0.09)	0.2–0.7 (0.52 ± 0.14)
After 5 y	0.6–0.9 (0.78 ± 0.10)	0.6–0.9 (0.80 ± 0.11)	0.6–0.9 (0.76 ± 0.10)
Bone loss in region 45	*	*	*
After 1 y	0.7–1.2 (0.93 ± 0.13)	0.7–1.1 (0.90 ± 0.13)	0.8–1.2 (0.95 ± 0.13)
After 5 y	1.1–1.5 (1.30 ± 0.13)	1.1–1.5 (1.29 ± 0.14)	1.1–1.5 (1.31 ± 0.11)

†Comparison of region 32 vs 35 and 42 vs 45 after 1 and 5 years.

* $P < .0001$.

of the SFFR as a sign of periodontal inflammation has been established elsewhere.³²

Statistical analysis

Data were analyzed with the software package STATISTICA (StatSoft Inc, Tulsa, Okla), employing nonparametric methods (Wilcoxon test for differences over time, Mann-Whitney U test for group differences, χ^2 test for discrete parameters); the level of significance was set at $P < .05$. Group comparisons were performed employing implants/implant sites and patients as the sample population where appropriate, respectively.

RESULTS

Two patients were lost to follow-up during the observation period due to relocation and were excluded from the analysis.

A total of 27 patients who were 43–77 years of age (mean: 64.4 ± 10.8 years), and predominantly female (70.4%) enrolled in the study. Only 2 subjects (7.5%) were smokers (Table 1). Patients choosing acrylic suprastructures were significantly younger (56.4 ± 8.8 vs 73.0 ± 3.9 years; $P = .0076$); other than that, there were no significant differences between patients receiving acrylic or ceramics suprastructures, with regard to demographics and baseline data (Table 1).

The smoking status in both groups was identical. Two patients reported and/or showed clinical signs of bruxism; both of these patients received acrylic suprastructures. The difference in insertion torque between patients with acrylic and ceramic suprastructures (Table 1) is clinically irrelevant; it may express a somewhat lower bone density in the substantially older subjects who received ceramic suprastructures.

The development of bone loss (compared to the bone level measured immediately after implant insertion) in both groups is shown in Table 2. Bone loss showed a uniform, albeit slight, progression during observation (the maximum value after 1 year was approximately equivalent to the minimum after 5 years), and it remained well within the limits for "success" according to the 2007 Pisa consensus¹¹ (<2 mm) for up to 5 years. Bone loss was significantly more pronounced around the

distal implants (regions 35 and 45), with the differences amounting to a factor of 2–3 ($P < .0001$ throughout). There were no appreciable or significant group differences.

Occlusal force improved dramatically (by almost a factor of 2) in both groups, and for the most part, this change occurred immediately after loading. Whereas a group difference was nonexistent before and immediately after loading, an increasing difference in favor of ceramic suprastructures began to evolve from 3 months onward, reaching statistical significance after 5 years (Figure 3).

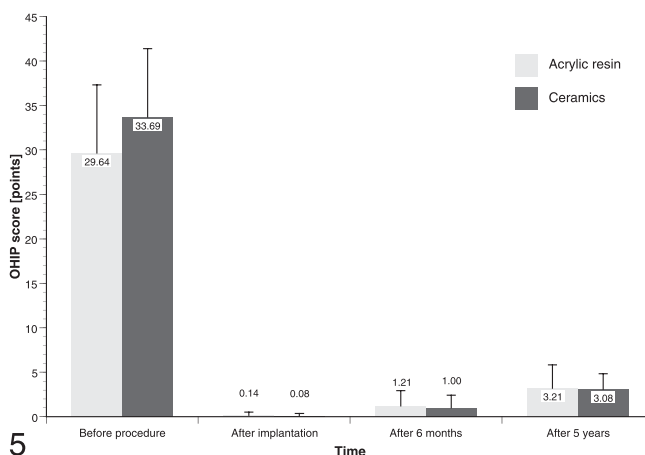
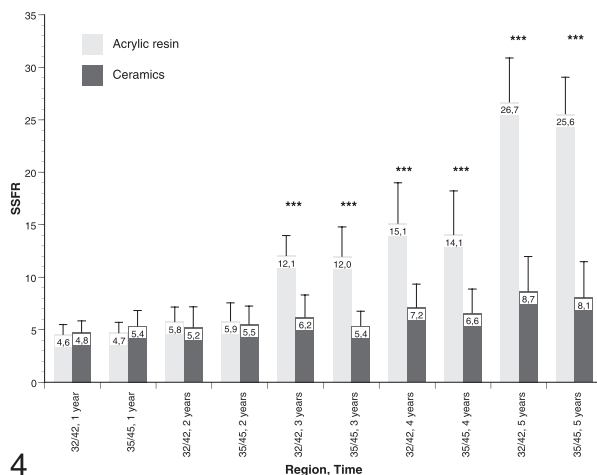
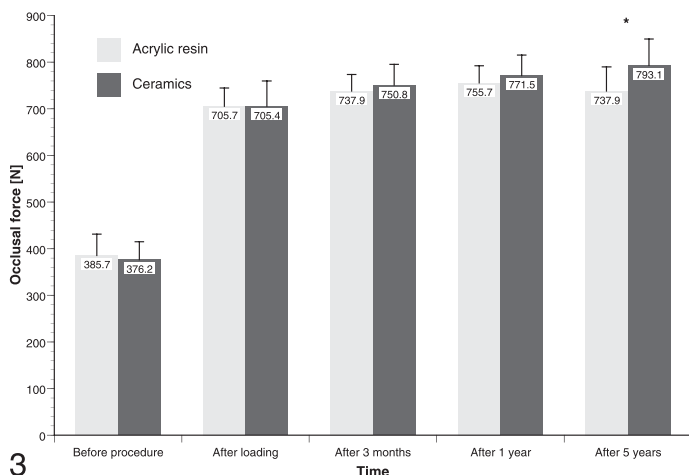
All in all, the peri-implant soft tissues showed some degree of degradation during observation. The PPD increased consistently and significantly over time in both groups; initially, pockets were between 2 mm (mesial regions) and 2.5 mm (distal regions deep), and approximately 1 further millimeter was gained during observation. There was a tendency toward shallower pockets at ceramics suprastructures, albeit mostly not significant. The BOP findings were less consistent, but also in agreement with a slight deterioration over time (Table 3).

The SFFR showed a gradual increase in both groups from the first year onward. Whereas this tendency continued throughout the observation period around implants that bore ceramic suprastructures, there was a substantial shift (approximately a factor of 2) around acrylic-bearing implants after 3 years of function, and a second, equivalent shift occurred after 5 years. The difference between ceramic- and acrylic-bearing implants was highly significant from the third year onward (Figure 4).

There was no meaningful statistical correlation between periodontal soft tissue characteristics and bone loss.

The subjective improvement as expressed by the OHIP score was dramatic. An initially substantial impairment (approximately 30 out of a maximum of 56 points, suggesting an intermediate burden) was practically cancelled after denture integration, and the score increased only slightly during observation. There were no differences between patients with acrylic and ceramic dentures (Figure 5).

All acrylic restorations showed some extent of abrasion that was, however, neither esthetically nor functionally relevant. Even though sufficient material strength had been assured by backward planning, veneer fractures occurred in 4 patients, all with acrylic suprastructures (28.6%). Three of those fractures (all



FIGURES 3–5. FIGURE 3. Occlusal force in both groups during the observation period ($*P < .05$). **FIGURE 4.** Sulcus fluid flow rate in both groups during the observation period ($***P < .0001$). **FIGURE 5.** Oral Health Impact Profile score in both groups during the observation period (no significant differences).

on canine teeth) were superficial and could be repaired in situ; only one reached the metal framework, and the denture had to be removed and repaired in the laboratory.

Besides a single loosening of a fixation screw, there were no prosthetic complications in patients with ceramic suprastructures.

DISCUSSION

The results of the present trial provide convincing long-term proof of concept for the All-on-4 method of fixed mandibular denture integration, support an emerging body of evidence,^{17,18,20,22} and corroborate the encouraging results of immediate loading fixed denture treatment concepts.^{33–36} There was an immediate and sustainable restoration of overall bite force due to denture integration, and the subjective relief of a previously substantial burden imposed by wearing a mucosa-based denture was instantaneous and complete. The advanced criteria for “success,” including bone resorption and exudation,¹¹ were fulfilled throughout the sample after 5 years of observation. Bone loss was more pronounced around the distal, angulated implants, but the threshold for “success” (<2 mm) was met, with

a minimum margin of 0.5 mm, by all implants. Considering bone loss, occlusal force, and OHIP, there were no appreciable or significant differences, with the exception of the occlusal force after 5 years, which favored ceramic dentures.

In principle, this study confirms the higher incidence of prosthodontic complications in metal-acrylic as opposed to metal-ceramic fixed dentures, as reported by Bozini et al.⁶ However, after 5 years, the resulting problems were well manageable and would not have convincingly outweighed the undisputable economic advantage of the acrylic restorations.

There is, however, one crucial and marked difference between the prosthodontic constructions under scrutiny. After 3 years of function and onward, the exudation around acrylic-bearing implants was orders of magnitude more pronounced than around ceramic-bearing implants. This is not a consequence of denture design; after an initial prototype was constructed and refined for cleansability, the design of the All-on-4 dentures was not altered during the observation period unless fractures occurred.

The sulcus flow rate is a meaningful parameter for the preservation of peri-implant soft tissues,³¹ and its results are in agreement with other soft tissue criteria such as PPD; thus, this finding raises concern about the further development of the

TABLE 3

Periodontal pocket depth (PPD, mm) and bleeding on probing (BOP, % of sites with bleeding) during observation†

Criterion	Total	Acrylic Resin	Ceramics
PPD in region 32	****	****	****
After 1 y	1.0–2.5 (1.94 ± 0.35)	1.0–2.5 (1.93 ± 0.33)	1.0–2.5 (1.96 ± 0.38)
After 2 y	1.0–2.5 (2.02 ± 0.35)	1.5–2.5 (2.00 ± 0.34)	1.0–2.5 (2.04 ± 0.38)
After 3 y	1.0–2.5 (2.15 ± 0.36)	1.5–2.5 (2.18 ± 0.32)	1.0–2.5 (2.12 ± 0.42)
After 4 y	1.5–3.0 (2.37 ± 0.33)	2.0–3.0 (2.46 ± 0.31)	1.5–2.5 (2.27 ± 0.33)
After 5 y*	1.5–3.5 (2.69 ± 0.42)	2.5–3.5 (2.86 ± 0.41)	1.5–3.0 (2.50 ± 0.35)
PPD in region 42	****	****	****
After 1 y	1.0–3.5 (2.13 ± 0.53)	1.0–3.5 (2.14 ± 0.63)	1.0–2.5 (2.12 ± 0.42)
After 2 y	1.0–3.5 (2.15 ± 0.53)	1.0–3.5 (2.18 ± 0.64)	1.0–2.5 (2.12 ± 0.42)
After 3 y	1.5–4.0 (2.31 ± 0.52)	1.5–4.0 (2.39 ± 0.63)	1.5–3.0 (2.23 ± 0.39)
After 4 y*	1.5–6.5 (2.59 ± 0.92)	1.5–6.5 (2.89 ± 1.16)	1.5–3.0 (2.27 ± 0.39)
After 5 y**	2.0–4.0 (2.73 ± 0.51)	2.0–4.0 (2.96 ± 0.56)	2.0–3.0 (2.50 ± 0.35)
PPD in region 35	****	****	****
After 1 y	1.5–3.5 (2.41 ± 0.44)	2.0–3.5 (2.43 ± 0.39)	1.5–3.0 (2.38 ± 0.51)
After 2 y	2.0–3.5 (2.43 ± 0.41)	2.0–3.5 (2.43 ± 0.39)	2.0–3.0 (2.42 ± 0.45)
After 3 y	2.0–3.5 (2.67 ± 0.37)	2.0–3.5 (2.64 ± 0.36)	2.0–3.0 (2.69 ± 0.38)
After 4 y	2.5–3.5 (3.06 ± 0.32)	2.5–3.5 (3.04 ± 0.31)	2.5–3.5 (3.08 ± 0.34)
After 5 y	2.5–4.0 (3.43 ± 0.41)	3.0–4.0 (3.50 ± 0.39)	2.5–4.0 (3.35 ± 0.43)
PPD in region 45	****	****	****
After 1 y	2.0–3.5 (2.43 ± 0.41)	2.0–3.5 (2.39 ± 0.40)	2.0–3.0 (2.46 ± 0.43)
After 2 y	2.0–4.0 (2.48 ± 0.49)	2.0–4.0 (2.46 ± 0.54)	2.0–3.0 (2.50 ± 0.46)
After 3 y	2.0–4.0 (2.70 ± 0.40)	2.0–4.0 (2.68 ± 0.46)	2.0–3.0 (2.73 ± 0.33)
After 4 y	2.5–4.0 (3.20 ± 0.42)	2.5–4.0 (3.32 ± 0.50)	2.5–3.5 (3.08 ± 0.28)
After 5 y**	3.5–4.5 (3.56 ± 0.47)	3.0–4.5 (3.75 ± 0.51)	3.0–4.0 (3.35 ± 0.32)
BOP in region 32			
After 1 y	7.41%	7.14%	7.69%
After 2 y	7.41%	14.29%	0.00%
After 3 y	22.22%	28.57%	15.38%
After 4 y	14.81%	7.14%	23.08%
After 5 y	25.93%	35.71%	15.38%
BOP in region 42			
After 1 y	11.11%	7.14%	15.38%
After 2 y	7.41%	7.14%	7.69%
After 3 y	14.81%	14.39%	15.38%
After 4 y	25.93%	28.57%	23.08%
After 5 y	14.81%	14.29%	15.38%
BOP in region 35		***	
After 1 y	3.70%	0.00%	7.69%
After 2 y	25.93%	21.43%	30.77%
After 3 y	22.22%	35.71%	7.69%
After 4 y	25.93%	28.57%	23.08%
After 5 y	40.74%	42.86%	38.46%
BOP in region 45			
After 1 y	14.81%	14.29%	15.38%
After 2 y	7.41%	7.14%	7.69%
After 3 y	18.52%	21.43%	15.38%
After 4 y*	14.81%	28.57%	0.00%
After 5 y*	25.93%	42.86%	7.69%

†Comparison of acrylic resin and ceramics superstructures: * $P < .1$; ** $P < .05$. Increase over time: *** $P < .1$; **** $P < .0001$.

bone-implant interface in patients with metal-acrylic restorations. A substantial body of evidence suggests that an increased sulcus flow rate leads to the degradation of the peri-implant bone,³⁷ with the ultimate consequence of peri-implantitis and implant loss. Consequently, the evaluation of sulcus flow rate may be considered to be a state-of-the-art component of implant-based denture evaluation.^{38–40}

A multitude of methods are available for the quantification of sulcus flow rate, and obviously, the validity of the employed method needs to be questioned when far-reaching conclusions are being drawn from its results. The SFFR is mainly employed

in Germany, but it is an established method for peri-implant tissue assessment.^{32,41,42} The underlying principle is fairly simple, as with most other methods, and it is based on the application of standard paper strips. Even though validation studies for the SFFR are largely absent, it nevertheless can be considered a valid assessment method. Moreover, the pertinent group differences are so striking that even the most meticulous methodical consideration will hardly result in their omission. Therefore, this study clearly shows a difference in exudation between the types of suprastructures and hence underlines the necessity of comprehensive long-term observation.

A 2-year observation period, considered to be “long-term” in the bulk of implantology literature, would have indicated a lack of difference between the acrylic and ceramic restorations and therefore more than likely would result in a recommendation of the former due to economic advantages. The same holds true for a 5-year observation that would have included bone resorption, but not exudation, as an endpoint. It will certainly be interesting to follow our sample for another 5 years to evaluate the eventual structural consequences of increased exudation in patients with acrylic dentures; until then, the results command caution with respect to their recommendation.

In earlier research, acrylic and ceramic suprastructures showed comparable short-term performance in animal models⁴³ and in clinical applications⁴⁴; however, the published evidence is sparse, and to our knowledge, no comparative study has yet evaluated bone loss and exudation after 5 (or more) years in function.

The hallmark result of the present study is the increased exudation around implants that bore metal-acrylic as compared to metal-ceramic dentures. The literature provides ample evidence for 2 pivotal facts that allow for preliminary conclusions in favor of ceramic suprastructures:

- Acrylic restorations have a higher surface roughness and a greater affinity for biofilm formation, with the consequence of increased exudation in periodontal or peri-implant soft tissues.^{45,46}
- Peri-implant exudation is a sign of soft-tissue inflammation³² and has been statistically correlated with the amount of bone resorption around implants.³⁷

Therefore, the apparent lack of group differences in terms of bite force, subjective assessment, and (for the most part) alveolar bone preservation may be specious. In conclusion, the higher rate of prosthodontic complications, in combination with markedly increased exudation, commands caution with respect to the recommendation of acrylic suprastructures. Since peri-implant soft tissue inflammation is the earliest precursor of bone degradation and eventual implant failure, the differences found in the present study may imply a reduction of long-term life expectancy for implants that bear acrylic suprastructures. A further significant shortcoming of acrylic suprastructures is their substantially increased susceptibility to various prosthodontic complications, such as veneer fracture and material wear, after long-term function.⁶

The present study fervently emphasizes the necessity of valid long-term observations that employ comprehensive outcome criteria and include cost-benefit analyses, allowing for evaluation according to the current consensus guidelines.¹¹ A shorter observation period and/or the omission of sulcus flow rate as an endpoint would have led to entirely different conclusions.

CONCLUSION

According to bone loss and subjective outcome, acrylic and ceramic suprastructures appeared to be equivalent after 5 years; however, sulcus flow and prosthodontic complications suggest that the economic advantage of acrylic dentures may be specious. The rational choice of implant suprastructures

requires comprehensive, long-term observation and careful cost-benefit analysis. Short-term economic benefits might be cancelled out in the long term.

ABBREVIATIONS

BOP: bleeding on probing
OHIP: Oral Health Impact Profile
PPD: periodontal probing depth
SFFR: sulcus fluid flow rate

REFERENCES

1. Esposito M, Maghaireh H, Grusovin MG, Ziounas I, Worthington HV. Interventions for replacing missing teeth: management of soft tissues for dental implants. *Cochrane Database Syst Rev*. 2012;2:CD006697.
2. Lang NP, Pun L, Lau KY, Li KY, Wong MC. A systematic review on survival and success rates of implants placed immediately into fresh extraction sockets after at least 1 year. *Clin Oral Implants Res*. 2012;23(suppl 5):39–66.
3. Meijer HJ, Stellingsma K, Meijndert L, Raghoobar GM. A new index for rating aesthetics of implant-supported single crowns and adjacent soft tissues—the Implant Crown Aesthetic Index. *Clin Oral Implants Res*. 2005;16:645–649.
4. Vere J, Joshi R. Quality assessment of randomised controlled trials of dental implant surgery and prosthodontics published from 2004 to 2008: a systematic review. *Clin Oral Implants Res*. 2011;22:1338–1345.
5. Raval N, Dahlgren S, Teiwik A, Gröndahl K. Long-term evaluation of Astra Tech and Branemark implants in patients treated with full-arch bridges. Results after 12–15 years. *Clin Oral Implants Res*. 2013;24:144–151.
6. Bozini T, Petridis H, Garefis K, Garefis P. A meta-analysis of prosthodontic complication rates of implant-supported fixed dental prostheses in edentulous patients after an observation period of at least 5 years. *Int J Oral Maxillofac Implants*. 2011;26:304–318.
7. Vajdovich I, Fazekas A. A ten-year clinical follow-up study of prosthetic rehabilitation of the edentulous lower jaw with endosteal dental implants. *J Long Term Eff Med Implants*. 1999;9:171–183.
8. Pjetursson BE, Tan K, Lang NP, Brägger U, Egger M, Zwahlen M. A systematic review of the survival and complication rates of fixed partial dentures (FPDs) after an observation period of at least 5 years. *Clin Oral Implants Res*. 2004;15:625–642.
9. Brägger U, Karoussis I, Persson R, Pjetursson B, Salvi G, Lang N. Technical and biological complications/failures with single crowns and fixed partial dentures on implants: a 10-year prospective cohort study. *Clin Oral Implants Res*. 2005;16:326–334.
10. Fu JH, Hsu YT, Wang HL. Identifying occlusal overload and how to deal with it to avoid marginal bone loss around implants. *Eur J Oral Implantol*. 2012;5(suppl):S91–S103.
11. Misch CE, Perel ML, Wang HL, et al. Implant success, survival, and failure: the International Congress of Oral Implantologists (ICOI) Pisa Consensus Conference. *Implant Dent*. 2008;17:5–15.
12. Annibaldi S, Cristalli MP, Dell’Aquila D, Bignozzi I, La Monaca G, Pilloni A. Short dental implants: a systematic review. *J Dent Res*. 2012;91:25–32.
13. Charyeva O, Altynbekov K, Zhartybaev R, Sabdanaliev A. Long-term dental implant success and survival—a clinical study after an observation period up to 6 years. *Swed Dent J*. 2012;36:1–6.
14. Ostman PO, Hellman M, Sennerby L. Ten years later. Results from a prospective single-centre clinical study on 121 oxidized (TiUnite) Branemark implants in 46 patients. *Clin Implant Dent Relat Res*. 2012;14:852–860.
15. Albrektsson T, Zarb G, Worthington P, Eriksson AR. The long-term efficacy of currently used dental implants: a review and proposed criteria of success. *Int J Oral Maxillofac Implants* 1986;1:11–25.
16. Zitzmann NU, Krastl G, Hecker H, Walter C, Weiger R. Endodontics or implants? A review of decisive criteria and guidelines for single tooth restorations and full arch reconstructions. *Int Endod J*. 2009;42:757–774.
17. Maló P, Rangert B, Nobre M. “All-on-Four” immediate-function concept with Branemark System implants for completely edentulous

- mandibles: a retrospective clinical study. *Clin Implant Dent Relat Res*. 2003;5(suppl 1):2–9.
18. Maló P, Rangert B, Nobre M. All-on-4 immediate-function concept with Branemark System implants for completely edentulous maxillae: a 1-year retrospective clinical study. *Clin Implant Dent Relat Res*. 2005;7(suppl 1):S88–S94.
19. Quantius B. Die Versorgung des zahnlosen Unterkiefers nach dem All-on-4™ Konzept. *Implantologie*. 2012;20:33–42.
20. Galindo DF, Butura CC. Immediately loaded mandibular fixed implant prostheses using the all-on-four protocol: a report of 183 consecutively treated patients with 1 year of function in definitive prostheses. *Int J Oral Maxillofac Implants*. 2012;27:628–633.
21. Antoun H, Belmon P, Cherfane P, Sitbon JM. Immediate loading of four or six implants in completely edentulous patients. *Int J Periodontics Restorative Dent*. 2012;32:e1–e9.
22. Crespi R, Vinci R, Capparé P, Romanos GE, Gherlone E. A clinical study of edentulous patients rehabilitated according to the “all on four” immediate function protocol. *Int J Oral Maxillofac Implants*. 2012;27:428–434.
23. Brägger U. Radiographic parameters for the evaluation of peri-implant tissues. *Periodontol* 2000. 1994;4:87–97.
24. Brägger U. Use of radiographs in evaluating success, stability and failure in implant dentistry. *Periodontol* 2000. 1998;17:77–88.
25. Slade GD, Spencer AJ. Development and evaluation of the Oral Health Impact Profile. *Community Dent Health*. 1994;11:3–11.
26. Borges Tde F, Mendes FA, de Oliveira TR, Gomes VL, do Prado CJ, das Neves FD. Mandibular overdentures with immediate loading: satisfaction and quality of life. *Int J Prosthodont*. 2011;24:534–539.
27. Jofre J, Castiglioni X, Lobos CA. Influence of minimally invasive implant-retained overdenture on patients’ quality of life: a randomized clinical trial. *Clin Oral Implants Res*. 2013;24:1173–1177.
28. Harris D, Höfer S, O’Boyle CA, et al. A comparison of implant-retained mandibular overdentures and conventional dentures on quality of life in edentulous patients: a randomized, prospective, within-subject controlled clinical trial. *Clin Oral Implants Res*. 2013;24:96–103.
29. Preciado A, Del Rio J, Suárez-García MJ, Montero J, Lynch CD, Castillo-Oyagüe R. Differences in impact of patient and prosthetic characteristics on oral health-related quality of life among implant-retained overdenture wearers. *J Dent*. 2012;40:857–865.
30. John MT, Miglioretti DL, LeResche L, Koepsell TD, Hujoel P, Micheelis W. German short forms of the Oral Health Impact Profile. *Community Dent Oral Epidemiol*. 2006;34:277–288.
31. Duello GV. An evidence-based protocol for immediate rehabilitation of the edentulous patient. *J Evid Based Dent Pract*. 2012;12:172–181.
32. Bhardwaj S, Prabhuji MLV. Comparative volumetric and clinical evaluation of peri-implant sulcular fluid and gingival crevicular fluid. *J Periodontal Implant Sci*. 2013;43:233–242.
33. Chiapasco M, Gatti C. Implant-retained mandibular overdentures with immediate loading: a 3- to 8-year prospective study on 328 implants. *Clin Implant Dent Relat Res*. 2003;5:29–38.
34. Gallucci GO, Doughtie CB, Hwang JW, Fiorellini JP, Weber HP. Five-year results of fixed implant-supported rehabilitations with distal cantilevers for the edentulous mandible. *Clin Oral Implants Res*. 2009;20:601–607.
35. Pieri F, Aldini NN, Fini M, Corinaldesi G. Immediate occlusal loading of immediately placed implants supporting fixed restorations in completely edentulous arches: a 1-year prospective pilot study. *J Periodontol*. 2009;80:411–421.
36. Peñarrocha M, Boronat A, Garcia B. Immediate loading of immediate mandibular implants with a full-arch fixed prosthesis: a preliminary study. *J Oral Maxillofac Surg*. 2009;67:1286–1293.
37. Schlegel KA, Karascholi T, Fenner M, Nkenke E. Clinical and radiological results after augmentation procedures—a prospective study [in German]. *Mund Kiefer Gesichtschir*. 2007;11:209–219.
38. Eitner S, Schlegel A, Emeka N, Holst S, Will J, Hamel J. Comparing bar and double-crown attachments in implant-retained prosthetic reconstruction: a follow-up investigation. *Clin Oral Implants Res*. 2008;19:530–537.
39. Salvi GE, Lang NP. Diagnostic parameters for monitoring peri-implant conditions. *Int J Oral Maxillofac Implants*. 2004;19(suppl):116–127.
40. Behneke A, Behneke N, d’Hoedt B. The longitudinal clinical effectiveness of ITI solid-screw implants in partially edentulous patients: a 5-year follow-up report. *Int J Oral Maxillofac Implants*. 2000;15:633–645.
41. Heckmann SM, Schrott A, Graef F, Wichmann MG, Weber HP. Mandibular two-implant telescopic overdentures. *Clin Oral Implants Res*. 2004;15:560–569.
42. Nothdurft F, Pospiech P. Prefabricated zirconium dioxide implant abutments for single-tooth replacement in the posterior region: evaluation of peri-implant tissues and superstructures after 12 months of function. *Clin Oral Implants Res*. 2010;21:857–865.
43. Hürzeler MB, Quiñones CR, Schüpbach P, Vlassis JM, Strub JR, Caffesse RG. Influence of the suprastructure on the peri-implant tissues in beagle dogs. *Clin Oral Implants Res*. 1995;6:139–148.
44. Hjalmarsson L, Smedberg JI, Pettersson M, Jemt T. Implant-level prostheses in the edentulous maxilla: a comparison with conventional abutment-level prostheses after 5 years of use. *Int J Prosthodont*. 2011;24:158–167.
45. Li L, Finnegan MB, Özkan S, et al. In vitro study of biofilm formation and effectiveness of antimicrobial treatment on various dental material surfaces. *Mol Oral Microbiol*. 2010;25:384–390.
46. Adamczyk E, Spiechowicz E. Plaque accumulation on crowns made of various materials. *Int J Prosthodont*. 1990;3:285–291.