

# An Alternative Method for Lateral Sinus Approach With Trepine Design Bur: A Clinical Report

Ji Suk Shim, DDS, MSD<sup>1</sup>  
 Jae Jun Ryu, DDS, PhD<sup>2</sup>  
 Jeong YoI Lee, DDS, PhD<sup>3</sup>  
 Yeon Jo Choi, DDS, PhD<sup>2</sup>  
 Sang Wan Shin, DDS, PhD<sup>3\*</sup>

## INTRODUCTION

**S**inus augmentation has a high rate of success and has become an accepted procedure before implant surgery at the posterior maxilla. However, it has a number of surgical and postsurgical complications. The most common surgical complication is Schneiderian membrane perforation, with a reported rate from 7% to 41% through lateral approach.<sup>1-5</sup> The membrane perforation is associated with postoperative complications, including bacterial invasion, swelling, bleeding, and loss of graft material.<sup>1</sup> Perforation of the membrane most frequently occurs during osteotomy for the osseous window to reach the sinus before lifting.<sup>6,7</sup> Various surgical techniques using alternative instruments have been proposed to prevent membrane perforation when performing antrostomy of vestibular cortex.

This case report describes another antrostomy technique for lateral sinus lift that minimizes the risks of membrane perforation using the specially designed surgical drills and trephine design bur.

## DESCRIPTION OF THE CASE

A 52-year-old man visited the clinic for replacing missing #14 and #15. The patient did not have any medical or surgical contraindication to implant surgery. The teeth had been extracted 5 months previously because of a periodontal problem. A radiographic analysis detected a left maxillary sinus pneumatized with a low bone height, and 5-mm height of the remaining alveolar bone. There were no remarkable pathologic findings. We planned to carry out a laterally-approached sinus lift and insertion of 2 implants simultaneously to minimize the surgical procedures.

Local anesthetic was administered at buccal and palatal sites. A full-thickness flap was reflected after crestal incision along the alveolar ridge. An alveolar process was revealed enough to gain access to the surgical area with adequate

instrumentation. The antrostomy began with the use of a 3.3-mm-diameter, dome-shaped drill (DASK; Dentium, Seoul, Korea) originally designed for crestal sinus approach. The drill has nonaggressive diamond grit and can be used with depth control cylinder for safe antrostomy without perforation of maxillary sinus membrane. The drilling depth was limited to 3 mm using a depth control cylinder because the thickness of lateral wall ranged from 3.0 to 3.2 mm in a computerized tomography (CT) scan (Figure 1). Antrostomy was performed with 1000 rpm drilling speed at a height of 6 mm above the crestal margin of the center of the maxillary second molar (Figure 2). After antrostomy the sinus membrane was observed as a bluish hue. The membrane was elevated with the specially designed DASK curettes (Dentium) that were sequentially used to detach the membrane (Figures 3 and 4). Sufficient displacement of the membrane from the lateral wall was confirmed. A 6.0-mm-diameter, DASK trephine design bur (Dentium) was positioned on the lateral wall at the site of membrane detachment, and osteotomy was performed at a drill speed of 1000 rpm with external irrigation, perpendicular to the sinus wall (Figure 5). The lateral bone window was removed with a curette and stored in saline solution (Figures 6 and 7). Removed bone block was crushed and mixed with bovine bone material (Bio-Oss; Geistlich Biomaterials, Wolhusen, Switzerland; Figure 8). The membrane was lifted with curettes and bone graft material was inserted. After the positioning implants the surgical area was sutured with 4-0 nylon.

## DISCUSSION

Lateral sinus approach with trephine bur has some recommended advantages that include reduced surgical time and simple procedures. In addition, there is no need to use additional instruments, such as auxiliary different hand pieces, chisels, mallets, and piezoelectric equipment.<sup>8</sup> However, trephine bur is not always safe for antrostomy.<sup>9</sup> The width of the sinus wall is often different at the point of trephine bur, but only certain depth of bone can be removed with trephine bur. Moreover, bone thinning in other procedures is gradually accomplished until the maxillary sinus membrane is identified to secure the intact membrane, but gradual elimination of bone is difficult using the trephine bur.

To supplement the safety of antrostomy using the trephine bur, a dome-shaped DASK drill originally for the crestal sinus

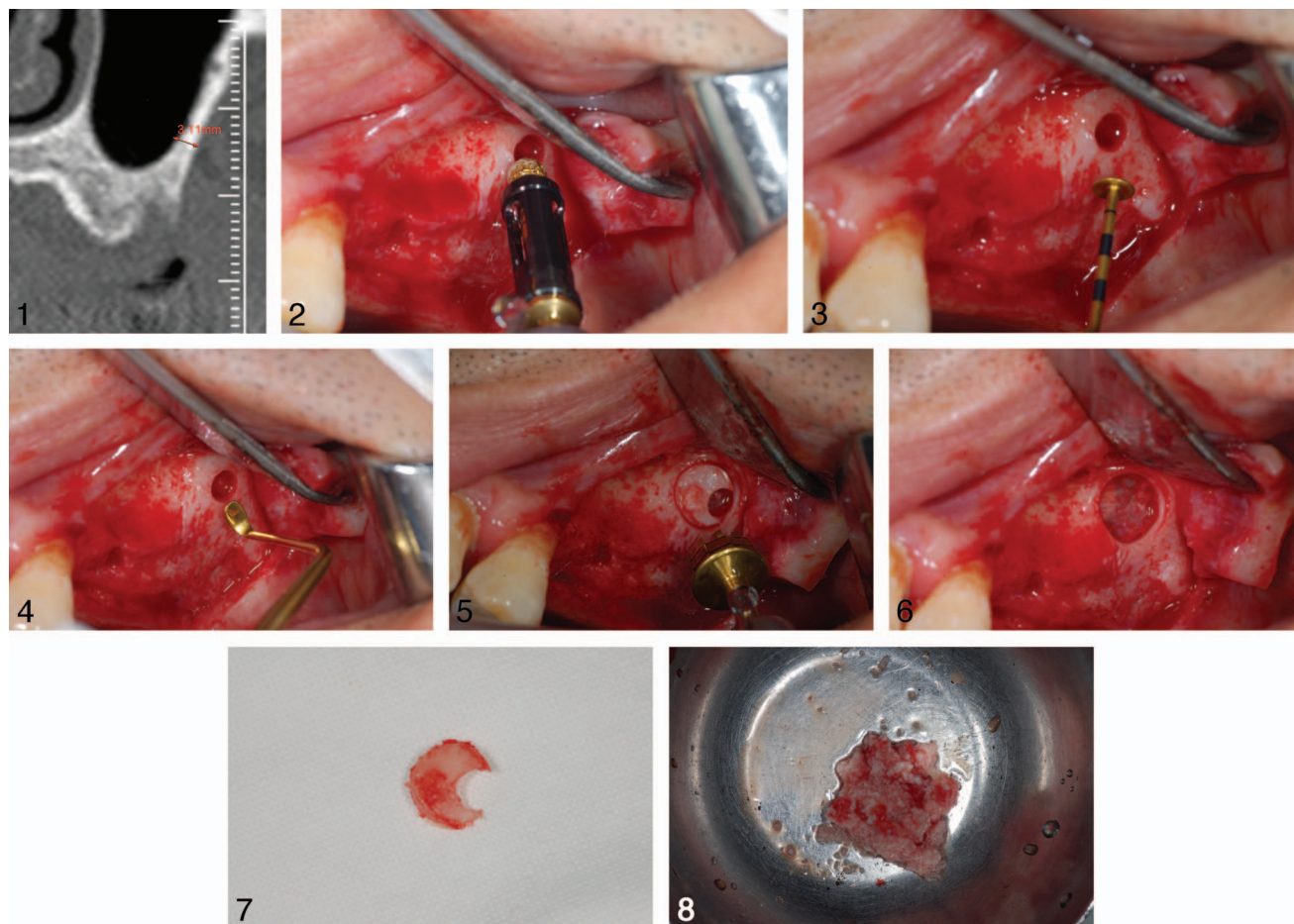
<sup>1</sup> Department of Prosthodontics, Korea University Ansan Hospital, Gyeonggi-do, Republic of Korea.

<sup>2</sup> Department of Prosthodontics, Korea University Anam Hospital, Seoul, Republic of Korea.

<sup>3</sup> Department of Prosthodontics, Korea University Guro Hospital, Seoul, Republic of Korea.

\* Corresponding author, e-mail: swshin@korea.ac.kr

DOI: 10.1563/aaid-joi-D-14-00017



**FIGURES 1–8.** **FIGURE 1.** The thickness of lateral wall ranged from 3.0–3.2 mm in a CT scan. **FIGURE 2.** Three-mm diameter, dome-shaped drill with depth control cylinder used to approach to sinus membrane. **FIGURE 3.** Sinus membrane was elevated with the dome-shaped curette. **FIGURE 4.** Spoon-shaped curette extended the undermined area of sinus membrane. **FIGURE 5.** Antrostomy was performed with 6-mm diameter trephine design bur. **FIGURE 6.** Lateral bone window was formed for sinus graft. **FIGURE 7.** Detached bone block was acquired. **FIGURE 8.** Removed bone block was crushed and mixed with bovine bone material.

approach was used in this case. The cutting edge of the dome-shaped drill is designed to eliminate bone with less damage to membrane. In addition, the exact depth of antrostomy is possible using the depth control cylinder. In 2011, Lozada et al<sup>10</sup> presented a case report about the crestal sinus approach with this drill and documented a perforation rate of 5.8%. The perforation rate after antrostomy with this drill for the lateral approach may be lower compared to the crestal approach, because the clinician can observe the osteotome site after osteotomy and gradually increase the depth of osteotomy for lateral approach, while relying on tactile sense in the crestal approach. In our experience, no perforation of the maxillary sinus membrane has occurred in the 19 patients treated with this technique to date.

The patient in this report had a thick sinus wall. Antrostomy is the most time-consuming of the lateral sinus approach procedures, because bone thinning is carefully performed to preserve the intact membrane, and much more time is required as the preparation site becomes deeper. Antrostomy with piezoelectric surgery is especially affected by the thickness of wall.<sup>11,12</sup> However, the presently described technique is

negligibly influenced by the thickness of wall: if thickness of lateral wall is measured in CT images and approximate osteotome depth of dome-shaped bur is determined, and more autogenous bone can be acquired from the detached bone block.

It is often difficult to secure sight during drilling of antrostomy of the second molar region, especially when the first molar remains and blocks the sight. Drilling with a dome-shaped DASK drill and a trephine bur can be performed without sight, because the dome-shaped drill is designed to grind the bone of the lateral wall with nonaggressive diamond grit and depth cylinder and trephine bur is used on the sinus wall on which the sinus membrane is detached.

There are some limitations of this technique because of the relative large size of trephine bur compared to other tools for antrostomy. To avoid soft tissue damage by trephine bur, sufficient flap elevation is necessary, and access to the patient who has small mouth or scars on the lip may be more difficult. Moreover, the size of antrostomy is difficult to control with this technique. Antrostomy with a 6.0-mm diameter trephine bur may be too excessive in the situation of sinus augmentation for

sinus elevation less than 5 mm. However, these problems can be solved by the production of various sizes of trephine burs.

Nineteen patients have so far been treated using the described lateral sinus technique, with only 1 perforated maxillary sinus membrane occurring. The perforation occurred during detachment of the sinus with a curette. As the perforation site was small, perforation site was covered with absorbable membrane and sinus lift could be successfully finished.

#### ABBREVIATION

CT: computerized tomography

#### REFERENCES

1. Nolan PJ, Freeman K, Kraut RA. Correlation between Schneiderian membrane perforation and sinus lift graft outcome: a retrospective evaluation of 359 augmented sinus. *J Oral Maxillofac Surg.* 2014;72:47–52.
2. Papa F, Cortese A, Maltarello MC, Sagliocco R, Felice P, Claudio PP. Outcome of 50 consecutive sinus lift operations. *Br J Oral Maxillofac Surg.* 2005;43:309–313.
3. Barone A, Santini S, Sbordon L, Crespi R, Covani U. A clinical study of the outcomes and complications associated with maxillary sinus augmentation. *Int J Oral Maxillofacial Implants.* 2006;21:81–85.
4. Buchmann R, Khoury F, Faust C, Lange DE. Peri-implant conditions in periodontally compromised patients following maxillary sinus augmentation. A long-term post-therapy trial. *Clin Oral Implants Res.* 1999;10:103–110.
5. Timmenga NM, Raghoobar GM, Boering G, van Weissenbruch R. Maxillary sinus function after sinus lifts for the insertion of dental implants. *J Oral Maxillofac Surg.* 1997;55:936–939; discussion 40.
6. Wallace SS, Mazor Z, Froum SJ, Cho SC, Tarnow DP. Schneiderian membrane perforation rate during sinus elevation using piezosurgery: clinical results of 100 consecutive cases. *Int J Periodont Restor Dent.* 2007;27:413–419.
7. Smiler DG, Johnson PW, Lozada JL, et al. Sinus lift grafts and endosseous implants. Treatment of the atrophic posterior maxilla. *Dent Clin North Am.* 1992;36:151–186; discussion 87–88.
8. Farre-Pages N, Auge-Castro ML, Alaejos-Algarra F, Mareque-Bueno J, Ferrés-Padró E, Hernández-Alfaro F. A novel trephine design for sinus lift lateral approach. Case report. *Med Oral Patol Oral Cir Bucal.* 2011;16:e79–e82.
9. Emtiaz S, Carames JM, Pragosa A. An alternative sinus floor elevation procedure: trephine osteotomy. *Implant Dent.* 2006;15:171–177.
10. Lozada JL, Goodacre C, Al-Ardah AJ, Garbacea A. Lateral and crestal bone planing antrostomy: a simplified surgical procedure to reduce the incidence of membrane perforation during maxillary sinus augmentation procedures. *J Prosthet Dent.* 2011;105:147–153.
11. Vercellotti T, De Paoli S, Nevins M. The piezoelectric bony window osteotomy and sinus membrane elevation: introduction of a new technique for simplification of the sinus augmentation procedure. *Int J Periodont Restor Dent.* 2001;21:561–567.
12. Kramer FJ, Ludwig HC, Materna T, Gruber G, Merten HA, Schliephake H. Piezoelectric osteotomies in craniofacial procedures: a series of 15 pediatric patients. Technical note. *J Neurosurg.* 2006;104:68–71.