

# Implant Injury Case Series and Review of the Literature

## Part 1: Inferior Alveolar Nerve Injury

Jonathan Du Toit, BChD, MSc Dent<sup>1\*</sup>  
 Howard Gluckman, BDS, MChD<sup>1</sup>  
 Rami Gamil, BDS<sup>1</sup>  
 Tara Renton, BDS, MDSc, PhD<sup>2</sup>

Injury to adjacent structures is an unfortunate and avoidable outcome of oral implant placement surgery. Paramount among these is perforation into paranasal sinus; into neighboring tooth root; through cortical plate; and into vessels, canals, and, most importantly, nerves. In most cases, injudicious oral implant placement can be attributed to poor treatment planning. We present the cases of several patients referred for postsurgical radiology that illustrate injury to the inferior alveolar canal by implant impingement, penetration, and even complete obliteration of the nerve and canal in the absence of proper treatment planning and imaging modalities. The authors stress the importance of thorough implant case preparation and planning, which may include the use of cone beam computerized tomography in order to minimize nerve injury.

**Key Words:** dental implant, CBCT, nerve damage, mandibular canal, treatment planning, radiographic guidelines

### INTRODUCTION

The treatment of missing teeth by restored dental implants is increasingly sought out and being provided to patients.<sup>1</sup> Dental implant treatment, though scientifically proven to be predictable and effective, is also increasingly being reported with complications.<sup>2,3</sup> Incidence in the literature of iatrogenic inferior alveolar nerve injury (IANI) directly resulting from implant treatment ranges from 0% to 33.2%.<sup>4,5</sup> Iatrogenic IANI in implant treatment is now a frequent sequelae with serious medicolegal implications.<sup>6,7</sup> These injuries vary from short-term sensory disturbance or total paresthesia to persistent neuropathy and dysfunction.<sup>8</sup> The psychosocial consequences of these injuries and significant impact on quality of life are poorly emphasized in the literature. Renton et al explored this theme, alerting clinicians to the severity thereof.<sup>9</sup> Most alarming is that these injuries are entirely avoidable; because dental implant treatment is entirely elective, negligence is implicit.<sup>10,11</sup> Moreover, the injuries are potentially permanent. The literature reports that early implant removal leads to partial and complete resolution, though late intervention may lead to further injury and leave the neuropathy unresolved.<sup>12,13</sup> In a 2013 study of 287 patients who had sustained IANI, 30 injuries were related to implant surgery, and 27 of the 30 injuries were permanent.<sup>14</sup> The predominant consequence in these cases was a combination of permanent dysesthesia, paresthesia, or anesthesia (Table 1). More than a third of these patients had only intraoral periapical

radiographs taken for their implant treatment planning. Pantomographs were taken as part of treatment planning for half of the patients. Cone beam computerized tomography (CBCT) formed part of the preoperative assessment and treatment planning in only 3 patients. Although authors have previously stated that intervention for trigeminal nerve injury is optimal at 3 months because permanent central nervous system changes can occur after nerve damage, there is increasing evidence that implant-related nerve injury requires urgent treatment within 30 hours.<sup>15,16</sup> Understressed in the literature is the need for thorough assessment and treatment planning before any implant surgery. The paucity of adequate diagnostic aids and thorough radiographic assessment in cases of IANI is alarming.

We present a case series of IANI resulting from dental implant treatment in patients who were referred for postoperative CBCT. There is an absence of preoperative CBCT imaging in all the cases. This article emphasizes the importance of meticulous treatment planning in preventing implant-related nerve injuries, and we stress the importance of preoperative radiographic planning, which may include CBCT imaging.

### CASE REPORTS

#### *Patient 1*

A 42-year-old female patient presented to a CBCT imaging clinic after dental implant treatment. The initial implant surgery was uneventful. The patient reported that no complications had occurred during the procedure. The patient's main complaint upon presentation to the imaging clinic was "my chin and the lip on the bottom right are still numb." No other symptoms, pain or otherwise, were reported. The numbness allegedly persisted despite the resolution of the local anesthet-

<sup>1</sup> Department of Oral Medicine & Periodontology, University of the Witwatersrand, Johannesburg, South Africa.

<sup>2</sup> Department of Oral Surgery, King's College London Dental Institute, London, United Kingdom.

\* Corresponding author, e-mail: drjondonu@gmail.com

DOI: 10.1563/AAID-JOI-D-14-00022

TABLE 1

Definitions of nerve symptoms in cases of injury

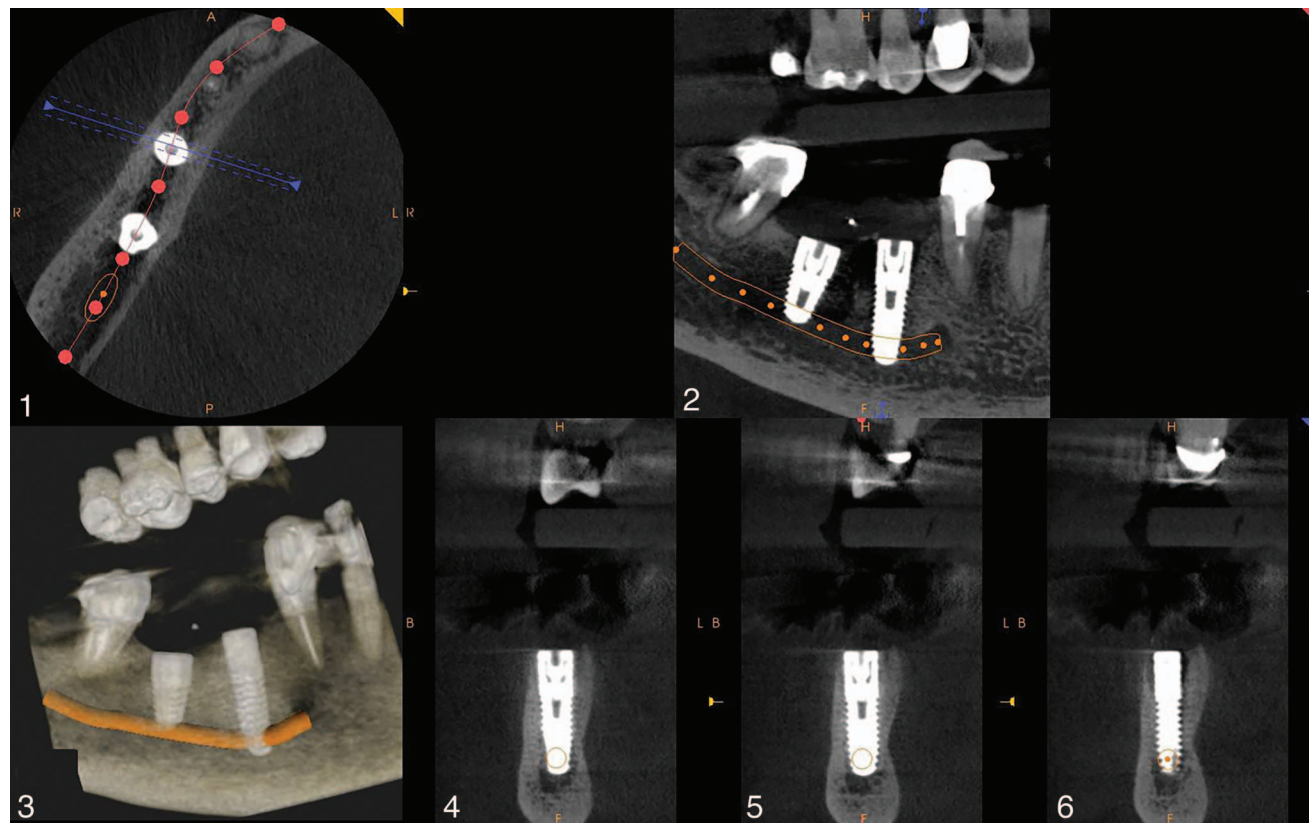
Anesthesia	Numbness, no sensation on examination
Allodynia	Pain from a stimulus not normally associated with pain.
Hyperalgesia	Exaggerated pain from a painful stimulus
Paresthesia	Altered sensation—tingling sensation, pins and needles.
Dysesthesia	Uncomfortable altered sensation

ic. The patient reported that she had notified the clinician who provided the implant treatment, and was advised to wait 6–8 weeks to monitor the symptoms. The clinician did not take a CBCT scan before, during, or after the implant procedure. No significant medical history was reported for the patient. Examination of the patient at the imaging clinic indicated anesthesia of the right side of the chin, spanning from middle of the corpus to the parasymphiseal area and from the mandibular border to the right half of the lower lip and commissure. Allodynia, hyperalgesia, paresthesia of the affected area, and associated dermatome were absent. The patient reported that the anesthesia had not resolved or altered since its initial onset. A CBCT scan of the patient’s jaws was taken to investigate further. The images demonstrated 2 endosteal implants situated in approximately the #29 and #30 positions. Although positioning in the anteroposterior dimension in the ridge between the existing teeth appeared to be without

concern (Figures 1 and 2), the scans demonstrated that the implant in the #29 position had penetrated the mandibular canal. It appeared that the implant was placed too deep subcrestally and was possibly longer than necessary (Figure 2). The implant apex had traversed and obliterated the canal (Figures 2 and 3). The misplacement of the implants can be appreciated in the axial view (Figures 4 through 6). The imaging indicated no other obvious dental pathologies.

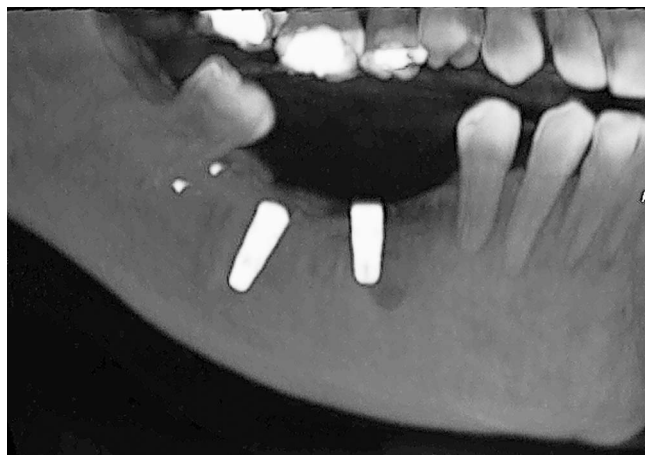**Patient 2**

A 33-year-old female patient presented to a CBCT imaging clinic after oral implant treatment. The patient was referred by a clinician for additional postoperative imaging. Before implant placement, only an orthopantomograph (OPG) was taken; The clinician did not perform CBCT imaging before, during or after the procedure. A CBCT scan of the patient’s jaws was taken at this subsequent visit with a specific focus on the right mandible. The images demonstrated 2 endosteal implants situated in approximately the #29 and #30 area. Angulation of the implant at #30 appeared to have a somewhat mesial inclination; the implant at #29 appeared closely associated with the mental foramen (Figure 7). The scans demonstrated that the implant in the #30 position had penetrated the mandibular canal (Figures 8 through 10). The apex of the implant #30 was clearly shown to be lying within the canal. No other obvious dental pathologies were identified on the images.



**FIGURES 1–6.** Patient 1: Cone beam computerized tomographic imaging illustrates 2 implants in the right side of the mandible that have penetrated and traversed the nerve canal.

Downloaded from <http://meridian.allenpress.com/joi/article-pdf/4/1/4/e144/2041925/aaid-io-d-14-00022.pdf> by guest on 10 October 2024



**FIGURE 7.** Patient 2: Implant at position #29, in close relation to the mental foramen. The implant at position #30 was placed significantly subcrestal.

### Patient 3

A 27-year-old female patient presented to an imaging clinic for her initial diagnostic OPG (Figure 11). After dental implant treatment, the patient returned for a 4-month follow-up OPG (Figure 12). During the follow-up imaging visit, the patient complained of numbness of the right side of the chin that had persisted since the treatment. The treating clinician did not take a CBCT scan before, during, or after the implant procedure. An OPG was taken before treatment and deemed sufficient for the implant treatment planning. The patient reported that she had informed the clinician about the persisting anesthesia. The patient's medical history was not significant. A CBCT scan of the patient's jaws was taken at this subsequent visit to investigate the complaint further. The images demonstrated 2 endosteal implants situated in approximately the #29 and #31 areas, adjacent on either side to an existing tooth, #30. Although the anteroposterior positioning appeared to be without concern (Figures 12 through 14), both the OPG and the scans demonstrated that the implant in the #31 position had penetrated the mandibular canal, and its apex was lying directly within it (Figures 12 through 15). The follow-up imaging indicated no other obvious dental pathologies.

### Patient 4

A 43-year-old male patient presented to a CBCT imaging clinic roughly a year after oral implant treatment. The patient's main complaint was "my chin and the lip on the bottom right are still numb a year after the surgery." The numbness was reported to have occurred after the implant treatment and was not present before. The patient reported that he had notified the treating clinician who had provided the implant and was advised to wait and monitor the symptoms. A CBCT scan was not taken before, during, or after the implant procedure. The patient reported no significant medical history. The follow-up OPG was inconclusive in terms of locating any pathology in the fourth quadrant that might be associated with the main complaint (Figure 16). The CBCT scan taken of the patient's jaws demonstrated 4 restored endosteal implants situated in approximately the #30 and #31

area and in the #18 and #19 area. Nerve tracing was done in the cross-sections for implants #30 and #31. The imaging demonstrated that these implants had been placed very near to the mandibular canal (Figures 17 and 18). The apex of implant #31 appeared to compromise the roof of the canal (Figure 19). Unassociated sinus penetration was noted on the right-hand side.

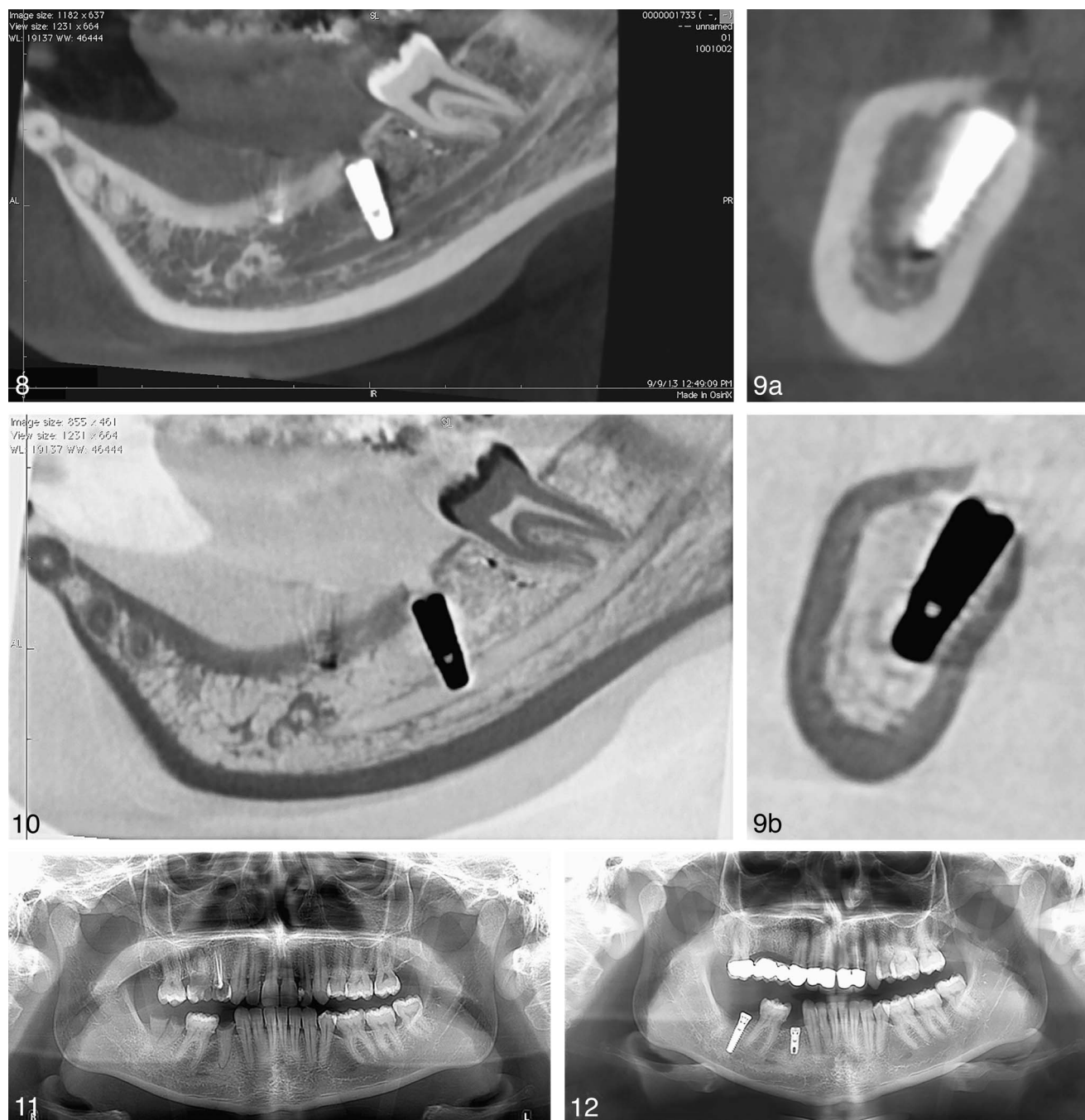
### DISCUSSION

A PubMed search of the literature on nerve injury in relation to dental implants, using the terms "implant" and "inferior alveolar nerve" returned 295 results. Of these, 3 case series and 7 case reports relating to IANI due to dental implant placement were sourced.<sup>15-18</sup> The reports were dated between 1996 and 2013. The reported injuries were attributed to dental implant placement in close proximity to the mandibular canal (15 cases), accessory innervation (2 cases), implant placement in close proximity to the mental foramen (2 cases), peri-implantitis (1 case), bruxism (1 case), and unknown etiology (1 case). Of these, one case series reported injuries resulting from dental implant approximation to the mandibular canal (13 cases), protrusion into the canal (6 cases), and dental implant crossing over the canal (6 cases).<sup>14</sup> A single case report demonstrated IANI resulting from perforation of the mandibular canal.<sup>19</sup> In all 4 cases reported in the current article, the patient had nerve injury in relation to mandibular implants placed in the premolar and molar region; an identified risk factor previously reported.

The frequency at which the 2 CBCT imaging centers mentioned in this report demonstrated and diagnosed IANI as a result of dental implant surgery during 2013 also reinforces the possibility that IANI is underreported in the literature. In the opinion of the authors, IANI may be occurring more frequently than is generally perceived. This should be of concern to patients seeking to have dental implants placed for the eventual restoration of their missing teeth, as they may be inadequately informed of the prevalence of nerve injury complications. Not providing valid consent denies a patient the right to understand and be accurately informed about an evidence-based risk of the intended procedure. Moreover, the demonstrable absence of CBCT planning in these cases may have contributed to the resulting injury; thus, in agreement with previous reports, we stress the importance of implementing adequate imaging modalities in planning dental implant placement.

In a recent overview of iatrogenic trigeminal nerve injuries in relation to dentistry, Renton et al<sup>14</sup> profiled 287 such patients. The authors reported that more than 70% of patients presented with a combination of neuropathic pain, altered sensation, and numbness. Interestingly, the 4 patients in the current series also reported numbness. That said, Renton et al<sup>14</sup> reported how the deleterious effect of lip and chin paresthesia, hypoesthesia, and hyperalgesia, resulting from IANI seriously affected the patients' ability to function normally. Daily activities, such as shaving, kissing, eating, and drinking, that a person with a healthy and intact sensory nerve may take for granted, are significantly hindered in the injured mental and inferior alveolar nerve patient.

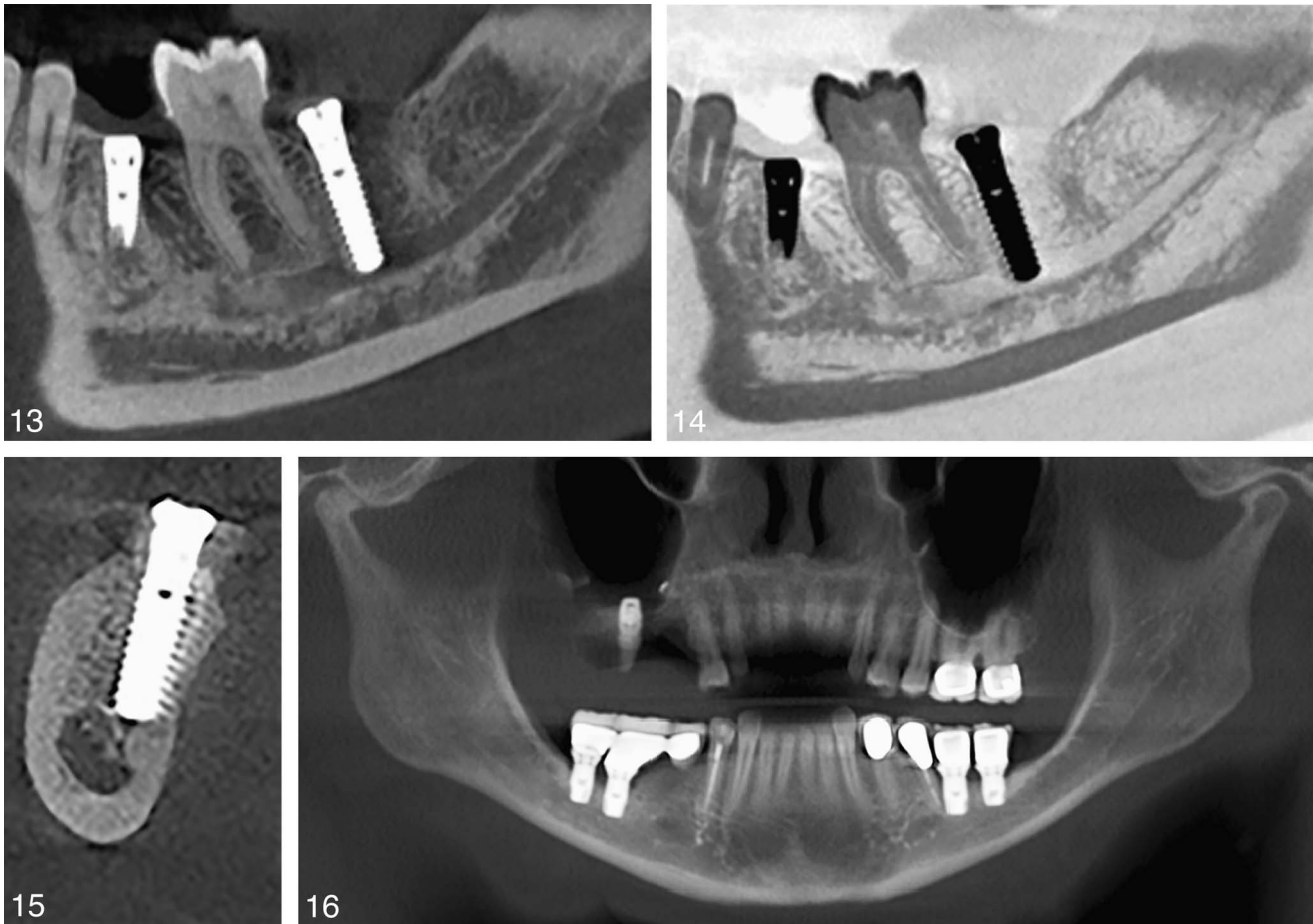




**FIGURES 8–12.** **FIGURES 8–10.** Patient 2: Cone beam computerized tomographic imaging clearly illustrates that the implant at position #30 has penetrated the nerve. **FIGURE 11.** Patient 3: Preoperative orthopantomograph. **FIGURE 12.** Patient 3: Postoperative orthopantomograph after implant placement in the right side of the mandible.

Of concern is the increasing evidence confirming that these injuries are frequently permanent.<sup>6,11,13</sup> Risk assessment is a prerequisite in planning mandibular implant surgery. Most importantly, when considering dental implant treatment, is obtaining a concise patient history (social, medical, and dental) and determining if the patient's expectations are appropriate.<sup>20</sup> Clinical evaluation underpins successful implant treatment, and evaluation of soft tissue and adjacent dental structures will

dictate additional potential limitations of the proposed treatment. Mandibular implant planning must include radiographs—first, a routine periapical radiograph to predominantly assess bone height availability and nerve position. Several recommendations for radiographic assessment are available for dental implant planning.<sup>21,22</sup> The American Association for Oral and Maxillofacial Radiology<sup>23</sup> has developed the following preoperative imaging recommendations:



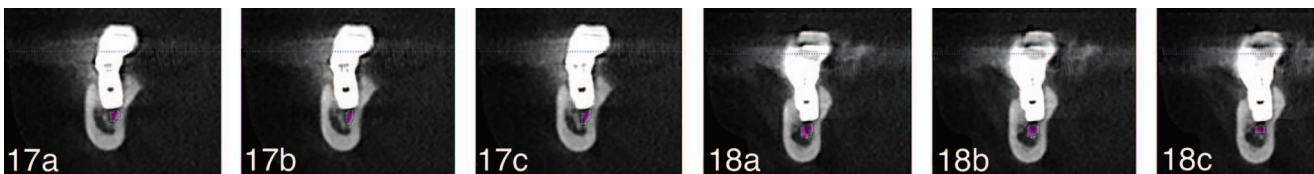
**FIGURES 13–16.** FIGURES 13–15. Patient 3: Cone beam computerized tomographic imaging better illustrates the extent of the implant length at #31 and the penetration into the nerve canal. **FIGURE 16.** Patient 4: Orthopantomographic view demonstrates 4 implants placed in an atrophic, posterior mandible. Note also the sinus penetration.

1. Panoramic radiography should be the imaging modality of choice in the initial workup for mandibular implants.
2. Use intraoral periapical views to supplement the preliminary panoramic investigation.
3. Do not use cross-sectional imaging as a first-line radiographic imaging evaluation.
4. However, radiographic examination of any potential implant site should include cross-sectional imaging orthogonal to the site of interest.
5. When selecting cross-sectional imaging for a potential implant site, CBCT should be the imaging modality of choice.
6. To assess sites planned for augmentation and grafting, namely sinus augmentation, block grafting, and so on, CBCT imaging should be used.

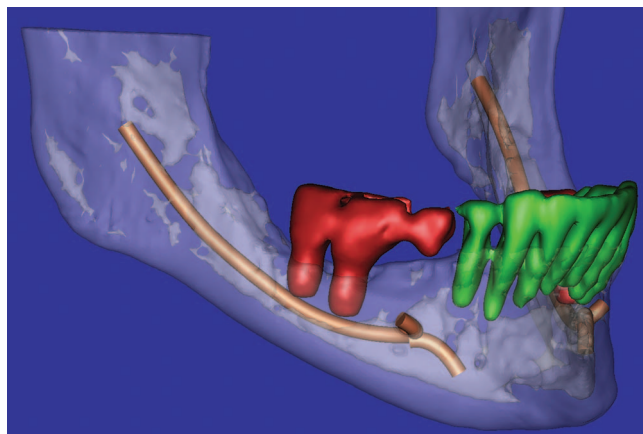
7. CBCT imaging should be used to assess sites that have been augmented and grafted to prepare for implant placement

General guidelines should be followed, including justification, optimization, and minimization of radiologic exposure.<sup>24</sup> When using radiography in accordance with national and international recommendations for radiation protection, the lowest radiation dose must be considered.<sup>25</sup>

The European Association for Osseointegration also has recommendations when considering CBCT scanning (Table 2). Their radiographic guidelines recommend cautionary prescription of cross-sectional tomography and 3-dimensional planning techniques.<sup>21,22</sup> By performing 3-dimensional plotting of the mandibular canal and its surrounding bone volume and



**FIGURES 17 AND 18.** Cone beam computerized tomographic imaging axial views better illustrate the proximity of the implant apices to the nerve canal roof.



**FIGURE 19.** Three-dimensional rendition of the cone beam computerized tomographic imaging showing implants in the right side of the mandible, intimate with the nerve.

density, IANI may better be avoided. This involves judicious use of clinical and radiographic investigations as part of the preoperative implant planning.

Cross-sectional imaging is applied in patients where more information is required after appropriate clinical examination and standard radiographic techniques have been performed. According to the European Association for Osseointegration, if the conventional radiographic examination reveals the relevant anatomical boundaries and adequate bone height and space, no additional imaging is required for implant placement. Pantomographic and periapical views may not provide for all the aforementioned.<sup>23</sup> Many anatomical boundaries can be identified during the surgical procedure; however, cross-sectional imaging may enhance the identification and location of certain anatomical structures and boundaries and their relationship to the potential surgical site. Cross-sectional imaging thus may have several indications (Table 3).

No consensus exists as to whether CBCT scanning or tomography effectively reduces inferior alveolar nerve (IAN) damage. However, strict guidelines do exist enforcing the use of cross-sectional imaging if required to better assess the IAN when routine radiography is inadequate. A recent study reports that using CBCT in selected high-risk patients before third-molar surgery, for example, reduces surgically related IANI.<sup>13</sup> Specifically relating to the IAN, localization should involve the visualization of the position of the nerve, including its anatomy

TABLE 2 Assessments needed from radiographic and clinical investigations to plan dental implant treatment
1. Bone density and quantity at the implant site
2. Implant location to support the ideal restoration or any deviations
3. Inferior alveolar nerve localization and risk factors when assessing nerve position (mental loop, characteristics of inferior alveolar nerve position in various sites of mandible)
4. Safety zone: risk of mandibular canal perforation and nerve injury
5. Surgical guide construction
6. Selection of implant

TABLE 3 Indications for cross-sectional imaging for the purpose of diagnosis and treatment planning
1. When the clinical examination and conventional radiography do not adequately demonstrate relevant anatomical boundaries (nerves, vessels, teeth, bone cortex) and the absence of pathology
2. When reference to such images can provide additional information that can help to minimize the risk of damage to important anatomical structures and that is not obtainable when using conventional radiographic techniques
3. In clinical borderline situations where there appears to be limited bone height and/or bone width available for successful implant treatment
4. Where implant positioning can be improved so that biomechanical, functional, and esthetic treatment results are optimized
5. When the diagnostic information can be enhanced by use of radiographic templates, computer-assisted planning, and surgical guides

(eg, bifid or not) and the presence of a mental loop; projection of the IAN beyond the mental foramen (commonly misnamed the mandibular “incisal canal”); and cortication and thickness of the canal cortex of the nerve.<sup>26,27</sup> Several reports in the literature highlight the difficulty in assessing the anatomy of the mental foramen. In a radiologic study, an anterior loop of the mental nerve was observed in 28% of patients, ranging in length from 0.4 to 2.19 mm.<sup>27</sup> Of the radiographically diagnosed anterior loops, 40% were not seen on anatomical examination. Because large variations in the anterior lingual loop at the mental foramen and in the diameter of the incisive canal have been noted, one should not assume that a fixed distance mesially (ie, clearance) from the mental foramen will be safe. Intraoperative examination of vital structures is indispensable for the safe installation of implants in the interforaminal area of the mandible. Using CBCT, anatomical variations related to the mandibular canal, such as bifid canals, anterior loop of mental nerve, and the canal’s cortication, can all be determined accurately.

Several issues are associated with the prescription of CBCT, however. Exposure can be reduced using 180° degree rotation, thereby halving the radiation dose but providing sufficient resolution to identify the mandibular canal.<sup>25</sup> Software programs purporting to clearly identify the IAN using CBCT and only 5 points to 3-dimensionally plot the mandibular canal on CBCT imaging may be misleading.<sup>28</sup> In addition, most clinicians have limited ability to read a patient’s CBCT scan. Mapping of the mandibular canal is often not undertaken by the prescribing clinician because of lack of knowledge and experience in reading CBCT.<sup>29</sup>

Despite multiple guidelines, there seems to be confusion around when to preassess patients radiographically by CBCT. The minimum radiographic requirement for mandibular implant planning should include a pantomograph view and additional intraoral films. The threshold by which CBCT assessment should be requested seems to elude many practitioners. A recent case study of a cohort of 30 patients with IANI revealed the following<sup>14</sup>:



- The most commonly affected region was the mandibular at areas 5 and 6.
- Implant lengths ranged from 5 to 13 mm, and there was often evidence of inappropriate selection criteria.
- Inadequate clearance (safety zone above mandibular canal) or direct perforation of the nerve was found.
- Reports of intraoperative bleeding, pain, a sudden "give," and neural stimulation (tingling, shooting pain over the chin) were noted.

That said, selection of the appropriate diagnostic imaging should be based on individual clinical needs.<sup>23</sup> Thus, we conclude that perhaps a pragmatic recommendation for the preoperative use of CBCT in dental implant planning that should be made based on the risk factors:

1. Region (mandibular premolar and molar region)
2. Proportional relationship between the:
  - 2.1 Depth of bone above the mandibular canal (based on a pantomograph assessment, with consideration of the magnification)
  - 2.2 Length of the intended implant
3. Minimum safety zone of 2 mm

The necessity of postoperative CBCT assessment of the dental implant position in patients presenting with nerve injuries is unclear. The development of nerve injury in relation to dental implants is a clinical diagnosis.<sup>8,11</sup> If the routine periapical view confirms that the implant is distant from the mandibular canal, this is sufficient to confirm a nerve injury due to local anesthetic.<sup>11</sup> Distance from the canal on the periapical view in patient where the site is infiltrated (ie, in the absence of a mental or IAN block) then succinctly excludes nerve damage from local anesthetic from the diagnosis. In summary, the necessary removal of the implant related to nerve injury based on an intraoral or pantomograph view is justified, and additional assessment and radiation by CBCT is probably not required. Further research is required before specific recommendations can be made.

To conclude, nerve injuries in relation to dental implants have strong consequences, can be permanent, and are often life changing for patients. Dental implant treatment is by nature an elective procedure and, thus, these injuries are avoidable. When nerve injury occurs the clinician is, therefore, deemed negligent and there may be medicolegal consequences. Doing preoperative planning, managing the patient's expectations, and obtaining explicit and valid consent are all imperative steps required before delivering this care. Permanent injuries cannot be rectified and thus damage must be prevented by all means.

#### CONCLUSIONS

Panoramic imaging modalities remain the standard for planning assessment in implant dentistry, and CBCT imaging has a significant role for presurgical implant site assessment, implant placement, and follow-up radiographic assessment for specific cases. The use of CBCT in implantology and oral surgery in general makes clinical decision making easier and more precise when clinicians are appropriately trained and familiar with prescription guidelines. Despite the numerous radiograph-

ic guidelines published, many practitioners seem confused about the best-practice preoperative radiographic assessment in implant treatment. Clarification and further research is required to provide pragmatic radiographic recommendations for patients undergoing dental implant treatment.

#### ABBREVIATIONS

CBCT: cone beam computerized tomography  
 IAN: inferior alveolar nerve  
 IANI: inferior alveolar nerve injury  
 OPG: orthopantomograph

#### REFERENCES

1. Narby B. Factors shaping demand for prosthetic dentistry treatment with special focus on implant dentistry. *Swed Dent J Suppl.* 2011;218:3–65.
2. Ferrigno N, Laureti M, Fanali S. Dental implants placement in conjunction with osteotome sinus floor elevation: a 12-year life-table analysis from a prospective study on 588 ITI implants. *Clin Oral Implants Res.* 2006;17:194–205.
3. Fugazzotto PA, Vlassis J, Butler B. ITI implant use in private practice: clinical results with 5,526 implants followed up to 72+ months in function. *Int J Oral Maxillofac Implants.* 2004;19:408–412.
4. Wismeijer D, van Wass MA, Vermeeren JI, Kalk W. Patient's perception of sensory disturbances of the mental nerve before and after implant surgery: a prospective study of 110 patients. *Br J Oral Maxillofac Surg.* 1997;35:254–259.
5. Bartling R, Freeman K, Kraut RA. The incidence of altered sensation of the mental nerve after mandibular implant placement. *J Oral Maxillofac Surg.* 1999;57:1408–1412.
6. Renton T, Yilmaz Z. Iatrogenic injuries to oral trigeminal nerve branches: 221 cases. Risk management from dental protection. *Riskwise UK.* 2009;39:4–9.
7. Renton T. Prevention of iatrogenic inferior alveolar nerve injuries in relation to dental procedures. *Dent Update.* 2010;37:350–352,354–356,358–360.
8. Alhassani AA, AlGhamdi A.S. Inferior alveolar nerve injury in implant dentistry: diagnosis, causes, prevention, and management. *J Oral Implantol.* 2010;36:401–407.
9. Smith JG, Elias LA, Yilmaz Z, et al. The psychosocial and affective burden of posttraumatic neuropathy following injuries to the trigeminal nerve. *J Orofac Pain.* 2013;27:293–303.
10. Ahmad I. Risk management in clinical practice. Part 5. Ethical considerations for dental enhancement procedures. *Br Dent J.* 2010;209:207–214.
11. Khawaja N, Renton T. Case studies on implant removal influencing the resolution of inferior alveolar nerve injury. *Br Dent J.* 2009;206:365–370.
12. Renton T, Yilmaz Z. Profiling of patients presenting with posttraumatic neuropathy of the trigeminal nerve. *J Orofac Pain.* 2011;25:333–344.
13. Ziccardi VB, Zuniga JR. Nerve injuries after third molar removal. *Oral Maxillofac Surg Clin North Am.* 2007;19:105–115.
14. Renton T, Dawood A, Shah A, Searson L, Yilmaz Z. Post-implant neuropathy of the trigeminal nerve. A case series. *Br Dent J.* 2012;212:E17.
15. Kim JE, Shim JS, Huh JB, Rim JS, Lee JY, Shin SW. Altered sensation caused by peri-implantitis: a case report. *Oral Surg Oral Med Oral Pathol Oral Radiol.* 2013;116:e9–e13.
16. Melis M, Coiana C, Secci S. Bruxism elicited by inferior alveolar nerve injury: a case report. *Int J Periodontics Restorative Dent.* 2012;32:e29–e33.
17. Maqbool A, Sultan AA, Bottini GB, Hopper C. Pain caused by a dental implant impinging on an accessory inferior alveolar canal: a case report. *Int J Prosthodont.* 2013;26:125–126.
18. Al-Ouf K, Salti L. Post insertion pain in region of mandibular dental implants: a case report. *Implant Dent.* 2011;20:27–31.
19. Leckel M, Kress B, Schmitter M. Neuropathic pain resulting from

implant placement: case report and diagnostic conclusions. *J Oral Rehabil.* 2009;36:543–546.

20. Gelb D, McAllister B, Nummikoski P, Del Fabbro M. Clinical and radiographic evaluation of Brånemark implants with an anodized surface following seven-to-eight years of functional loading. *Int J Dent.* 2013;2013:583–567.

21. Harris D, Buser D, Dula K, et al. E.A.O. guidelines for the use of diagnostic imaging in implant dentistry: a consensus workshop organization by the European Association for Osseointegration in Trinity College Dublin. *Clin Oral Implants Res.* 2002;13:566–570.

22. Horner K, Islam M, Flygare L, Tsiklakis K, Whaites EJ. Basic principles for use of dental cone beam computed tomography: consensus guidelines of the European Academy of Dental and Maxillofacial Radiology. *Dentomaxillofac Radiol.* 2009;38:187–195.

23. American Dental Association Council on Scientific Affairs. The use of cone-beam computed tomography in dentistry: an advisory statement from the American Dental Association Council on Scientific Affairs. *J Am Dent Assoc.* 2012;143:899–902.

24. SEDENTEXTCT. *Radiation Protection: Cone Beam CT for Dental and*

*Maxillofacial Radiology: Evidence Based Guidelines* 2011. [http://www.sedentext.eu/files/guidelines\\_final.pdf](http://www.sedentext.eu/files/guidelines_final.pdf). Accessed Month XX, 20XX.

25. Dawood A, Brown J, Sauret-Jackson V, Purkayastha S. Optimization of cone beam CT exposure for pre-surgical evaluation of the implant site. *Dentomaxillofac Radiol.* 2012;41:70–74.

26. Juodzbaly G, Wang HL, Sabalys G. Anatomy of mandibular vital structures. Part I: mandibular canal and inferior alveolar neurovascular bundle in relation with dental implantology. *J Oral Maxillofac Res.* 2010;1:e2.

27. Uchida Y, Yamashita Y, Goto M, Hanihara T. Measurement of anterior loop length for the mandibular canal and diameter of the mandibular incisive canal to avoid nerve damage when installing endosseous implants in the interforaminal region. *J Oral Maxillofac Surg.* 2007;65:1772–1779.

28. Platzer S, Bertha G, Heschl A, Wegscheider WA, Lorenzoni M. Three-dimensional accuracy of guided implant placement: indirect assessment of clinical outcomes. *Clin Implant Dent Relat Res.* 2013;15:724–734.

29. Miles DA. CBCT in clinical practice. In: *Atlas of Cone Beam Imaging for Dental Applications*. 2nd ed. Hanover Park, Ill: Quintessence; 2012.