

Model-Guided Flapless Immediate Implant Placement and Provisionalization in the Esthetic Zone Utilizing a Nanostructured Titanium Implant: A Case Report

Steven E. Holbrook, DMD

INTRODUCTION

There have been many reports of successful immediate implant placement in the literature.¹⁻⁴ One potential problem that has been identified in immediate implant placement is gingival recession in the esthetic zone.⁵ This case illustrates a technique designed to minimize this potential for recession by using model-guided flapless implant placement.

Guided placement of the implant allows for optimal positioning, thus reducing esthetic complications.⁶ The technique relies on a panorex radiograph to determine the vertical height of available bone, and the construction of a model of the ridge to determine the width of available bone.

A ridge mapping procedure based on a bone sounding technique was used to construct the model of the ridge. An extremely thin acupuncture needle (0.30 mm), rather than a caliper, was used for the bone sounding, allowing measurements to be made without anesthetizing the patient.

A surgical stent was then prepared on the model to optimally position the implant as determined from the diagnostic wax up. This technique is cost-effective and exposes the patient to a minimal amount of radiation while allowing for flapless implant placement, and optimal implant positioning for prosthetic reconstruction. The implant provides a platform shift to maintain bone and reduce the risk of gingival recession.⁷ The final abutment was placed immediately with a provisional restoration to provide support for the tissue and minimize the risk of gingival recession.⁸⁻¹¹ A socket shielding technique is also used to reduce the potential for gingival recession by using the retained root structure to help maintain the bone and soft tissue.¹²

The implant was composed of nanostructured commercially pure (CP) titanium, which has been shown to integrate faster than implants composed of conventional CP titanium and have strength greater than implants composed of titanium alloys.¹³ As such, a nanostructured CP titanium implant is especially appropriate for immediate implant placement and immediate provisionalization.

CASE REPORT

The patient presented complaining of issues with the fixed bridge that replaced his missing front tooth 15 years previously; he noticed himself spitting air and saliva from under the bridge when speaking. He had replaced missing posterior teeth with implants and found that they were easier to floss than his fixed bridge. He was interested in the possibility of replacing his fixed bridge with an implant. He also expressed concern regarding the appearance of his lower anterior teeth and wanted whiter teeth. Clinical examination revealed a fixed partial denture from tooth #7 to tooth #9. There was approximately 2 mm of gingival recession at the facial aspects of teeth #s 7 and 9, exposing the metal margin of the porcelain fused to the metal fixed partial denture (Figure 1). The patient was not concerned with the exposed margin as when he smiled he did not display this area. The gingival levels of the anterior teeth were uneven, but this was also not a concern to the patient due to lack of display of the area when he smiled.

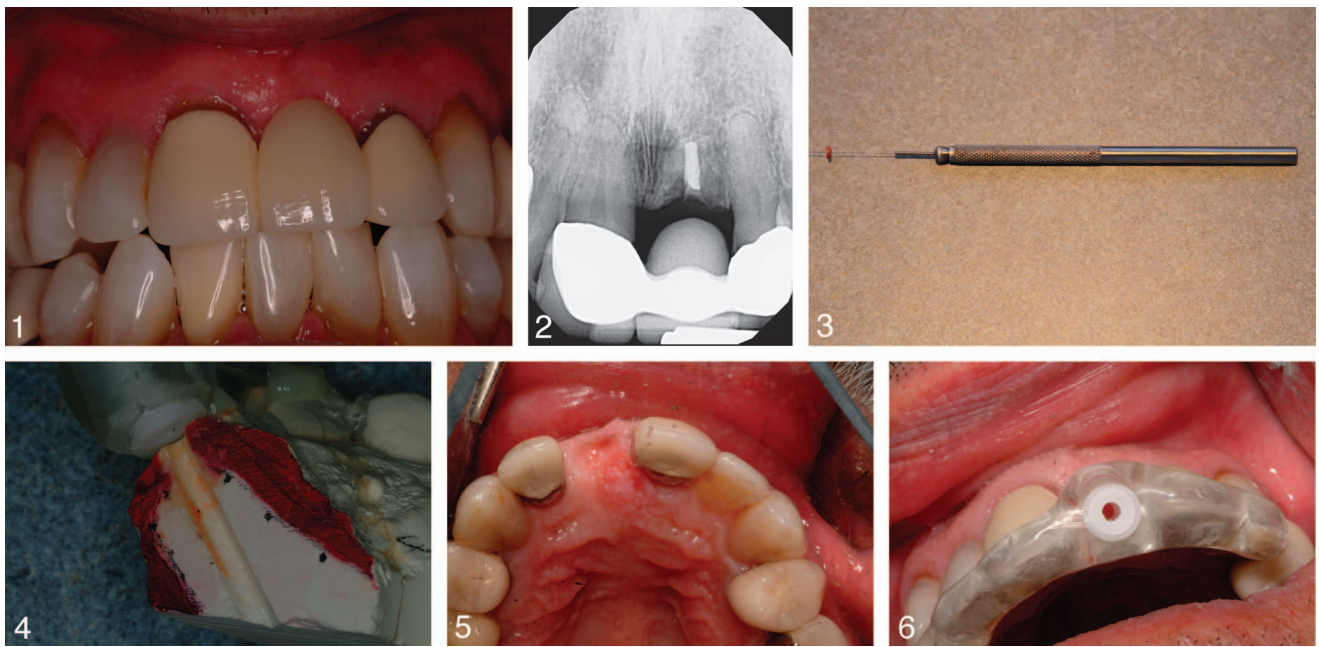
Radiographic examination revealed a retained endodontically treated root in the area of tooth #8 (Figure 2). There appeared to be adequate height of bone available for implant placement. The root of tooth #8 was retained when the bridge was constructed by the patient's previous dentist to help prevent bone and soft tissue loss, which occurs following an extraction.

The width of bone available for implant placement was determined by utilizing a bone sounding technique. Impressions were made, a facebow transfer was taken, and a centric relation bite registration was made for the construction of diagnostic casts. Preoperative photographs were taken to aid in diagnosis. A diagnostic wax up was done to help determine the optimal position for the implant to replace tooth #8, and to provide a model for development of provisional restorations.

Bone sounding was accomplished using an acupuncture needle attached to a microsurgical scalpel holder (Figure 3). An endodontic stopper was placed on the needle, which was then advanced through the tissue until it made contact with bone. The tissue thickness was determined using a millimeter caliper. These measurements were then transferred to the model, and the ridge was mapped (Figure 4). The optimal position for the implant was determined in the laboratory, and a surgical guide was constructed to allow for flapless surgery.

The patient's fixed bridge was sectioned to allow for the removal of the pontic replacing tooth #8. The retaining abutment crowns were left in place on teeth #7 and #9 (Figure

Corresponding author, e-mail: abqdentist@aol.com
DOI: 10.1563/AAID-JOI-D-14-00040



FIGURES 1–6. **FIGURE 1.** Preoperative photograph. **FIGURE 2.** Preoperative radiograph. **FIGURE 3.** Bone sounding instrument. **FIGURE 4.** Cross-sectional model of ridge. **FIGURE 5.** Ridge following sectioning bridge. **FIGURE 6.** Surgical guide positioned.

5). The osteotomy was then prepared using the guide (Figure 6). The facial portion of the retained root was maintained to help minimize the potential for gingival recession (Figures 7 and 8).¹² All other root fragments and residual gutta percha that remained after the use of the osteotomy drills were removed by curettage with hand instruments and irrigation with sterile saline. A 4.3 × 11.5-mm implant (Ossotanium Implants, Albuquerque, NM) was placed with an insertion torque of 40 N-cm, and, as such, immediate provisionalization was appropriate.¹⁴ A final abutment was then placed, and a luxatemp provisional restoration was then fabricated utilizing a putty template made from a duplicated model of the diagnostic wax up (Figure 9). The provisional restoration was then adjusted so there was no contact in centric relation and in excursive movements.

The implant site and the soft tissue were allowed to heal and mature for 18 weeks prior to the process of the fabrication of final restorations. During this time period, the lower anterior teeth were restored with veneers, and the patient's teeth were whitened. The provisional was then removed along with the retainers of the fixed bridge on teeth #7 and #9. The natural teeth were prepared, and single crowns were placed on teeth #7 and #9 and on the implant at the #8 position (Figures 10 and 11). The patient was pleased with the esthetic result, the improvement in function, and the ease of maintenance.

DISCUSSION

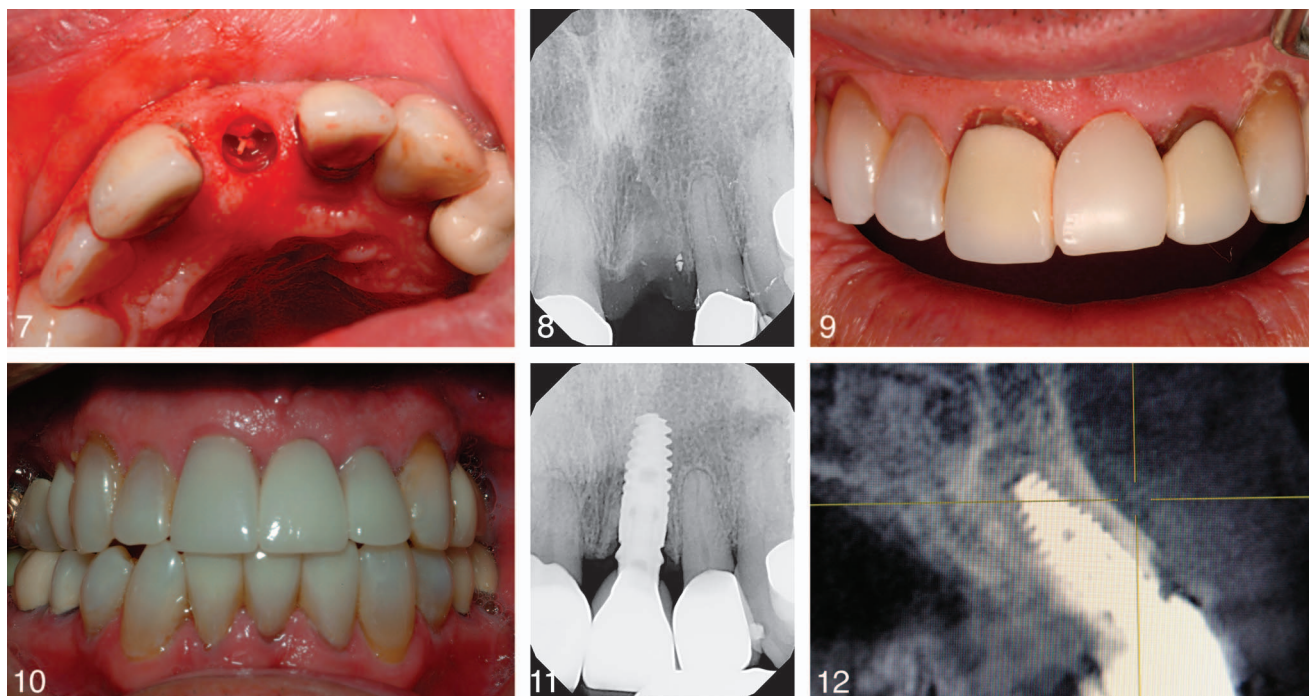
There are many advantages of flapless surgery for both the patient and the dentist. There is less pain with flapless surgery compared with implant placement involving the reflection of a flap.¹⁵ Foin et al¹⁵ concluded that pain decreased faster with flapless surgery, the number of patients who felt no pain was

more than twice as high, and patients took less pain medication. This is because there is less trauma and therefore less swelling of the tissues when a flap is not reflected. The duration of the surgery is reduced with flapless surgery, as are the potential surgical complications. In addition, flapless surgery has been shown to reduce recession in the esthetic zone.¹⁶

The implant is optimally positioned with guided surgery, which minimizes prosthetic complications.

Model-guided surgery has several advantages over computer-guided surgery for implant placement. These advantages include less radiation exposure for the patient, less cost for the patient, and an accuracy equivalent to computer-guided surgery. Model-guided surgery is advantageous as there is less radiation exposure for the patient compared with computer-guided surgery.¹⁷ The imaging required for model-guided surgery involves panorex and periapical radiographs as opposed to computerized tomography (CT) or cone beam imaging. This allows the dentist to follow the principle of ALARA (as low as reasonably achievable) and avoid the exposure of the patient to unnecessary radiation. Model-guided surgery is less costly than computer-guided surgery.¹⁸ Bedard¹⁸ noted that technological advances have occurred at ever increasing costs to patients and that cast-based guided implant placement is simple and inexpensive.

Most importantly, model-guided surgery has been shown to be as accurate as computer-guided surgery.^{19,20} Fitzgerald et al¹⁹ found that ridge mapping was a satisfactory technique in cases with adequate bone volume (more than 5 mm of buccal lingual width), and that the accuracy of model-based surgery was within acceptable limits for guided surgery as described in the literature. Chen et al²⁰ concluded that ridge mapping provided measurements of the buccal-lingual ridge width, which were consistent with those obtained by direct caliper



FIGURES 7–12. **FIGURE 7.** Root fragment during osteotomy. **FIGURE 8.** Radiograph following osteotomy. **FIGURE 9.** Immediate provisional. **FIGURE 10.** Postoperative photograph. **FIGURE 11.** Postoperative radiograph. **FIGURE 12.** One-year postoperative cone beam computerized tomography.

measurement following surgical exposure of the bone. Chen et al²⁰ also found that cone beam CT (CBCT) was less consistent compared with direct caliper measurements and did not provide any additional significant diagnostic information compared with ridge mapping.

The method utilized for determining the available bone for implant placement in model-guided surgery uses bone sounding techniques. Bone sounding measurements are used to map the ridge, and these measurements are transferred to models that are then used to fabricate a stent for guided implant placement. Flanagan²¹ described a technique using bone sounding to estimate the size, width, and angulation of the edentulous ridge. Stumpel²² used an anesthetic syringe and an endodontic stopper for ridge mapping to prepare for cast-based implant placement. In this case, a less invasive method of bone sounding was used that did not require the patient to be anesthetized.

A socket shield technique was utilized to minimize the potential for facial recession by retaining a portion of the retained root facial to the implant.²³ The premise of the socket shield technique is that the retention of the tooth fragment and the corresponding periodontal ligament will help maintain the facial plate and thus preserve the gingival contours by preventing facial bone remodeling following immediate implant placement. The retention of roots to maintain alveolar ridge contour and develop pontic sites has long been an accepted technique in dentistry. In 1980, Casey and Lauciello²⁴ reported that submerged root procedures were an accepted technique to reduce alveolar bone resorption associated with overdenture techniques. They also found that a layer of cementum formed over the prepared dentin surfaces of

retained roots. This would suggest that the retention of a root fragment might also help preserve alveolar bone.

Salama et al²⁵ reported on the advantages of retaining a submerged root for pontic site development, and concluded that a greater amount of surrounding tissue was preserved than with extraction and a socket preservation technique. Fillipi et al²⁶ reported on the preservation of bone and soft tissue by decoronation of a tooth prior to implant placement and concluded that decoronation was a simple and safe surgical procedure for the preservation of bone prior to implant placement. The conclusions of Salama et al²⁵ and Filipi et al²⁶ suggest that the retention of a root fragment may preserve both bone and soft tissue.

Gray and Vernino²⁷ found that placement of dental implants into retained root fragments did not result in inflammation and found a cementum or cementum-like matrix on the titanium surface adjacent to the periodontal ligament of the retained root. This result suggests that a layer of cementum may form at sites where the root fragment contacts the implant, and that normal osseointegration would take place in the areas where the root portion and titanium did not contact.

Hurzeler et al¹² showed that retaining the buccal portion of the retained root in conjunction with immediate implant placement allowed the implant to achieve osseointegration without any inflammatory or resorptive response. They also showed that the lingual aspects of the retained roots were covered with new cementum; where there was contact between the implant and the retained root, cementum formed on the implant surface without the interposition of fibrous tissue. The buccal aspects of the retained roots demonstrated a

normal periodontal ligament attaching to the buccal bone plate.¹²

Kan and Rungcharassaeng²³ reported that the success of the socket shield technique depends on the condition of the failing tooth. They stated that the tooth must be healthy with no evidence of pathology. Contraindications for this technique would include infection, fracture, internal or external resorption, and perforation. Failing teeth with mobility or widened periodontal ligaments are also contraindicated as they may present an increased risk for root fragment dislodgement.

In this case, the endodontically treated root was retained by the previous dentist following decoronation to help retain the bone and soft tissue. There was no pathology associated with the retained root, and the implant was placed to the lingual of the remaining buccal root portion. The cross-sectional view from a CBCT taken 1 year postoperatively shows contact of the root fragment and the implant along with the maintenance of the facial cortical bone (Figure 12). This view also confirms that the model-guided surgical placement accurately positioned the implant faciolingually in the alveolar bone.

The final abutment was positioned immediately upon placement of the implant to minimize peri-implant bone resorption and the potential for gingival recession.²⁸ Of course, the placement is dependent on optimal positioning of the implant, which is assured by the model-guided technique. The positioning of the final abutment at the time of implant placement allows for the dentist to prevent the repeated destruction of the connective tissue attachment that occurs due to multiple abutment changes and thus preserve the peri-implant marginal bone and gingiva.²⁹

The implant design in this case used a platform switch that has been shown to minimize marginal bone loss.³⁰ This is accomplished by separating the implant abutment junction from the restorative margin to decrease the negative influence of the microgap. The implant was immediately provisionalized, which has been shown to prevent recession by providing support for the soft tissue following extraction and implant placement.³¹

Cavallaro et al¹⁴ stated that immediate implant placement with provisionalization can be considered if primary stability can be achieved during implant placement with an insertion torque of 30–40 N·cm. However, Becker³² reported successful immediate provisionalization with insertion torque values as low as 15 N·cm. In this case, immediate provisionalization was considered to be appropriate because the insertion force exceeded 40 N·cm.

The implant utilized in this case was composed of ultrafine grained or nanostructured CP titanium. This material provides a distinct advantage in immediate loading in that it provides for faster osseointegration and thus may be more appropriate for earlier loading compared with CP titanium.³³ The use of this nanostructured ultrafine grained titanium allows for shorter treatment time.

The increased osteoblast adhesion on nanostructured titanium compared with conventional CP titanium may be explained by the grain size of nanostructured titanium compared with conventional CP titanium, and the similarity of the grain size of nanostructured titanium to the inorganic mineral grain size of bone.³⁴ Conventional commercially pure

titanium has a grain size of 10–50 μm , whereas woven bone has a grain size of 10–50 nm, and lamellar bone has a grain size of 20–50 nm.³⁵ Nanostructured or ultrafine grained titanium has a grain size of less than 50 nm. Thus, nanostructured titanium is more effective in mimicking the extracellular matrix roughness and nanostructure of bone. This is significant because stem cells, preosteoblasts, and osteoblasts adhere to titanium at grain boundaries. The increase in the number of grain boundaries found in nanostructured titanium leads to an increase in osteoblast attachment and proliferation to nanostructured titanium surfaces.

Faghihi et al³³ also showed an increase in extracellular protein secretion by these cells, an increase in fibronectin secretion, and an increase in attachment and calcification of osteoid. The rate of calcification of osteoid was 3 times greater on nanostructured titanium compared with conventional CP titanium. The nanostructured titanium surface showed increased wettability, hydrophilicity, protein adsorption, and surface energy compared with conventional titanium. All of these factors may contribute to the increased attachment, spreading, cytoskeletal, and extracellular activity of osteoblasts. This enhanced response to the nanostructured titanium surface should allow for earlier loading and would be optimal for immediate implant loading.

It is important to note that these nanostructured titanium implants have advantages in both surface and bulk properties. Dental implants traditionally have been composed of commercially pure titanium, which has been proven to be very biocompatible. Titanium alloys such as AL6V4Ti were developed to provide the benefit of greater strength, but at the cost of reduced biocompatibility.³⁶ Nanostructured or ultrafine grained titanium was developed in an effort to enhance the strength of CP titanium while also maintaining biocompatibility. Nanostructured titanium implants have been proven to be stronger than conventional commercially pure titanium implants, as strong as titanium alloy implants, and more biocompatible than titanium alloy implants.^{37,38}

Valiev et al³⁹ compared the strength values of conventional titanium, titanium alloy, and nanostructured titanium. They found that nanostructured titanium had an ultimate tensile strength of 1240 MPa compared with 700 MPa for conventional titanium and 940 MPa for titanium alloy (Ti-6Al-4V). The ultimate tensile strength is the maximum stress that a material can withstand before failure occurs. The yield strength of nanostructured titanium was 1200 MPa compared with 530 MPa for conventional titanium and 840 MPa for titanium alloy. Yield strength measures the amount of stress that a material can withstand before permanent deformation occurs. The fatigue strength was 620 MPa for nanostructured titanium compared with 340 MPa for conventional titanium and 530 MPa for titanium alloy. Fatigue strength measures the ability of a material to withstand repeated stress. The percentage of elongation was only 12% for nanostructured titanium compared with 25% for conventional titanium and 16% for titanium alloy. Percentage elongation is a measure of a material's toughness or resistance to tensile stress. The percentage of reduction in area was 42% for nanostructured titanium compared with 52% for conventional titanium and 45% for

titanium alloy. The percentage of reduction of area is a measure of the ductility of a material.

Nanostructured implants provide a significant increase in strength with only a small decrease in ductility. An implant with increased strength in the anterior maxilla could provide a significant advantage, as functional loading in this area is rarely axial.

CONCLUSION

All of the parameters used in this case—model-guided surgery, a socket shield technique, immediate implant placement, immediate placement of a final abutment, immediate provisionalization, and the use of a nanostructured titanium implant—allowed for a successful result in the esthetic zone with a minimal amount of patient discomfort. Although the use of the socket shield technique proved to be successful in this case, additional long-term studies need to be completed prior to recommending this technique for routine use. In addition, although initial studies indicate that the use of nanostructured titanium implants should be advantageous, more clinical studies are needed to evaluate the efficacy of nanostructured titanium implants compared with conventional titanium implants in immediate loading.

ABBREVIATIONS

CBCT: cone beam computerized tomography

CT: computerized tomography

REFERENCES

- Esposito M, Grusovin V, Willings M, Coulthard P, Worthington HV. The effectiveness of immediate, early, and conventional loading of dental implants: A Cochrane systematic review of randomized controlled clinical trials. *Int J Oral Maxillofac Implants.* 2007;22:893–904.
- Tarnow DP, Emtiaz S, Classi A. Immediate loading of threaded implants at stage 1 in edentulous arches: Ten consecutive case reports with 1-to-5 year data. *Int J Oral Maxillofac Implants.* 1997;12:319–324.
- Crespi R, Cappare P, Gherlone E, Romanos G. Immediate versus delayed loading of dental implants placed in fresh extraction sockets in the maxillary esthetic zone: A clinical comparative study. *Int J Oral Maxillofac Implants.* 2008;23:753–758.
- Prosper L, Crespi R, Valenti E, Cappare P, Gherlone E. Five year follow-up of wide diameter implants placed in fresh molar extraction sockets in the mandible: Immediate versus delayed loading. *Int J Oral Maxillofac Implants.* 2010;25:607–612.
- Grunder U. Stability of the mucosal topography around single tooth implants and adjacent teeth: 1-year results. *Int J Periodontics Restorative Dent.* 2000;20:11–17.
- Funato A, Salama MA, Ishikawa T. Timing, positioning, and sequential staging in esthetic implant therapy: A four dimensional perspective. *Int J Periodontics Restorative Dent.* 2007;27:313–323.
- Lazzara RJ, Porter SS. Platform switching: A new concept in implant dentistry for controlling postrestorative crestal bone levels. *Int J Periodontics Restorative Dent.* 2006;26:9–17.
- Herman F, Lerner H, Palti A. Factors influencing the preservation of periimplant marginal bone. *Implant Dent.* 2007;16:165–175.
- Rodriguez X, Vela X, Mendez V, Segala M, Calvo-Guirado JL, Tarnow DP. Effect of abutment dis/reconnection on periimplant bone resorption: A radiologic study of platform switched and non platform switched implants placed in animals. *Clin Oral Implant Res.* 2013;24:305–311.
- Iglhaut G, Becker K, Golubovic V, Schliephake H, Mihatovic I. Impact of dis/reconnection of laser microgrooved and machined implant abut-

ments on soft and hard tissue healing. *Clin Oral Implant Res.* 2013;24:391–397.

- Alberti L, Donnini F, Alberti C, Camerino M, Sgaramella N, Muzio L. Clinical and radiologic evaluation of 70 immediately loaded single implants in the maxillary esthetic zone: Preliminary results after one year of functional loading. *Int J Oral Maxillofac Implants.* 2012;27:181–186.
- Hurzeler MB, Zuhr O, Schupbach P, Rebele SF, Emmanouilidis N, Fickl S. The socket shield technique: A proof of principle report. *J Clin Periodontol.* 2010;37:855–862.
- Webster T, Ejiiofor J. Increased osteoblast adhesion on nanophase metals: Ti, Ti6Al4V, and CoCrMo. *Biomaterials.* 2004;25:4731–4739.
- Cavarallo J, Greenstein B, Greenstein G. Clinical methodologies for achieving primary implant stability: The effects of alveolar bone density. *J Am Dent Assoc.* 2009;140:1366–1372.
- Foin T, Bosson JL, Isidori M, Blanchet E. Effect of flapless surgery on pain experienced in implant placement using an image guided system. *Int J Oral Maxillofac Implants.* 2006;21:298–304.
- Oh TJ, Shotwell JL, Billy EJ, Wang HL. Effect of flapless surgery on soft tissue profile: A randomized controlled clinical trial. *J Periodontol.* 2006;77:874–882.
- The American Dental Association Council on Scientific Affairs. The use of cone beam tomography in dentistry: an advisory statement from the American Dental Association Council on scientific affairs. *J Am Dent Assoc.* 2012;143:899–902.
- Bedard J. Enhanced cast based guided dental implant placement for ultimate esthetics: Concept and technical procedures. *J Oral Maxillofac Surg.* 2009;67:108–114.
- Fitzgerald M, O'Sullivan M, O'Connell B, Houston F. Accuracy of bone mapping and guided implant placement in human cadavers using a model-based planning procedure. *Int J Oral Maxillofac Implants.* 2010;25:999–1006.
- Chen LC, Lundgren T, Hallstrom H, Cherel F. Comparison of different methods of accessing alveolar ridge dimensions prior to dental implant placement. *J Periodontol.* 2008;79:401–405.
- Flanagan D. A nonradiologic method for estimating bone volume for dental implant placement in the completely edentulous arch. *J Oral Implantol.* 2001;27:115–117.
- Stumpel L. Cast based guided implant placement: A novel technique. *J Prosthetic Dent.* 2008;100:61–69.
- Kan JL, Rungcharassaeng K. Proximal socket shield for interimplant papilla preservation in the esthetic zone. *Int J Periodontics Restorative Dent.* 2013;33:e24–e31.
- Casey DM, Lauciello FR. A review of the submerged-root concept. *J Prosthetic Dent.* 1980;43:128–132.
- Salama M, Ishikawa T, Salama H, Funato A, Garber D. Advantages of the root submergence technique for pontic site development in esthetic implant therapy. *Int J Periodontics Restorative Dent.* 2007;27:521–527.
- Filippi A, Pohl Y, Von Arx T. Decoronation of an ankylosed tooth for preservation of alveolar bone prior to implant placement. *Dental Traumatol.* 2001;17:93–95.
- Gray JL, Vernino AR. The interface between retained roots and dental implants: A histologic study in baboons. *J Periodontol.* 2004;75:1102–1106.
- Tarnow D, Rodriguez X. Effect of abutment dis/reconnections on peri-implant bone resorption. *Clin Oral Implant Res.* 2013;24:305–311.
- Iglhaut G, Becker K, Golubovic V, Schliephake H, Mihatovic L. The impact of dis-reconnection of laser microgrooved and machined implant abutments on soft-and hard-tissue healing. *Clin Oral Implant Res.* 2013;24:391–397.
- Al-Nsour M, Chan H-L, Wang H-L. Effect of the platform switching technique on preservation of peri-implant marginal bone: A systematic review. *Int J Oral Maxillofac Implants.* 2012;27:138–145.
- Kan JY, Rungcharassaeng K, Lozada JL, Zimmerman G. Facial gingival tissue stability following immediate placement and provisionalization of maxillary anterior single implants: A 2 to 8 year follow up. *Int J Oral Maxillofac Implants.* 2011;26:179–187.
- Becker CM, Wilson TG Jr, Jensen OT. Minimum criteria for immediate provisionalization of single tooth dental implants in extraction sites: a 1-year retrospective study of 100 consecutive cases. *J Oral Maxillofac Surg.* 2011;69:491–497.
- Faghihi S, Azari F, Zhilyaev A, Szpunar J, Vali H, Tabrizian M. Cellular and molecular interactions between MC3T3-E1 pre-osteoblasts and nanostructured titanium produced by high-pressure torsion. *Biomaterials.* 2007;28:3887–3895.

34. Estrin Y, Ivanova E, Michalska A, Truong V, Lapovok R, Boyd R. Accelerated stem cell attachment to ultrafine grained titanium. *Acta Biomaterials*. 2011;7:900–906.
35. Webster T, Ejiolor J. Increased osteoblast adhesion on nanophase metals: Ti, Ti6Al4V, and CoCrMo. *Biomaterials*. 2004;25:4731–4739.
36. Brunski J, Puelo D, Nanci A. Biomaterials and biomechanics of oral and maxillofacial implants: Current status and future developments. *Int J Oral Maxillofac Implants*. 2000;15:15–46.
37. Serra G, Morais L, Semenova I, et al. Nanostructured severe plastic deformation processed titanium for orthodontic mini-implants. *Mater Sci Eng C Mater Biol Appl*. 2013;33:4107–4202.
38. Stolyarov V, Zhu Y, Lowe T, Valiev R. Microstructures and properties of ultrafine-grained pure titanium processed by equal channel angular pressing and cold deformation. *J Nanosci Nanotechnol*. 2001;1:237–242.
39. Valiev R, Semenova I, Latysh V, et al. Nanostructured titanium for biomedical applications. *Adv Engineer Mater*. 2008;10:1–4.