

Minimally Invasive Surgical Approaches for Esthetic Implant Dentistry: A Case Report

Joichiro Hayashi, DDS, PhD^{1*}

Kitetsu Shin, DDS, PhD¹

Henry H. Takei, DDS, MS²

INTRODUCTION

Although replacing missing single teeth with dental implants has become routine, restoring anterior teeth with implant-supported crowns is highly technique-sensitive and remains a challenging task.^{1,2} The long-term clinical and esthetic success of an implant-supported restoration is determined by stable peri-implant soft-tissue morphology that is in harmony with the surrounding tissue architecture of the natural dentition. However, after second-stage dental implant surgery, peri-implant soft tissues recede approximately 0.8 to 1.4 mm.³ Recession usually occurs during the first 3 to 6 months after surgery.⁴ As a result, correction of marginal soft tissue morphology around implant restoration is required in some cases.

Subepithelial connective tissue graft techniques are a predictable means to treat gingival recession in natural dentition^{5,6} and to correct peri-implant soft tissue margins,^{5,7} offering a good color match with the adjacent tissues. However, this technique has some disadvantages, such as increased technical difficulty and the involvement of two surgical areas, one being the palatal wound donor area. The semilunar coronally positioned flap (SCPF) had been described to cover denuded root surfaces.⁸ This technique causes no disturbance of the adjacent papillae, no shortening of the vestibule, and no tension on the flap. In addition to these advantages, no sutures are needed. Therefore, it is a minimally invasive periodontal plastic surgery to treat gingival recession. Several clinical trials^{9–11} confirmed the predictability of this technique when used to treat Miller Class I gingival recession defects. Nevertheless, to our knowledge, no study or case report has described resolution of recession around implant restorations using this technique.

In some cases of esthetic implant restoration, the correction of gingival margin of natural teeth adjacent to implants could be a better solution for esthetic problems than that of marginal soft tissue around implant. Surgical crown-lengthening procedures, such as apically positioned flap with osseous resection, are often performed to adjust gingival levels for an esthetic outcome.¹² However, the rate of gingival growth after surgery differs in the facial and interdental areas, causing changes in

crown form,¹³ and the position of the free gingival margin changes during healing periods ranging from 3 to 12 months.^{13,14} In addition, attachment loss occurs at adjacent teeth.¹⁵ Thus, it is difficult to control the final gingival margin and determine the correct timing of subgingival crown placement, especially in esthetic areas.

In this case report, we describe two surgical approaches to harmonize peri-implant soft-tissue morphology with the surrounding tissue architecture of the natural dentition based on the philosophy of minimally invasive dentistry. One surgical approach is SCPF to coronally position the marginal soft tissue around the implant restoration; the other is a flapless technique to lengthen a crown, namely, minimally invasive esthetic crown lengthening (MIECL) to achieve the desired free gingival margin position in a short period.

CASE REPORT

A 45-year-old female patient presented for management of a fractured maxillary right central incisor associated with chronic periodontitis. This tooth was extracted. Two months later, an implant fixture (Tapered Screw-Vent Implant System, Zimmer Dental Inc, Carlsbad, Calif) measuring 3.7 mm in diameter and 11.5 mm in length was placed with guided bone regeneration; the procedure utilized a titanium-reinforced expanded polytetrafluoroethylene membrane (Gore-Tex TR4Y, W. L. Gore & Associates Inc, Flagstaff, Ariz) (Figure 1). After second-stage implant surgery, provisional restorations were placed on the implant and maxillary left central incisors. Six months after the second-stage implant surgery, asymmetry was observed between the marginal tissues of implant and left incisor (Figure 2). The ideal width-to-length ratio of the central incisors is 8:10 (Figure 3).¹⁶ In addition, ideally, the central incisors and cuspids touch the gingival line (the line drawn from the cervical area of the right and left cuspids) while the lateral incisors approximately 1 mm above.¹⁶ Thus, we planned to lengthen the crown of the left central incisor by 1 mm using MIECL and to correct the high scalloped soft tissue architecture at the implant using SCPF.

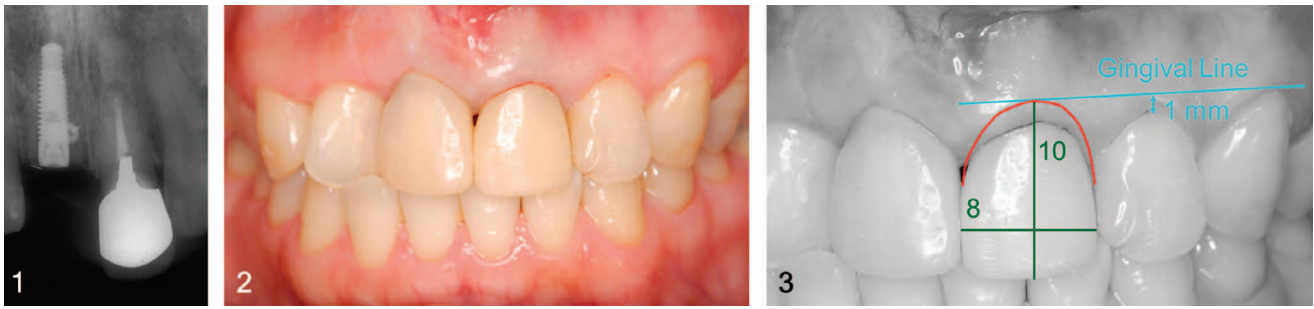
First, MIECL was performed at the left incisor. Following administration of local anesthetic, an intrasulcular incision was made on the labial surface using a No. 15c surgical blade (315c-B, Kai Corporation, Tokyo, Japan) (Figure 4a). The crestal bone position of the patient was verified using a periodontal probe (PCP118, Hu-Friedy Mfg Co, Chicago, Ill) (Figure 4b). In this case, the preoperative biologic width (the total distance from the gingival crest to the alveolar crest) was 3 mm. Since the location

¹ Division of Periodontology, Department of Oral Biology & Tissue Engineering, Meikai University School of Dentistry, Saitama, Japan.

² Section of Periodontics, University of California – Los Angeles, School of Dentistry, Los Angeles, Calif.

* Corresponding author, e-mail: hayashi@dent.meikai.ac.jp

DOI: 10.1563/aaid-joi-D-14-00065



FIGURES 1–3. **FIGURE 1.** Radiograph of the maxillary incisors. After the maxillary right central incisor was extracted, an implant fixture was placed. **FIGURE 2.** Six months after second-stage implant surgery, the marginal gingiva between the marginal tissues of implant and left incisor appeared to be asymmetric. **FIGURE 3.** The desired marginal line (red line) was planned based on the gingival line (blue line) and width-to-length ratio of the crown (green line).

of the gingival margin may change after MIECL, the top of the abutment was set as the reference point to determine the location of the alveolar crest. The distance from the top of abutment to the alveolar crest was 11 mm. A standard rigid periodontal curette (Gracey curettes, Hu-Friedy) was then inserted into the gingival crevice and extended over the osseous crest, and 1 mm of labial crestal bone was resected (Figure 4c).

To produce a scalloped gingival margin, gradualization of marginal bone was performed by the periodontal curette. A periodontal probe was used to verify whether the distance from the top of abutment to the osseous crest was 12 mm as planned (Figure 4d). Apical positioning of the gingival margin was observed just after the treatment (Figure 5a and b), and the level of the margin remained stable for a month (Figure 5c).

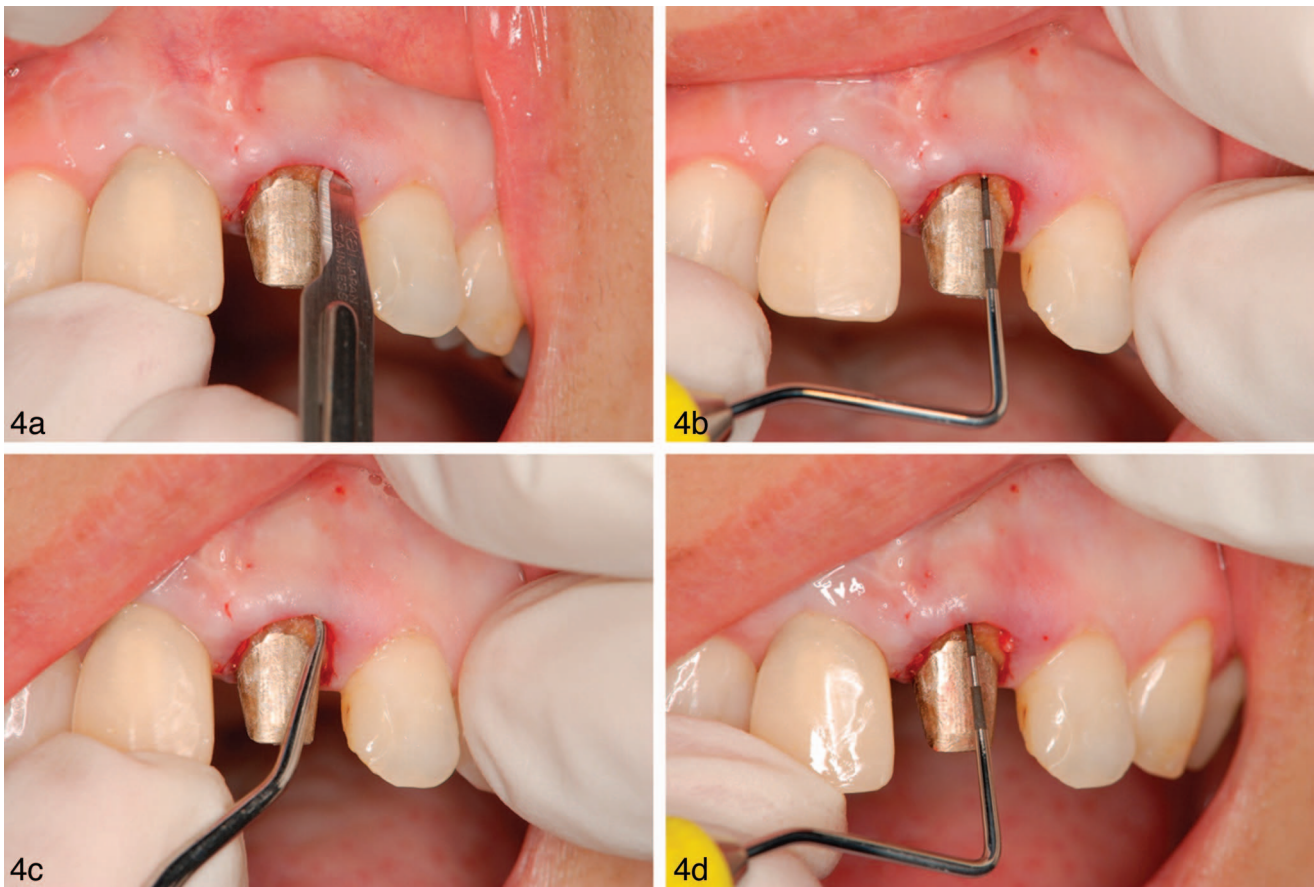
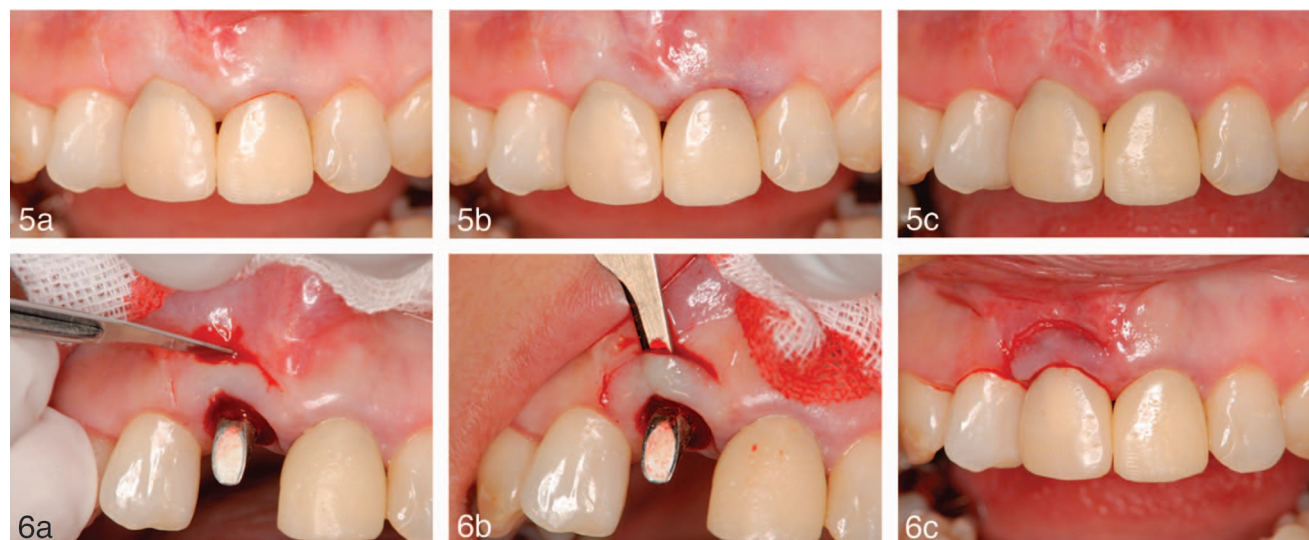


FIGURE 4. Minimally invasive esthetic crown lengthening (MIECL) was performed at the left incisor. (a) Following administration of local anesthetic, an intracutaneous incision was made using a No. 15c scalpel blade. (b) The preoperative biologic width parameters and crestal bone position of the patient were verified using a periodontal probe. (c) A periodontal curette was inserted into the gingival crevice and extended over the osseous crest, and 1 mm of bone was resected. (d) The distance from the top of abutment to the osseous crest was confirmed using the periodontal probe. The distance increased from 11 mm to 12 mm after MIECL.



FIGURES 5–6. **FIGURE 5.** (a) Photograph taken before minimally invasive esthetic crown lengthening (MIECL). (b) Photograph taken immediately after MIECL was performed. (c) Photograph taken 1 month postoperatively. **FIGURE 6.** Procedure of semilunar coronally positioned flap (SCPF). (a) A semilunar incision was made along the curvature of the receded gingival margin ending 2 to 3 mm short of the tip of the papillae. (b) A partial-thickness dissection was performed coronally from the incision and connected to the sulcus. (c) The tissue collapsed coronally. It was then held in its new position for a few minutes with moist gauze. Photograph taken immediately after SCPF.

Next, SCPF was performed at the implant a month after the MIECL. A semilunar incision was made along the curvature of the receded gingival margin, ending 2 to 3 mm short of the tip of the papillae using the No. 15c surgical blade (Figure 6a).¹⁷ A partial-thickness dissection was performed coronally from the incision and connected to the sulcus (Figure 6b). The tissue was placed coronally. It was then held in its new position for a few minutes with moist gauze (Figure 6c). There was no need to suture or to pack. Healing was rapid and uneventful (Figure 7a and b). The gap at the marginal level healed without complication.

Clinically, the surgeries resulted in satisfactory outcomes, with marginal tissues framing the implant and the left incisor in a harmonious manner. After 3 months, the definitive superstructure for the implant and crown restoration for the incisor were placed (Figure 8a). The embrasure space between the implant and the incisor was completely filled by papilla (Figure 8b). The soft tissue around the implant and the incisor has remained stable for 3 years.

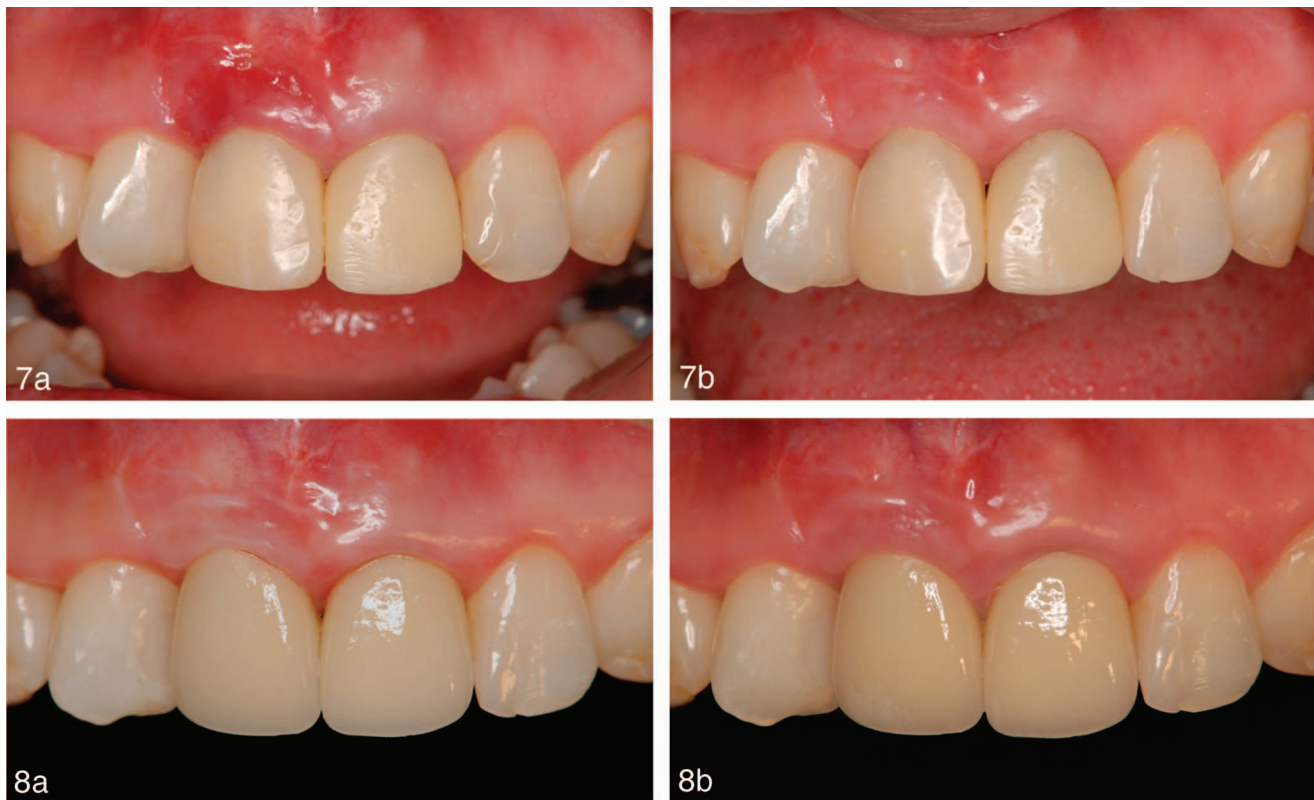
DISCUSSION

The present report appears to be the first to demonstrate the applicability of SCPF in implant dentistry. The advantage of pedicle flap over free soft tissue grafts is the retention of flap vascularity. Pedicle flap of SCPF can be performed by a partial-thickness dissection. Despite a high success rate in achieving root coverage, the coronally advanced flap requires periosteal and vertical releasing incisions for tension-free flap mobilization.¹¹ This may result in the shallowing of the vestibule and, depending on the gingival phenotype, scarring of the vertical incisions that could detract from the esthetics. The decision to use the SCPF

technique depended on factors related to the height and class of gingival recession, and the width and thickness of the keratinized tissue. This procedure has been successful in covering gingival recessions with a maximum height of 4 mm and a minimum of 2 mm of keratinized tissue.⁹ With regard to the postoperative period, SCPF was confirmed as a painless technique for root coverage; the discomfort reported in other procedures is greater because of pain related to the donor area.⁹ However, the use of SCPF in anterior teeth or implants is not recommended for patients with a high smile line because the persistence of small white scars can compromise the esthetic result.

In general, the overlying gingival tissue is influenced by the contours of the underlying osseous structure, thus maintaining the biologic width.^{18,19} The distance between the gingival margin and the osseous crest measures about 3 mm in most healthy adult patients.²⁰ In this case, we found a 3 mm distance at the labial surface of the left incisor. This meant that we had to remove 1 mm of bone to lengthen the crown of the incisor by 1 mm. In MIECL, bone is removed while gingival soft tissue is left intact.

Even though the MIECL technique is relatively simple, the advantages of this procedure are numerous. First, it is a minimally invasive technique that can be performed much faster than traditional methods, requiring no flap elevation or sutures. Postoperative pain is extremely rare, and no significant inflammation occurs during the shorter healing phase; thus, analgesics or antibiotics are seldom necessary. In addition, MIECL does not cause gingival scarring, as often occurs when vertical incisions are used. Second, it is easy to control the marginal level of labial gingiva without changing the interdental marginal gingiva. Third, it takes less time to place the final restoration. Actually, the labial margin of



FIGURES 7–8. **FIGURE 7.** (a) Photograph taken 4 days after the semilunar coronally positioned flap (SCPF). (b) Photograph taken 1 month postoperatively. Note the marginal tissues framing the implant and the left incisor in a harmonious manner. **FIGURE 8.** (a) The definitive superstructure and crown restoration were installed 3 months after the SCPF. (b) Photograph taken 3 years after SCPF.

gingiva was apically positioned just after the treatment in this case (Figure 5) and remained stable during 3 years of observation without rebound of gingiva (Figure 8). Therefore, it may be possible to determine the final gingival margin during the treatment. MIECL is used where crown lengthening is not necessary for palatal areas. Minor correction of facial gingival margin, as shown in this case, is an indication for the option to use this technique.

While these techniques are relatively simple to perform, it is important to recognize that clinical skills and careful soft tissue management are essential. In addition, the recurrence of gingival margin asymmetry can occur again if the patient does not understand the etiology of gingival recession, for example, traumatic brushing habits. Additional cases and longer postoperative evaluations are necessary to confirm the stability and long-term benefit of these surgical techniques.

CONCLUSION

SCPF may be available to correct apically located marginal soft tissues not only in natural teeth but also in implants. MIECL makes it possible to achieve the desired free gingival margin position of the labial surface without changing the interdental marginal gingiva in a short healing period in maxillary anterior teeth. Either SCPF or MIECL—or a combination of these—may be useful minimally invasive surgical approaches to correct

minor marginal soft tissue discrepancy around implants and natural teeth in the esthetic areas.

ABBREVIATIONS

SCPF: semilunar coronally positioned flap
MIECL: minimally invasive esthetic crown lengthening

ACKNOWLEDGMENT

The authors thank Dr Perry R. Klokkevold, Section of Periodontics, University of California – Los Angeles, School of Dentistry, Los Angeles, Calif for reviewing this manuscript.

REFERENCES

1. Cosyn J, Eghbali A, De Bruyn H, Dierens M, De Rouck T. Single implant treatment in healing versus healed sites of the anterior maxilla: an aesthetic evaluation. *Clin Implant Dent Relat Res*. 2012;14:517–526.
2. Raes F, Cosyn J, Crommelinck E, Coessens P, De Bruyn H. Immediate and conventional single implant treatment in the anterior maxilla: 1-year results of a case series on hard and soft tissue response and aesthetics. *J Clin Periodontol*. 2011;38:385–394.
3. Small PN, Tarnow DP. Gingival recession around implants: a 1-year longitudinal prospective study. *Int J Oral Maxillofac Implants*. 2000;15:527–532.
4. Henriksson K, Jemt T. Measurements of soft tissue volume in

association with single implant restorations: a 1-year comparative study after abutment connection surgery. *Clin Implant Dent Relat Res*. 2004;6:181–189.

5. Zuhr O, Bäumer D, Hürzeler M. The addition of soft tissue replacement grafts in plastic periodontal and implant surgery: critical elements in design and execution. *J Clin Periodontol*. 2014;41(suppl 15): S123–142.

6. Kuis D, Sciran I, Lajnert V, et al. Coronally advanced flap alone or with connective tissue graft in the treatment of single gingival recession defects: a long-term randomized clinical trial. *J Periodontol*. 2013;84:1576–1585.

7. Lee YM, Kim DY, Kim JY, et al. Peri-implant soft tissue level secondary to a connective tissue graft in conjunction with immediate implant placement: a 2-year follow-up report of 11 consecutive cases. *Int J Periodontics Restorative Dent*. 2012;32:213–222.

8. Tarnow DP. Semilunar coronally repositioned flap. *J Clin Periodontol*. 1986;13:182–185.

9. Bittencourt S, Del Peloso Ribeiro E, Sallum EA, et al. Comparative 6-month clinical study of a semilunar coronally positioned flap and subepithelial connective tissue graft for the treatment of gingival recession. *J Periodontol*. 2006;77:174–181.

10. Bittencourt S, Ribeiro Edel P, Sallum EA, Sallum AW, Nociti FH, Casati MZ. Semilunar coronally positioned flap or subepithelial connective tissue graft for the treatment of gingival recession: a 30-month follow-up study. *J Periodontol*. 2009;80:1076–1082.

11. Santana RB, Mattos CM, Dibart S. A clinical comparison of two flap designs for coronal advancement of the gingival margin: semilunar versus coronally advanced flap. *J Clin Periodontol*. 2010;37:651–658.

12. Hempton TJ, Dominici JT. Contemporary crown-lengthening therapy: a review. *J Am Dent Assoc*. 2010;141:647–655.

13. Pontoriero R, Carnevale G. Surgical crown lengthening: a 12-month clinical wound healing study. *J Periodontol*. 2001;72:841–848.

14. Brägger U, Lauchenauer D, Lang NP. Surgical lengthening of the clinical crown. *J Clin Periodontol*. 1992;19:58–63.

15. Lanning SK, Waldrop TC, Gunsolley JC, Maynard JG. Surgical crown lengthening: evaluation of the biological width. *J Periodontol*. 2003;74:468–474.

16. Cohen ES. Esthetic structural analysis. In: Cohen ES, ed. *Atlas of Cosmetic and Reconstructive Periodontal Surgery*. 3rd ed. Hamilton, ON: BC Decker; 2007:223–238.

17. Sorrentino JM, Tarnow DP. The semilunar coronally repositioned flap combined with a frenectomy to obtain root coverage over the maxillary central incisors. *J Periodontol*. 2009;80:1013–1017.

18. Gargiulo AW, Wentz FM, Orban B. Dimensions and relations of the dentogingival junction in humans. *J Periodontol*. 1961;32:261–267.

19. Spear FM, Cooney JP. Restorative interrelationships. In Newman MG, Takei HH, Klokkevold PR, Carranza FA, eds. *Carranza's Clinical Periodontology*. 12th ed. St Louis, Mo: Elsevier Saunders; 2015:652–657.

20. Kois JC. Altering gingival levels: the restorative connection, part I: biologic variables. *J Esthet Dent*. 1994;6:3–7.