

Mini Implants Supporting Fixed Partial Dentures in the Posterior Mandible: A Retrospective

Dennis Flanagan, DDS, MSc

Small-diameter, or mini, dental implants have been successfully used to support removable and fixed oral prostheses. These implants impart about twice the per-square-millimeter force on the supporting bone and this should be addressed during treatment planning. In the posterior jaws, bite forces are of a higher magnitude than in the anterior jaws and may induce an overload of the supporting bone and failure of the osseointegration. Thus there should not be occlusal contact in functional excursions that induce off axial loads. The cases presented herein demonstrate that mini dental implants may be used successfully to support fixed partial dentures in mandibular sites in highly selected patients. Attention should be given to the bone density of the site, very slow seating rotation of the implant with intermissions or cooling during insertion, observation of a 4-month healing time, flapless placement, treatment of any existing periodontitis, an insoluble cement, and exclusion of occlusal contact in functional excursions. Importantly, a narrow, rounded occlusal table should be used to minimize off axial loads and an insoluble luting cement should be used to prevent loosening of the crowns due to dissolution of the cement and an overload of the retained implant with any residual cement-retained in the retainer. The implant that supports the cement retained retainer will be subjected to leveraged rotation that may destroy the osseointegration and result in exfoliation of the implant.

Key Words: dental implant, thermal, blood supply, mini implant, small diameter implant, narrow diameter implant, osseous support

INTRODUCTION

Mini or small-diameter dental implants (<3.2 mm) have been used successfully for many years.^{1,2} Probably most of these have been used to retain removable partial and complete dentures. Nevertheless, many clinicians use mini implants to support fixed complete and partial dentures. There have been no long-term randomized blinded controlled trials of this treatment or a failure rate established. Many patients have site conditions, or medical or psychological conditions that preclude the use of standard-diameter implants (>3.25 mm). These patients may not be able to undergo augmentation procedures or they may object to a larger metallic foreign body being placed in the jaw. Economics may be an issue as well. Mini implants may be placed in many of these patients without substantial augmentation procedures and surgical trauma may be much less. In addition, the cost of mini implant surgery is substantially less than standard diameter implants.³

Some clinicians may feel comfortable using mini implants to support fixed partial dentures in the posterior mandible. The posterior mandible has a higher occlusal load magnitude with multidirectional cyclic loading. This subjects the bone-implant-prosthesis complex to more severe loading conditions than in anterior sites. This may affect the longevity of the treatment outcome so treatment planning for this parameter is of paramount importance.

The object of this effort is to demonstrate that in highly

selected cases with appropriate prosthetic design and osseous support, mini implants may be successfully used to support fixed partial dentures in the mandible.

CASE SERIES

Fifty-eight patients were treated with 144 mini implants supporting 1, 2, 3, and 4 unit fixed cemented crowns or partial dentures beginning on March 7, 2006 through May 13, 2010 (Tables 1, 2, 3, 4). One patient, #48-49, was treated bilaterally. Six patients died and 3 were not available. A total of 132 mini implants were considered in the remaining patients. All were placed by 1 operator (DF) in 1 private dental practice in eastern Connecticut. All patients had medical, economic, psychological, and or attenuated site reasons that made standard diameter implants not an option for treatment. All implants were small diameter ranging from 2.0-3.0 mm manufactured by Imtec (Irvine, Calif), IntraLock (Boca Raton, Fla), or Biohorizons (Birmingham, Ala). All prosthetics were single crowns, 2, 3, or 4 splinted prosthetic units fabricated in porcelain fused to noble alloy (PFM) by a commercial dental laboratory (York Dental Lab, Branford, Conn). All implants were placed in healed, partially edentulous sites. Prosthetic design included a very narrow, rounded, occlusal table, less than premolar dimensions, with absolutely no occlusal contact in functional excursions (Figures 1 and 2). Esthetic compromises were accepted preoperatively by all patients. All prostheses were made with a flat narrow rounded occlusal table with little artistic anatomical recreation by the technician. The laboratory technician was instructed to place 3 coats of die separator to ensure a passive fit and account for the expansion and

Private practice, Willimantic, Conn.

Corresponding author, e-mail: dffdds@comcast.net

DOI: 10.1563/AAID-JOI-D-14-00081

TABLE 1

Forty-nine patients in 50 cases were treated. Most implants were successfully functioning for a documented average of 5.5 years

Mini Implants											
	Name	Site #	Date Placed	Date CN's Placed	Last-Seen Date	Success or Failed	Retreat Date	Opposing Dentition	# of Implants	Cement Used	Total Months
1	SC	29	2/10/2006	10/5/2007	3/19/2009	Success	-----	N.T.	1	Zinc	37
2	SG	30	6/23/2008	3/20/2009	9/20/2013	Success	-----	N.T.	2	Fuji	62
3	SB	19-21	4/16/2010	1/24/2011	3/2/2011	Success	-----	N.T.	4	Fuji	10
4	CM	30	3/17/2008	9/28/2008	9/21/2011	Success	-----	N.T.	2	Fuji	42
5	EG	18-20	4/23/2007	4/8/2009	1/22/2014	Success	-----	N.T.	4	Fuji	80
6	RF	30	7/23/2007	8/27/2008	1/20/2014	Success	-----	N.T.	2	Fuji	77
7	EG	18, 19	1/17/2007	2/27/2008	2/6/2012	Success	-----	N.T.	3	Fuji	60
8	VM	30	12/6/2006	4/11/2007	10/9/2013	Success	-----	N.T.	2	Zinc	82
9	PB	19	8/2/2006	5/22/2007	12/6/2013	Cement failure	1/31/2007	N.T.	2	Zinc/Zinc	88
10	ER	18-20	2/4/2008	2/4/2009	10/23/2013	Success	-----	N.T.	3	Fuji	68
11	TB	30-32	6/4/2007	3/19/2008	9/30/2013	Success	-----	N.T.	4	Fuji	75
12	CS	19	12/1/2006	4/27/2007	11/26/2013	Success	-----	N.T.	2	Zinc	83
13	MK	17-19	9/15/2008	3/30/2009	8/22/2013	Success	-----	N.T.	4	Fuji	59
14	LL	30-32	12/13/2006	8/27/2007	12/30/2013	Success	-----	N.T.	4	Zinc	84
15	JP	30	12/18/2006	10/9/2007	7/31/2013	Success	-----	N.T.	2	Zinc	79
16	JL	19	11/10/2006	4/6/2007	10/8/2013	Success	-----	N.T.	2	Zinc	82
17	RP	28-31	9/27/2006	8/27/2007	12/22/2011	Success	-----	F/	4	Zinc	62
18	RM	28-31	10/4/2006	8/27/2008	12/30/2013	Success	-----	Implants	4	Temrex	86
19	RD	19	10/6/2006	6/27/2007	12/13/2013	Success	-----	N.T.	2	Zinc	86
20	JP	30	7/21/2006	1/29/2007	10/31/2007	Success	-----	N.T.	2	Zinc	11
21	JC	18-20	7/10/2006	3/30/2007	5/14/2008	Success	-----	N.T.	4	Zinc	22
22	TS	17-19	6/23/2006	6/18/2007	11/8/2010	Success	-----	N.T.	4	Zinc	52
23	RJ	19, 20	10/15/2007	4/30/2008	6/3/2008	Success	-----	N.T.	3	Zinc	7
24	AO	19	11/8/2006	5/14/2007	12/4/2013	Success	-----	N.T.	2	Zinc	84
25	MB	29-31	12/11/2006	6/18/2007	9/25/2013	Success	-----	F/	4	Zinc	81
26	GV	18, 19	12/20/2006	8/8/2007	12/6/2013	Success	-----	N.T.	3	Zinc	83
27	LC	18, 19	3/18/2008	8/28/2008	7/15/2013	Success	-----	N.T.	4	Fuji	63
28	EM	18-20	8/22/2006	6/5/2007	10/5/2010	Failed intregation	7/24/2007	N.T.	4	Zinc/Fuji	49
29	JS	19	1/30/2007	8/16/2007	10/17/2013	Success	-----	N.T.	2	Zinc	80
30	LH	19, 20	1/10/2006	3/15/2007	2/21/2013	Cement failure	10/12/2006	N.T.	3	Zinc/Fuji	85
31	RP	19	9/21/2006	7/31/2007	7/12/2012	Success	-----	N.T.	2	Zinc	69
32	MS	30-32	9/21/2006	12/29/2009	12/23/2013	Cement failure	7/7/2009	N.T.	4	Zinc/Fuji	87
33	RK	30-32	5/4/2006	9/26/2006	12/4/2012	Success	-----	N.T.	4	Zinc	79
34	SM	28-30	5/30/2006	1/4/2007	11/11/2010	Success	-----	F/	4	Zinc	53
35	BM	19	3/23/2006	8/10/2006	12/6/2013	Success	-----	N.T.	2	Zinc	92
36	DS	30	10/10/2008	7/31/2009	3/15/2013	Success	-----	N.T.	2	Fuji	53
37	JH	21	6/4/2007	11/20/2007	1/31/2014	Success	-----	N.T.	1	Zinc	79
38	RS	19	1/5/2007	5/5/2008	6/13/2013	Success	-----	N.T.	2	Fuji	77
39	MS	19	10/4/2006	4/18/2007	2/2/2011	Success	-----	N.T.	2	Zinc	51
40	JC	18, 19	9/1/2006	3/23/2007	11/27/2013	Success	-----	N.T.	4	Zinc	86
41	GW	18-20	7/17/2006	5/16/2007	8/3/2013	Success	-----	N.T.	4	Zinc	84
42	PS	28-30	6/16/2006	12/6/2006	2/18/2011	Success	-----	N.T.	4	Zinc	56
43	PS	18-19	6/16/2006	12/6/2006	2/18/2011	Success	-----	N.T.	4	Zinc	56
44	YG	29-31	10/26/2006	6/5/2007	12/17/2013	Success	-----	N.T.	4	Fuji	85
45	SR	30	8/1/2006	1/23/2007	12/9/2013	Success	-----	N.T.	2	Zinc	88
46	BR	29-31	6/27/2006	12/21/2006	8/12/2008	Success	-----	N.T.	4	Zinc	25
47	LC	29-32	5/1/2007	12/13/2011	11/13/2013	Cement failure	5/17/2011	N.T.	4	Zinc/Fuji	78
48	RG	19	3/6/2006	12/6/2007	7/24/2012	Success	-----	N.T.	2	Zinc	76
49	RG	30	3/6/2006	12/6/2007	7/24/2012	Success	-----	N.T.	2	Zinc	76
50	JR	30	6/9/2006	1/12/2007	1/15/2014	Success	-----	F/	2	Zinc	91

Downloaded from http://meridian.allenpress.com/doi/pdf/10.1563/AID-JOI-D-14-00081 by guest on 18 August 2022

contraction of the impression material (Implant, 3-M ESPE) and polyurethane die material (PolyDie, Guilford, Conn). All implants were surgically placed using facial and lingual infiltration local anesthesia using 1.6 cc lidocaine (Xylocaine, York, Pa) or articaine (Septocaine, Lancaster, Pa). No sites were augmented with gingival or osseous graft material. All sites were deemed to have an adequate 2 mm minimum zone of keratinized tissue. All impressions were made with closed tray polyvinyl siloxane

(Imprint, 3-M-ESPE). All prosthetics were cemented with zinc oxide eugenol (Temrex, Free Port, NY), zinc phosphate (Fleck's, Gibbstown, NJ) or resin-modified glass ionomer cement (FujiCEM, GC America, Alsip Ill), mixed to the manufacturers' specifications. The cements were placed in each crown retainer in very small increments with a periodontal probe to prevent void formation due to the surface tension of the cement. All opposing dentition was adjusted so that no contact was

TABLE 2

A total of 56 patients were treated with posterior mini implant-supported fixed 1, 2, 3, or 4 unit partial dentures. Areas treated included all molar and premolar sites, including third molar sites although splinted. Four patients died and 2 could not be reached by phone or postal. A total of 132 implants were considered in the surviving patients

Number of Patients	Number of Implants in the Case
2	1
23	2
6	2
6	3
18	3
3	4
56 Total	

allowed in working or balancing excursions. All cases were tooth bound at the mesial and distal. In maximum intercuspation approximately 100 microns of occlusal relief as measured by shim stock was provided. This prevents the prosthesis and or implants from bearing the total occlusal load due to intrusion of the adjacent natural teeth under function. All patients were instructed in oral hygiene and maintenance. All patients were satisfied with the long-term function of the prosthetics. Since the sites were all in what was considered a non esthetic zone by the patients, they were satisfied with their esthetic and functional outcomes.

RESULTS

Ninety-two percent of the placed implants functioned for an average of 5.5 years (Tables 1 through 4). Four partial dentures loosened after cement failure. Two of these were recemented with a resin-modified glass ionomer and 2 were recemented with zinc phosphate. One case, #47, had an early fail to integrate. This case was treated by re-implantation and subsequent prosthetic fabrication. Of 50 cases in 49 patients a total of 46 cases were successfully functional. This results in a 92% success rate over several years. This is below the reported rates of standard diameter implant treatment.⁴ Nevertheless, the 4 cement failures were easily recemented except in one case in which a fractured implant was retrieved and revision treatment instituted. All of the cement failures were caused by apparent dissolution of zinc phosphate cement. These were recemented with resin-modified glass ionomer (FujiCEM). The earliest cement failure occurred at 9 months. The average time of successful function was 5.5 years confirmed by appointed evaluation and this is ongoing. All of the implants are still in function for the foreseeable future.

TABLE 3

Most implants were 2.0 and 3.0 mm in diameter

Implant Diameter mm	Number Placed
2.0	79
2.5	7
3.0	46

TABLE 4

Most implants that were placed were less than 13 mm in length due to proximity of the mandibular canal

Implant Length mm	Number Placed
10	68
11.5	40
12	18
13	6

No calibrated radiographs were taken at the time of placement so subsequent radiographs have no baseline from which to measure. Nevertheless there appears to be slight or no bone loss at any of the implants.

DISCUSSION

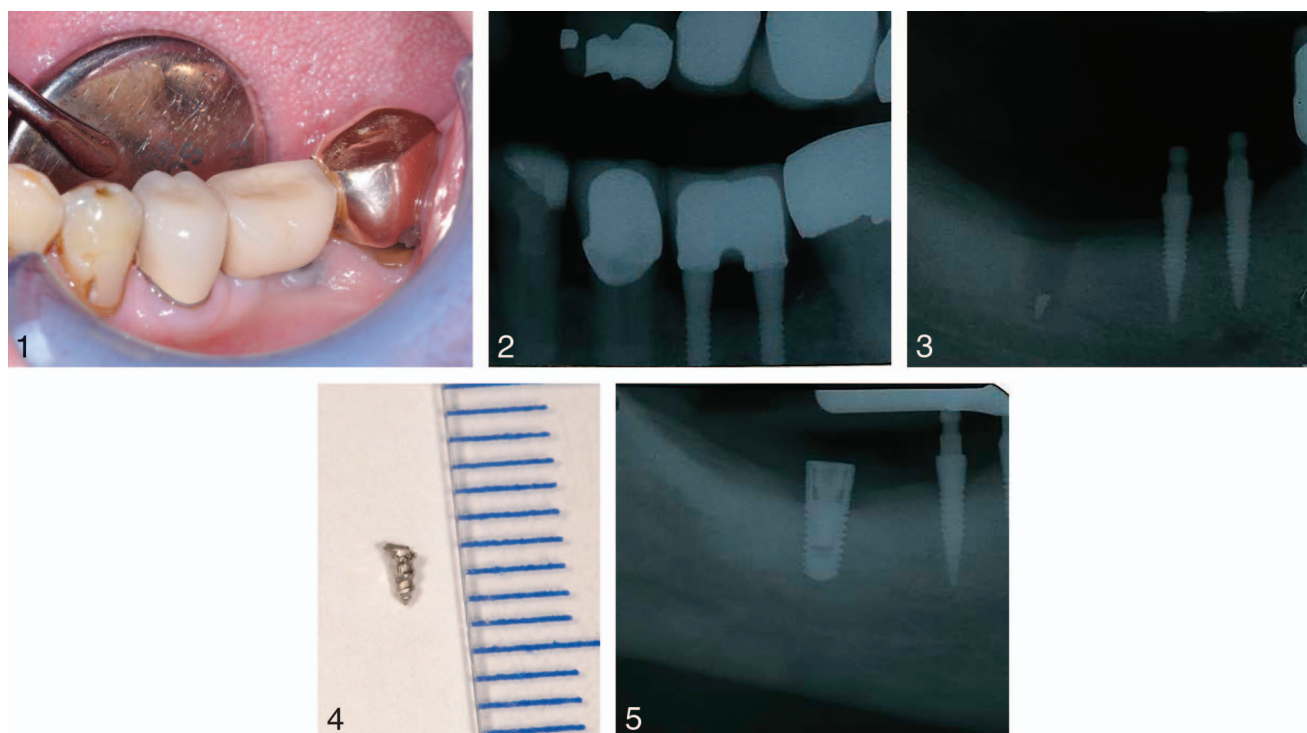
Many patients who present for treatment may not be candidates for standard-diameter implants for a variety of reasons. Some of these patients may be candidates for mini implant fixed partial denture treatment when the osseous density is adequate and the jaw bite force is not excessive.⁵ Medically compromised and very elderly patients may have cogent reasons for mini implant treatment. Economics may play a part since costs may be much less with mini implants.

Mini implants used in the anterior jaws to support single crowns and fixed partial dentures do not bear a relatively high magnitude of load.^{1,6} However, in the anterior maxilla, the loads are off axial and transferred to the facial and lingual bone. These facial and lingual cortices should be substantial to resist the imparted loads. Generally a 1.8-mm minimum may be an adequate thickness cortical.⁷ Occlusal forces that are axially directed may not expose the bone surrounding the implant to a substantial load under cyclic loading conditions.⁸ The bone that supports mini implants takes on about twice the off-axial load that is delivered by standard diameter implants so this needs to be considered preoperatively.^{9,10}

A removable complete maxillary denture develops much less magnitude of force in the jaws as compared to natural tooth dentition. Since this load is much less, these patients may be able to be treated with mini implant supported fixed partial dentures in the posterior mandible. These prostheses may be successful for many years. However, patients with maxillary opposing natural teeth generate a much greater force. This much higher magnitude of force (especially in the posterior jaws) must be addressed if mini implants are used to support fixed prosthetics. While the force magnitude cannot be controlled by the clinician, prosthetic design can minimize the forces placed on the implant-prosthetic complex. The cases in this series were designed with flat, rounded, very narrow occlusal tables that were less than the width of adjacent premolars.¹ This design minimizes off axial loads and thus the transfer to the facial and lingual cortices.

The bone is the ultimate bearer of occlusal loads. It may be that mini implants should only be placed in type 1 or 2 (Misch) bone to ensure appropriate osseous resistance to occlusal loading.¹

As an edentulous ridge ages, the facial cortex approaches



FIGURES 1–5. **FIGURE 1.** The crowns and fixed partial dentures were fabricated with a very narrow occlusal table to minimize off-axial loads. **FIGURE 2.** A recent radiograph demonstrates little or no bone loss. No graduated operative radiographs were made so bone loss measurements could not be made. **FIGURE 3.** The distal abutment retained a cement purchase and fractured after the mesial abutments lost their cement retention. **FIGURE 4.** The apical fragment was retrieved. **FIGURE 5.** A larger diameter implant was placed after a ridge expansion.

the lingual cortex. When they become very close or coalesce, the site then becomes a type 1 bone (Misch) site that would be very supportive. Nevertheless, adequate facial and lingual bone thickness is needed for support. Type 3 and 4 (Misch) bone types may not adequately resist occlusal loads, or allow micromovement, and could result in a loss of integration and exfoliation of the implant.¹

An implant site may have atrophic bone that limits the site width that may preclude standard diameter implants without augmentation.¹ Additionally, adjacent natural teeth can drift into the edentulous space encroaching on the site that reduces the available site length. Without orthodontic treatment this may preclude the use of standard diameter implants.

Torque seating force should be at least 32 newton centimeters (Ncm) for these types of cases to ensure adequate resistance during healing.¹ The implant threads may engage the facial and lingual cortices for adequate support and initial stability.¹

Parallel placement is important for design and fabrication of the definitive prosthesis. Laboratory technical fabrication is made easier if the abutments are parallel. A passive fit should be attained by instructing the technician to apply 3 coats of die separator on the working cast.¹

Flapless implant placement may be less traumatic and disruptive as compared to gaining access to the bone with a mucogingival flap. A flapless approach maintains the periosteum and its blood supply and may prevent substantial bone loss. In the anterior mandible the periosteum is the major blood

supplier emanating from the facial artery and if disrupted may result in bone loss.¹¹

A 2-mm minimum zone of attached tissue is needed to protect the implant gingival margin from muscle pulls that may disrupt the attachment and allow bacterial invasion and subsequent bone loss.¹ This zone can be augmented pre, intra or postoperatively with an apically positioned gingival flap, free gingival graft, lateral pedicle graft or porcine xenograft, or dermal allograft. The small diameter of these implants does not encroach on any minimal attached gingival band and thus reduces the need for an augmentation. A larger diameter implant may encroach on remaining gingiva necessitating an augmentation.

Treatment of existing periodontitis should be done to prevent the potential for bacterial inoculation and colonization of the mini implants.¹²

While mini implants can be immediately loaded with a removable denture, fixed dentures may impart an overload to the integrating implants and cause a micromovement that may abort osseointegration.¹ Bone remodeling occurring at the second to fourth postoperative week causes a decreased resistance to load. A minimum of 4-month healing period may need to be observed, nevertheless, this has not been well studied.

After a few years of function in this series, a few prostheses dislodged due to zinc phosphate or zinc oxide eugenol cement dissolution. The crowns were cleaned and recemented with insoluble resin modified glass ionomer cement (FujiCEM, 3M

ESPE) and have been in uneventful service since. The cement failure was treated by cleaning the prosthesis with sodium hypochlorite, rinsing with water and recementing with a resin-modified glass ionomer (FujiCEM, 3M ESPE). Resin-modified glass ionomer luting cement is insoluble and may not dissolve in functional loads.¹³ When implants were lost, each site was evaluated and revision treatment was instituted after a discussion with the patient. Only multiple unit prosthetics had cement failures.

One 4-unit case dislodged (Figures 3 through 5) after several years of function due to dissolution of the zinc phosphate cement. Two retainers loosened and created a rotation of the fixed partial denture on the remaining cemented retainer/implant causing a loss of integration and exfoliation of the prosthesis and implant. The loosened retainer caused a fracture of an implant apex (Figures 3 through 5). Zinc phosphate is slightly soluble and may dissolve if the fit of the retainer margin is not a perfect seat seal against the implant cervical margin, which practically may not occur.¹⁴

Since mini implants place about twice the force on the embedding bone the load imparted should be minimized to prevent a microluxation of the implant in the bone.^{9,10} The implant-bone interface may be disturbed and microscopically bleed at the interface. Microhemorrhage may then cause fibrosis and loosening of the implant/s. Off-axial microstrains range between a multiple of 1.5–2.5 times those imparted on standard diameter implants.⁹ Thus off-axial loading should be minimized by the occlusal design.⁹ Since the per-square-mm of osseous load is much greater with mini implants this phenomenon must be addressed in the prosthetic design in order to prevent an occlusal overload and subsequent failure.

A longer implant length may be used to ensure long-term function although many cases with 10-mm length implants seem to fare well. While implant length does not contribute greatly to force distribution any additional implant surface can distribute the load over as much implant-bone interface as possible.¹

Metal fatigue of the coronal portion of the mini implants did not occur since no implants fractured during the years of function. Flanagan and coworkers found that mini implants placed in a vise and subjected to a horizontal 200-newton cyclic load generally fractured after 1 million cycles.⁸ This may indicate that fatigue fracture may occur from off-axial loads, but when minimized by prosthetic design, it may not be clinically significant.

The percutaneous portion of mini implants is much less than standard sized implants and thus presents less of an opportunity for coronal epithelial attachment issues. The circumference ($\pi \times \text{diameter}$) of a 2.5-mm mini implant is 7.85 mm as compared to a standard-sized implant (4.0 mm) at 12.56 mm, which is 160% longer. This presents much less of an opportunity for peri-implantitis, but the rate of peri-implantitis in mini implants has not yet been reported.

Detrimental heat may be generated during seating of mini implants in dense type 1 (Misch) bone.¹⁵ An 8°C temperature rise may occur due to friction during seating. Because mini implant volume will not absorb heat generated at the implant bone interface during seating it will dissipate into the surrounding bone and may cause necrosis at the ridge crest.

Thus a very slow seating rotation rate at 1–2 rpm or 12 rpm with waiting periods after each complete revolution may be observed to minimize heat generation. Additionally, water cooling of the fixture may dissipate any heat generation.

The single implants were placed in sites where the distal molar had tipped into the site. Each crown was not in occlusal contact by about 1 mm. This makes them, in effect, space maintainers.

The average time of successful function was 5.5 years. Most patients are seen for routine dental cleanings once or twice annually and evaluated for tissue status. No patients experienced severe bone loss, loss of integration, or peri-implantitis. Cement failure appears to be the primary reason for prosthetic loosening.

CONCLUSIONS

These cases demonstrate that many patients with conditions that may preclude standard diameter implant treatment, may be treated with mini implant-supported fixed partial dentures. This is a highly selective and exclusive group of patients that may qualify for such treatment. Particular care should be given to bone density of the site, observation of a 4-month healing time, flapless placement, use of longer implants than 10 mm, treatment of any existing periodontitis, choice of an insoluble luting cement, exclusion of occlusal contact in excursions, and very slow seating rotation with intermissions and water irrigation during seating. As a retrospective case series this work is a lower level of credibility. More study of occlusal design, materials, and bone resistance physiology is needed to develop this treatment concept.

ACKNOWLEDGMENT

The author acknowledges the assistance of data compilation and chart research by Brittany Ames Mahoney, CDA and the kind and gentle redaction by Danielle Green, DMD.

ABBREVIATION

PFM: porcelain fused to noble alloy

REFERENCES

1. Flanagan D, Mascolo A. The mini dental implant in fixed and removable prosthetics: a review. *J Oral Implantol*. 2011;37:123–132.
2. Shatkin TE, Petrotto CA. Mini dental implants: a retrospective analysis of 5640 implants placed over a 12-year period. *Compend Contin Educ Dent*. 2012;33:2–9.
3. Vojvodic D, Celebic A, Mehulic K, Zabarovic D. Prosthetic rehabilitation of a patient with mandibular resection prosthesis using mini dental implants (MDIs)—case report. *Coll Antropol*. 2012;36:307–311.
4. Javed F, Ahmed HB, Crespi R, Romanos GE. Role of primary stability for successful osseointegration of dental implants: factors of influence and evaluation. *Interv Med Appl Sci*. 2013;5:162–167.
5. Chen XY, Zhang CY, Nie EM, Zhang MC. Treatment planning of implants when 3 mandibular posterior teeth are missing: a 3-dimensional finite element analysis. *Implant Dent*. 2012;21:340–343.
6. Balaji A, Mohamed JB, Kathiresan R. A pilot study of mini implants

as a treatment option for prosthetic rehabilitation of ridges with sub-optimal bone volume. *J Maxillofac Oral Surg.* 2010;9:334–338.

7. Spray JR, Black CG, Morris HF, Ochi S. The influence of bone thickness on facial marginal bone response: stage 1 placement through stage 2 uncovering. *Ann Periodontol.* 2000;5:119–128.

8. Flanagan D, Ilies H, McCullough P, McQuoid S. Measurement of the fatigue life of mini dental implants: a pilot study. *J Oral Implantol.* 2008;34:7–11.

9. Bourauel C, Aitlahrach M, Heinemann F, Hasan I. Biomechanical finite element analysis of small diameter and short dental implants: extensive study of commercial implants. *Biomed Tech (Berl).* 2012;57:21–32.

10. Sallam H, Kheiralla LS, Aldawakly A. Microstrain around standard and mini implants. *J Oral Implantol.* 2012;38:221–229.

11. Flanagan D. Important arterial supply of the mandible, control of an arterial hemorrhage, and report of a hemorrhagic incident. *J Oral Implantol.* 2003;29:65–173.

12. Page LR, Rams TE. Subgingival root brushing in deep human periodontal pockets. *J Int Acad Periodontol.* 2013;15:55–63.

13. Garg P, Gupta G, Prithviraj DR, Pujari M. Retentiveness of various luting agents used with implant-supported prostheses: a preliminary in vitro study. *Int J Prosthodont.* 2013;26:82–84.

14. Del'Acqua MA, Chávez AM, Amaral AL, Compagnoni MA, Mollo Fde A Jr. Comparison of impression techniques and materials for an implant-supported prosthesis. *Int J Oral Maxillofac Implants.* 2010;25:771–776.

15. Flanagan DF. Heat generated during implant seating. *J Oral Implantol.* 2014;40:174–181.