

Platelet-Rich Fibrin in Maxillary Sinus Augmentation: A Systematic Review

Sherif Ali, MSc*

Saleh Ahmed Bakry, PhD

Hesham Abd-Elhakam, PhD

The aim of this study was to systemically assess the efficacy of platelet-rich fibrin (PRF) on maxillary sinus augmentation using the lateral approach. A PubMed search and a hand search of relevant journals and the bibliographies of selected articles were performed. Clinical studies using PRF with open maxillary sinus augmentation were included. The search provided 290 titles; only 8 studies fulfilled the inclusion criteria. Identified studies showed heterogeneity regarding surgical technique, grafting material, implant placement time, protocol, outcome measures, healing time for biopsy, and implant placement, as well as follow-up period. From the 8 identified studies, 3 studies used PRF as a sole filling material, whereas the other 5 studies used PRF with bone substitutes. PRF showed promising results as a sole filling material for sinus lift with simultaneous implant placement, and PRF seemed to accelerate maturation of a demineralized freeze dried bone allograft. Conversely, it had no effect on deproteinized bovine maturation. PRF fibrin membranes represent an easy and successful method to cover the sinus membrane or osteotomy window.

Key Words: dental implants, maxillary sinus lift, platelet-rich fibrin, systematic review

INTRODUCTION

The posterior maxilla represents a unique and challenging site for successful dental implant installation because of its relatively poor bone quality and deficient bone volume caused by ridge resorption and sinus pneumatization.¹⁻³ Reconstruction of posterior maxillary bone volume has been achieved by different procedures, such as onlay grafts, Le Fort I osteotomies with interpositional bone grafting, and sinus lifts.⁴⁻⁹ Maxillary sinus augmentation is considered one of the most predictable procedures that can be performed using different grafting materials, such as autogenous, allograft, xenograft, alloplastic bone, and, recently, platelet concentrates.¹⁰⁻¹⁶

Platelet concentrates were originally used for the treatment and prevention of hemorrhage due to severe thrombopenia. The standard platelet concentrate for transfusion has been named platelet-rich plasma (PRP) and classically contains 0.5×10^{11} platelets per unit.¹⁷⁻¹⁹

Platelet concentrates have been used to improve healing and enhance bone generation by releasing growth factors. Platelets contain high quantities of key growth factors, such as platelet-derived growth factor, transforming growth factor β_1 and β_2 , and vascular endothelial growth factor, which are able to stimulate cell proliferation and enhance angiogenesis.²⁰ A variety of autologous platelet concentrate techniques have been developed. Blood is collected with anticoagulant and processed by centrifugation, and finally the obtained platelet

concentrate is applied with activator to trigger platelet activation and fibrin polymerization. However, all these techniques are expensive and time consuming, and their development in private practice remains quite limited.²¹

In 2001, a new protocol was introduced to concentrate platelets and fibrin in a simpler way without blood modification. Blood is collected and immediately centrifuged without the use of anticoagulant or activator, forming a platelet-rich fibrin (PRF) clot.^{22,23} Unlike other platelet concentrates, PRF does not dissolve quickly after application: platelets and leucocytes are collected with high efficiency and platelets are activated during the process, leading to substantial embedding of platelet and leukocyte growth factors into the fibrin matrix. Another advantage of this method is its low cost and the great ease of the procedure.^{24,25}

Recently, several clinical studies have been performed to evaluate the use of PRF in maxillary sinus augmentation. The aim of this systematic review was to determine the effect of PRF on the graft quality, quantity, and clinical outcome (based on implant survival).

MATERIALS AND METHODS

Search strategy

A search was performed on PubMed electronic database, using the following search terms ("sinus augmentation" OR "sinus lift" OR "sinus floor elevation" OR "sinus graft") AND ("platelet" OR "growth factors").

In addition, a further hand search was performed on the major international journals in the field of implant dentistry, as well as oral and maxillofacial surgery, from 2000 to 2014 (*British*

Oral and Maxillofacial Surgery Department, Faculty of Oral and Dental Medicine, Cairo University, Cairo, Egypt

* Corresponding author, e-mail: sherif.ali@dentistry.cu.edu.eg

DOI: 10.1563/AAID-JOI-D-14-00167

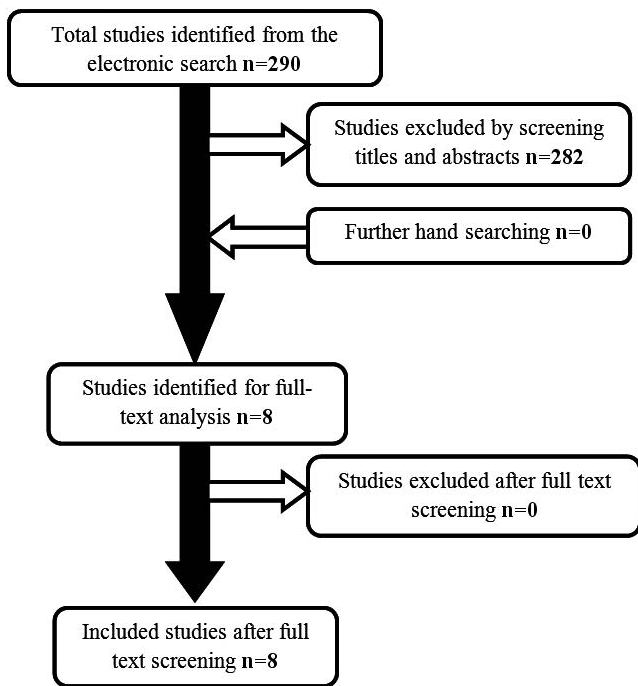


FIGURE. Study selection process.

Dental Journal; British Journal of Oral and Maxillofacial Surgery; Clinical Implant Dentistry and Related Research; Clinical Oral Implants Research; European Journal of Oral Implantology, Implant Dentistry; International Journal of Oral and Maxillofacial Implants; International Journal of Oral and Maxillofacial Surgery; International Journal of Periodontics and Restorative Dentistry; Journal of Clinical Periodontology; Journal of Oral and Maxillofacial Surgery; Journal of Oral Implantology; Journal of Periodontology; Oral Surgery, Oral Medicine, Oral Pathology, Oral Radiology, and Endodontology; and Periodontology 2000). The manual search also included the bibliographies of all articles selected for full-text screening. The last electronic search was performed on November 23, 2014.

Selection criteria

All clinical trials assessing the effect of PRF on sinus augmentation procedures were included. No limitation was placed regarding the number of patients treated. Studies were selected according to the following inclusion criteria: (1) human studies; (2) maxillary sinus lift performed using the lateral approach; (3) PRF used as a grafting material (either as a sole grafting material or in combination with other materials); and (4) treatment outcomes (implant survival or graft quality or volumetric stability) clearly reported by the authors.

Study selection and data extraction

The titles of the retrieved articles were screened, and publications that fulfilled the inclusion criteria were identified. Abstracts of all titles agreed on were obtained and screened for meeting the inclusion criteria. After screening the abstracts, the selected articles were then obtained in full text. If the title and

abstract of an article did not provide sufficient information to make a decision regarding the inclusion criteria, the full text was obtained and examined. Finally, the selection based on inclusion criteria was made for the full-text articles by screening their materials and methods and results. This screening procedure was performed by 2 reviewers.

The included studies were sorted into 2 groups: (1) studies that used PRF as a sole grafting material; and (2) studies that used PRF in combination with bone substitutes.

RESULTS

A total of 290 titles were identified by the electronic literature search. After initial screening of titles and abstracts, irrelevant studies were excluded by the reviewers and a total of 8 articles were selected for full-text screening.^{26–33} No additional articles were found through hand searching. The 8 articles that fulfilled the inclusion criteria were included in the present analysis (Figure). The articles included in this study were published in a period ranging from 2006 to 2013 with 209 sinus lift procedures performed. The selected articles were sorted into 2 groups, and the first group include 3 articles using PRF as the sole grafting material.^{26–28} Although the second group included 5 articles that used PRF in combination with bone substitutes,^{29–33} 4 of these articles used a xenograft as a bone substitute, and only 1 article used an allograft²⁹ (Table 1).

Preparation of PRF

In all studies, venous blood was collected in dry glass or glass-coated plastic tubes without anticoagulant and immediately centrifuged. Centrifugation resulted in the formation of 3 layers: the red blood cell base layer, acellular plasma top layer, and a PRF clot in the middle. The PRF clot was removed from the tube and separated from the red blood cell basal layer. Some clots were cut into fragments or gently compressed to form a membrane. Various centrifugal durations (range, 10–14 minutes) and centrifugal forces were used. All studies used stable speed during centrifugation except the study of Tajima et al,²⁸ which used the following parameters: 30 seconds of acceleration, 2 minutes at 2700 rpm, 4 minutes at 2400 rpm, 4 minutes at 2700 rpm, 3 minutes at 3000 rpm, and 36 seconds to decelerate and stop^{26–33} (Table 1).

PRF as a sole grafting material

PRF was used as a sole filling material in 3 studies.^{26–28} A total of 57 sinus lift procedures were performed and 110 implants were placed in 46 patients. Presurgical radiographic evaluation was performed to assess the residual bone height, where the average height was 2.67 mm (range, 1.5–6.1 mm).

In all studies, sinus lift was performed using the lateral approach, and implants were placed immediately to serve as tent pegs. PRF clots were compressed inside the sinus cavity to fill all of the volume around the implants. In the studies of Mazor et al²⁶ and Simonpieri et al,²⁷ 1 or 2 PRF membranes were placed on the sinus membrane and osteotomy window. Conversely, Tajima et al²⁸ placed no membranes. All the studies performed the stage 2 surgery for abutment placement 6 months postoperatively.^{26–28}

TABLE 1

Studies assessing the effect of platelet-rich fibrin on sinus augmentation procedures*

Reference	No. of Sinuses	No. of Patients	Age (y)	Graft Material	PRF Preparation	No. of Implants	Outcome Measures
Mazor et al ²⁶	25	20	54.1	PRF	400g for 12 min	41 Sm	Implant survival Radiographic bone height Histomorphometric analysis
Simonpieri et al ²⁷	23	20	59.8	PRF	400g for 12 min	52 Sm	Implant survival Radiographic bone height
Tajima et al ²⁸	9	6	67.8	PRF	30-s acceleration, 2 min at 2700, 4 min at 2400, 4 min at 2700, 3 min at 3000, 36-s deceleration	17 Sm	Implant survival Resonance frequency analysis Radiographic bone height Radiographic bone density Radiographic bone volume Histomorphometric analysis
Choukroun et al ²⁹	Test 6 Control 3	N	N	PRF + DFDBA DFDBA	2500 rpm (about 280g) for 10 min	N	Histomorphometric analysis
Inchingolo et al ³⁰	31	23	N	PRF + Bio-oss	3000 rpm for 10 min	95 Sm	Implant survival Radiographic bone density
Zhang et al ³¹	Test 6 Control 5	10	43.5 46.2	PRF + Bio-oss Bio-oss	300g for 10 min	N	Histomorphometric analysis
Tatullo et al ³²	Test 42 Control 30	60	43-62	PRF + Bio-oss Bio-oss	3000 rpm for 10 min	240 Del	Implant survival Resonance frequency analysis Histomorphometric analysis Histologic analysis
Bölükbaşı et al ³³	Test 17 Control 15	25	50.06 47.7	PRF + Bio-oss Bio-oss	400g for 12 min	66 Del	Implant survival Radiographic bone height Histomorphometric analysis Histologic analysis

*Del, implants placed during second stage surgery; DFDBA, freeze-dried bone allograft; N, not reported; PRF, platelet-rich fibrin; Sm, implants placed spontaneously with sinus lift.

No complications were observed during the healing period. In 5.3% of the cases (3 cases), clear sinus membrane perforations were observed and easily patched by PRF membranes. During abutment placement and tightening, the 110 implants placed were clinically stable. The study of Tajima et al²⁸ used an Osstell Mentor device to perform resonance frequency analysis at the time of stage 2 surgery, and the mean implant stability quotient (ISQ) was 66.5 ± 6.15 (range, 57–75 ISQ). Regarding the follow-up period, only the study of Simonpieri et al²⁷ provided a long-term follow-up (2–6 years) for implants, with a 100% survival rate.^{26–28}

Radiographic evaluation was performed by panoramic radiographs or CT scan about 6 months after the sinus lift to evaluate the bone formation in all studies, where the average bone gained was 9.8 mm. In the study of Simonpieri et al,²⁷ the radiographic evaluation was extended from 1 to 6 years, and the vertical bone gained was always substantial and stable. Tajima et al²⁸ determined the density (in Hounsfield units [HU]) and volume of the newly formed bone around the implant: the mean density was 323 ± 156.2 HU (range, 185–713 HU), and the mean volume was 0.70 ± 0.31 mL^{26–28} (Table 2).

Histologic and histomorphometric evaluation was performed by Mazor et al²⁶: they harvested bone biopsies during stage 2 surgery. Histologic evaluation showed well-organized and vital bone with structured trabeculae, dense collagen matrix, easily identified osteoblasts, and osteocytes in the lacunae. In addition, histomorphometric evaluation showed that bone matrix was often more than 30% (mean, 33 ± 5%; Table 2).²⁶

PRF with allograft

PRF was used in combination with demineralized freeze-dried bone allograft (DFDBA) in 1 study.²⁹ Sinus lift using the lateral approach was performed in 9 sinuses. DFDBA granules (Phoenix, TBF, Mions, France) were used to fill 3 sinuses that served as a control group. For the other 6 sinuses, the allograft/PRF mixture was used to fill the sinus, and PRF membranes were used to cover the sinus membrane and osteotomy window. Stage 2 surgery was performed for implant placement, and biopsies were harvested 4 months postoperatively for the test group and 8 months for the control group. Membrane perforation occurred in 1 case, and it was easily patched by PRF membrane.²⁹

In the allograft/PRF group, histomorphometric analysis showed that the rate of vital bone/inert bone in the bone trabecular areas was 65% vital new bone (20.95% of the overall sample) and 35% inert bone (9.41% of the overall sample). In the control group, the rate of vital bone/inert bone in the bone trabecular areas was 69% vital new bone (20.306% of the overall sample) and 31% inert bone (10.934% of the overall sample) (Table 3).²⁹

PRF with xenograft

PRF was mixed with Bio-oss (Geistlich Pharma AG, Wolhusen, Switzerland) and used as a filling material in 4 studies,^{30–33} in which 146 sinus lift procedures were performed. In all the studies, sinus lift was performed using the lateral approach. In the study of Inchingolo et al,³⁰ implants were placed immediately, the PRF/xenograft mixture was used as a filling

TABLE 2

Studies assessing the use of platelet-rich fibrin as a sole filling material*

Reference	Survival Rate	Radiographic Results					Histomorphometric Results	
		Duration	Residual Bone	Bone Gained	Bone Volume	Density	No. of Biopsies	Bone Matrix
Mazor et al ²⁶	100%	6 mo	2.9 mm	10.1 mm	N	N	25	33%
Simonpieri et al ²⁷	100%	6 mo	1.8 mm	10.4 mm	N	N	No histomorphometric analysis	
Tajima et al ²⁸	100%	6 mo	4.28 mm	7.5 mm	0.7 mL	323 HU	No histomorphometric analysis	

*N, not reported.

material in all sinuses, and the PRF membranes were placed on the sinus membrane and osteotomy window.³⁰

The other 3 studies used the PRF/xenograft mixture for the test group and xenograft alone for the control group, with implants placed at the second stage surgery. Zhang et al³¹ and Tatullo et al³² used the PRF membrane to cover the access window in the test group, whereas Bölükbaşı et al³³ used PRF membranes to cover the access window and sinus membrane in the test group and a resorbable collagen membrane in the control group. Second stage surgery was performed for implant placement and bone biopsy harvesting after 6 months in the studies of Zhang et al³¹ and Bölükbaşı et al,³³ whereas Tatullo et al³² performed the second stage surgery at different time intervals: 106 days (early protocol), 4 months (intermediate protocol), and 5 months (late protocol).³¹⁻³³

No complications were observed during the healing period in all studies. In the study of Inchingolo et al,³⁰ 6 sinus membrane perforations were observed, but they did not develop any postoperative complications. Survival rate was reported in 3 studies, and it was 100%.^{30,32,33} The study of Tatullo et al³² used the Osstell Mentor device to perform resonance frequency analysis for primary implant stability, and the mean ISQ of primary implant stability was 37.2 ± 4.2 in the

early protocol group, 36.8 ± 6.1 in the intermediate protocol group, and 39.1 ± 9 in the late protocol group. There were no statistically significant differences between test groups and control groups in any of the protocols.

Radiographic evaluation was performed by panoramic radiographs or CT scan to evaluate the bone formation in all studies. The study of Inchingolo et al³⁰ reported an average increase in the peri-implant bone density of 31% after 6 months. The studies of Zhang et al³¹ and Tatullo et al³² revealed the presence of mineralized tissue (bone and bone substitute), which was well integrated with the residual bone and adequate in the amount and density in all cases; whereas the study of Bölükbaşı et al³⁴ evaluated the relationship between sinus-graft height and the implant (the ratio of the distance from the grafted sinus floor above the implant to the head of the fixture [BL] to the distance from the apex to the head of the fixture [IL]) and the change in the height of grafted sinus (the ratio of the distance from the marginal bone to the grafted sinus floor above the lowest part of the original sinus height [GSH] to the original sinus height [OSH]) at different time intervals (10 days after sinus lifting [T₀], 10 days after implant placement [T₁], 6 months after implant placement [T₂], 6 months after loading [T₃], 12 months after loading [T₄], and 24

TABLE 3

Studies assessing the use of platelet-rich fibrin with bone substitute (histomorphometric results)

Reference	Duration	No. of Biopsies		Histomorphometric Results	
		Test	Control	Test	Control
Choukroun et al ²⁹	Test 4 mo	6	3	Medullary spaces 66.5%	Medullary spaces 67.7%
	Control 8 mo			Osteoid borders 2.26%	Osteoid borders 1.94%
Zhang et al ³¹	6 mo	6	5	Trabecular bone 31.24%	Trabecular bone 30.36%
				New bone 20.95%	New bone 20.306%
Tatullo et al ³²	106 d	12	12	Inert bone 9.41%	Inert bone 10.934%
				Newly formed bone $18.35 \pm 5.62\%$	Newly formed bone $12.95 \pm 5.33\%$
				bone substitute $19.16 \pm 6.89\%$	bone substitute $28.54 \pm 12.01\%$
Bölükbaşı et al ³³	6 mo	17	15	Bone-to-bone substitute contact $21.45\% \pm 14.57\%$	Bone-to-bone substitute contact $18.57\% \pm 5.39\%$
				Medullary spaces 70.2%	Medullary spaces 68.44%
				Osteoid borders 7.01%	Osteoid borders 5.12%
Tatullo et al ³²	4 mo	12	12	Trabecular bone 22.79%	Trabecular bone 26.44%
				Medullary spaces 70.01%	Medullary spaces 68.18%
				Osteoid borders 3.84%	Osteoid borders 3.12%
Tatullo et al ³²	5 mo	12	12	Trabecular bone 26.15%	Trabecular bone 28.7%
				Medullary spaces 61.41%	Medullary spaces 58.15%
				Osteoid borders 3.53%	Osteoid borders 2.88%
Bölükbaşı et al ³³	6 mo	17	15	Trabecular bone 37.06%	Trabecular bone 38.97%
				New bone formation 35.0 ± 8.60	New bone formation 32.97 ± 9.71
				Connective tissue 30.63 ± 7.53	Connective tissue 33.94 ± 9.15
Bölükbaşı et al ³³	6 mo	17	15	Biomaterial remnants 33.05 ± 6.29	Biomaterial remnants 33.79 ± 8.57

TABLE 4
Studies assessing the use of platelet-rich fibrin with bone substitute (clinical and radiographic results)*

Reference	Survival Rate	Duration	Radiographic Results				Bone Density
			BL/IL		GSH/OSH		
			T	C	T	C	
Choukroun et al ²⁹	N	No radiographic analysis					
Inchingolo et al ³⁰	100%	6 mo			N		31%
Zhang et al ³¹	N	3–6 mo			N		N
Tatullo et al ³²	100%	6 mo			N		N
Bölükbaşı et al ³³	100%	10 d after sinus lifting			4.26	4.2	N
		10 d after implant placement	1.43	1.46	4.78	4.55	
		6 mo after implant placement	1.38	1.43	4.78	4.52	
		6 mo after loading	1.37	1.37	4.39	4.09	
		12 mo after loading	1.32	1.29	4.39	3.81	
		24 mo after loading	1.30	1.23	4.36	3.67	

*BL, distance from the grafted sinus floor above the implant to the head of the fixture; C, control; GSH, ratio of the distance from the marginal bone to the grafted sinus floor above the lowest part of the original sinus height; IL, distance from the apex to the head of the fixture; N, not reported; OSH, original sinus height; T, test group.

months after loading [T₅]. For BL/IL, the difference between T₃ and T₄ was statistically significant in the test group, whereas in the control group, it was significant between T₂-T₃, T₃-T₄, and T₄-T₅. The test group showed statistically less change in BL/IL values than the control group (P = .022). For GSH/OSH, the difference between T₀ and T₁ was statistically significant in the test group, whereas in the control group, it was significant between T₂ and T₃. The differences between the 2 groups were not statistically significant (Table 4).

Histomorphometric analysis was performed in 3 studies.^{31–33} Different histomorphometric parameters were evaluated in different studies. The study of Tatullo et al³² revealed comparable results for the 2 groups. Zhang et al³¹ and Bölükbaşı et al³⁴ reported that there was no statistically significant difference between the 2 groups (Table 3).

DISCUSSION

The present study aimed to determine the effect of PRF on the open maxillary sinus augmentation procedures. The results of this literature analysis showed that few clinical studies have been performed to assess the effect of PRF in the sinus augmentation procedure. Furthermore, it was not possible to perform a meta-analysis of the data because of the heterogeneity of the identified studies regarding surgical technique, grafting material, implant placement time, protocol, outcome measures, healing time for biopsy and implant placement, as well as follow-up period. This study revealed that PRF has been used in 2 ways – either as fragments mixed with different bone substitutes or as a sole filling material.^{26–33}

In the 3 studies that used PRF clots as a sole filling material, implants were placed spontaneously with sinus lift and served as tent pegs. The tent peg technique based on guided bone regeneration as implants is to place immediately with sinus lift and not use grafting material to fill the created space. The implant tips maintain the Schneiderian membrane in an elevated position, triggering a series of events including blood clot formation, which fills the dead space and serves as a scaffold for bone formation, cellular migration, differentiation,

angiogenesis, and osteogenesis.^{26–28,34} However, some experimental studies showed that the length of implant protrusion into the sinus cavity is not related to the height of new bone in the sinus, the bone gain along with osseointegration was limited, and implants’ apical ends may be enmeshed in the connective tissue.^{35,36} The analyzed studies used PRF to serve as an optimized blood clot and stabilize a good amount of bone around the implants for a benefit from growth factors released by PRF.^{26–28}

The overall implant survival rate of the analyzed studies was as high as 100%, and it was harmonious with recent systematic reviews and articles reporting the implant survival rate with sinus lift,^{37,38} whereas only the study of Simonpieri et al²⁷ provided long-term follow-up (2–6 years). The studies of Mazor et al²⁶ and Tajima et al²⁸ provided only a 6-month follow-up period. Resonance frequency analysis was performed by Tajima et al²⁸ at the time of stage 2 surgery. The mean ISQ reported by this study was accepted, as studies showed that the clinical range of the ISQ is normally from 55 to 80, with lower values in the maxilla, and that an ISQ more than 60 was associated with 100% implant success.^{39,40}

Radiographic evaluation 6 months after the sinus lift showed a comparable bone gain in the studies of Mazor et al²⁶ and Simonpieri et al.²⁷ However, Tajima et al²⁸ reported lower bone gain. The difference in the bone gain was attributed to the high residual bone height in the study of Tajima et al²⁸ compared with the others. However, the total bone height was comparable for the 3 studies and corresponded to the implant length. The bone density of the newly formed bone was only evaluated in the study of Tajima et al²⁸: it was comparable to normal bone density at the posterior maxilla as reported by some authors^{41–43} and slightly lower than others.⁴⁴ Nevertheless, HU values for bone density cannot be considered as absolute values and used in the comparison between studies due to differences in methodologic approaches.⁴⁵

This analysis revealed that the use of PRF as a sole filling material during simultaneous sinus lift and implantation showed optimistic results, but it was comparable to studies using implants as tent pegs with no graft.^{46,47} Moreover, all

studies were case series with no control group to prove the benefits gained from the use of PRF to fill the sinus instead of a natural blood clot.

The second group of these analyzed studies used PRF fragments mixed with different bone substitutes (Bio-Oss and DFDBA). Bone substitutes overcome donor site morbidity, long duration, and unpredictable resorption occurring with autogenous bone, but they only act as a scaffold for bone growth due to the lack of osteoinductivity. Conversely, maxillary sinus floor augmentation is an elective procedure, indicating the priority to reduce patient morbidity.^{15,48} The analyzed studies used PRF fragments with bone substitutes in a trial to improve their performance.^{29–33}

The PRF fragments were mixed with DFDBA in the study of Choukroun et al.² DFDBA is a commonly used allograft prepared by demineralizing bone in hydrochloric acid to expose bone morphogenic proteins followed by freeze drying.⁴⁹ This study showed an equivalent new bone formation for the PRF/DFDBA mixture after 4 months and for DFDBA alone after 8 months, concluding that the use of PRF with DFDBA as a grafting material in sinus floor lift seems to accelerate bone regeneration, reduce maturation time of DFDBA, and allow implant placement after only 4 months rather than 8 months of healing. Moreover, it reduces the amount of DFDBA used, which reduces the cost of the procedure.²⁹ The new bone formation in this study in both groups was lower than that reported by Kolerman et al,⁵⁰ who used mineralized freeze-dried bone allograft (FDBA) after 9 months, and Kassolis et al,⁵¹ who used PRP/FDBA and FDBA after 4.5–6 months. Although the study of Choukroun et al²⁹ showed histologic benefits of the use of PRF with DFDBA, it does not provide any reporting for the volumetric stability of the graft and implant survival.

The studies of Inchingolo et al, Zhang et al, Tatullo et al, and Bölükbaşı et al^{30–33} used PRF fragments with Bio-Oss, which is a commonly used deproteinized bovine bone. Recent histomorphometric meta-analysis and systematic review showed that total bone volume with Bio-Oss as a grafting material (22%) was lower than that for autogenous bone (40%) or a Bio-Oss/autogenous bone mixture (28%) after 4–9 months, whereas the total bone volume was comparable after more than 9 months. Conversely, the slow biodegradation of Bio-Oss seems to maintain graft height and prevent bone loss.^{15,52} The analyzed studies used PRF fragments with Bio-Oss in a trial to accelerate its maturation.

The overall survival rate was 100%, which was harmonious with the implant survival rate reported in recent systematic reviews and articles.^{37,38} Resonance frequency analysis was performed by Tatullo et al³² to assess the primary stability, where the mean ISQ in early, intermediate, and late protocol groups showed no statistically significant differences between test and control groups. However, the ISQ values reported by Tatullo et al³² were lower than the threshold ISQ,^{39,40,53} and implants showed a 100% survival rate after 36 months of functional loading. This result supports the hypothesis that resonance frequency analysis for primary stability failed to significantly predict implant failure.³⁹

Volumetric stability is mainly affected by the grafting material, followed by the presence of a functional implant. An

anorganic bovine xenograft showed minor to no changes in bone height compared with an autogenous bone or xenograft/autogenous bone mixture.⁵⁴ Bölükbaşı et al³³ performed a radiographic evaluation to assess the volumetric stability of the graft. This showed that the addition of PRF to Bio-Oss does not adversely affect the vertical stability of the graft. Moreover, this showed a statistically significant lower resorption for PRF/Bio-Oss group at areas of implant placement. Conversely, this study used BL/IL and GSH/OSH ratio instead of real measurements. Thus, the changes in bone height reported in this study cannot be compared with other studies.³³ Histomorphometric data analysis showed comparable results for PRF/Bio-Oss and Bio-Oss alone at different time intervals. Zhang et al³¹ and Bölükbaşı et al³³ showed no statistically significant difference after 6 months, and Tatullo et al³² showed comparable results at 106 days, 4 months, and 5 months and stated that PRF does not appear to accelerate maturation of Bio-Oss. This may be attributed to its slow resorption rate. However, PRF reduces the quantity of bone substitute used, lowering the cost of the procedure.^{15,31–33}

This systematic review showed that only limited randomized controlled clinical trials are available to evaluate the use of PRF in sinus augmentation procedures either as a sole filling material or with bone substitutes, indicating the need for further work.

CONCLUSION

The PRF as a sole filling material for sinus lift with simultaneous implant placement is a simple technique with promising results. However, its benefits compared with a natural blood clot have not yet been shown.

Addition of PRF to DFDBA accelerates graft maturation and decreases the healing period before implant placement. Conversely, it has no beneficial effect on graft maturation of deproteinized bovine bone.

The PRF membranes represent an easy and successful method to cover the sinus membrane or osteotomy window.

ABBREVIATIONS

BL: distance from the grafted sinus floor above the implant to the head of the fixture
DFDBA: demineralized freeze dried bone allograft
FDBA: freeze-dried bone allograft
GSH: distance from the marginal bone to the grafted sinus floor above the lowest part of the original sinus height
HU: Hounsfield units
IL: distance from the apex to the head of the fixture
ISQ: implant stability quotient
OSH: original sinus height
PRF: platelet-rich fibrin
PRP: platelet-rich plasma

REFERENCES

1. Jang YJ, Choi SY, Choi JY, Jeong JH, Kwon TG. Histomorphometric analysis of sinus augmentation using bovine bone mineral with two

- different resorbable membranes. *Clin Oral Implants Res.* 2013;Suppl A100:1–7.
2. Misch CE. Available bone and dental implant treatment plans. In: Misch CE, ed. *Contemporary Implant Dentistry*. 3rd ed. St. Louis, Mo: Mosby, Elsevier; 2008:178–199.
 3. Wong K. Immediate implantation of endosseous dental implants in the posterior maxilla and anatomic advantages for this region: a case report. *Int J Oral Maxillofac Implants.* 1996;11:529–533.
 4. Isaksson S. Evaluation of three bone grafting techniques for severely resorbed maxillae in conjunction with immediate endosseous implants. *Int J Oral Maxillofac Implants.* 1994;9:679–688.
 5. Chiapasco M, Casentini P, Zaniboni M. Bone augmentation procedures in implant dentistry. *Int J Oral Maxillofac Implants.* 2009;24(suppl):237–259.
 6. Pelo S, Gasparini G, Moro A, Boniello R, Amoroso PF. Segmental Le Fort I osteotomy with bone grafting in unilateral severely atrophied maxilla. *Int J Oral Maxillofac Surg.* 2009;38:246–249.
 7. Munoz-Guerra MF, Naval-Gias L, Capote-Moreno A. Le Fort I osteotomy, bilateral sinus lift, and inlay bone-grafting for reconstruction in the severely atrophic maxilla: a new vision of the sandwich technique, using bone scrapers and piezosurgery. *J Oral Maxillofac Surg.* 2009;67:613–618.
 8. Cordaro L, Torsello F, Accorsi Ribeiro C, Liberatore M, Mirisola di Torresanto V. Inlay-onlay grafting for three-dimensional reconstruction of the posterior atrophic maxilla with mandibular bone. *Int J Oral Maxillofac Surg.* 2010;39:350–357.
 9. Felice P, Iezzi G, Lizio G, Piattelli A, Marchetti C. Reconstruction of atrophied posterior mandible with inlay technique and mandibular ramus block graft for implant prosthetic rehabilitation. *J Oral Maxillofac Surg.* 2009;67:372–380.
 10. Kim YK, Yun PY, Kim SG, Lim SC. Analysis of the healing process in sinus bone grafting using various grafting materials. *Oral Surg Oral Med Oral Pathol Oral Radiol Endod.* 2009;107:204–211.
 11. Browaeys H, Bouvry P, De Bruyn H. A literature review on biomaterials in sinus augmentation procedures. *Clin Implant Dent Relat Res.* 2007;9:166–177.
 12. Hieu PD, Chung JH, Yim SB, Hong KS. A radiographical study on the changes in height of grafting materials after sinus lift: a comparison between two types of xenogenic materials. *J Periodontal Implant Sci.* 2010;40:25–32.
 13. Scarano A, Piattelli A, Perrotti V, Manzon L, Iezzi G. Maxillary sinus augmentation in humans using cortical porcine bone: a histological and histomorphometrical evaluation after 4 and 6 months. *Clin Implant Dent Relat Res.* 2011;13:13–18.
 14. Yildirim M, Spiekermann H, Handt S, Edelhoff D. Maxillary sinus augmentation with the xenograft Bio-Oss and autogenous intraoral bone for qualitative improvement of the implant site: a histologic and histomorphometric clinical study in humans. *Int J Oral Maxillofac Implants.* 2001;16:23–33.
 15. Handschel J, Simonowska M, Naujoks C, et al. A histomorphometric meta-analysis of sinus elevation with various grafting materials. *Head Face Med.* 2009;11:5–12.
 16. Andreaana S, Cornellini R, Edsberg LE, Natiella JR. Maxillary sinus elevation for implant placement using calcium sulfate with and without DFDBA: six cases. *Implant Dent.* 2004;13:270–277.
 17. Whitman DH, Berry RL, Green DM. Platelet gel: an autologous alternative to fibrin glue with applications in oral and maxillofacial surgery. *J Oral Maxillofac Surg.* 1997;55:1294–1299.
 18. Froum SJ, Wallace SS, Tarnow DP, Cho SC. Effect of platelet-rich plasma on bone growth and osseointegration in human maxillary sinus grafts: three bilateral case reports. *Int J Periodontics Restorative Dent.* 2002;22:45–53.
 19. Del Corso M, Toffler M, Dohan Ehrenfest DM. Use of an autologous leukocyte and platelet-rich fibrin (L-PRF) membrane in post-avulsion sites: an overview of Choukroun's PRF. *J Implant Adv Clin Dent.* 2010;1:27–35.
 20. Froum SJ, Wallace SS, Tarnow DP, Cho SC. Effect of platelet-rich plasma on bone growth and osseointegration in human maxillary sinus grafts: three bilateral case reports. *Int J Periodontics Restorative Dent.* 2002;22:45–53.
 21. Dohan Ehrenfest DM, Rasmusson L, Albrektsson T. Classification of platelet concentrates: from pure platelet-rich plasma (P-PRP) to leukocyte- and platelet-rich fibrin (L-PRF). *Trends Biotechnol.* 2009;27:158–167.
 22. Choukroun J, Adda F, Schoeffler C, Vervelle A. An opportunity in perio-implantology: the PRF. *Implantodontie.* 2001;42:55–62.
 23. Dohan DM, Choukroun J, Diss A, et al. Platelet-rich fibrin (PRF): a second-generation platelet concentrate. Part I: technological concepts and evolution. *Oral Surg Oral Med Oral Pathol Oral Radiol Endod.* 2006;101:e37–e44.
 24. Dohan DM, Choukroun J, Diss A, et al. Platelet-rich fibrin (PRF): a second-generation platelet concentrate. Part II: platelet-related biologic features. *Oral Surg Oral Med Oral Pathol Oral Radiol Endod.* 2006;101:e45–e50.
 25. Dohan DM, Choukroun J, Diss A, et al. Platelet-rich fibrin (PRF): a second-generation platelet concentrate. Part III: leukocyte activation: a new feature for platelet concentrates. *Oral Surg Oral Med Oral Pathol Oral Radiol Endod.* 2006;101:e51–e55.
 26. Mazor Z, Horowitz RA, Del Corso M, Prasad HS, Rohrer MD, Ehrenfest D. Sinus floor augmentation with simultaneous implant placement using Choukroun's platelet-rich fibrin as the sole grafting material: a radiologic and histologic study at 6 months. *J Periodontol.* 2009;80:2056–2064.
 27. Simonpieri A, Choukroun J, Del Corso M, Sammartino G, Ehrenfest D. Simultaneous sinus-lift and implantation using microthreaded implants and leukocyte- and platelet-rich fibrin as sole grafting material: a six-year experience. *Implant Dent.* 2011;20:2–12.
 28. Tajima N, Ohba S, Sawase T, Asahina I. Evaluation of sinus floor augmentation with simultaneous implant placement using platelet-rich fibrin as sole grafting material. *Int J Oral Maxillofac Implants.* 2013;28:77–83.
 29. Choukroun J, Diss A, Simonpieri A, et al. Platelet-rich fibrin (PRF): a second-generation platelet concentrate. Part V: histologic evaluations of PRF effects on bone allograft maturation in sinus lift. *Oral Surg Oral Med Oral Pathol Oral Radiol Endod.* 2006;101:299–303.
 30. Inchingolo F, Tatullo M, Marrelli M, et al. Trial with platelet-rich fibrin and Bio-Oss used as grafting materials in the treatment of the severe maxillary bone atrophy: clinical and radiological evaluations. *Eur Rev Med Pharmacol Sci.* 2010;14:1075–1084.
 31. Zhang Y, Tangli S, Huber CD, Lin Y, Qiu L, Rausch-Fan X. Effects of Choukroun's platelet-rich fibrin on bone regeneration in combination with deproteinized bovine bone mineral in maxillary sinus augmentation: a histological and histomorphometric study. *J Craniomaxillofac Surg.* 2012;40:321–328.
 32. Tatullo M, Marrelli M, Cassetta M, et al. Platelet-rich fibrin (P.R.F.) in reconstructive surgery of atrophied maxillary bones: clinical and histological evaluations. *Int J Med Sci.* 2012;9:872–880.
 33. Bölükbaşı N, Ersanlı S, Keklikoğlu N, Başgeçmez C, Ozdemir T. Sinus augmentation with platelet-rich fibrin in combination with bovine bone graft versus bovine bone graft in combination with collagen membrane. *J Oral Implantol.* 2015;41:586–595.
 34. Hatano N, Sennerby L, Lundgren S. Maxillary sinus augmentation using sinus membrane elevation and peripheral venous blood for implant-supported rehabilitation of the atrophic posterior maxilla: case series. *Clin Implant Dent Relat Res.* 2007;9:150–155.
 35. Sul SH, Choi BH, Li J, Jeong SM, Xuan F. Histologic changes in the maxillary sinus membrane after sinus membrane elevation and the simultaneous insertion of dental implants without the use of grafting materials. *Oral Surg Oral Med Oral Pathol Oral Radiol Endod.* 2007;105:e1–e5.
 36. Sul SH, Choi BH, Li J, Jeong SM, Xuan F. Effects of sinus membrane elevation on bone formation around implants placed in the maxillary sinus cavity: an experimental study. *Oral Surg Oral Med Oral Pathol Oral Radiol Endod.* 2008;105:684–687.
 37. Wallace SS, Froum SJ. Effect of maxillary sinus augmentation on the survival of endosseous dental implants. A systematic review. *Ann Periodontol.* 2003;8:328–343.
 38. Chiapasco M, Casentini P, Zaniboni M. Bone augmentation procedures in implant dentistry. *Int J Oral Maxillofac Implants.* 2009;24(suppl):237–259.
 39. Rodrigo D, Aracil L, Martin C, Sanz M. Diagnosis of implant stability and its impact on implant survival: a prospective case series study. *Clin Oral Implants Res.* 2010;21:255–261.
 40. Sennerby L, Meredith N. Implant stability measurements using resonance frequency analysis: biological and biomechanical aspects and clinical implications. *Periodontology.* 2008;47:51–66.
 41. Shapurian T, Damoulis PD, Reiser GM, Griffin TJ, Rand WM. Quantitative evaluation of bone density using the Hounsfield index. *Int J Oral Maxillofac Implants.* 2006;21:290–297.
 42. Norton MR, Gamble C. Bone classification: an objective scale of bone density using the computerized tomography scan. *Clin Oral Implants Res.* 2001;12:79–84.
 43. Park HS, Lee YJ, Jeong SH, Kwon TG. Density of the alveolar and

basal bones of the maxilla and the mandible. *Am J Orthod Dentofacial Orthop.* 2008;133:30–37.

44. Turkyilmaz I, Ozan O, Yilmaz B, Ersoy AE. Determination of bone quality of 372 implant recipient sites using Hounsfield unit from computerized tomography: a clinical study. *Clin Implant Dent Relat Res.* 2008;10:238–244.

45. De Oliveira RC, Leles CR, Normanha LM, Lindh C, Ribeiro-Rotta RF. Assessments of trabecular bone density at implant sites on CT images. *Oral Surg Oral Med Oral Pathol Oral Radiol Endod.* 2008;105:231–238.

46. Riben C, Thor A. The maxillary sinus membrane elevation procedure: augmentation of bone around dental implants without grafts—a review of a surgical technique. *Int J Dent.* 2012;2012:105483.

47. Lundgren S, Andersson S, Gualini F, Sennerby L. Bone reformation with sinus membrane elevation: a new surgical technique for maxillary sinus floor augmentation. *Clin Implant Dent Relat Res.* 2004;6:165–173.

48. Nkenke E, Stelzle F. Clinical outcomes of sinus floor augmentation for implant placement using autogenous bone or bone substitutes: a systematic review. *Clin Oral Implants Res.* 2009;20(suppl 4):124–133.

49. Kalish BP, Schuster GS, Peacock ME, et al. Influence of matrix-suspended demineralized bone on osseous repair using a critical-sized

defect in the rat (*Rattus norvegicus*) calvarium. *J Oral Implantol.* 2008;34:83–89.

50. Kolerman R, Tal H, Moses O. Histomorphometric analysis of newly formed bone after maxillary sinus floor augmentation using ground cortical bone allograft and internal collagen membrane. *J Periodontol.* 2008;79:2104–2111.

51. Kassolis JD, Reynolds MA. Evaluation of the adjunctive benefits of platelet-rich plasma in subantral sinus augmentation. *J Craniofac Surg.* 2005;16:280–287.

52. Jensen T, Schou S, Stavropoulos A, Terheyden H, Holmstrup P. Maxillary sinus floor augmentation with Bio-Oss or Bio-Oss mixed with autogenous bone as graft: a systematic review. *Clin Oral Implants Res.* 2012;23:263–273.

53. Nedir R, Bischof M, Szmukler-Moncler S, Bernard JP, Samson J. Predicting osseointegration by means of implant primary stability. *Clin Oral Implants Res.* 2004;15:520–528.

54. Mardinger O, Chaushu G, Sigalov S, Herzberg R, Shlomi B, Schwartz-Arad D. Factors affecting changes in sinus graft height between and above the placed implants. *Oral Surg Oral Med Oral Pathol Oral Radiol Endod.* 2011;111:e6–e11.