

Use of CAD/CAM Healing Abutment Immediately After Dental Implant Placement for the Non-Esthetic Zone: A Guided Soft Tissue Healing Technique

Periklis Proussaefs, DDS, MS

INTRODUCTION

Dental implants were introduced for the treatment of totally edentulous patients.¹ However, soon after their introduction, dental implants became a valid treatment modality for the treatment of partially edentulous patients.^{2,3} Studies have shown that it is important to provide interim restorations for partially edentulous patients because they help confirm the diagnostic design,^{4,5} esthetics,⁴⁻⁶ contours,⁴⁻⁸ and phonetics⁸ as well as duplicate the results to the definitive restoration.⁹⁻¹⁵ In addition, the healing response around the abutments and remaining dentition as well as the patient's oral hygiene can be evaluated.^{8,10} The soft tissue around the fixtures can heal according to the contours of the final restoration.^{6,11-16} It has been also supported that provisional restorations allow clinicians to observe the osseointegration of the fixtures.¹²

Interim restorations, however, have been associated with restorative and biological complications. Abboud et al¹⁷ reported implant failure associated with the presence of residual cement when cement-retained interim crowns were placed after implant surgery. Oyama et al¹⁸ evaluated 17 consecutively treated root form dental implants in patients receiving interim restoration the day of surgery. All complications were prosthetically related to the interim restoration. In their study, they experienced 7 fractured provisionals, 2 debonded provisionals, and 3 loosened provisional abutment screws. All complications occurred during the first 3 months after surgery.

For the non-esthetic zone, several authors have introduced the concept of providing a custom healing abutment instead of a crown immediately after dental implant surgery or during the second-stage surgery.^{19,20} With this technique, composite resin is applied externally on a temporary abutment in an attempt to support the soft tissue and simulate the contours of the definitive restoration.²⁰ The limitation of this technique is the additional chair time needed to fabricate the custom healing abutment and the limited guidance the clinician may have while customizing the healing abutment. With the introduction and application of digital technology in current dental practice, a technique has been suggested that involves fabrication of a

computer-aided design/computer-aided manufacturing (CAD/CAM) healing abutment and impression coping before dental implant surgery that enables the tissue to heal according to the contours of the definitive restoration. The purpose of the current clinical report is to describe a method for fabricating a CAD/CAM healing abutment that is placed immediately after implant surgery.

CLINICAL METHODOLOGY

Patient examination and preparation procedures

A 37-year-old white male patient presented at the author's private prosthodontic practice seeking treatment for his partial edentulism at the area of the mandibular right first molar. After evaluating different treatment options, the decision was made to replace the missing mandibular tooth with a root-form dental implant (Inclusive, Glidewell Corp, Newport Beach, Calif). The patient was a nonsmoker with good oral hygiene and no history of periodontal disease. There were no medical issues.

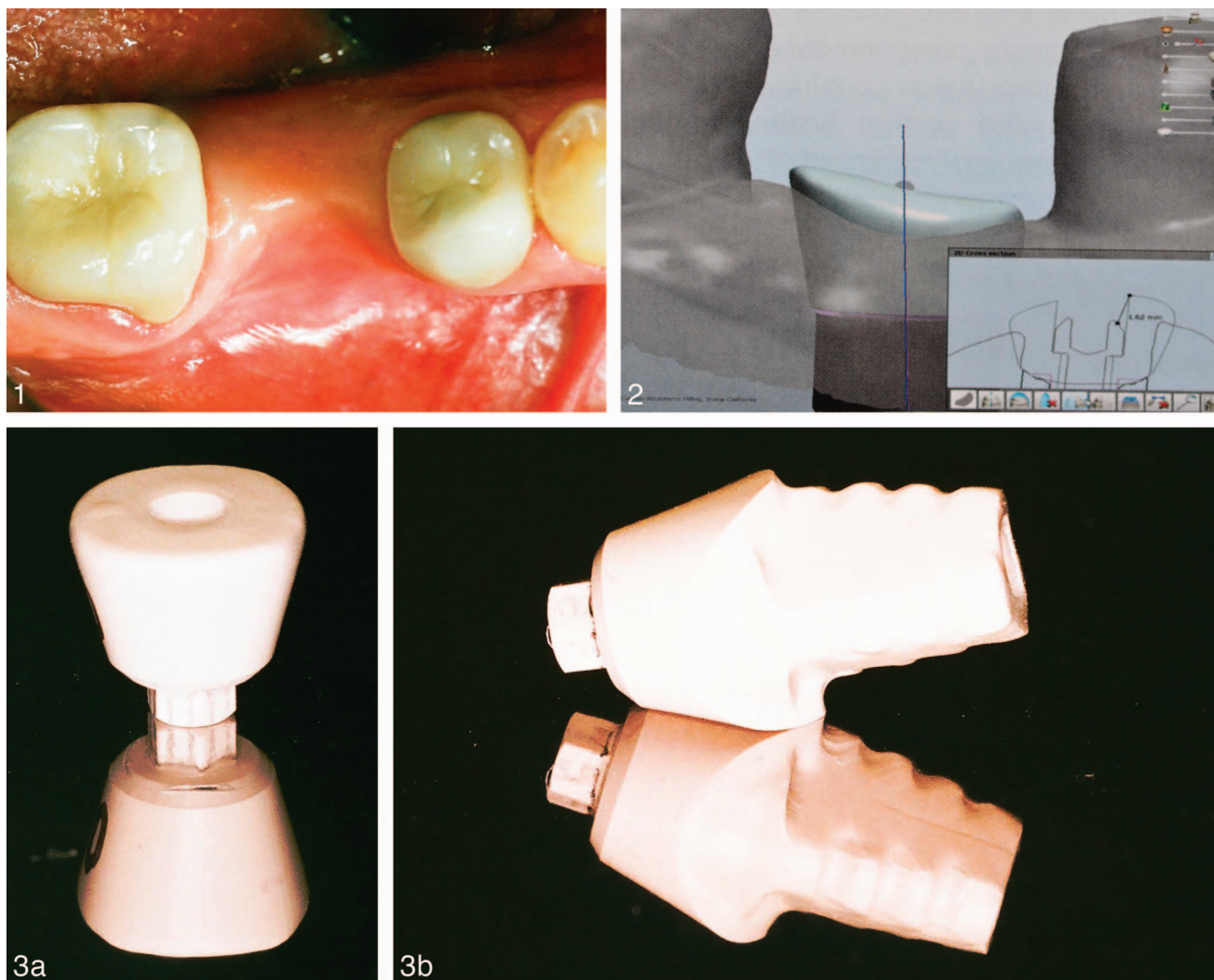
The tissue around the healing abutments was evaluated for signs or symptoms of pathosis (ie, bleeding, redness, pain) (Figure 1). Complete preliminary arch impressions were made preoperatively from the patient's maxillary and mandibular arches using polyvinylsiloxane impression material (Silgimix, SultanHealthCare, York, Pa). An interocclusal record was also made using polyvinylsiloxane occlusal registration material (Exabite II NSD, GC America Inc, Alsip, Ill) at the maximum intercuspation position.

CAD/CAM healing abutment preparation procedures

The impressions were scanned (D700, 3Shape, Copenhagen, Denmark) and the definitive prosthesis was simulated using the software incorporated into the scanner. The computer software allows the user to digitally design the size and shape of each component. Using the contours of the definitive prosthesis as reference, a custom healing abutment was digitally designed (Figure 2). The custom healing abutment was then made from a polymethyl methacrylate (PMMA) block in the laboratory using a milling machine (TS150 Milling Solution, IOS Technologies, San Diego, Calif) (Figure 3a).

In addition, a CAD/CAM custom impression coping was milled from a PMMA block (Figure 3b). The contours of the custom impression coping were identical to the contours of the

Advance Education Program in Implant Dentistry, Loma Linda University, School of Dentistry, Loma Linda, Calif, and private practice, Ventura, Calif.
Corresponding author, e-mail: DrProussaefs@gmail.com
DOI: 10.1563/aaid-joi-D-14-00228



FIGURES 1–3. **FIGURE 1.** Preoperative evaluation. **FIGURE 2.** The computer-aided design/computer-aided manufacturing healing abutment is digitally designed to simulate the contours of the definitive prosthesis. **FIGURE 3.** (a) Computer-aided design/computer-aided manufacturing (CAD/CAM) healing abutment. The contours are based on the contours of the definitive restoration. (b) CAD-CAM impression coping.

healing abutment and in accordance with the contours of the prospective definitive prosthesis.

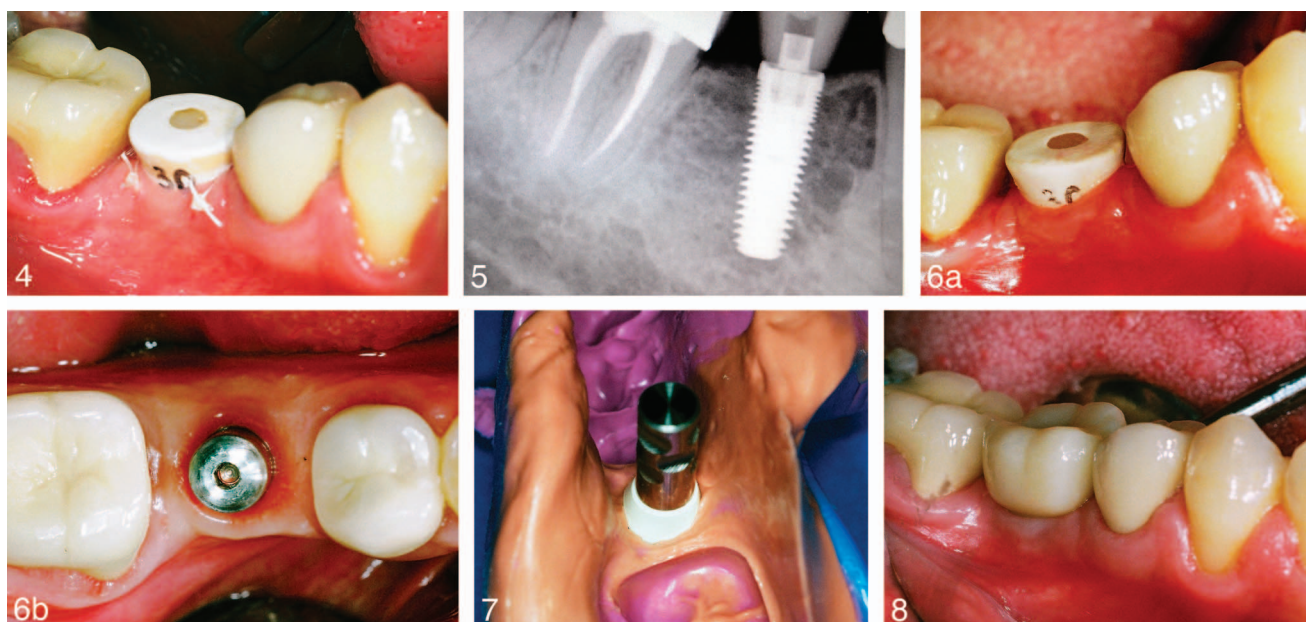
Implant surgery and healing abutment placement procedures

The patient underwent dental implant surgery under local anesthesia. A threaded root form a resorbable blast media surfaced dental implant was placed (Inclusive, Glidwell Corp) with the use of a surgical stent and copious saline irrigation. Full-thickness labial-lingual flaps were reflected. After confirming adequate primary stability at 40 Ncm, the CAD/CAM healing abutment was hand-tightened on the implant and light-cured composite resin cement was placed on the occlusal access hole. A dry cotton pellet was placed underneath (Figure 4). As part of the data collection process, implant stability was evaluated on the day of surgery using the Periotest device (Periotest, Siemens AG, Bensheim, Germany). Periotest measured -1 , which was consistent with adequate implant stability.^{21–23}

Panoramic and periapical radiographs were taken after surgery (Figure 5).

Implant restoration fabrication procedures

Three months after surgery (Figure 6a) the implant was checked for stability using the Periotest device. The Periotest measured -2 and the radiographic evaluation revealed no pathosis, which suggested successful osseointegration of the dental implant. No probing >4 mm was detected around the implant (measured at mesiolingual, midlingual, distal-lingual, mesio-buccal, midbuccal, and distal-buccal). After osseointegration was confirmed, the CAD/CAM healing abutment was removed and the tissue evaluated (Figure 6b). The tissue appeared to have obtained contours compatible with the contours of the prospective definitive prosthesis. The CAD/CAM custom impression coping was hand-tightened on the implant and the final impression was made using polyvinylsiloxane impression material (Exafast NDS, GC America) (Figure 7).



FIGURES 4–8. **FIGURE 4.** Healing abutment on the day of implant surgery. **FIGURE 5.** Postoperative x-ray on the day of surgery. **FIGURE 6.** (a) Three months after tissue healing. (b) Tissue has been contoured based on the contours of the definitive prosthesis. The stock healing abutment has been placed for demonstration purposes. **FIGURE 7.** Computer-aided design/computer-aided manufacturing impression coping for final impression. **FIGURE 8.** The definitive prosthesis 1 year after loading.

A CAD/CAM titanium abutment was fabricated. The abutment was torqued at 35 Ncm. Polyvinylsiloxane impression material was placed in the occlusal access hole. The contours of the definitive restoration were similar to the contours of the interim healing abutment since the data had been stored in the software. After confirming occlusion, contact points, and esthetics, the definitive prosthesis was cemented with resin modified glass ionomer cement (Rely-X, 3M ESPE, St Paul, Minn) (Figure 8).

DISCUSSION

The described technique is limited to the non-esthetic zone because the interim healing abutment does not provide adequate esthetic outcome. The custom healing abutment is made from a monolithic PMMA block as opposed to composite resin or autopolymerized acrylic resin applied on a prefabricated temporary abutment. According to the manufacturer's specifications, the compressive strength of a milled PMMA abutment is around 110–130 MPa, similar or slightly higher than what is typically anticipated from feldspathic porcelain when fused to metal alloy. Therefore, taking the high compressive strength in consideration, the suggestion can be made that a CAD/CAM monolithic healing abutment may have few if any failures due to mechanical failure, including but not limited to chipping, fracturing, or debonding. In a laboratory study, Santing et al²⁴ reported that use of chairside fabricated PMMA implant-supported crowns did not have sufficient mechanical properties to withstand laboratory-simulated occlusal wear. In their study there was significant deterioration 1 day after laboratory-simulated intraoral conditions. In contrast, interim restorations made in the laboratory had superior

mechanical properties and the ability to better withstand mechanical forces during simulated mastication circles. However, in their study, milled PMMA was not utilized; therefore, their conclusions should be evaluated with caution before applying their principles in the presented technique. It can be hypothesized that the biological¹⁷ and mechanical¹⁸ failures associated with immediately restoring single dental implants utilizing chairside autopolymerized acrylic resin materials could be partially or completely overcome by utilizing milled CAD/CAM healing abutments that can offer guided soft tissue healing with reduced biological or mechanical failures. A case series report is needed to evaluate the potential of the described technique to overcome these problems.

Davidoff²⁵ described a technique where the peri-implant soft tissues can be trimmed with a bur. However, this technique will probably extend the healing of the tissue and seems to provide less control on the peri-implant tissue contours compared with a well-contoured and well-designed custom healing abutment.

Some authors have advocated the use of anatomic abutments to provide natural contours on the peri-implant tissues during the healing phase.^{16,26,27} However, the anatomic abutments have limited shapes and cannot approximate all contours.⁸ A custom fabricated healing abutment that provides customized contours and shape can provide the optimum healing response around the fixtures.^{19,20}

In the described technique, the CAD/CAM healing abutment is digitally designed with the assumption that one of the flat surfaces of the implant hex is parallel to the tangent of the adjacent teeth. The implant surgeon needs to place the implant so that one of the flat surfaces of the implant is parallel to the tangent of the adjacent teeth as well. Failure to accomplish this will result in a non-fitting healing abutment. This quest for

implant positioning imposes an additional variable to the implant surgeon, who needs to be well aware of the design methodology of this healing abutment.

Alternatively, an impression can be made during implant surgery. The CAD/CAM healing abutment will then be fabricated with similar methodology while the implant is been osseointegrated. In this situation, the CAD/CAM healing abutment will be placed during second-stage surgery. While this technique will facilitate dental implant surgery, since the dental implant placement can be done at any rotational position, it will extend treatment time because tissue healing and contouring will be performed after the implant is considered osseointegrated.

In the described technique, a CAD/CAM impression coping was used to transfer soft tissue anatomy to the laboratory before fabricating the definitive prosthesis. The contours of the CAD/CAM milled PMMA impression coping were identical to the contours of the milled healing abutment. Other authors have suggested use of an interim prosthesis while making the impression,^{14,28} fabricating a custom impression coping by placing autopolymerized acrylic resin around the impression coping,²⁸⁻³⁰ or using intraoral scanners.³¹ To the author's best knowledge, there is no consensus with regards to which technique better transfers soft tissue architecture in the laboratory before fabricating a definitive prosthesis. The described technique might offer the advantage of reducing chair time by having the custom impression coping fabricated in advance before implant surgery. The CAD/CAM impression coping may have an advantage in transferring soft tissue architecture because it is predesigned exactly as the interim prosthesis, so when secured on the implant with a retentive screw, it applies minimal or no pressure on the surrounding tissue. A clinical study is needed to validate potential advantages of utilizing a CAD/CAM impression coping.

The additional cost of the CAD/CAM healing abutment may not prohibit the clinician from applying the described technique; The laboratory cost for a milled PMMA healing abutment is similar to or slightly higher than the cost of a stock temporary metallic abutment. However, customization of the stock temporary metallic abutment involves chair time for reducing the height, adding acrylic resin around it, allowing sufficient time to set, and then trimming, contouring, and polishing. Use of the described CAD/CAM healing abutment eliminates these clinical steps, effectively reducing chair time.

The main advantage of the proposed technique is that it offers the clinician an option to contour the soft tissue in a way that will passively accommodate the definitive prosthesis because the contours of the CAD/CAM healing abutment are identical to those of the definitive prosthesis. In a recent publication, Proussaefs³² introduced the principle of guided soft tissue healing through CAD/CAM technology for the esthetic zone by placing a CAD/CAM interim crown on an implant the day of implant surgery. The assumption can be made that when the soft tissue acquires contours similar to the contours of the definitive restoration, the definitive restoration will be placed with minimal if any pressure on the tissue. This minimal or no pressure placement of the definitive prosthesis may lead to better long-term tissue stability; however, a clinical study is needed to confirm the validity of this hypothesis.

CONCLUSIONS

The described technique may offer an alternative for guided soft tissue healing, eliminating the need for second-stage surgery. While it may not be utilized in the esthetic zone, it can offer soft tissue contours similar to the contours of the definitive prosthesis. A case series study is needed to validate the use of the described technique on a routine basis.

ACKNOWLEDGMENT

The author acknowledges Glidewell Laboratories for performing the laboratory steps in the described technique.

REFERENCES

1. Adell R, Lekholm U, Rockler B, Branemark PI. A 15 year study of osseointegrated implants in the treatment of the edentulous jaw. *Int J Oral Surg.* 1981;10:387-416.
2. Jemt T, Lekholm U, Adell R. Osseointegrated implants in the treatment of partially edentulous patients: a preliminary study of 876 consecutively installed fixtures. *Int J Oral Maxillofac Implants.* 1989;4:211-217.
3. Jemt T, Pettersson P. A 3-year follow-up study on single implant treatment. *J Dent.* 1993;21:203-208.
4. Moscovitch MS, Saba S. The use of a provisional restoration in implant dentistry: a clinical report. *Int J Oral Maxillofac Implants.* 1996;11:395-399.
5. Capp NJ. The diagnostic use of provisional restorations. *Restorative Dent.* 1985;1:94-98.
6. Neale D, Chee WW. Development of implant soft tissue emergence profile: a technique. *J Prosthet Dent.* 1994;71:364-368.
7. Breeding LC, Dixon DL. Transfer of gingival contours to a master cast. *J Prosthet Dent.* 1996;75:341-343.
8. Saba S. Anatomically correct soft tissue profiles using fixed detachable provisional implant restorations. *J Can Dent Assoc.* 1997;63:767-770.
9. Sze AJ. Duplication of anterior provisional fixed partial denture for the final restoration. *J Prosthet Dent.* 1992;68:220-223.
10. Listgarten MA, Lang NP, Schroeder HE, Schroeder A. Periodontal tissues and their counterparts around endosseous implants. *Clin Oral Implants Res.* 1991;2:1-19.
11. Daftary F, Bahat O. Prosthetically formulated natural esthetics in implant prostheses. *Pract Periodontics Aesthet Dent.* 1994;6:75-83.
12. Lewis S. Anterior single-tooth implant restorations. *Int J Periodontics Restorative Dent.* 1995;15:31-41.
13. Proussaefs P. The use of healing abutments for the fabrication of cement-retained, implant-supported provisional prostheses. *J Prosthet Dent.* 2002;87:333-335.
14. Proussaefs P, Kan J, Lozada J, Kleinman A, Farnos A. Effects of immediate loading with threaded hydroxyapatite-coated root-form implants on single premolar replacements: a preliminary report. *Int J Oral Maxillofac Implants.* 2002;17:567-572.
15. Proussaefs P, Lozada J. Immediate loading of single root form implants with the use of a custom acrylic stent. *J Prosthet Dent.* 2001;85:382-385.
16. Binon PP. Provisional fixed restorations supported by osseointegrated implants in partially edentulous patients. *Int J Oral Maxillofac Implants.* 1987;2:173-178.
17. Abboud M, Koeck B, Stark H, Wahl G, Pailon R. Immediate loading of single-tooth implants in the posterior region. *Int J Oral Maxillofac Implants.* 2005;20:61-68.
18. Oyama K, Kan JY, Rungcharassaeng K, Lozada J. Immediate provisionalization of a 3.0-mm-diameter implants replacing single missing maxillary and mandibular incisors: 1-year prospective study. *Int J Oral Maxillofac Implants.* 2012;27:173-180.
19. Kerstein RB, Castellucci F, Osorio J. Ideal gingival form with computer-generated permanent healing abutments. *Compend Contin Educ Dent.* 2000;21:793-797.

20. Cobb GW, Reeves GW, Duncan JD. Guided tissue healing for single-tooth implants. *Compend Contin Educ Dent*. 1999;20:571–578.
21. Olive J, Aparicio C. Periotest method as a measure of osseointegrated oral implant stability. *Int J Oral Maxillofac Implants*. 1990;5:390–400.
22. Teerlinck J, Quirynen M, Darius P, van Steenberghe D. Periotest: an objective clinical diagnosis of bone apposition towards implants. *Int J Oral Maxillofac Implants*. 1991;6:55–61.
23. Elias J, Brunski JB, Scarton HA. A dynamic modal testing technique for noninvasive assessment of bone-dental implant interfaces. *Int J Oral Maxillofac Implants*. 1996;11:728–734.
24. Santing HJ, Kleverlaan CJ, Werner A, Feilzer AJ, Raghoobar GM, Meijer HJ. Occlusal wear of provisional implant-supported restorations. *Clin Implant Dent Relat Res*. 2015;17:179–185.
25. Davidoff SR. Late stage soft tissue modification for anatomically correct implant-supported restorations. *J Prosthet Dent*. 1996;76:334–338.
26. Saadoun AP, Sullivan DY. Single tooth implant: management for success. *Pract Periodontics Aesthet Dent*. 1994;6:73–82.
27. Preston J, Daftary F, Bahat O. Is it a tooth or an implant? *J Calif Dent Assoc*. 1992;20:53–56.
28. Man Y, Qu Y, Dam HG, Gong P. An alternative technique for the accurate transfer of periimplant soft tissue contour. *J Prosthet Dent*. 2013;109:135–137.
29. Kan JY, Rungcharassaeng K, Lozada J. Immediate placement and provisionalization of maxillary anterior single implants: 1-year prospective study. *Int J Oral Maxillofac Implants*. 2003;18:31–39.
30. Noh K, Kwon KR, Kim HS, Kim DS, Pae A. Accurate transfer of soft tissue morphology with interim prosthesis to definitive cast. *J Prosthet Dent*. 2014;111:159–162.
31. Lin WS, Harris BT, Morton D. Use of implant-supported interim restorations to transfer periimplant soft tissue profiles to a milled polyurethane definitive cast. *J Prosthet Dent*. 2013;109:333–337.
32. Proussaefs P. Immediate provisionalization with a CAD/CAM interim abutment and crown: a guided soft tissue healing technique. *J Prosthet Dent*. 2015;113:91–95.