

Custom Cast Post Treatment on an Implant Platform in 2 Patients

Erhan Dilber, PhD, DDS^{1*}
Ebru Nur Baytaroğlu, DDS¹
Haluk Barış Kara, PhD, DDS²
Özlem Kara, PhD, DDS³

INTRODUCTION

The use of implant-supported prostheses to replace missing natural teeth has become an accepted treatment approach in dentistry. Although implant prostheses have a high overall success rate, numerous complications have been reported, and the device sometimes fails. The biological complications associated with the use of the device include peri-implant radiolucency, peri-implantitis, and loss of osseointegration radiographically. Mechanical failure of implant components can manifest in the form of loosened screws, loss of retention, screw or fixture fracture, and porcelain or framework fracture.¹⁻³

Screw complications are caused by screw-joint instability, which may occur due to bruxism, unfavorable superstructure, overloading, malfunction, interceptive occlusal contact, metal fatigue after screw loosening, and component misfit.⁴⁻⁶ While several factors may affect screw complications, the most important are (1) adequate preload, (2) a precise fit of the mating implant components, and (3) basic antirotational characteristics of the implant and abutment interface. To avoid screw loosening, a precise fit between the mating implant components is very important; once a screw is loosened, the resulting metal fatigue may lead to screw fracture.¹ The most catastrophic mechanical complication is fixture fracture, which is usually caused by loss of the implant.⁷ The causes of fixture fractures in the posterior region include cantilevers, bruxism, and heavy occlusal forces; all lead to bending overload.^{8,9} To avoid fixture fracture, the manufacturer currently recommends the use of a wider diameter fixture and a third fixture, and offsetting the fixtures to achieve a tripod effect.¹⁰

When an abutment screw is fractured or deformed, it must be removed without damaging the implant body for the new abutment.¹¹ Location of the fracture along the abutment screw dictates the removal method of the broken fragments. If a fracture occurs above the implant head, an explorer, hemostat forceps, or straight probe may be successful in removing the fractured fragments. When the fracture occurs below the implant head, other specialized removal systems are required,

such as retrieval instruments (Nobel Biocare, Zurich, Switzerland), the Neo Screw Remover Kit (Neobiotech, Seoul, Korea), and the Implant Repair Kit (ITI Dental Implant System, Institute Straumann, AG, Waldenburg, Switzerland).¹²⁻¹⁵

Removal and replacement of the fractured fragment with a new abutment is the appropriate option for most patients, but in some patients, an alternative solution may be required. The present clinical report presents an alternative method for removal of a deformed abutment screw and trapped healing cup without damaging the implant components.

CLINICAL REPORTS

Patient 1

A 67-year-old partially edentulous women patient with type 2 diabetes was examined at the Department of Prosthodontics, Sifa University Faculty of Dentistry, Izmir, Turkey, due to a missing implant crown at teeth number #6, #7, and #8. On clinical and radiographic examination of the implant site, the abutment at right maxillary central incisor was healthy with no visible deformation, but at right maxillary lateral and canine, deformation was observed in the implant screw thread (Figure 1). Severe thread and neck deformation limited us to connect the abutment so that we did not try to solve the problem with searching the manufacturer's brand name.

The screw was impossible to retrieve due to the thread deformation, and the implants could not be removed because they were well osseointegrated and showed no signs of peri-implantitis. Furthermore, the duration of healing required to achieve a second osseointegration has not been determined in diabetic patients.¹⁶ An alternative treatment option was needed in this situation; therefore, a custom cast post was elected for the implant platform.

To secure the custom cast post, a hole was drilled into the implant screw with a diamond bur (Super Coarse, 180 to 200 µm, No:544; Acurata GmbH, Thurmansbang, Germany) in a high-speed handpiece (320 000 rpm) under water-cooling. An impression of the implant site was obtained using an endodontic file and a small amount of vinyl polysiloxane impression material (Speedex Light Body; Coltane/Whaledent, Altstätten, Switzerland; Figure 2). A second impression was then made using with a heavy-body silicone (Speedex Heavy Body, Coltane/Whaledent; Figure 3). Custom cast posts were fabricated in the dental laboratory using a chrome-cobalt alloy (Figure 4).

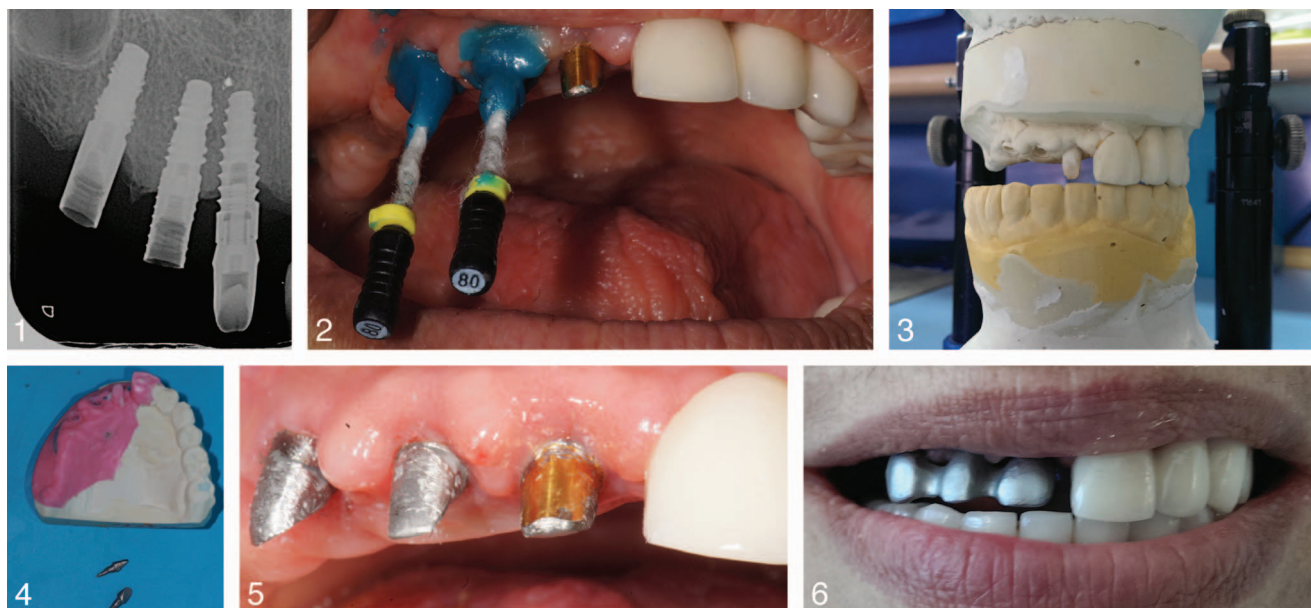
¹ Department of Prosthodontics, Sifa University, Izmir, Turkey.

² Department of Prosthodontics, Istanbul Medipol University, Istanbul, Turkey.

³ Department of Prosthodontics, Bezmi-alem Vakif University, Istanbul, Turkey.

* Corresponding author, e-mail: dilberhan@gmail.com

DOI: 10.1563/aaid-joi-D-14-00269



FIGURES 1–6. **FIGURE 1.** Patient 1: Radiograph of the deformed abutment screw in a 67-year-old female patient. The site at tooth number 11 is intact, but those at 12 and 13 show deformation in the screw threads. **FIGURE 2.** Impression of the custom cast post using polysiloxane material. **FIGURE 3.** Cast of the entire dental arcade for the custom cast posts using polysiloxane material. **FIGURE 4.** Custom cast posts were constructed from a chrome-cobalt alloy. **FIGURE 5.** Custom cast posts were cemented into the implant sites. **FIGURE 6.** Metal framework for restoration.

In a subsequent appointment, the custom cast posts were fitted at the implant site for proper fit. The posts were then cemented onto the implant platform with self-polymerize resin cement Panavia F 21 (Kuraray Medical Inc, Tokyo, Japan) and an impression was made for the metal-ceramic restorations with silicone mold (Speedex, Coltane/Whaledent; Figure 5). Metal-ceramic restorations for right maxillary central, lateral, and canine incisors were fabricated in the dental laboratory. The restorations were adjusted for retention, stability, vertical dimension, occlusal, and esthetic criteria, and then cemented with provisional implant resin cement (Premier Implant Cement, Premier Dental Product Company, Plymouth, Pa; Figures 6 and 7). The patient was scheduled for periodic referrals and 1 year following the initial treatment, no mobility, bleeding, radiolucency, nor peri-implantitis were observed. The surgeon put 2 implants at the posterior region with bone graft (Figure 8).

Patient 2

A 45-year old male partially edentulous patient was examined at the Department of Prosthodontics, Selçuk University Faculty of Dentistry, Konya, Turkey, due to a missing crown at mandibular left second premolar. The patient had a standard Straumann 4.1-mm platform diameter regular neck (RN) implant with wedged healing cap at mandibular left second premolar.

On clinical and radiographic examination of the implant site, an implant with a wedged healing cap was observed at mandibular left second premolar (Figure 9a). The healing cap could not be removed with torque meter with reverse direction. Therefore, a custom cast post was recommended

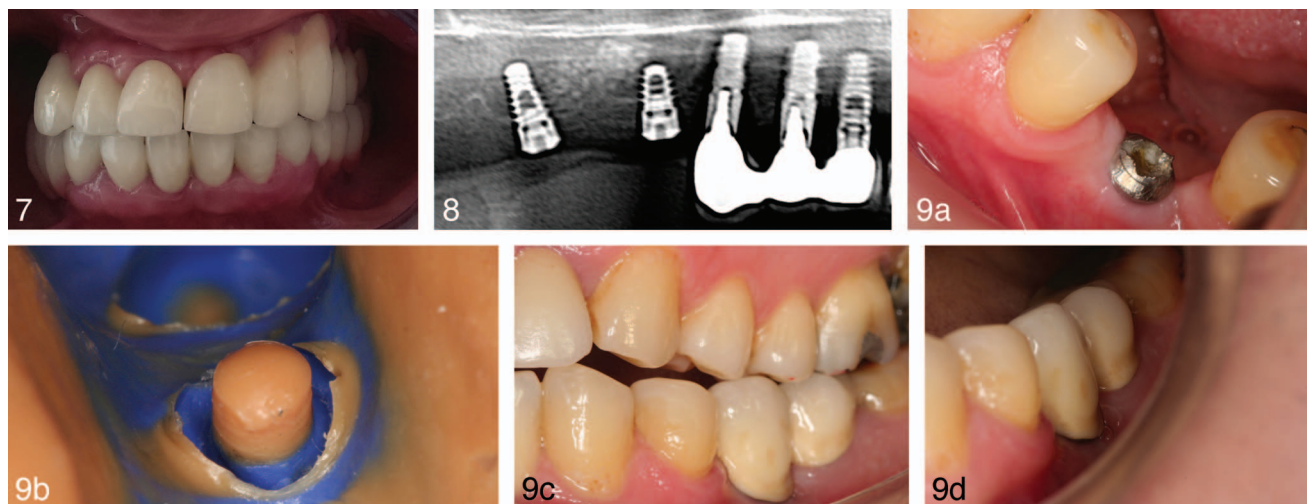
for the implant platform using the same clinical and laboratory preparation as described for patient 1.

To secure the custom cast post, a hole was drilled into the implant screw using a diamond bur (Super Coarse, 180 to 200 µm, No:544; Acurata GmbH) in a high-speed handpiece (320 000 rpm) under water-cooling, and a direct impression was made on the implant platform with silicone mold (Speedex, Coltane/Whaledent; Figure 9b). The custom cast post was fabricated in the dental laboratory, cemented onto the implant platform with C & B Metabond (Parkell Products, Farmingdale, NY), and the impression made for the metal-ceramic restoration with silicone mold (Speedex, Coltane/Whaledent). The metal-ceramic restoration of mandibular left second premolar was fabricated in the dental laboratory and cemented onto the implant platform with provisional implant resin cement (Premier Implant Cement, Premier Dental Product Company; Figure 9c). The patient was scheduled for periodic referrals and 1 year following the initial treatment (Figure 9d).

DISCUSSION

At present, only 2 reports describe a technique to convert the screw chamber into a custom cast post space and construct a post-core for prosthetic treatment.^{17,18} Both these reports present a similar solution for prosthetic treatment of a screw fracture.

In this clinical report, the first patient underwent prosthetic treatment of an implant with a deformed screw thread, and the second patient had a lodged healing cap that could not be removed from the implant platform. The implant manufacturer for the first patient was unknown. Implant removal was not



FIGURES 7–9. **FIGURE 7.** Metal-ceramic restoration. **FIGURE 8.** Radiography after 1 year follow-up. **FIGURE 9.** (a) Patient 2: A wedged healing cup was present at mandibular left second premolar. (b) Impression of the custom cast post. (c) Buccal view of the metal-ceramic restoration. (d) Restoration after 2 years' follow-up.

considered in either situation because the sites were healthy except for the screw thread deformation. The implants were osseointegrated, the bone showed no signs of peri-implantitis, and the patients declined implant removal. Moreover, removal of the deformed and wedged screws was impossible. The first patient was diabetic, and the duration of bone remodeling and healing time has not been established for diabetic patients; thus, implant removal was not considered.¹⁶ In both patients, an individual cast post was used as an abutment for restoration with fixed metal-ceramic crowns, minimizing the time and cost of a new implant.

Previous studies recommend removal and replacement of a fractured screw with a new screw, being sure to avoid damage to the internal implant threads.^{18,19} However, in some patients, implant removal is impossible, as in the patients described in the present study. An alternative protocol was used in the present clinical report; namely, custom cast posts on the implant platform served as an abutment for restoration with a fixed prosthesis. This method is conservative, easy to perform, cost-effective, quick, and does not require additional equipment, but it should be employed judiciously to prevent further complications such as loosening or fracturing of the custom cast posts.¹⁸ Several factors are important to consider avoiding these complications, including effective cementation of the custom post and implant components, control of occlusion, elimination of interceptive contact, and avoidance of excessive masticatory force and parafunctional activities such as bruxism.^{13,20} In this report, the custom cast posts were cemented onto the implant platform with self-cure resin cement Panavia F 21 containing MDP to improve its adhesive performance to the titanium, as a previous report strongly suggests that MDP is an effective resin.²¹

CONCLUSION

Custom cast posts as an abutment may be an alternative option when a deformed screw thread and wedged healing cup cannot be removed.

REFERENCES

1. Binon P, Sutter F, Beatty K, Brunski J, Gulbransen H, Weiner R. The role of screws in implant systems. *Int J Oral Maxillofac Implants.* 1994;9:48–63.
2. Schwarz MS. Mechanical complications of dental implants. *Clin Oral Implants Res.* 2000;11:156–158.
3. Bragger U, Aeschlimann S, Burgin W, Hammerle CH, Lang NP. Biological and technical complications and failures with fixed partial dentures (FPD) on implants and teeth after four to five years of function. *Clin Oral Implants Res.* 2001;12:26–34.
4. Goodacre CJ, Kan JY, Rungcharassaeng K. Clinical complications of osseointegrated implants. *J Prosthet Dent.* 1999;81:537–552.
5. Eckert SE, Meraw SJ, Cal E, Ow RK. Analysis of incidence and associated factors with fractured implants: a retrospective study. *Int J Oral Maxillofac Implants.* 2000;15:662–667.
6. Bakaeen LG, Winkler S, Neff PA. The effect of implant diameter, restoration design, and occlusal table variations on screw loosening of posterior single-tooth implant restorations. *J Oral Implantol.* 2001;27:63–72.
7. Adell R, Eriksson B, Lekholm U, Branemark PI, Jemt T. Long-term follow-up study of osseointegrated implants in the treatment of totally edentulous jaws. *Int J Oral Maxillofac Implants.* 1990;5:347–359.
8. Rangert B, Krogh PH, Langer B, Van Roekel N. Bending overload and implant fracture: a retrospective clinical analysis. *Int J Oral Maxillofac Implants.* 1995;10:326–334.
9. Balshi TJ. An analysis and management of fractured implants: a clinical report. *Int J Oral Maxillofac Implants.* 1996;11:660–666.
10. Rangert B. Biomechanical principles preventing prosthetic overload induced by bending. *Nobelpharma news.* 1993;7:4–5.
11. Luterbacher S, Fourmoussis I, Lang NP, Bragger U. Fractured prosthetic abutments in osseointegrated implants: a technical complication to cope with. *Clin Oral Implants Res.* 2000;11:163–170.
12. Williamson RT, Robinson FG. Retrieval technique for fractured implant screws. *J Prosthet Dent.* 2001;86:549–550.
13. Maalagh-Fard A, Jacobs LC. Retrieval of a stripped abutment screw: a clinical report. *J Prosthet Dent.* 2010;104:212–215.
14. Taira Y, Sawase T. A modified technique for removing a failed abutment screw from an implant with a custom guide tube. *J Oral Implantol.* 2012;38:165–169.
15. Satwalekar P, Chander KS, Reddy BA, Sandeep N, Sandeep N, Satwalekar T. A simple and cost effective method used for removal of a fractured implant abutment screw: a case report. *J Int Oral Health.* 2013;5:120–123.
16. Branemark PI, Adell R, Breine U, Hansson BO, Lindstrom J, Ohlsson A. Intra-osseous anchorage of dental prostheses. I. Experimental studies. *Scand J Plast Reconstr Surg.* 1969;3:81–100.

17. Gupta V, Prithviraj DR, Muley N. A new restorative technique for the perishing implant due to abutment screw fracture. *J Oral Implantol.* 2014;40: 755–757.

18. Canpolat C, Ozkurt-Kayahan Z, Kazazoglu E. Management of a fractured implant abutment screw: a clinical report. *J Prosthodont.* 2014;23: 402–405.

19. Pow EH, Wat PY. A technique for salvaging an implant-supported crown with a fractured abutment screw. *J Prosthet Dent.* 2006;95:169–170.

20. Nergiz I, Schmäge P, Shahin R. Removal of a fractured implant abutment screw: a clinical report. *J Prosthet Dent.* 2004;91:513–517.

21. Tsuchimoto Y, Yoshida Y, Mine A, et al. Effect of 4-MET- and 10-MDP-based primers on resin bonding to titanium. *Dent Mater J.* 2006;25: 120–124.