

# Clinical and Radiographic Evaluation of Immediate Loaded Dental Implants With Local Application of Melatonin: A Preliminary Randomized Controlled Clinical Trial

Mona Y. El-Gammal, MSc<sup>1\*</sup>  
 Ahmed S. Salem, PhD<sup>1,2</sup>  
 Mohamed M. Anees, PhD<sup>3</sup>  
 Mohamed A. Tawfik, PhD<sup>1</sup>

Immediate loading of dental implants in situations where low bone density exist, such as the posterior maxillary region, became possible recently after the introduction of biomimetic agents. This 1-year preliminary clinical trial was carried out to clinically and radiographically evaluate immediate-loaded 1-piece implants with local application of melatonin in the osteotomy site as a biomimetic material. 14 patients with missing maxillary premolars were randomized to receive 14 implants of 1-piece type that were subjected to immediate loading after 2 weeks of initial placement. Group I included 7 implants with acid-etched surface while group II included 7 implants with acid-etched surface combined with local application of melatonin gel at the osteotomy site. Patients were recalled for follow up at 1, 3, 6, and 12 months after loading. All implants were considered successful after 12 months of follow-up. Significant difference ( $P < 0.05$ ) was found between both groups at 1 month of implant loading when considering the implant stability. At 1 and 3 months there were significant differences in the marginal bone level between the 2 groups. These results suggest that the local application of melatonin at the osteotomy site is associated with good stability and minimal bone resorption. However, more studies for longer follow-up periods are required to confirm the effect of melatonin hormone on osseointegration of dental implants.

**Key Words:** one-piece, implant, melatonin, acid-etched, immediate loading

## INTRODUCTION

Good osseointegration is a prerequisite for immediate loading of dental implants. Optimal osseointegration depends on the formation of new bone around implants, which may be stimulated by the application of biomimetic agents.<sup>1</sup>

Considering the bone metabolism, melatonin acts directly on the osteoclast, a multinucleated cell, which resorbs the extracellular matrix through various mechanisms, including the production of free radicals.<sup>2</sup> Also, melatonin, may interfere with the function of the osteoclast and thereby inhibit bone resorption.<sup>3</sup>

These actions of melatonin on bone tissue are of interest as it may be possible to apply melatonin during endosseous dental implant surgery as a biomimetic agent. As a result, the healing process may be more precise, initial conditions of

receptor tissues may be enhanced, the period of osteointegration and settling of the implant maybe shortened.<sup>4</sup>

Cutando et al,<sup>5</sup> conducted an experimental study using melatonin with dental implants in dogs. Two weeks after implant insertion, melatonin significantly increased all parameters of osteointegration.<sup>5</sup>

Considering the next step of the application of melatonin in clinical dentistry, the present study is designed to clinically and radiographically evaluate the effect of Melatonin when locally applied in the osteotomy site before one piece implant insertion.

## MATERIALS AND METHODS

The study followed the Declaration of Helsinki on medical protocol and ethics and was approved by the Regional Ethical Review Board of Mansoura University. This study was performed at the Oral and Maxillofacial Surgery Department, Faculty of Dentistry, Mansoura University from January 2013 to April 2014. Patients with missing maxillary premolars were asked to participate in the study after signing an informed consent. The selected cases should have adequate amount of bone vertically and horizontally in the edentulous area as well as adequate occlusion. For patient demographic data, please refer to Table 1.

<sup>1</sup> Oral and Maxillofacial Surgery Department, Faculty of Dentistry, Mansoura University, Mansoura, Egypt.

<sup>2</sup> OMFS-IMPACT Research Group, Department of Imaging and Pathology, Faculty of Medicine, University of Leuven and Department of Maxillofacial Surgery, University Hospitals Leuven, Leuven, Belgium.

<sup>3</sup> Oral Medicine and Periodontology Department, Faculty of Dentistry, Mansoura University, Mansoura, Egypt.

\* Corresponding author, e-mail: monayelgammal@gmail.com

DOI: 10.1563/aaid-joi-D-14-00277

TABLE 1

Demographic data for the patients who participated in the study

	Age		Gender		Menopausal		Smoking		Systemic Disease	
	≤ 30 y	> 30 y	Male	Female	Pre	Post	Smoke	Non	With	Without
Received melatonin	7	10	5	9	9	0	0	14	0	14
	2	5	3	4	4			7		7

Fourteen single-piece, sandblasted, acid-etched endosseous implants (Dentium Co Ltd Dang-dong, Gunpo-si, Gyeonggi-do, Korea) were used to restore missing upper premolars. Implant length was 10 mm and width was 3.5 mm. Patients were randomly divided into 2 groups: group I (study group): patients received implants with local application of melatonin gel, group II (control group): patient received implants without local application of melatonin. Melatonin gel was prepared by mixing the melatonin powder with propylene glycol (1.2 mL) to act as a carrier. According to the study reported by Cutando et al<sup>5</sup> the estimated dose of melatonin required to enhance osseointegration of dental implant and minimize the marginal bone resorption is 1.2 mg of melatonin powder for each implant. In our study, we used 1 mL of 1.2 mg/mL of melatonin gel for each implant.

For proper implant placement, surgical stents and preoperative radiographs were obtained. All patients were instructed to use chlorhexidine 0.12% mouthwash and amoxicillin 500 mg 4 times daily (Emox, Egyptian Int Pharmaceutical Industries Co, E.I.P.C.O., A.R.E., 10th of Ramadan city, Cairo, Egypt) or erythromycin 500 mg 4 times daily (SEDICO, 1st industrial zone, 6th of October city, Cairo, Egypt) in case of sensitivity to penicillin for 5 days starting from the day before the operation.

After local anesthetic infiltration, a mucoperiosteal flap was reflected. Manufacturer's instructions were followed for the preparation of the implant osteotomy site. A series of drills used included: 1.8, 2, and 2.6 mm. For group I, 1 mL of 1.2 mg/mL of melatonin gel was injected in each osteotomy site before the insertion of the implant. For group II, no melatonin gel was injected and implants were inserted directly after the irrigation of the prepared implant site (Figures 1 and 2).

Sutures were placed after flap replacement, immediate preoperative radiographs were obtained, and immediate temporary composite crowns were inserted. Patients were instructed to use soft diet and proper oral hygiene measures. Permanent metal fused to porcelain crowns were cemented within 2 weeks of implant insertion.

Patients were followed up regularly at 3, 6, and 12 months. Periapical standard parallel radiographs were taken and converted to a soft copy. A digital radiographic analysis (ImageJ software, 1.42q, Wayne Rasband, National Institutes of Health, Bethesda, Md) was done to measure the marginal bone loss (MBL).

The clinical evaluation comprised

- (1) Implant stability using Periotest.
- (2) Gingival health according to the angulated bleeding index (AngBI). A periodontal probe was passed along the buccal margin at 60° angulation in the gingival sulcus. The resultant bleeding was recorded as present (+) or absent (-).<sup>6</sup>

(3) Peri-implant propping depth was measured mesially and distally using a graduated periodontal probe.

(4) Esthetics: Digital photographs were used for were used for evaluation of the pink esthetic score (PES). Charts containing the 7 variables were designed. These include: mesial papilla, distal papilla, soft-tissue level, soft-tissue contour, alveolar process deficiency, soft-tissue color, and texture. Each variable was recorded with a 2–1–0 score, where 2 is the best and 0 is the poorest score.

The collected data was statistically analyzed in the form of mean ± SD. Student *t* test was used to compare between mean of 2 groups of numerical (parametric) data. Intergroup comparison of categorical data was performed by using chi square test.

RESULTS

At the end of the 1-year follow-up period, all implants were considered successful.

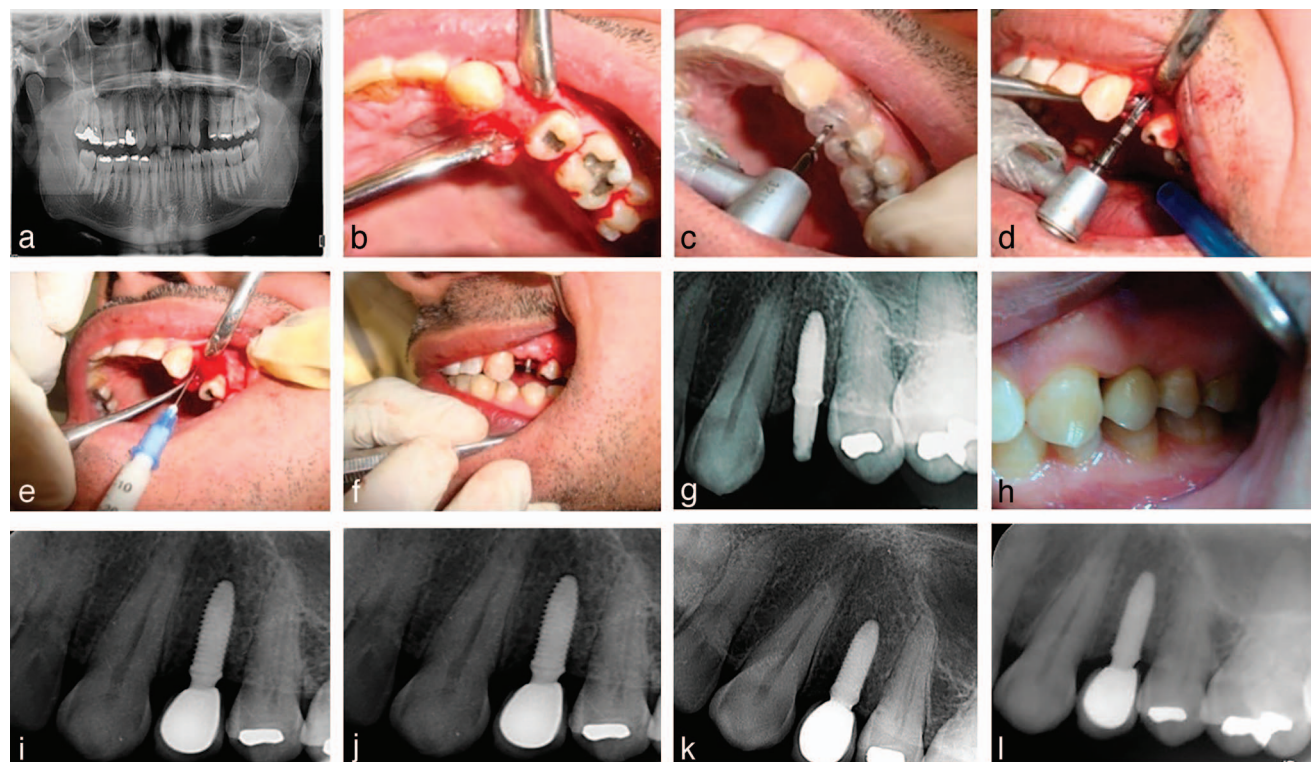
Adequate implant stability was obtained at regular follow-up periods for both groups. However, better values of the Periotest measurements (BTM) were observed in the study group. There was significantly higher implant stability for group I at 1 month (*P* = 0.01). At subsequent follow-up periods, there was no significant statistical difference in the BTM between the 2 groups (Table 2).

The PES at the time of permanent crown placement was good for both groups. The mean values of PES for the study and control groups were 10.6 ± 1.13 and 10.14 ± 0.69, respectively. There was no significant statistical difference between the 2 groups (*P* = 0.4; Figure 3).

The gingival health was accepted for both groups despite the recorded 2 cases with positive (AgBI) values at 1 month among the control group (*P* = 0.35).

The probing depth measurements for both groups lied within normal limits and they were less than 2 mm, which is considered one of the successful criteria of dental implants. The data about mesial and distal probing depth throughout the 1-year of follow-up were shown in Table 2. There was no significant difference when comparing the probing depth of the study and control groups.

MBL was measured at 1, 3, 6, and 12 months and all values were within the accepted limit for dental implants. The mean MBL at 1 month for the study group was 0.34 ± 0.12 and 0.98 ± 0.29 for the control group. At 3 months the mean MBL for the study group was 0.60 ± 0.16 and 1.1 ± 0.41 for the control group. There were significant statistical differences between the 2 groups at 1 and 3 months (*P* = 0.001 and 0.01), respectively (Table 2).



**FIGURE 1.** Series of photographs for one-piece implant placement with local application of melatonin gel and follow-up of digital standard periapical radiographs. (a) Preoperative panoramic radiograph. (b) A photograph shows a raised flap at the implant premolar site. (c–f) shows the implant placement and local melatonin application. (g) Immediate post insertion radiograph. (h) Photograph shows final prosthetic restoration in place and in occlusion, 2 weeks after initial implant placement. (i–l) Periapical radiographs show levels of marginal bone loss around the implant after 3, 6, and 12 months, respectively.

Different evaluation criteria are compared to each other in both study and control groups in Table 3. There was a significant difference between the MBL and the depth of the distal pocket in the study group. Also, a significant difference was found between the distal pocket depth and the Periotest measurements in the control group.

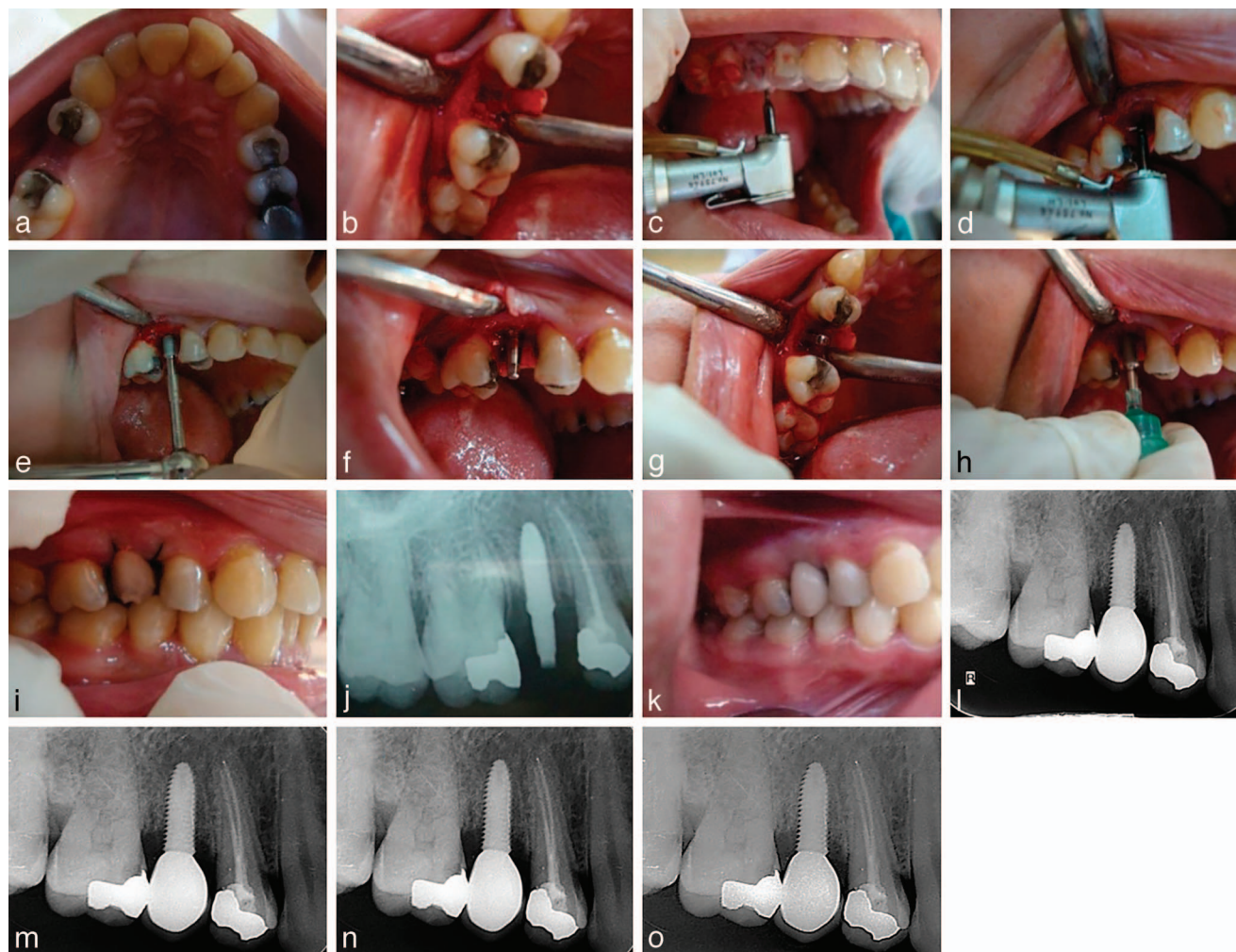### DISCUSSION

While several randomized controlled trials and reviews have demonstrated clinical efficiency in shortening the time of loading for edentulous patients,<sup>8–11</sup> it is critical for providing rigid fixation of a dental implant within the alveolar bone and

promoting the long-term success of dental implants.<sup>12,13</sup> One of the most widely investigated topics is searching for novel biomaterials to improve the host/implant tissue response.<sup>14,15</sup> Melatonin, by the regulation of RANKL and osteoprotegerin synthesis and release from osteoblasts, can induce osteoblastogenesis and at the same time inhibit osteoclastogenesis. In addition, melatonin's free-radical scavenging and antioxidant properties are additional mechanism by which melatonin can maintain the bone health. Recently, melatonin is used in bone-grafting procedures, in reversing bone loss due to osteopenia and osteoporosis, and in treating periodontal diseases.<sup>16</sup>

The present study compared the topical application of melatonin gel at the implant osteotomy site (group I) with those without local application of melatonin (group II).

	Periotest Measurements			Mesial Probing Depth			Distal Probing Depth			Marginal Bone Level		
	Study Group (n = 7)	Control Group (n = 7)	P	Study Group (n = 7)	Control Group (n = 7)	P	Study Group (n = 7)	Control Group (n = 7)	P	Study Group (n = 7)	Control Group (n = 7)	P
1 month	-1.28 ± 0.76	0.85 ± 1.77	0.01	0.90 ± 0.19	1.00 ± 0.31	0.4	1.1 ± 0.19	0.85 ± 0.24	0.054	0.34 ± 0.12	0.98 ± 0.29	0.001
3 months	0 ± 0.58	0.42 ± 0.78	0.2	1.35 ± 0.24	1.50 ± 0.41	0.4	1.14 ± 0.24	0.94 ± 0.09	0.054	0.60 ± 0.16	1.1 ± 0.41	0.01
6 months	-1.71 ± 1.25	-1.5 ± 0.77	0.38	1.54 ± 0.31	1.57 ± 0.35	0.88	1.5 ± 0.17	1.35 ± 0.24	0.26	1.05 ± 0.33	1.35 ± 0.56	0.2
12 months	-2.14 ± 1.57	-2 ± 0.58	0.45	1.67 ± 0.32	1.78 ± 0.39	0.4	1.75 ± 0.25	1.64 ± 0.19	0.36	1.38 ± 0.43	1.57 ± 0.57	0.27



**FIGURE 2.** Series of photographs for one-piece implant placement without local melatonin application and follow-up of digital standard periapical radiographs. (a) and (b) A perioperative photograph and flap reflection. (c–h) Photographs show the steps of implant placement. (i) and (j) Photograph and a radiograph show the implant in place after initial placement. (k) A photograph shows final prosthetic restoration in place and in occlusion, 2 weeks after initial implant placement. (l–o) Periapical radiographs show levels of marginal bone loss around the implant after 3, 6, and 12 months, respectively.

At 1 month of follow-up, the PTM in group I in the present study were significantly more than the PTM in group II. It is well known that the implant stability is directly related to the percentage of the bone to implant contact area.<sup>17</sup> Cutando et al<sup>5</sup> showed that after a 2-week treatment period, melatonin significantly increased the perimeter of bone that was in direct contact with the treated implants, bone density, new bone formation, and interthread bone.

The same outcome also was demonstrated by Guardia et al<sup>18</sup> They found that after 5- and 8-week treatment periods, melatonin significantly increased the interthread bone and new bone formation in comparison to control implants in both weeks. Moreover, in a further study performed by Guirado et al<sup>19</sup>, the results revealed that melatonin plus porcine bone significantly increased the perimeter of bone that was in direct contact with the treated implants.

Our results can be explained by the biological effect of

melatonin on bone such as the modulation of bone formation and resorption.<sup>20</sup> This could be explained by 3 principal actions. First, melatonin increases pre-osteoblast/osteoblast/osteoblast-like cell proliferation, promotes the expression of type I collagen and bone marker proteins (eg, alkaline phosphatase, osteopontin, bone sialoprotein, and osteocalcin), and stimulates the mineralized matrix formation in these cells<sup>21–23</sup>.

In addition, melatonin prevents the differentiation of osteoclasts by reducing the expression of RANK mRNA and increases in both the mRNA and protein levels of osteoprotegerin.<sup>24</sup> Secondly, melatonin can indirectly regulate bone metabolism via the interaction with systemic hormones (eg, PTH, calcitonin, and estrogen) or other molecules. Ladizesky et al<sup>25</sup> showed that estradiol treatment might prolong the effect of melatonin to enhance bone remodeling in ovariectomized rats. The third mechanism is that osteoclasts create high levels of superoxide anions during bone resorption that is linked to

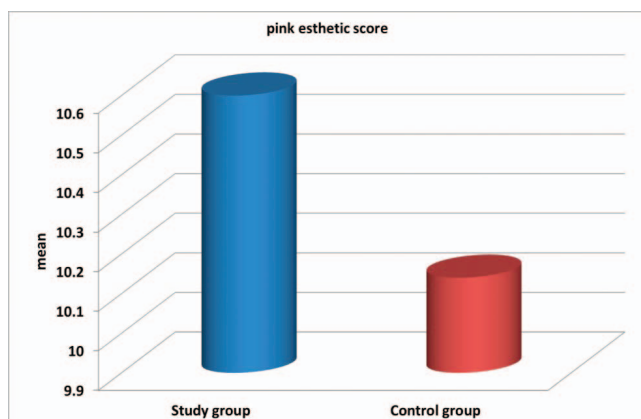


FIGURE 3. The pink esthetic score for study and control groups.

the degradative process. Melatonin can remove these free radicals and protect bone cells from oxidative attacks.<sup>26</sup>

An interesting study by Witt-Enderby et al<sup>27</sup> showed that hormone replacement therapy (HRT) alone increased surface bone, reduced trabecular space, and decreased the number of osteoclasts without affecting osteoblasts. Chronic HRT + melatonin therapy did not significantly increase bone density, although this combination significantly increased BGLAP mRNA levels. HRT with or without nocturnal melatonin in cycling mice showed unique effects on bone markers and bone density. The effects of estrogen/progesterone- or melatonin-based therapies alone and combined may enhance the bone health in women in perimenopause and with low nocturnal melatonin levels as a result of too little sleep, too much light, or age. However, in the present study all the female patients were premenopausal and their implants were successful when combined with melatonin application. Further studies are required to compare the effect of melatonin in premenopausal, perimenopausal, or postmenopausal females.

Our results showed that in both groups, the PTM were decreased at 3 months of follow up and then elevated at 6 months to values very close to those observed at 1 month. This result suggests that the roughness caused by surface treatment increases the friction between the implant surface and bone, influencing primary stability.<sup>28,29</sup>

Moreover, in pre-osteoblast cultures from rats, melatonin, in a dose-dependent manner, promoted the development of bone sialoprotein and other protein bone markers, including alkaline phosphatase, osteopontin, and osteocalcin, and speeds up their period of differentiation into osteoblasts from the normal rate, which is 21 days, to 12 days. This reaction is mediated by the membrane receptors for the indole.<sup>2</sup>

Another study<sup>21</sup> showed that melatonin stimulates certain genes which control the presence of determined proteins at the osteoid matrix. Accordingly, it has been shown that melatonin is capable, after a period of 5 and 9 days, of stimulating the presence of osteocalcin, sialoprotein, and alkaline phosphatase. Also, this could be explained by a greater percentage of interthread bone and new bone formation around the implants treated with topical melatonin.

Interthread bone is an intermediate situation of new bone in contact with the implant by stimulation of osteoblasts and

Groups	P		
	Mesial Pocket Depth	Distal Pocket Depth	Marginal Bone Level
Study group			
Periotest	0.945	0.057	0.563
Mesial pocket depth		0.116	0.424
Distal pocket depth			0
Control group			
Periotest	0.972	0	0.095
Mesial pocket depth		0.505	0.098
Distal pocket depth			0.292

the old bone in the total peri-implant area by osteoclast inhibition, and melatonin continues its activity passing on from the second to the fifth week and to the eighth week.<sup>21,30</sup>

At 1 and 3 months of follow-up, the implants in the study group showed a significant less marginal bone loss. This was in agreement with the findings of Guardia et al.<sup>31</sup> They stated that melatonin acts by inhibiting the action of osteoclasts. This is a direct action lasting for a very short time, as there is no bone remodeling but only the existence of interthread bone and total peri-implant bone area. For this reason, melatonin continues to act on a part of the bone that has suffered aggressive placement of the implant, necessitating remodeling by osseous matrix production, which requires 5 to 8 weeks.<sup>32</sup>

The enhanced osseointegration and minimal bone changes at the first follow-up assessment in our study was in the same line with Clafshenkel et al<sup>33</sup> who showed that CA-Mel scaffolds, when compared with CA scaffolds, improved the adhesion, viability, and proliferation of normal human osteoblasts cells but not that of NIH3T3 fibroblasts. Moreover, human adult mesenchymal stem cells grown on CA or CA-Mel scaffolds have a time-dependent induction into osteoblasts over 14 days. The improved MBL at 3 and 6 months in the study group continued was also in concomitance with the studies of Clafshenkel et al<sup>33</sup> who showed that the implantation of CA-Mel scaffolds into critical size calvarial defects in female, ovariectomized rats have the ability to allow for tissue infiltration, and scaffold biodegradation by 3 and 6 months.

Regarding the gingival health, no patients in group I showed a positive AngBI while only 2 patients showed a positive AngBI in group II. This was in agreements with Gomez-Florit et al who suggested that melatonin could protect and recover the integrity of gingival tissues as it increases collagen, decorin, and IL10 expression, reduces the matrix metalloproteinase-1/tissue inhibitor of metalloproteinases-1 ratio, and promotes wound healing without scars, in addition to its antioxidant properties.<sup>34</sup>

There was no statistical significant difference between both groups when comparing the PES at the time of placement of permanent restorations. Both groups showed an acceptable PES and this may be related to the 1-stage immediate loaded protocol, which allows undisturbed healing of the soft tissue as well as the immediate provisionalization, which helps the

surrounding soft tissue to take the emergence profile around the crown resampling the appearance of natural gingiva.

Considering the pre-implant pocket depth, there was no significant statistical difference between both groups at mesial or distal pockets at 1, 3, 6, and 12 months of follow-up. This can be explained by the 1-piece implant design and the single-stage surgical protocol. This was in agreement with Garcia et al<sup>35</sup> who found that while there was no significant difference considering the pocket depth, gingival health, and plaque retention between single-stage and 2-stage implants, there was an advantage of single-stage implants protocol over the other surgical protocol, which is the retaining of a band of keratinized mucosa.

However, the slight decrease in the pocket depth and the significant difference between the distal pocket depth and marginal bone level that were observed in group I could be related to the anti-inflammatory and anti-osteoclastic activity of melatonin. Melatonin has an anti-inflammatory effect, is a free radical scavenger, and is a stimulator of antioxidant enzymes. Also, melatonin levels are correlated with the periodontal health status, indicating that it may have a protective role in periodontal disease. Moreover, it has antibacterial effects against gram-positive and gram-negative bacteria by decreasing the availability of intracellular substrates, such as free iron and fatty acids.<sup>36</sup>

Also the decrease in pocket depth in our study group can be explained according to Srinath et al who revealed that melatonin was expressed in the gingival crevicular fluid (GCF). Salivary and GCF melatonin levels decreased in patients with periodontitis compared to their levels in healthy patients suggesting that melatonin may protect from periodontal diseases.<sup>36,37</sup>

#### CONCLUSION

Based on the limitations of this study, such as the small sample size and early follow-up, we can conclude that the topical application of melatonin at the osteotomy site at the time of implant placement is associated with good implant stability and minimal marginal bone loss, which are indicators of a good osseointegration.

The topical melatonin application could be a good treatment option for immediate loaded dental implants especially in posterior maxilla. We recommend further studies in the future with long-term follow-up and on a wide scale.

#### ABBREVIATIONS

AngBI: angulated bleeding index  
BTM: better values of Periotest measurements  
GCF: gingival crevicular fluid  
HRT: hormonal replacement therapy  
MBL: marginal bone loss  
PES: pink esthetic score

#### ACKNOWLEDGMENTS

The authors would like to thank Mansoura University for funding. There was no conflict of interest.

#### REFERENCES

- Ramazanoglu M, Lutz R, Ergun C, von Wilmsowky C, Nkenke E, Schlegel KA. The effect of combined delivery of recombinant human bone morphogenetic protein-2 and recombinant human vascular endothelial growth factor 165 from biomimetic calcium-phosphate-coated implants on osseointegration. *Clin Oral Implants Res.* 2011;22:1433–1439.
- Roth JA, Kim BG, Lin WL, Cho MI. Melatonin promotes osteoblast differentiation and bone formation. *J Biol Chem.* 1999;274:22041–22047.
- Cardinali DP, Ladizesky MG, Boggio V, Cutrera RA, Mautalen C. Melatonin effects on bone: experimental facts and clinical perspectives. *J Pineal Res.* 2003;34:81–87.
- Maldonado MD, Murillo-Cabezas F, Terron MP, et al. The potential of melatonin in reducing morbidity-mortality after craniocerebral trauma. *J Pineal Res.* 2007;42:1–11.
- Cutando A, Gomez-Moreno G, Arana C, et al. Melatonin stimulates osteointegration of dental implants. *J Pineal Res.* 2008;45:174–9.
- Van der Weijden GA, Timmerman MF, Nijboer A, Reijerse E, Van der Velden U. Comparison of different approaches to assess bleeding on probing as indicator of gingivitis. *J Clin Periodontol.* 1994;21:589–594.
- Lai HC, Zhang ZY, Wang F, Zhuang LF, Liu X, Pu YP. Evaluation of soft tissue alteration around implant-supported single-tooth restoration in the anterior maxilla: the pink esthetic score. *Clin Oral Implant Res.* 2008;19:560–564.
- Fischer K, Stenberg T, Hedin M, Sennerby L. Five-year results from a randomized, controlled trial on early and delayed loading of implants supporting full-arch prosthesis in the edentulous maxilla. *Clin Oral Implants Res.* 2008;19:433–441.
- Raghoebar GM, Meijer, HJ, Van't Hof M, Stegenga B, Vissink A. A randomized prospective clinical trial on the effectiveness of three treatment modalities for patients with lower denture problems. A 10 year follow-up study on patient satisfaction. *Int J Oral Maxillofac Surg.* 2003;32:498–503.
- Attard NJ, Zarb GA. Immediate and early implant loading protocols: a literature review of clinical studies. *J Prosthet Dent.* 2005;94:242–258.
- Cooper L, De Kok IJ, Reside GJ, Pungpapong P, Rojas-Vizcay F. Immediate fixed restoration of the edentulous maxilla after implant placement. *J Oral Maxillofac Surg.* 2005;63:97–110.
- Franchi M, Fini M, Martini D, et al. Biological fixation of endosseous implants. *Micron* 2005;36:665–671.
- Joos U, Wiesmann HP, Szuwart T, Meyer U. Mineralization at the interface of implants. *Int J Oral Maxillofac Surg.* 2006;35:783–790.
- Simon Z, Watson PA. Biomimetic dental implants—new ways to enhance osseointegration. *J Can Dent Assoc.* 2002;68:286–288.
- Gao SS, Zhang YR, Zhu ZL, Yu HY. Micromotions and combined damages at the dental implant/bone interface. *Int J Oral Sci.* 2013;4:182–188.
- Maria S, Witt-Enderby PA. Melatonin effects on bone: potential use for the prevention and treatment for osteopenia, osteoporosis, and periodontal disease and for use in bone-grafting procedures. *J Pineal Res.* 2014;56:115–125.
- Scarano A, Degidi M, Iezzi G, Petrone G, Piattelli A. Correlation between implant stability quotient and bone-implant contact: a retrospective histological and histomorphometrical study of seven titanium implants retrieved from humans. *Clin Implant Dent Relat Res.* 2006;8:218–222.
- Guardia J, Gomez-Moreno G, Ferrera MJ, Cutando A. Evaluation of effects of topical melatonin on implant surface at 5 and 8 weeks in Beagle dogs. *Clin Implant Dent Relat Res.* 2011;13:262–268.
- Calvo-Guirado JL, Gomez-Moreno G, Lopez-Mari L, et al. Actions of melatonin mixed with collagenized porcine bone versus porcine bone only on osteointegration of dental implants. *J Pineal Res.* 2010;48:194–203.
- Ostrowska Z, Kos-Kudla B, Nowak M, et al. The relationship between bone metabolism, melatonin and other hormones in sham-operated and pinealectomized rats. *Endocr Regul.* 2003;37:211–224.
- Radio NM, Doctor JS, Witt-Enderby PA. Melatonin enhances alkaline phosphatase activity in differentiating human adult mesenchymal stem cells grown in osteogenic medium via MT2 melatonin receptors and the ME K/ERK (1/2) signaling cascade. *J Pineal Res.* 2006;40:332–342.
- Satomura K, Tobiume S, Tokuyama R, et al. Melatonin at pharmacological doses enhances human osteoblastic differentiation in vitro and promotes mouse cortical bone formation in vivo. *J Pineal Res.* 2007;42:231–239.
- Sethi S, Radio NM, Kotlarczyk MP, et al. Determination of the minimal melatonin exposure required to induce osteoblast differentiation from human mesenchymal stem cells and these effects on downstream signaling pathways. *J Pineal Res.* 2010;49:222–238.

24. Koyama H, Nakade O, Takada Y, Kaku T, Lau KH. Melatonin at pharmacologic doses increases bone mass by suppressing resorption through down-regulation of the RANKL-mediated osteoclast formation and activation. *J Bone Miner Res.* 2002;17:1219–1229.
25. Ladizesky MG, Boggio V, Alborno LE, Castrillon PO, Mautalen C, Cardinali DP. Melatonin increases oestradiol-induced bone formation in ovariectomized rats. *J Pineal Res.* 2003;34:143–151.
26. Gomez-Moreno G, Guardia J, Ferrera MJ, Cutando A, Reiter RJ. Melatonin in diseases of the oral cavity. *Oral Dis.* 2010;16:242–247.
27. Witt-Enderby PA, Slater JP, Johnson NA. Effects on bone by the light/dark cycle and chronic treatment with melatonin and/or hormone replacement therapy in intact female mice. *J Pineal Res.* 2012;53:374–384.
28. González JMM, Sabán FG, Bernal JF, Lafuente JCG, Sánchez JC, Dorado CB. Removal torque and physico-chemical characteristics of dental implants etched with hydrofluoric and nitric acid. An experimental study in beagle dogs. *Med Oral Patol Oral Cir Bucal.* 2006;11:281–285.
29. Stüker RA, Teixeira ER, Beck JCP, Costa NP. Preload and torque removal evaluation of three different abutment screws for single standing implant restorations. *J Appl Oral Sci.* 2008;16:55–58.
30. Roth JA, Kim BG, Lin WL, Cho MI. Melatonin promotes osteoblast differentiation and bone formation. *J Biol Chem.* 1999;274:22041–22047.
31. Guardia J, Gómez-Moreno G, Ferrera MJ, Cutando A. Evaluation of effects of topic melatonin on implant surface at 5 and 8 weeks in Beagle dogs. *Clin Implant Dent Relat Res.* 2011;13:262–268.
32. Suzuki N, Hattori A. Melatonin suppresses osteoclastic and osteoblastic activities in the scales of goldfish. *J Pineal Res.* 2002;33:253–258.
33. Clafshenkel WP, Rutkowski JL, Palchesko RN, et al. A novel calcium aluminate-melatonin scaffold enhances bone regeneration within a calvarial defect. *J Pineal Res.* 2012;53:206–218.
34. Gomez-Florit M, Ramis JM, Monjo M. Anti-fibrotic and anti-inflammatory properties of melatonin on human gingival fibroblasts in vitro. *Biochem Pharmacol.* 2013;86:1784–1790.
35. Garcia RV, Kraehenmann MA, Bezerra FJ, Mendes CM, Rapp GE. Clinical analysis of the soft tissue integration of non-submerged (ITI) and submerged (3i) implants: a prospective-controlled 316 cohort study. *Clin Oral Implants Res.* 2008;19:991–996.
36. Srinath R, Acharya AB, Thakur SL. Salivary and gingival crevicular fluid melatonin in periodontal health and disease. *J Periodontol.* 2010;81:277–283.
37. Almugharbi OM, Marzouk KM, Hasanato RM, Shafik SS. Melatonin levels in periodontal health and disease. *J Periodont Res.* 2013;48:315–321.