

Simultaneous Application of Bone Morphogenetic Protein-2 and Platelet-Rich Fibrin for the Treatment of Bisphosphonate-Related Osteonecrosis of Jaw

Jin-Woo Kim, DDS, PhD
Sun-Jong Kim, DDS, PhD*
Myung-Rae Kim, DDS, PhD

INTRODUCTION

Bisphosphonate-related osteonecrosis of the jaws (BRONJ) is one of the most serious complications in patients receiving bisphosphonates. It is clinically characterized by an exposed necrotic jaw bone lasting longer than 8 weeks despite continuous treatment by the health care provider.^{1,2} Although there have been constant efforts to elucidate the pathogenic nature of the disease, many aspects, such as diagnosis, mechanism, treatment, and prognosis, remain unknown.^{3,4}

In general, for the treatment of BRONJ, position papers from the American Association of Oral and Maxillofacial Surgeons¹ and the American Society for Bone and Mineral Research² have recommended conservative approaches, including systemic antibiotic therapy, oral antimicrobial rinses, and minimal surgical debridement. These treatment modalities, however, have inconsistent results and, thus, are considered to be palliative management rather than definitive treatment.

A novel approach to treating BRONJ, the application of platelet-rich plasma, which is an autologous product containing a high concentration of various growth factors, was attempted and showed positive results.^{5,6} Another form of platelet concentrate, platelet-rich fibrin (PRF) was recently used to treat BRONJ.^{7,8} The rationale for the use of platelet concentrates for BRONJ is based on the role of growth factors in stimulating and accelerating regeneration of soft and hard tissues, which were thought to be disoriented by the pharmacologic effects of bisphosphonates.⁹ However, the absence of bone morphogenetic proteins (BMPs) within platelet concentrates resulted in controversy about whether the platelet concentrate is effective for an osseous disease such as BRONJ.^{10,11}

Regarding the delivery of BMP to the lesion of BRONJ, fibrin is a recognized support matrix for BMP, and the fibrin matrix associated with BMP has angiogenic, hemostatic, and osseous conductive properties.^{12,13} This suggests that BMP within a fibrin matrix such as PRF is expected to stimulate not only soft

tissue healing but also osseous regeneration, thus contributing to the successful treatment of BRONJ. In this report, the authors describe the simultaneous application of BMP-2 and PRF for a refractory case of BRONJ.

DESCRIPTION OF THE CASE

A 72-year-old woman was referred from a local clinic to our department for her poor wound healing after extraction of right mandibular teeth. (Figure 1a) The patient complained of prolonged right buccal swelling and pain 3 months after extraction. Clinical examination revealed an unhealed extraction socket and exposed bone with purulent discharge and moderate buccal swelling. The patient had been taking 70 mg of alendronate (Fosamax, Merck Co, Rahway, NJ) once a week for 4 years due to osteoporosis. The patient also had type 2 diabetes and a 2-year history of glucocorticoid therapy due to rheumatic arthritis, a possible comorbidity of osteonecrosis of the jaw.

The patient was initially treated with conservative approaches, including administration of third-generation cephalosporin intravenous antibiotics with pain medication, antibacterial mouth rinse, and daily irrigation with chlorhexidine 0.12%. After acute inflammatory signs subsided, surgical debridement and curettage of necrotic bone, followed by intensive topical antibiotic irrigation and primary closure, were performed under general anesthesia (Figure 1b). However, the patient's wound showed dehiscence with purulent discharge before suture removal and exposure of jaw bone extended gradually. Even after 2 surgeries for wound closure, bone exposure was still persistent (Figure 2a).

As a method for better tissue healing, the authors conducted surgery with adjunctive application of PRF from patient's autologous peripheral blood and commercially available recombinant human BMP-2. In accordance with the principles of the conservative approach for BRONJ, surgical debridement and minimal osteotomy were performed.

To prepare the PRF, 20 mL of peripheral blood was collected into two 10-mL tubes without anticoagulant and immediately centrifuged at 3000 rpm for 10 minutes. To prevent untoward initiation of coagulation cascades before centrifugation and to allow the natural transformation of fibrin matrix during centrifugation, these procedures were performed

Department of Oral and Maxillofacial Surgery, Ewha Womans University, Seoul, Korea.

* Corresponding author, e-mail: oralsurgeonsj@gmail.com

DOI: 10.1563/aaid-joi-D-14-00309

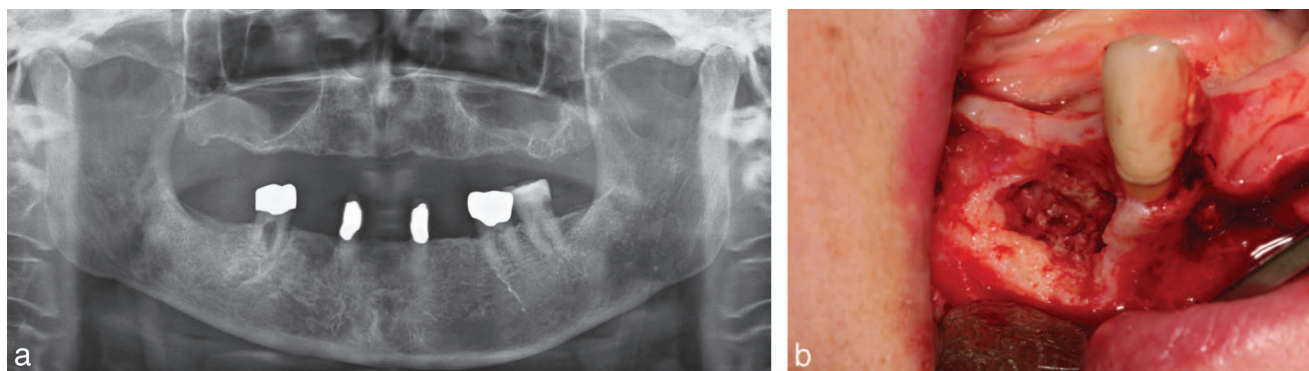


FIGURE 1. (a) Panoramic view taken at the first visit showing a nonhealing lesion at the right mandible. (b) Photograph taken at the first surgery presenting necrotic bone. Minimal surgical debridement was performed.

rapidly by a skilled assistant. After centrifugation, PRF was obtained from the tube; the red corpuscles at the bottom and the acellular plasma at the top were discarded. Simultaneously, a commercially available kit (Novosis, Daewoong Pharma, Seoul, Korea) containing 0.5 mL recombinant human BMP-2 (rhBMP-2) solution and hydroxyapatite for graft was prepared. Only rhBMP-2 solution was used for this surgery. As an rhBMP-2 carrier, collagen sponge (Ateroplug, Bioland, Seoul, Korea) was sectioned into thin round shapes and soaked in the solution. (Figure 3a)

A parachute-manner suture was started at the time of preparation of PRF and rhBMP-2. After the intensive antibacterial irrigation, collagen sponge sections with rhBMP-2 were inserted with contact to bone surface, followed by the PRF (Figure 3b and c). Then the mucoperiosteal flap was closed with primary closure. After the surgery, the patient's healing progress was observed through 12 days of admission, and complete removal of sutures was performed 11 days after the surgery. The patient showed excellent treatment response to surgery with simultaneous PRF and rhBMP-2 application. The surgical area had full mucosal coverage at the time of discharge. At the 11th week of follow-up, no evidence of inflammation or bony exposure was present. (Figure 4a and b)

DISCUSSION

The absence of a definitive treatment method for BRONJ mainly stems from the unclear pathophysiologic mechanism of the

disease. Given the increasing global dependence of bisphosphonates in the nonhormonal treatment of osteoporosis and various metabolic and pathologic bone diseases,¹⁴ the need to establish the pathogenesis and definitive treatment method for BRONJ is urgent.

Based on the main pharmacologic effects of bisphosphonates; inhibition of osteoclast-mediated bone resorption, pathogenesis of BRONJ is currently understood as a disease mainly associated with oversuppression of bone remodeling.^{3,15} Despite several positive results from using platelet concentrates for BRONJ,^{5,6} there have been contradictory opinions about the absence of BMP within platelet concentrates in relation to the osseous nature of BRONJ.^{10,11} Platelet concentrate has been known to accelerate epithelial wound healing, promote tissue vascularization, and enhance regeneration of soft tissues;^{10,13} however, direct curative effects for BRONJ seems to be hardly evident.

Among several forms of platelet concentrates, PRF presents unique biological characteristics compared with others. Because no chemicals are added in the coagulation process, the PRF is allowed to make more favorable physiologic fibrin matrix architectures and provide firm and slow-dissolving membrane.¹⁶ Moreover, the roles of leukocyte within PRF, including immune regulation, anti-infectious action,¹⁷ and production of vascular endothelial growth factor,¹⁸ are worthy of notice.

Within this report, the authors point out the possible synergetic effect of simultaneous application of PRF and rhBMP-2. Except for the high concentration of various growth factors themselves, PRF is a known supporting matrix for BMP

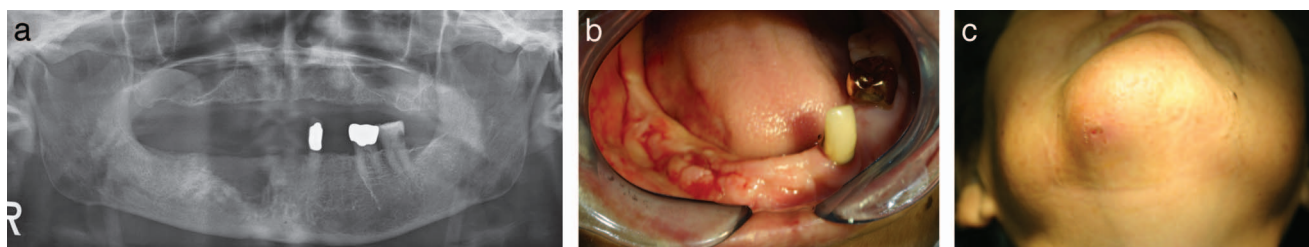


FIGURE 2. (a) Panoramic view taken 2 weeks after the second surgery. Note the extended bone lesion at the inferior border of the mandible. (b) Image taken right after suture removal after the second surgery. Note the purulent discharge and persistent inflammation. (c) Image taken after the second surgery showing extraoral fistula.

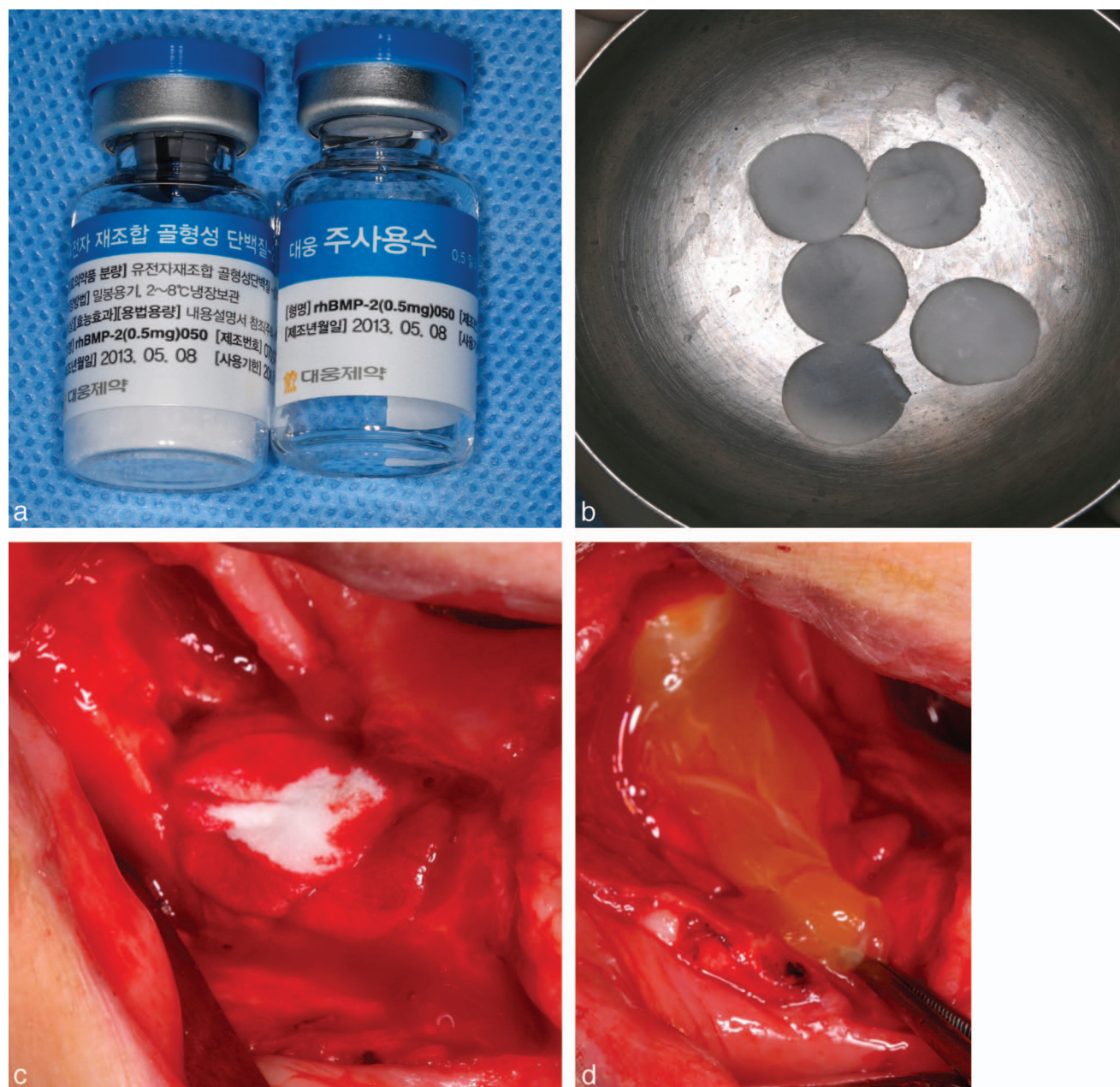


FIGURE 3. (a) Preparation of recombinant human bone morphogenetic protein-2 (rhBMP-2) and sectioned collagen sponge carrier. (b) Application of the rhBMP-2 smeared collagen carrier. (c) Application of platelet-rich fibrin above the rhBMP-2 carrier.

transplants.¹² BMP enmeshed in the PRF is progressively released and thus may affect the BRONJ lesion directly.

Among the transforming growth factor beta superfamily, BMP-2 and BMP-7 are known to have osteoinductive effects.¹⁹ RhBMP-2 has been widely used for the treatment of bone defects, delayed or nonunion, and for bone grafts, especially in the field of orthopedics.²⁰ The authors used products containing *Escherichia coli*-derived rhBMP-2 and hydroxyapatite in this report. In the management of BRONJ, bone graft was expected to have negative effects due to the relative reduction of tissue perfusion and possible foreign body reaction, thus

discarding the hydroxyapatite. Bone grafts for further implant rehabilitation might be implemented after sufficient follow-up.

A confounding factor needs to be taken into consideration when selecting a BRONJ treatment method: the high cost of purchasing rhBMP. It is reasonable to choose the treatment method according to the severity of the disease, but the price barrier can lead to a biased selection and skew the rhBMP effectiveness. Properly designed clinical trials to compare the treatment effects of PRP and rhBMP are needed.

In this case report, we described a novel method; adjunctive simultaneous application of both PRF and rhBMP-2. This technique was found to be effective for the management of

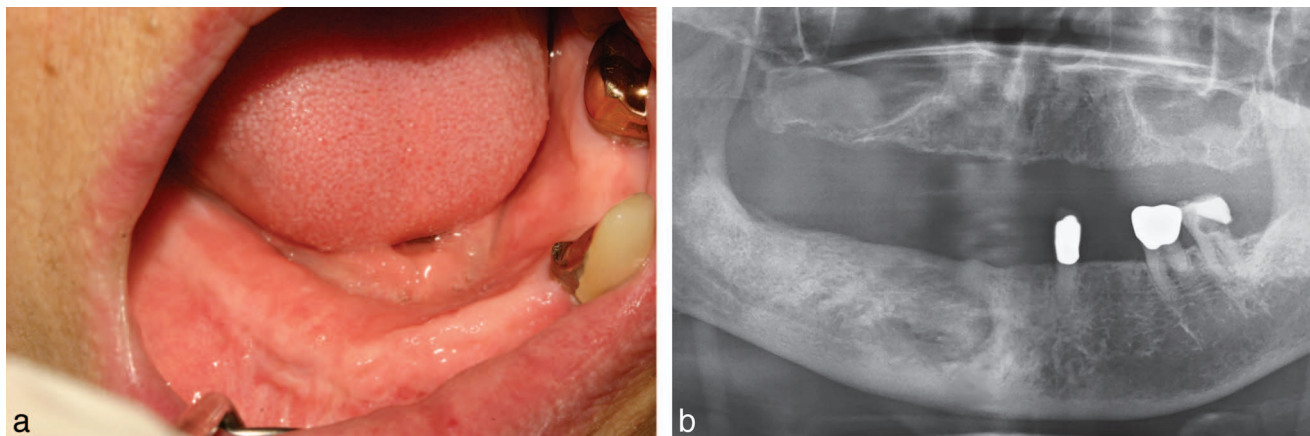


FIGURE 4. (a) Photograph taken 6 weeks after simultaneous application of platelet-rich fibrin and recombinant human bone morphogenetic protein-2 showing the fully resolved lesion. (b) Panoramic view taken 11 weeks after surgery.

BRONJ, especially for a refractory case. Given that currently recommended treatment modalities are mostly limited to conservative, although not conclusive, methods, our promising results indicate that this may effectively contribute to successful treatment for BRONJ. Further prospective trials are needed to confirm the effectiveness for BRONJ treatment.

ACKNOWLEDGMENTS

This work was supported by a Ewha Womans University Research Grant of 2014 (1-2014-0643-001-1), Seoul, Korea. The authors declare no potential conflicts of interest with respect to the authorship and/or publication of this article.

REFERENCES

1. American Association of Oral and Maxillofacial Surgeons position paper on medication-related osteonecrosis of the jaw—2014 update. *J Oral Maxillofac Surg.* 2014;72:1938–1956.
2. Khosla S, Burr D, Cauley J, et al. Bisphosphonate-associated osteonecrosis of the jaw: report of a task force of the American Society for Bone and Mineral Research. *J Bone Miner Res.* 2007;22:1479–1491.
3. Subramanian G, Cohen HV, Quek SY. A model for the pathogenesis of bisphosphonate-associated osteonecrosis of the jaw and teriparatide's potential role in its resolution. *Oral Surg Oral Med Oral Pathol Oral Radiol Endod.* 2011;112:744–753.
4. Allen MR, Burr DB. The pathogenesis of bisphosphonate-related osteonecrosis of the jaw: so many hypotheses, so few data. *J Oral Maxillofac Surg.* 2009;67:61–70.
5. Curi MM, Cossolin GS, Koga DH, et al. Bisphosphonate-related osteonecrosis of the jaws—an initial case series report of treatment combining partial bone resection and autologous platelet-rich plasma. *J Oral Maxillofac Surg.* 2011;69:2465–2472.
6. Bocanegra-Perez S, Vicente-Barrero M, Knezevic M, et al. Use of platelet-rich plasma in the treatment of bisphosphonate-related osteonecrosis of the jaw. *Int J Oral Maxillofac Surg.* 2012;41:1410–1415.

7. Kim JW, Kim SJ, Kim MR. Leucocyte-rich and platelet-rich fibrin for the treatment of bisphosphonate-related osteonecrosis of the jaw: a prospective feasibility study. *Br J Oral Maxillofac Surg.* 2014;52:854–859.

8. Soydan SS, Uckan S. Management of bisphosphonate-related osteonecrosis of the jaw with a platelet-rich fibrin membrane: technical report. *J Oral Maxillofac Surg.* 2014;72:322–326.

9. Mozzati M, Gallesio G, Arata V, Pol R, Scoletta M. Platelet-rich therapies in the treatment of intravenous bisphosphonate-related osteonecrosis of the jaw: a report of 32 cases. *Oral Oncol.* 2012;48:469–474.

10. Marx RE. Platelet-rich plasma: evidence to support its use. *J Oral Maxillofac Surg.* 2004;62:489–496.

11. Soffer E, Ouhayoun JP, Anagnostou F. Fibrin sealants and platelet preparations in bone and periodontal healing. *Oral Surg Oral Med Oral Pathol Oral Radiol Endod.* 2003;95:521–528.

12. Kawamura M, Urist MR. Human fibrin is a physiologic delivery system for bone morphogenetic protein. *Clin Orthop Relat Res.* 1988;(235):302–310.

13. Choukroun J, Diss A, Simonpieri A, et al. Platelet-rich fibrin (PRF): a second-generation platelet concentrate. Part IV: clinical effects on tissue healing. *Oral Surg Oral Med Oral Pathol Oral Radiol Endod.* 2006;101:e56–e60.

14. Lo JC, O'Ryan FS, Gordon NP, et al. Prevalence of osteonecrosis of the jaw in patients with oral bisphosphonate exposure. *J Oral Maxillofac Surg.* 2010;68:243–253.

15. Reid IR, Cornish J. Epidemiology and pathogenesis of osteonecrosis of the jaw. *Nat Rev Rheumatol.* 2012;8:90–96.

16. Dohan Ehrenfest DM, Rasmusson L, Albrektsson T. Classification of platelet concentrates: from pure platelet-rich plasma (P-PRP) to leucocyte- and platelet-rich fibrin (L-PRF). *Trends Biotechnol.* 2009;27:158–167.

17. Dohan DM, Choukroun J, Diss A, et al. Platelet-rich fibrin (PRF): a second-generation platelet concentrate. Part III: leucocyte activation: a new feature for platelet concentrates? *Oral Surg Oral Med Oral Pathol Oral Radiol Endod.* 2006;101:e51–e55.

18. Werther K, Christensen IJ, Nielsen HJ. Determination of vascular endothelial growth factor (VEGF) in circulating blood: significance of VEGF in various leucocytes and platelets. *Scand J Clin Lab Invest.* 2002;62:343–50.

19. Chen D, Zhao M, Mundy GR. Bone morphogenetic proteins. *Growth Factors.* 2004;22:233–241.

20. Khan SN, Lane JM. The use of recombinant human bone morphogenetic protein-2 (rhBMP-2) in orthopaedic applications. *Expert Opin Biol Ther.* 2004;4:741–748.