

Immediate Loading of Maxillary One-Piece Screw Implants Utilizing Intraoral Welding: A Case Report

Franco Rossi, DDS¹
 Marco E. Pasqualini, DDS^{2*}
 Luca Dal Carlo, DDS³
 Mike Shulman, DDS⁴
 Michele Nardone, MD⁵
 Sheldon Winkler, DDS⁶

INTRODUCTION

International conferences have defined procedures and techniques for immediate loading, based on scientific and clinical evidence and considering various edentulous anatomic forms, the type of bone, and the length and structure of the implants used.¹⁻³ Clinicians from the study group of NuovoGISI have long and successful experiences with immediate loading of maxillary implants connected together by intraoral welding.⁴⁻⁷ Intraoral welding can join and stabilize implants by the use of a titanium wire or bar that is permanently connected to the implants. An electric current is used to fuse the titanium to the abutments in milliseconds.

The welding procedure is performed intraorally before the immediate loading. Stabilization and fixation of the implants allows immediate loading and prosthesis insertion (provisional or definitive) to occur the same day as the surgery. By inserting a prosthesis with adequate retention and stability the same day as the surgery, patient complaints and discomfort can be avoided or substantially reduced. The instantaneous stability that results from the splinting can reduce the risk of failure during the healing period. Intraoral welding can also eliminate errors caused by unsatisfactory impression making.

MATERIALS AND METHODS

The intraoral welding machine was developed by Pierluigi Mondani⁸ of Genoa, Italy, to permanently connect 1-piece implants or abutments (sometimes called welding or dedicated welding abutments) to a titanium wire or bar by means of an electric current (Figure 1). The current is applied for a short period of time (4 ms) so the heat generated does not cause any pathology or patient discomfort.

One-piece implants are placed without flaps (Figure 2). The titanium wire or bar is bent and aligned passively to the contour of the labial and lingual surfaces of the implants

(Figure 3) before applying the electric current to permanently connect the bar to the implants.

This procedure can be modified and used in 2 steps with approximately 4 months between surgeries for atrophic bony ridges. Submerged implants are inserted in the maxillary tuberosity regions during the first surgery. One-piece implants are placed anteriorly during the second surgery and all of the implants welded immediately to a titanium bar.⁹

SURGICAL PROTOCOL

The surgical protocol of this technique has 4 objectives:

Number of implants—As many implants as possible should be placed, corresponding to the number of missing teeth to be replaced.

Primary stabilization—All implants must reach and penetrate the deep cortical bone to achieve bicorticalism, which provides primary stability.^{10,11}

Immediate splinting—Strong and stable splinting of the implants can be obtained using a 1.2-mm wide titanium supporting bar, set internally on the mucosa without any compression and welded to each implant by intraoral solder.^{12,13} The supporting bar must be placed so that the emerging implant abutments rise up free of any interference in the oral cavity.

Temporary prosthesis—During the surgical session, a temporary resin prosthesis is inserted. Occlusal plane height must be correct. A lingualized (lingual contact) scheme of occlusion is recommended. The upper anterior teeth are best arranged without any vertical overlap. The amount of horizontal overlap is determined by the jaw relationship. A vertical overlap for appearance can be used, provided that an adequate horizontal overlap is included to guard against interference within the functional range.¹⁴

The ideal screws for the maxillary temporary prosthesis are those with wide threads, as they can provide greater stability when inserted into bone that is not particularly compact.¹⁵

CLINICAL REPORT

A healthy 67-year-old Caucasian woman presented for treatment at the office of 1 of the co-authors (CDL) with an unstable maxillary complete prosthesis supported by 6 anterior residual

¹ Private practice, Varese, Italy.

² Private practice, Milan, Italy.

³ Private practice, Venice, Italy.

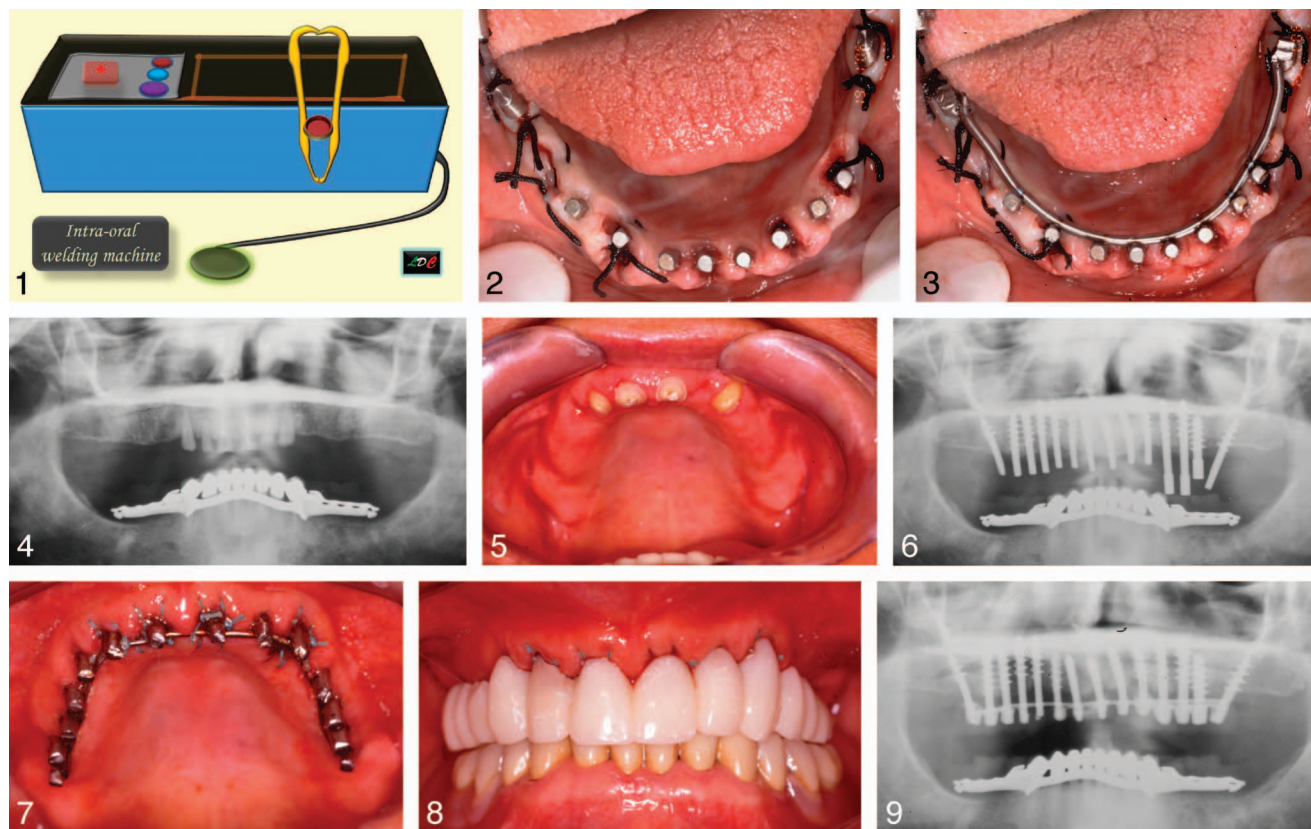
⁴ Private practice, Clifton, NJ.

⁵ Ministry of Public Health, Rome, Italy.

⁶ Midwestern University School of Dental Medicine, Glendale, Ariz.

* Corresponding author, e-mail: dott.marcopasqualini@tiscali.it

DOI: 10.1563/aaid-joi-D-14-00332



FIGURES 1–9. **FIGURE 1.** Schematic drawing of Mondani intraoral solder unit. **FIGURE 2.** Two blade and 8 screw implants inserted in the lower jaw of a patient. **FIGURE 3.** The 10 implants have been welded intraorally to a titanium bar by an electric current. **FIGURE 4.** Panoramic radiograph of 67-year-old Caucasian female patient. **FIGURE 5.** Intraoral photograph of patient before treatment. **FIGURE 6.** A panoramic radiograph confirms the deep bicortical placement of the implants. **FIGURE 7.** Immediate splinting is performed with a titanium supporting bar of 1.5-mm diameter set on the mucosa without any compression and welded to each implant with intraoral solder. The supporting bar must be placed so that the emerging abutments of the implants are free in the oral cavity. **FIGURE 8.** Intraoral view of provisional resin prosthesis cemented to the implants (immediate load). **FIGURE 9.** Panoramic radiograph taken 90 days after insertion of the provisional prosthesis.

roots (Figures 4 and 5). The maxillary bone was checked with a thickness gauge, examined radiographically, and found to be appropriate for dental implants. After extraction of the retained roots, 14 implants were inserted in 1 session. A panoramic radiograph (Figure 6) confirmed the deep bicortical placement of the implants.

Immediate stabilization of the implants was achieved by welding (Aptiva Intraoral Welding Unit NS1100, Vicenza, Italy) each implant to a 1.5-mm supporting titanium bar (Bio-Micron, Milano, Italy), which previously had been bent to fit passively on the palatal mucosa (Figure 7). A provisional resin prosthesis was inserted, which provided an acceptable vertical dimension and a balanced occlusion (Figure 8).

After 90 days a panoramic radiograph suggested complete integration (Figure 9) and a healthy mucosa was observed (Figure 10). The definitive full-arch gold-ceramic maxillary prosthesis was inserted (Figure 11), which greatly pleased the patient and her family.

Oral hygiene procedures were demonstrated to the patient and reviewed at all future appointments (Figure 12).

The case was later completed with a lower full arch prosthesis on implants and natural teeth. The 13-year follow-up radiograph shows satisfactory preservation of bone surround-

ing all of the implants and a healthy appearance of the oral mucosa (Figures 13 and 14).

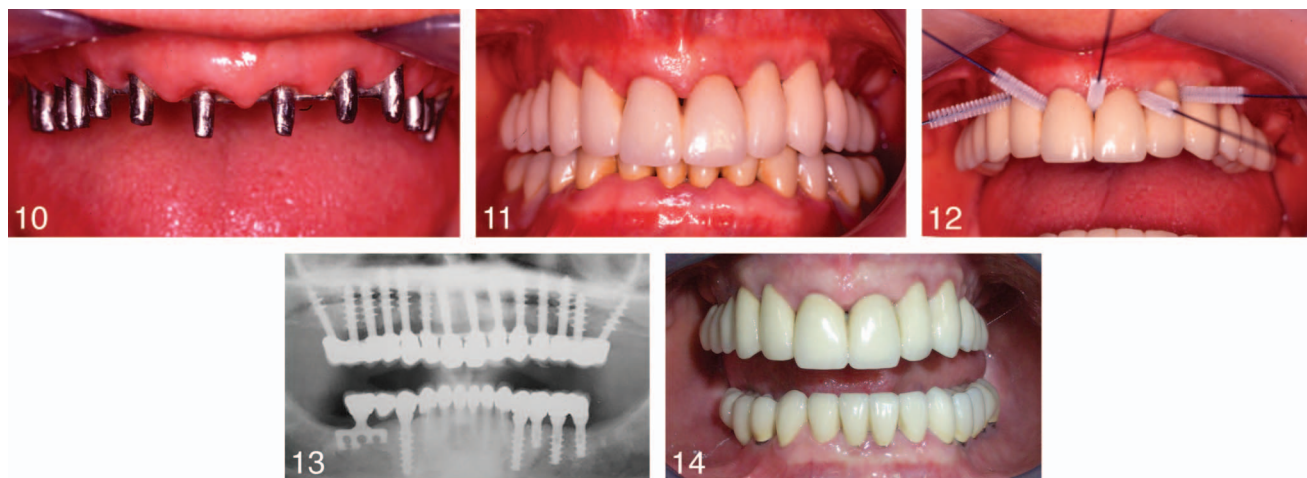DISCUSSION

When possible, surgical trauma can be reduced by the insertion of implants without flaps. This technique, proposed by Tramonte,¹⁶ can be performed when the bony crest is wide and an adequate amount of attached gingiva is present. The technique allows for uneventful healing, a reduction of postsurgical inflammation, and only moderate inconvenience for the patient, who can eat efficiently the same day.

The soft tissues underlying the welded bar experience minimal inflammation, similar to that which can be observed with 2-stage implants.^{17,18} The successful use of intraoral welding for maxillary immediate restorations has been reported in the dental literature.^{19–21}

CONCLUSION

Long-term success of restorations fabricated by immediate loading of maxillary 1-piece implants utilizing intraoral welding has been reported in the dental literature. The technique can



FIGURES 10–14. **FIGURE 10.** Correct positioning of the supporting bar and abutments before cementation of the definitive prosthesis. **FIGURE 11.** Full-arch, gold-ceramic maxillary prosthesis after insertion. **FIGURE 12.** Oral hygiene procedures are demonstrated to the patient. **FIGURE 13.** Thirteen-year follow-up radiograph shows preservation of bone surrounding all of the implants. **FIGURE 14.** Thirteen-year follow-up intraoral photograph shows healthy appearance of the oral mucosa.

also be used with implant abutments and submerged implants. Among the advantages of intraoral welding are immediate stabilization of the implants, immediate provisionalization, reduced risk of failure during the healing period, elimination of errors caused by unsatisfactory impression-making, and a potential reduction in patient complaints and discomfort.

REFERENCES

- Misch CE, Hahn J, Judy KW, et al; Immediate Function Consensus Conference. Workshop guidelines on immediate loading in implant dentistry. *J Oral Implantol.* 2004;30:283–288.
- Aparicio C, Rangert B, Sennerby L. Immediate/early loading of dental implants: a report from the Sociedad Española de Implantes World Congress consensus meeting in Barcelona, Spain, 2002. *Clin Implant Dent Relat Res.* 2003;57–60.
- Accademia Italiana di Stomatologia Implantoprotetica. Consensus on the loading in implant dentistry. *Dental Cadmos.* 2004;2:81–83.
- Rossi F, Pasqualini ME, Mangini F, et al. Immediate loading of one-step screw implants in the upper jaw. *Dent Cadmos.* 2005;465–469.
- Rossi F, Pasqualini ME, Carinci F, et al. One-piece immediate-load post-extraction implants in labial bone-deficient upper jaws. *Annals Oral Maxillofac Surg.* 2013;1:14.
- Dal Carlo L. Welding together submerged implants: over 12 years of clinical experience. *Rivista Italiana di Stomatologia.* 2008;2:34–42.
- Dal Carlo L. Integration of different implant techniques in superior posterior atrophy treatment. *Mag Stomat (special issue), Warszawa.* 2006:46–52.
- Mondani PL, Mondani PM. The Pierliugi Mondani intraoral electric solder. Principles of development and explanation of the solder using syncrystallization. *Riv Odontostomatol Implantoprotesi.* 1982;4:28–32.
- L. Dal Carlo Surgical and prosthetic protocol to treat serious periodontal cases directly passing to immediately loaded fixed prosthesis on welded implants. Paper presented at: Accademia Italiana di Stomatologia Implantoprotetica 7th International Congress; March 23–24, 2007; Bologna, Italy.
- Strecha J, Jurkovic R, Siebert T, Prachar P, Bartakova S. Fixed bicortical screw and blade implants as a non-standard solution to an edentulous (toothless) mandible. *Int J Oral Sci.* 2010;2:105–110.
- Morgano AT. Functional load in oblique bicortical implants: parasinusal implants and palatine implants. *J Oral Implantol.* 2013;39:467–474.
- Dal Carlo L. The numerous applications of the Mondani intra-oral solder. 17 years of clinical experience. *Revista Espanola Odontostomatologica de Implantos.* 2006;14:24–34.
- Pasqualini, ME, Mangini F, Colombo D, et al. Stabilization of immediately loaded emerging implants: endoral soldering. *Dental Cadmos.* 2001;9:67–71.
- Winkler S, ed. *Essentials of Complete Denture Prosthodontics.* 3rd ed. Delhi, India: AITBS Publishers; 2015.
- Tramonte SM. Self-threading endosseous screw. *Actual Dent.* 1989; 5:44–49.
- Tramonte, S. A further report on intraosseous implants with improved drive screws. *J Oral Implant Transplant Surg.* 1965;11:35–37.
- Fanali S, Perrotti V, Riccardi L, et al. Inflammatory infiltrate, microvessel density, vascular endothelial growth factor, nitric oxide synthase, and proliferative activity in soft tissues below intraoral welded titanium bars. *J Periodontol.* 2010;81:748–757.
- Hruska AR. Welding implants in the mouth. *J Oral Implantol.* 1989; 15:198–203.
- Avanzo P, Fabrocini LA, Ciavarella D, Awanzo A, Lo Muzio L, De Maio RA. Use of intraoral welding to stabilize dental implants in augmented sites for immediate provisionalization: a case report. *J Oral Implantol.* 2012;38:33–41.
- Degidi M, Nardi D, Piattelli A. A six-year follow-up of full-arch immediate restorations fabricated with an intraoral welding technique. *Implant Dent.* 2013;22:224–231.
- Hruska AR, Borelli P. Intra-oral welding of implants for an immediate load with overdentures. *J Oral Implantol.* 1993;19:34–38.