

# Extraction Socket Management Utilizing Platelet Rich Fibrin: A Proof-of-Principle Study of the "Accelerated-Early Implant Placement" Concept

Georgios A. Kotsakis, DDS, MS<sup>1\*</sup>  
 Foteini Boufidou, MD<sup>2</sup>  
 James E. Hinrichs, DDS, MS<sup>1</sup>  
 Hari S. Prasad, MS<sup>3</sup>  
 Michael Rohrer, DDS, MS<sup>3</sup>  
 Kostantinos I. Tosios, DDS, PhD<sup>4</sup>

Dental implants are widely accepted as the golden standard for the rehabilitation of an edentulous site following the extraction of a tooth. The ideal time for implant placement is dependent on the time required for partial or complete tissue healing and the adequacy of socket dimensions. The use of autologous growth factors is a promising new concept that aids clinicians in minimizing treatment time and increasing patient satisfaction. The purpose of this paper is to introduce a protocol for "accelerated-early" implant placement. In this protocol, platelet rich fibrin is employed to accelerate soft and hard tissue healing and to provide a better-healed recipient site for accelerated, early implant placement. Histological analysis revealed that at 6 weeks postextraction, the application of our approach resulted in delicate newly formed bone showing intense osteoblastic activity surrounded by connective tissue as well as areas of mineralized tissue. The present study is a proof-of-principle study of the acceleration of the physiologic postextraction healing sequelae with the use of autologous growth factors. The accelerated-early implant placement concept is a bioengineered protocol that may aid clinicians to achieve increased primary stability, by placing implants in ridges in an advanced stage of bone healing, while offering patients the benefits associated with early implant placement. Controlled studies are warranted to verify the reproducibility of this treatment concept and identify specific indications where the use of the presented technique can lead to significant clinical results.

**Key Words:** PRF, platelet rich fibrin, extraction, socket preservation, early implant placement

## INTRODUCTION

Handling of the postextraction socket has become an integral step of contemporary implant-drive dental practice.<sup>1-3</sup> There is an ongoing debate among clinicians to determine the ideal time for implant placement after a tooth extraction. In cases when immediate implant placement is not indicated, 2 treatment modalities are available: early (previously "immediate-delayed"), or late (or "delayed") implant placement.<sup>4,5</sup> Early implants are inserted after 4 weeks, up to approximately 2 months postextraction to allow for an adequate soft tissue healing period.<sup>6</sup> In early placement there is enough time for the resolution of any localized infection and for soft tissue healing of the site to facilitate adequate flap adaptation and management of the

surgical site.<sup>7,8</sup> On the other hand, there is not enough time for new bone formation in the alveolar socket, thus the bone density is suboptimal.<sup>5,9</sup>

Late implant placement is defined as implant placement in a socket where bone fill has occurred.<sup>9</sup> Typically, a healing period of at least 16 weeks is required. The timeframe for late implant placement is adequate for bone healing to occur in the postextraction socket, but during this protracted period of healing, the socket may have undergone significant 3-dimensional resorption.<sup>10,11</sup> If ridge preservation is not performed, additional grafting may be needed during implant placement to cover the resulting buccal defect.<sup>12</sup> Although it is a feasible option, simultaneous implant placement and grafting seems to lead to complete defect correction in 2 out of 3 cases (61%), according to Le and Borzabadi-Farahani.<sup>12</sup> In order to limit the inevitable alveolar ridge resorption, many different bone substitutes have been proposed for ridge preservation, but their placement functions as a double-edged sword; it is effective in limiting ridge resorption, but it delays healing in the socket.<sup>11,13</sup> Due to increasing patient demands for timely and esthetic treatment, there is a need for new therapeutic protocols that accelerate the healing of

<sup>1</sup> Department of Periodontics, University of Washington, Seattle, Wash.

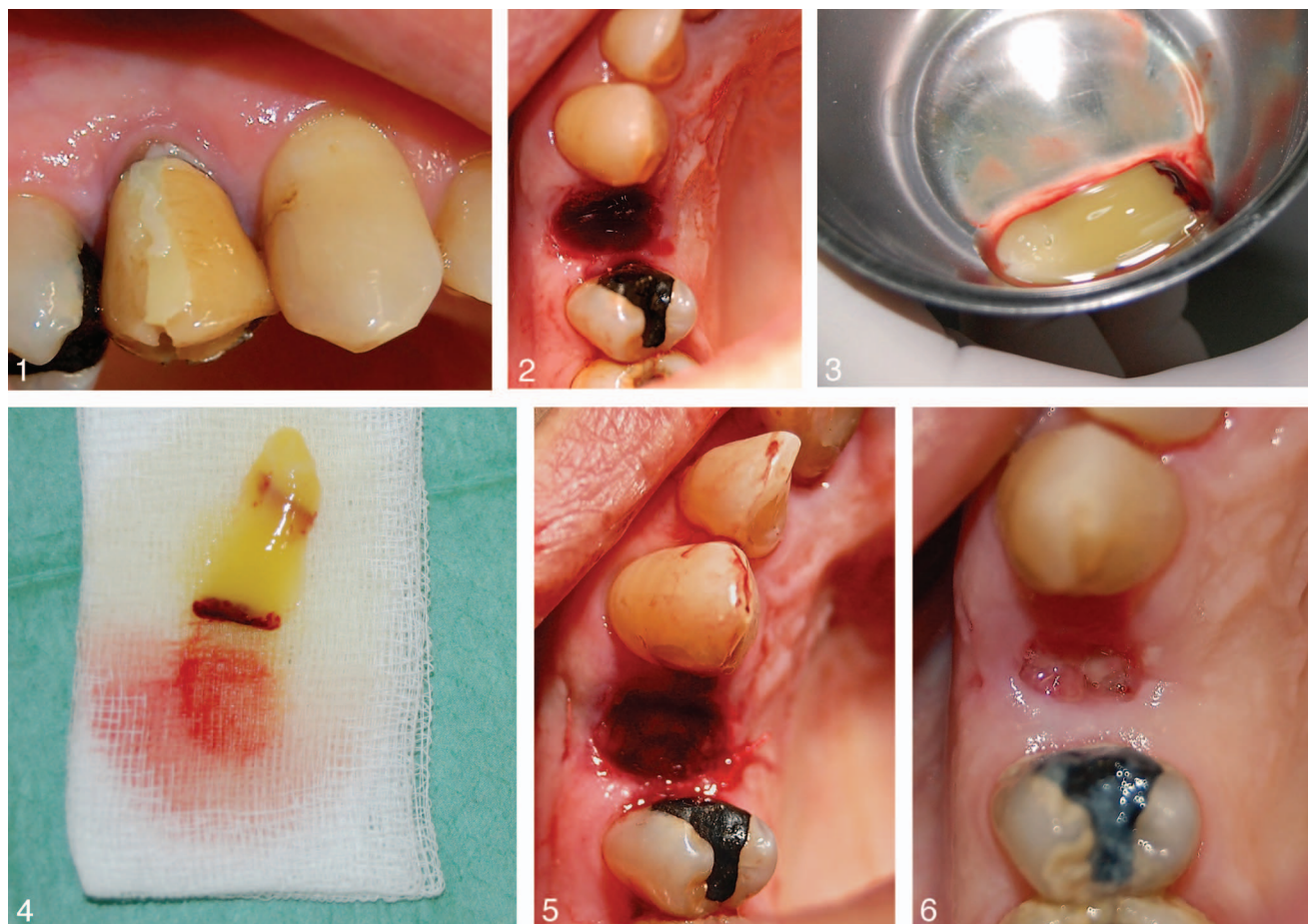<sup>2</sup> University of Athens Medical School, Athens, Greece.

<sup>3</sup> Hard Tissue Research Laboratory, University of Minnesota, Minneapolis, Minn.

<sup>4</sup> Department of Oral Pathology, Dental School, University of Athens, Athens, Greece.

\* Corresponding author, e-mail: kotsakis@uw.edu

DOI: 10.1563/aid-joi-D-15-00001



**FIGURES 1–6.** **FIGURE 1.** Baseline clinical view of the hopeless maxillary first premolar. **FIGURE 2.** Intraoperative view following tooth extraction. Note the maintenance of gingival contours owing to the atraumatic extraction technique. **FIGURE 3.** Platelet rich fibrin (PRF) clot immediately following extraction from the centrifuged blood sample vial. **FIGURE 4.** Fibrin membrane formed following manipulation of the PRF clot. **FIGURE 5.** Clinical view at the end of the surgical procedure. **FIGURE 6.** Clinical view at 2 weeks postoperatively showing complete epithelization.

postextraction sockets while minimizing the duration of the treatment.

Autologous platelet preparations have shown promising results in bone regeneration in the postextraction socket.<sup>14</sup> Platelet rich fibrin (PRF) is a platelet concentrate that has recently attracted the interest of clinical researchers due to its simplicity of preparation as well as promising results from its clinical applications.<sup>15–18</sup> The purpose of this paper is to introduce a protocol for “accelerated-early” implant placement. In this protocol, PRF is employed to accelerate soft and hard tissue healing, thus providing a better-healed ridge for accelerated, early implant placement.

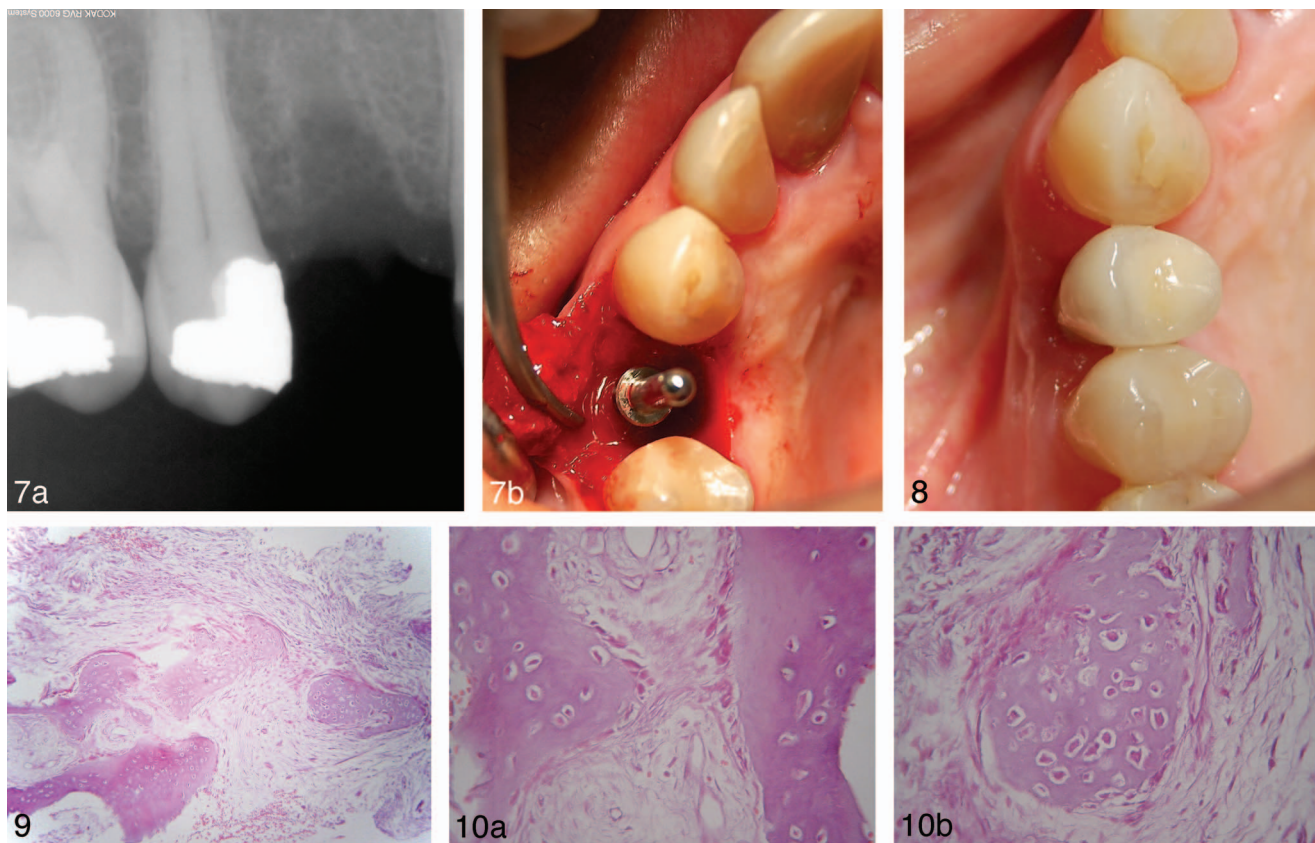
#### CASE EXAMPLE

A 48-year-old nonsmoking female patient presented for extraction of a maxillary upper-right first premolar. The involved tooth had been endodontically treated 15 years ago and exhibited apical root resorption. Clinical assessment revealed class I mobility with no signs of active periodontitis

(Figure 1). Immediate implant placement was not preferred due to the periapical pathology of the involved tooth, so extraction and ridge preservation was proposed to the patient. Based on the patient’s desire to reduce treatment time, the final treatment plan involved tooth extraction, and placement of a PRF plug and membrane in the socket for accelerated-early implant placement. The rationale was to allow for resolution of the periapical lesion and soft tissue maturation, while accelerating bone healing in the socket. The patient was thoroughly informed on the surgical procedure and the preparation of the PRF and signed an informed consent.

#### Technique

On the day of the extraction, 16 mL of peripheral venous blood where collected and placed in 2 10 mL sterile vials (8 mL each). The tubes were centrifuged at 2700 rpm for 12 minutes and then progressively decelerated.<sup>19</sup> At this time the PRF occupied the space between the supernatant and the red blood cells



**FIGURES 7–10.** **FIGURE 7.** (a) Radiograph showing radiopaque tissue forming in the site that may be indicative of incipient trabecularization. The coronal aspect of the bundle bone is still noticeable as expected at 6 weeks postextraction. (b) Implant placement was performed with good primary stability. **FIGURE 8.** Clinical view at the 30-month follow-up appointment. Note the adequate preservation of buccal tissue contours. **FIGURE 9.** Photomicrograph showing trabeculae of delicate newly formed bone with numerous lacunae occupied by osteocytes, in a fibrous vascular connective tissue matrix (hematoxylin and eosin stain, original magnification  $\times 100$ ). **FIGURE 10.** (a) and (b) High power photomicrographs showing numerous osteocytes and focal lining by osteoblasts (hematoxylin and eosin stain, original magnification  $\times 400$ ).

fraction.<sup>19</sup> The tubes were left undisturbed until the fibrin reached a viscous state.

During this time, local anesthesia was administered and the tooth was extracted in the least traumatic way with the aid of periostomes and a luxator, as previously described<sup>20</sup> (Figure 2). After debridement of the alveolar socket the 2 fibrin clots were extracted from the vials in the form of 2 “gelly” cylinders of approximately 5 cm<sup>3</sup> each (Figure 3). One of the cylinders was placed in the socket. The second cylinder was compressed between 2 sterile gauzes in order to form a membrane (Figure 4), which was used for the coverage of the socket and was stabilized with a horizontal mattress suture (Figure 5). Postoperatively, analgesics and 0.12% chlorhexidine solution were prescribed. Two weeks postoperative evaluation revealed good tissue healing with signs of epithelization over the socket (Figure 6). The patient reported an uneventful healing period.

#### **Implant surgery**

At 6 weeks postextraction local anesthesia was administered, and after raising a full-thickness mucoperiosteal flap, a 2.5  $\times$  6 mm bone core was trephined out and placed in 10% buffered

formalin for histological evaluation. Subsequently, the implant bed was prepared according to the manufacturer’s instructions and a 4.3 mm  $\times$  11 mm implant was placed in the healed site (Figure 7a and b). The implant achieved an initial insertion torque of 35N.cm exhibiting good primary stability. A cover screw was placed and the patient was scheduled for second stage surgery and subsequent delivery of a porcelain-fused-to-metal cement-retained restoration at 3 months postsurgery. The implant remained successfully in function at the 48-month follow-up with no signs of mobility or inflammation, and no subjective symptoms such as pain or altered sensation<sup>21</sup> (Figure 8).

#### **Histological analysis**

Following decalcification in an EDTA-based solution (Biodeck, Milano, Italy) and paraffin-embedding, 5 $\mu$ m-thick tissue sections were stained with hematoxylin and eosin. Microscopic examination revealed bone trabeculae embedded in fibrous and vascular connective tissue matrix (Figure 9). The trabeculae were composed of delicate newly formed bone showing numerous bone lacunae occupied by osteocytes and focally lined by osteoblasts (Figure 10a and b). Overall, bone

TABLE 1

Technique-related advantages of platelet rich fibrin (PRF) in comparison to platelet rich plasma (PRP)	
PRP	PRF
Technically demanding procedure. Requires specially trained staff. Usually requires a series of 2 centrifugations Blood is mixed with anticoagulant (usually bovine thrombin) and chemical substances such as CaCl <sub>2</sub>	Simplified procedure Single centrifugation No chemical substance is involved in the handling of the blood.

trabeculae accounted for approximately 30% of the total tissue area. The connective tissue showed mild and diffuse infiltration by inflammatory cells, mostly lymphocytes and plasma cells.

### DISCUSSION

In the present study, we combined the concept of early implant placement with PRF and found partial bone healing that is consistent with later phases of socket healing.<sup>22</sup> Thus, re-entry could be performed timely enough before a large percentage of the alveolar ridge resorption has occurred.<sup>6</sup> This accelerated waiting period increases patient satisfaction.<sup>23</sup> The downside of conventional early placement is that only soft tissue healing has occurred in the socket and adequate primary implant stability in the immature site may be jeopardized.<sup>9,24,25</sup> However, histologic evaluation of the bone specimen retrieved at 6 weeks postextraction with the use of PRF revealed bone formation, with bone trabeculae occupying approximately 30% of the total tissue area.

Comparing our results to the classic work of Evian et al, the stage of healing 6 weeks following the placement of PRF in the socket was consistent with at least 8 weeks normal healing in an ungrafted socket.<sup>22</sup> The work of Amler (1960, 1969) in human extraction sockets has also shown that a period where dense, cellular connective tissue elements occupy the socket precedes the bone maturation period that spans from 8 to 12 weeks postextraction.<sup>26,27</sup> Nonetheless in our 6-week specimen, multiple sizeable bone trabeculae were already formed within the connective tissue bed.

Autologous growth factors were introduced in dentistry with platelet rich plasma (PRP).<sup>28</sup> The main drawback of PRP is the need for heterologous factors, such as bovine thrombin, for its preparation. Bovine thrombin may elicit coagulopathies associated with antibodies against specific clotting factors.<sup>29,30</sup> Moreover, evidence on its efficacy remains equivocal in terms of its efficacy in bone augmentation.<sup>31</sup> The use of PRF was introduced in 2000 to overcome the complexity and possible health risks associated with PRP, and to improve wound healing and bone regeneration (Table 1).<sup>32</sup> In PRF, platelets are entrapped in the fibrin matrix of PRF and growth factors such as PDGF, TGF- $\beta$ , VEGF, and IGF are gradually released for a period of at least 7 days from the fibrin matrix.<sup>33,34</sup> The temporal availability of growth factors prolongs their chemotactic properties and contributes to cell growth and proliferation.<sup>34</sup> In preclinical studies, PRF has been shown to lead to similar results as autogenous bone in contained defects in

rabbits.<sup>35</sup> These attributes make PRF an excellent matrix for socket regeneration.

In our case, socket occlusion with a PRF membrane was utilized in a flapless manner for ridge preservation in lieu of primary closure. According to Kotsakis et al, flap advancement for primary closure in ridge preservation interventions may lead to repositioning of the mucogingival junction, displacement of the keratinized mucosa, and additional ridge resorption due to flap elevation.<sup>20</sup> PRF was used as a source of growth factors that enabled the acceleration of the initial steps of healing, thus shortening the rehabilitation time required of an edentulous site. In addition, the fibrin plays the role of a biomaterial with a positive effect on early vascularization where fibrin, fibronectin, and thrombospondin act as a provisory extracellular matrix, which may enhance bone formation in the socket.<sup>36</sup> The concept of acceleration of postextraction sockets has been previously validated in a controlled trial that compared healing in premolar sockets grafted with PRF to healing in ungrafted sockets.<sup>37</sup> At 8 weeks postextraction, microcomputed tomographic analysis showed significantly improved microarchitecture and significantly higher bone quality in the PRF group in agreement with our histological data.<sup>37</sup> An interesting finding was advancement of a flap during extraction neutralized any added benefit from the use of PRF.<sup>37</sup> Simon et al also verified the enhanced bone healing after placement of platelet-rich fibrin matrix in extraction sockets.<sup>38</sup> Even though it was undiscussed in the present study, they also showed a significant advantage in the preservation of postextraction alveolar ridge dimensions with the use of PRF.<sup>38</sup> Future advances in autologous preparations, such as the introduction of APRF and EPRF, have a promising potential to further enhance the efficacy and broaden the spectrum of applications of autologous growth factors in implant dentistry.

### CONCLUSION

Based on existing evidence from the literature and our findings, it seems that the use of PRF in combination with a flapless extraction approach may accelerate the physiologic postextraction healing sequelae in sockets re-entered as early as 6 to 8 weeks postextraction. The "accelerated-early" implant placement concept is a bioengineered protocol that may aid clinicians to achieve increased primary stability by placing implants in ridges in an advanced stage of bone healing, while offering patients the benefits associated with early implant placement.

## ABBREVIATIONS

PRF: platelet rich fibrin  
 PRP: platelet rich plasma

## REFERENCES

- Zarb GA, Schmitt A. The longitudinal clinical effectiveness of osseointegrated dental implants: the Toronto Study. Part II: The prosthetic results. *J Prosthet Dent.* 1990;64:53-61.
- Branemark PI. On looking back with Per-Ingvar Branemark. Interview. *Int J Prosthodont.* 2004;17:395-396.
- Albrektsson T, Wennerberg A. The impact of oral implants - past and future, 1966-2042. *J Can Dent Assoc.* 2005;71:327.
- Polizzi G, Grunder U, Goene R, et al. Immediate and delayed implant placement into extraction sockets: a 5-year report. *Clin Implant Dent Relat Res.* 2000;2:93-99.
- Chen ST, Wilson TG Jr., Hammerle CH. Immediate or early placement of implants following tooth extraction: review of biologic basis, clinical procedures, and outcomes. *Int J Oral Maxillofac Implants.* 2004;19:12-25.
- Buser D, Bornstein MM, Weber HP, Grutter L, Schmid B, Belsler UC. Early implant placement with simultaneous guided bone regeneration following single-tooth extraction in the esthetic zone: a cross-sectional, retrospective study in 45 subjects with a 2- to 4-year follow-up. *J Periodontol.* 2008;79:1773-1781.
- Buser D, Wittneben J, Bornstein MM, Grutter L, Chappuis V, Belsler UC. Stability of contour augmentation and esthetic outcomes of implant-supported single crowns in the esthetic zone: 3-year results of a prospective study with early implant placement postextraction. *J Periodontol.* 2011;82:342-349.
- Sanz I, Garcia-Gargallo M, Herrera D, Martin C, Figuero E, Sanz M. Surgical protocols for early implant placement in post-extraction sockets: a systematic review. *Clin Oral Implants Res.* 2012;23:67-79.
- Hammerle CH, Chen ST, Wilson TG Jr. Consensus statements and recommended clinical procedures regarding the placement of implants in extraction sockets. *Int J Oral Maxillofac Implants.* 2004;19:26-28.
- Ashman A. Ridge preservation: important buzzwords in dentistry. *Gen Dent.* 2000;48:304-312.
- Kotsakis GA, Salama M, Chrepa V, Hinrichs J, Gaillard P. A randomized, blinded, controlled clinical study of particulate anorganic bovine bone mineral and calcium phosphosilicate putty bone substitutes for alveolar ridge preservation. *Int J Oral Maxillofac Implants.* 2014;29:141-151.
- Le BT, Borzabadi-Farahani A. Simultaneous implant placement and bone grafting with particulate mineralized allograft in sites with buccal wall defects, a three-year follow-up and review of literature. *J Craniomaxillofac Surg.* 2014;42:552-559.
- Heberer S, Al-Chawaf B, Jablonski C, Nelson JJ, Lage H, Nelson K. Healing of ungrafted and grafted extraction sockets after 12 weeks: a prospective clinical study. *Int J Oral Maxillofac Implants.* 2011;26:385-392.
- Rutkowski JL, Johnson DA, Radio NM, Fennell JW. Platelet rich plasma to facilitate wound healing following tooth extraction. *J Oral Implantol.* 2010;36:11-23.
- Li Q, Pan S, Dangaria SJ, et al. Platelet-rich fibrin promotes periodontal regeneration and enhances alveolar bone augmentation. *BioMed Research Int.* 2013;2013:638043.
- Lekovic V, Milinkovic I, Aleksic Z, et al. Platelet-rich fibrin and bovine porous bone mineral vs. platelet-rich fibrin in the treatment of intrabony periodontal defects. *J Periodont Res.* 2012;47:409-417.
- Simonpieri A, Del Corso M, Sammartino G, Dohan Ehrenfest DM. The relevance of Choukroun's platelet-rich fibrin and metronidazole during complex maxillary rehabilitations using bone allograft. Part II: implant surgery, prosthodontics, and survival. *Implant Dent.* 2009;18:220-229.
- Kotsakis G, Chrepa V, Katta S. Practical application of the newly introduced natural bone regeneration (NBR) concept utilizing alloplastic putty. *Int J Oral Implantol Clin Res.* 2011;2:145-149.
- Dohan DM, Choukroun J, Diss A, et al. Platelet-rich fibrin (PRF): a second-generation platelet concentrate. Part I: technological concepts and evolution. *Oral Surg Oral Med Oral Pathol Oral Radiol Endod.* 2006;101:e37-e44.
- Kotsakis GA, Chrepa V, Marcou N, Prasad H, Hinrichs J. Flapless alveolar ridge preservation utilizing the "socket-plug" technique: clinical technique and review of the literature. *J Oral Implantol.* 2014;40:690-698.
- Buser D, Weber HP, Lang NP. Tissue integration of non-submerged implants. 1-year results of a prospective study with 100 ITI hollow-cylinder and hollow-screw implants. *Clin Oral Implants Res.* 1990;1:33-40.
- Evian CI, Rosenberg ES, Coslet JG, Corn H. The osteogenic activity of bone removed from healing extraction sockets in humans. *J Periodontol.* 1982;53:81-85.
- Schropp L, Isidor F, Kostopoulos L, Wenzel A. Patient experience of, and satisfaction with, delayed-immediate vs. delayed single-tooth implant placement. *Clin Oral Implants Res.* 2004;15:498-503.
- Chen ST, Beagle J, Jensen SS, Chiapasco M, Darby I. Consensus statements and recommended clinical procedures regarding surgical techniques. *Int J Oral Maxillofac Implants.* 2009;24:272-278.
- Barewal RM, Stanford C, Weesner TC. A randomized controlled clinical trial comparing the effects of three loading protocols on dental implant stability. *Int J Oral Maxillofac Implants.* 2012;27:945-956.
- Amler MH. The time sequence of tissue regeneration in human extraction wounds. *Oral Surg Oral Med Oral Pathol.* 1969;27:309-318.
- Amler MH, Johnson PL, Salman I. Histological and histochemical investigation of human alveolar socket healing in undisturbed extraction wounds. *J Am Dent Assoc.* 1960;61:32-44.
- Marx RE, Carlson ER, Eichstaedt RM, Schimmele SR, Strauss JE, Georgeff KR. Platelet-rich plasma: growth factor enhancement for bone grafts. *Oral Surg Oral Med Oral Pathol Oral Radiol Endod.* 1998;85:638-646.
- Landesberg R, Moses M, Karparkin M. Risks of using platelet rich plasma gel. *J Oral Maxillofac Surg.* 1998;56:1116-1117.
- Ortel TL, Mercer MC, Thames EH, Moore KD, Lawson JH. Immunologic impact and clinical outcomes after surgical exposure to bovine thrombin. *Ann Surg.* 2001;233:88-96.
- Sanchez AR, Sheridan PJ, Kupp LI. Is platelet-rich plasma the perfect enhancement factor? A current review. *Int J Oral Maxillofac Implants.* 2003;18:93-103.
- Choukroun J, Adda F, Schoeffler C, Vervelle A. Une opportunit  en paro-implantologie: le PRF [in French]. *Implantodontie.* 2000;42:55-62.
- Dohan DM, Choukroun J, Diss A, et al. Platelet-rich fibrin (PRF): a second-generation platelet concentrate. Part II: platelet-related biologic features. *Oral Surg Oral Med Oral Pathol Oral Radiol Endod.* 2006;101:e45-e50.
- Dohan Ehrenfest DM, de Peppo GM, Doglioli P, Sammartino G. Slow release of growth factors and thrombospondin-1 in Choukroun's platelet-rich fibrin (PRF): a gold standard to achieve for all surgical platelet concentrates technologies. *Growth Factors.* 2009;27:63-69.
- Pripatnanont P, Nuntanarant T, Vongvatcharanon S, Phurisat K. The primacy of platelet-rich fibrin on bone regeneration of various grafts in rabbit's calvarial defects. *J Cranio Maxillofac Surg.* 2013;41:e191-e200.
- Maciel J, Oliveira MI, Colton E, et al. Adsorbed fibrinogen enhances production of bone- and angiogenic-related factors by monocytes/macrophages. *Tissue Eng Part A.* 2014;20:250-263.
- Hauser F, Gaydarov N, Badoud I, Vazquez L, Bernard JP, Ammann P. Clinical and histological evaluation of postextraction platelet-rich fibrin socket filling: a prospective randomized controlled study. *Implant Dent.* 2013;22:295-303.
- Simon BI, Gupta P, Tajbakhsh S. Quantitative evaluation of extraction socket healing following the use of autologous platelet-rich fibrin matrix in humans. *Int J Periodont Restor Dent.* 2011;31:285-295.