

Anterior Loop of the Inferior Alveolar Canal: A Cone-Beam Computerized Tomography Study of 494 Cases

Halil Sahman, DDS, PhD^{1*}
Yildiray Sisman, DDS, PhD²

The aim of this study was to use cone-beam computerized tomography (CBCT) images of patients to assess the prevalence of different types, especially anterior loop, of the mental portion of the inferior alveolar canal and to evaluate the anterior loop lengths. CBCT images of 494 patients providing inclusion criteria were examined by 2 oral radiologists. Sagittal, axial, and multiplanar reformatted images were used to detect the type of mental portion of the inferior alveolar canal. The anterior loop length was measured in the respective sections of each CBCT image. Statistical analysis was performed using SPSS v. 15, and *t* tests were used for statistical analysis. Of the 494 patients, 217 anterior loops were detected in 141 (28.5%) patients. The mean anterior loop lengths for the right side and the left side were 2.19 ± 1 mm and 2.08 ± 0.89 mm, respectively. The difference between males and females in the mean anterior loop length was statistically significant for both sides (Right: $P < .05$; Left: $P < .05$). A presurgical CBCT image examination is necessary prior to implant insertion to reveal the presence of anterior loop and to detect actual anterior loop length.

Key Words: anterior loop, inferior alveolar canal, cone beam computerized tomography, mental foramen

INTRODUCTION

The inferior alveolar canal is usually divided into 2 parts in the premolar region: the mandibular incisive canal and the mental canal.¹ The closest portion of the inferior alveolar canal to the mental foramen curves upwards to form the mental foramen on the buccal side of the mandible. The inferior alveolar nerve emerges from the mental foramen and generates the mental nerve, which is a somatic afferent sensory nerve supplying the chin and lower lip area.²

The mental portion of the inferior alveolar canal is classified into 3 types according to the course of the canal: straight, vertical, and anterior loop (AL).³⁻⁵ Of these types, the AL has been the focus of much research because of its clinical importance.^{2,6} In the AL type, the inferior alveolar canal runs upward and backward before creating the mental foramen.⁷ Researchers have studied the AL with cadavers, orthopantomographs (OPGs), periapical radiographs, computerized tomography (CT), and cone-beam computerized tomography (CBCT).^{3,8-11} The literature has reported large variations (7% to 88%) in the prevalence of the AL.^{8,12} Also, anterior loop lengths (ALLs) were evaluated on radiographs and cadaver sections.^{3-5,7} Values ranging from 0.11 mm to 11 mm were reported in the literature.^{3,12,13}

Any violation of the inferior alveolar canal may damage the inferior alveolar nerve and adjacent vascular structures.¹⁴ Care must therefore be taken during surgical procedures in patients with an AL. In implant applications, a safe area must be left between the distal surface of the implant and the mesial

surface of the mental foramen. Researchers have proposed various safe area distances, from 1 mm to 6 mm.^{15,16}

The goals of the present study were to assess the prevalence of the different types of the mental portion of the inferior alveolar canal and to evaluate the ALLs using CBCT images from a group of the Turkish population. Descriptions of the radiological characteristics of the ALs are presented using one of the largest data of CBCT images in the literature.

MATERIALS AND METHODS

A retrospective study was carried out using CBCT (Accuitomo 170, J. Morita Mfg Corp, Kyoto, Japan; automatic exposure parameters) images obtained from patients referred to the Panoson Medical Imaging Center with various dental problems (implant insertion, planning of surgery, orthodontic treatment, etc). A study population was homogeneously selected from Turkey's northwestern population. The slice thickness (0.125–0.25 mm isotropic voxel size) varied according to the requirement of each individual, and the images were taken by a radiology technician. A total of 542 CBCT images were examined and 48 were excluded due to the exclusion criteria, described as follows:

- Insufficient image quality caused from various errors
- Any lesions and unerupted teeth in the premolar region
- The presence of fractures
- Ongoing orthodontic treatment
- Excessive resorption of the mandibular crest

The remaining 494 CBCT images were included in the present study. Study population consisted of 240 (48.6%) females and 254 (51.4%) males (age range 20–84 years; mean age 41.2 ± 15).

¹ Department of Dentomaxillofacial Radiology, Faculty of Dentistry, Abant İzzet Baysal University, Bolu, Turkey.

² Department of Dentomaxillofacial Radiology, Faculty of Dentistry, Erciyes University, Kayseri, Turkey.

* Corresponding author, e-mail: dt.sahman@gmail.com

DOI: 10.1563/aaid-joi-D-15-00038

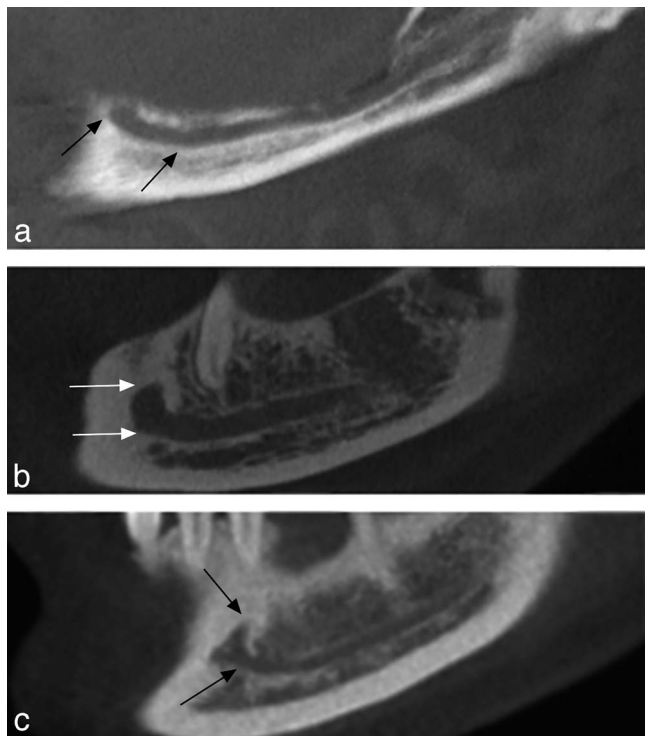


FIGURE 1. Cone-beam computerized tomography images of different patients show the straight (a), vertical (b), and anterior loop (c) types of the inferior alveolar canal. Mental portion was indicated between the arrows.

CBCT examinations

Two oral radiologists (HS and YS) with a minimum 7 years of experience examined the CBCT images together. Whenever a disagreement occurred between the 2 observers' assessments, a consensus was reached by discussion. Images were processed with I-Dixel software (V 1.1.6.4, J. Morita). The sagittal, cross-sectional, and multiplanar reformatted images of the patients were carefully evaluated. Multiplanar reformatted images parallel to the hemimandibles were used to evaluate the type of the canal (Figure 1). The ALL was evaluated in the respective sections of each CBCT image with the length measurement tool of the I-Dixel software, at magnification up to 4X. The ALL is the

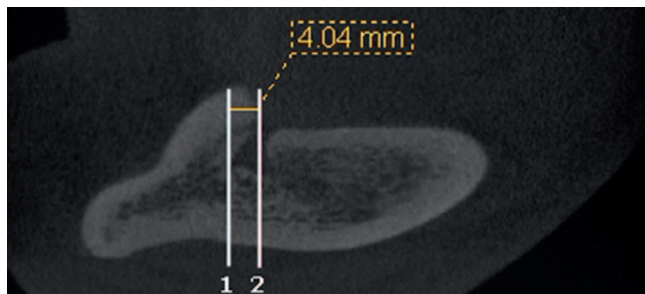


FIGURE 2. Cone-beam computerized tomography image of patient shows the anterior loop with 4.04 mm. Anterior loop length is the distance between the anterior borders of the inferior alveolar canal curve (1) and the mental foramen (2).

TABLE 1
Different types of inferior alveolar canal according to the sides are shown

	Vertical	Straight	AL*	Total
Right	210 (42.5%)	168 (34%)	116 (23.5%)	494
Left	232 (47%)	161 (32.6%)	101 (20.4%)	494

*AL, anterior loop.

distance between the anterior borders of the inferior alveolar canal curve and the mental foramen (Figure 2).

Statistical analysis

The statistical analysis was performed using SPSS v. 15 (SPSS Inc., Chicago, Ill), and comparisons of values of all measurements were made between sides and genders using *t* tests. A *P* value < .05 was considered statistically significant.

RESULTS

CBCT images of 494 patients were included in this study. The most frequent canal type was the vertical (right = 210, left = 232; Table 1). In the study group, 217 ALs were detected in 141 (28.5%) patients. Of these patients, 65 (46.1%) had a unilateral AL, and 76 (53.9%) had bilateral AL. Of the unilateral cases, 40 (61.5%) were at the right side, and 25 (38.5%) were at the left side. There was no statistically significant difference in the presence of the AL between males and females (*P* > .05; Table 2).

The mean ALLs for the right side and the left side were 2.19 ± 1 mm (ranging from 0.6 to 6 mm) and 2.08 ± 0.89 mm (ranging from 0.6 to 4.5 mm), respectively. Figure 3 shows the 3 samples of the ALL measurements. The difference between the sides in the mean ALLs was not statistically significant (*P* > .05; Table 3). The mean ALL in males was greater than that in females. The difference between males and females in the mean ALL was statistically significant for both sides (Right: *P* < .05; Left: *P* < .05; Table 4).

DISCUSSION

Many different methods have been used to study the AL (cadavers, OPG, CT, and CBCT).^{3,8-11} The AL type was identified in 37%,³ 61.5%,¹⁷ 59%,¹⁶ 62.7%,⁵ and 88%¹² of cases in the

TABLE 2
Different types of inferior alveolar canal according to the gender are shown

	Gender	Vertical	Straight	AL	Total	<i>P</i> value
Right	M*	109 (42.9%)	76 (29.9%)	69 (27.3%)	254	.060
	F	101 (42.1%)	92 (38.3%)	47 (19.6%)	240	
Left	M	119 (46.9%)	80 (31.5%)	55 (21.7%)	254	.774
	F	113 (47.1%)	81 (33.8%)	46 (19.1%)	240	

*M, male; F, female; AL, anterior loop.

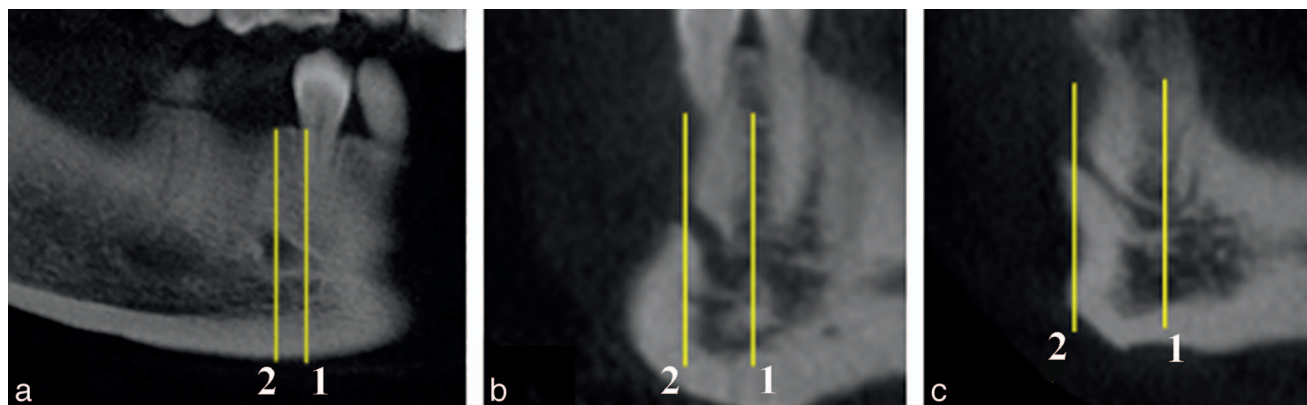


FIGURE 3. Cone-beam computerized tomography images of different patients reveal following anterior loop lengths: (a) 2.5 mm, (b) 4.8 mm, (c) 6 mm. The most anterior borders of the inferior alveolar canal curve (1) and the mental foramen (2) are indicated.

different cadaver studies. However, insufficient numbers of cases in these studies may restrict assessments of the actual prevalence. Therefore, it is necessary to consider the incidence reported in studies with a greater number of subjects. In OPG-based studies, researchers reported an AL in 12% of 324 OPGs,¹¹ 11% of 545 OPGs,⁹ and 40% of 240 OPGs.⁷ Another cadaver study of 140 hemimandibles observed an AL in 99 (71%) cases.⁴ An examination of 694 CBCT scans revealed an AL prevalence of 69.73%.¹⁸

In the present study, 217 (21.7%) ALs were detected in 494 CBCT images of the patient. To the best of our knowledge, the present study was performed with 1 of the largest CBCT datasets in the literature.¹⁸ The wide range of current values in the literature may originate from ethnic differences, varied study techniques, and the number of study subjects. Among the different techniques, the data obtained from cadavers are certainly the most accurate. However, CT and CBCT techniques have gained acceptance as a gold standard. In contrast, values derived from OPGs can be very misleading due to limitations of 2-dimensional radiographic techniques.^{19,20}

The literature contains reports of different mean ALL values, depending on the measurement technique used. In OPG-based studies, mean ALL values of 1 mm,¹⁶ 2.5 mm,¹⁵ 4.13 mm,¹² and 5 mm¹¹ have been reported. Mean ALL values of 1.5 mm,⁵ 2.69 mm,²¹ and 5 mm²² were reported in cadaver studies. CBCT studies reported a mean ALL of 0.89 mm,⁶ 2.09 mm,² 2.40 mm,¹³ and 3.54 mm.²³ In the present study, the mean ALL for the right and left sides was 2.19 ± 1 mm (0.6 mm to 6 mm) and 2.08 ± 0.89 mm (0.6 mm to 4.5 mm), respectively. Neither this study nor the previous studies showed any statistically significant difference between the sides ($P = .431$). Previous studies reported statistically significant sex-based differences in

the mean ALL.^{4-6,13} In the current study, the mean ALL of the males was greater than that of the females for both sides. The findings of the present study are in accordance with those reports, with the difference in ALLs statistically significant for both sides in males and females (Right: $P < .001$; Left: $P = .004$).

Direct trauma to the inferior alveolar canal and may induce pain, sensory disturbance, and increased bleeding during or after an operation.¹⁴ Particular attention must be paid to the ALL during the insertion of implants in the premolar region.^{4,5} Studies have reported sensory disturbance lasting 3–16 months after the insertion of implants in the interforaminal region.²⁴⁻²⁶ As a result, researchers have proposed that a safe area should be left between the distal surface of the implant and mesial surface of the mental foramen. However, they have recommended different safe area distances, such as 1 mm,¹⁵ 2 mm,²⁷ 3 mm,²⁵ 4 mm,³ and 6 mm.¹⁶ Considering the difference among the minimum, maximum, and mean values of ALLs, it may be risky to rely on a standard safe area before implant applications.⁵

Uchida et al⁴ evaluated ALLs using the CBCT image compared with the cadaver of the same mandibles; equal results with very small differences were found. Therefore, it appears that the results of CBCT systems are closest to actual anatomical measurements. Based on the present literature, CBCT systems offer superior opportunity, such as high-contrast, cross-sectional, and multiplanar images, for evaluating ALs. CT imaging may also provide sufficient view of the interforaminal region. However, disadvantages such as limited voxel sizes, high costs, and too much radiation dose in comparison to CBCT restrict its usage in dentistry.^{28,29} In contrast, some information obtained with OPG-based studies are highly suspecting due to

Anterior loop lengths according to the sides are shown						
	Number	Min* (mm)	Max (mm)	Mean (mm)	SD (mm)	P value
Right	116	0.6	6	2.19	1	.431
Left	101	0.6	4.5	2.08	.89	

*Min, minimum length; Max, maximum length; SD, standard deviation.

Anterior loop lengths according to the gender are shown					
	Gender	Number	Mean (mm)	SD* (mm)	P value
Right	M	69	2.45	1.01	< .001
	F	47	1.79	.87	
Left	M	55	2.31	.86	.004
	F	46	1.81	.86	

*SD, standard deviation.

the limitations of two-dimensional imaging, including the superimposition of anatomical structures and image distortions.^{19,20} In the light of this knowledge, the following can be concluded: (1) ALs detected in OPGs may not really exist; (2) OPGs fail to detect some existing ALs; and (3) the length of ALs may be incorrectly measured using OPGs (ie, the AL may be longer or shorter than its actual length).^{3,5,19,21}

CONCLUSIONS

When tomographic techniques are considered to be the gold standard in dental imaging, a presurgical CBCT examination is necessary prior to implant insertion to reveal the AL and actual ALL (ie, relying on a standard distance to determine the safe area may not be appropriate).

ABBREVIATIONS

AL: anterior loop
ALL: anterior loop length
CBCT: cone-beam computerized tomography
CT: computerized tomography
OPG: orthopantomograph

REFERENCES

1. Neves FS, Torres MG, Oliveira C, Campos PS, Crusoe-Rebello I. Lingual accessory mental foramen: a report of an extremely rare anatomical variation. *J Oral Sci.* 2010;52:501–503.
2. Li X, Jin ZK, Zhao H, Yang K, Duan JM, Wang WJ. The prevalence, length and position of the anterior loop of the inferior alveolar nerve in Chinese, assessed by spiral computed tomography. *Surg Radiol Anat.* 2013;35:823–830.
3. Kuzmanovic DV, Payne AG, Kieser JA, Dias GJ. Anterior loop of the mental nerve: a morphological and radiographic study. *Clin Oral Implants Res.* 2003;14:464–471.
4. Uchida Y, Noguchi N, Goto M, et al. Measurement of anterior loop length for the mandibular canal and diameter of the mandibular incisive canal to avoid nerve damage when installing endosseous implants in the interforaminal region: a second attempt introducing cone beam computed tomography. *J Oral Maxillofac Surg.* 2009;67:744–750.
5. Uchida Y, Yamashita Y, Goto M, Hanihara T. Measurement of anterior loop length for the mandibular canal and diameter of the mandibular incisive canal to avoid nerve damage when installing endosseous implants in the interforaminal region. *J Oral Maxillofac Surg.* 2007;65:1772–1779.
6. Apostolakis D, Brown JE. The anterior loop of the inferior alveolar nerve: prevalence, measurement of its length and a recommendation for interforaminal implant installation based on cone beam CT imaging. *Clin Oral Implants Res.* 2012;23:1022–1030.
7. Ngeow WC, Dionysius DD, Ishak H, Nambiar P. A radiographic study on the visualization of the anterior loop in dentate subjects of different age groups. *J Oral Sci.* 2009;51:231–237.
8. Jacobs R, Mraiwa N, vanSteenberghe D, Gijbels F, Quirynen M. Appearance, location, course, and morphology of the mandibular incisive canal: an assessment on spiral CT scan. *Dentomaxillofac Radiol.* 2002;31:322–327.
9. Jacobs R, Mraiwa N, Van Steenberghe D, Sanderink G, Quirynen M. Appearance of the mandibular incisive canal on panoramic radiographs. *Surg Radiol Anat.* 2004;26:329–333.
10. Kieser J, Kuzmanovic D, Payne A, Dennison J, Herbison P. Patterns of emergence of the human mental nerve. *Arch Oral Biol.* 2002;47:743–747.
11. Misch CE, Crawford EA. Predictable mandibular nerve location—a clinical zone of safety. *Int J Oral Implantol.* 1990;7:37–40.
12. Neiva RF, Gapski R, Wang HL. Morphometric analysis of implant-related anatomy in Caucasian skulls. *J Periodontol.* 2004;75:1061–1067.
13. Rosa MB, Sotto-Maior BS, Machado Vde C, Francischone CE. Retrospective study of the anterior loop of the inferior alveolar nerve and the incisive canal using cone beam computed tomography. *Int J Oral Maxillofac Implants.* 2013;28:388–392.
14. Greenstein G, Tarnow D. The mental foramen and nerve: clinical and anatomical factors related to dental implant placement: a literature review. *J Periodontol.* 2006;77:1933–1943.
15. Bavitz JB, Harn SD, Hansen CA, Lang M. An anatomical study of mental neurovascular bundle-implant relationships. *Int J Oral Maxillofac Implants.* 1993;8:563–567.
16. Solar P UC, Frey G, Matejka M. A classification of the intraosseous paths of the mental nerve. *Int J Oral Maxillofac Implants.* 1994;9:339–344.
17. Hu KS, Yun HS, Hur MS, Kwon HJ, Abe S, Kim HJ. Branching patterns and intraosseous course of the mental nerve. *J Oral Maxillofac Surg.* 2007;65:2288–2294.
18. Filo K, Schneider T, Locher MC, Kruse AL, Lubbers HT. The inferior alveolar nerve's loop at the mental foramen and its implications for surgery. *J Am Dent Assoc.* 2014;145:260–269.
19. Sahman H, Sekerci AE, Sisman Y, Payveren M. Assessment of the visibility and characteristics of the mandibular incisive canal: cone beam computed tomography versus panoramic radiography. *Int J Oral Maxillofac Implants.* 2014;29:71–78.
20. Scarfe WC, Eraso FE, Farman AG. Characteristics of the Orthopantomograph OP 100. *Dentomaxillofac Radiol.* 1998;27:51–57.
21. Arzouman MJ, Otis L, Kipnis V, Levine D. Observations of the anterior loop of the inferior alveolar canal. *Int J Oral Maxillofac Implants.* 1993;8:295–300.
22. Hwang K, Lee WJ, Song YB, Chung IH. Vulnerability of the inferior alveolar nerve and mental nerve during genioplasty: an anatomic study. *J Craniofac Surg.* 2005;16:10–14; discussion 14.
23. Parnia F, Moslehifard E, Hafezeqoran A, Mahboub F, Mojaver-Kahnamoui H. Characteristics of anatomical landmarks in the mandibular interforaminal region: a cone-beam computed tomography study. *Med Oral Patol Oral Cir Bucal.* 2012;17:e420–e425.
24. Bartling R, Freeman K, Kraut RA. The incidence of altered sensation of the mental nerve after mandibular implant placement. *J Oral Maxillofac Surg.* 1999;57:1408–1412.
25. Wismeijer D, van Waas MA, Vermeeren JI, Kalk W. Patients' perception of sensory disturbances of the mental nerve before and after implant surgery: a prospective study of 110 patients. *Br J Oral Maxillofac Surg.* 1997;35:254–259.
26. Walton JN. Altered sensation associated with implants in the anterior mandible: a prospective study. *J Prosthet Dent.* 2000;83:443–449.
27. Misch CE. Root form surgery in the edentulous mandible: Stage I implant insertion. In: Misch CE, ed. *Contemporary Implant Dentistry.* St Louis, MO: The CV Mosby Company; 1999.
28. Patil S, Matsuda Y, Okano T. Accessory mandibular foramina: a CT study of 300 cases. *Surg Radiol Anat.* 2013;35:323–330.
29. Sahman H, Sekerci AE, Ertas ET. Lateral lingual vascular canals of the mandible: a CBCT study of 500 cases. *Surg Radiol Anat.* 2014;36:865–870.