

Implant Placement in Failed Endodontic Sites: A Review

Dennis Flanagan, DDS, MSc

Dental implants may fail to osseointegrate in sites of endodontic failure. This may occur as a result of colonization by various anaerobic and facultative bacterial species. If an implant is placed in a site where vegetative bacteria are residing, the implant may fail to integrate if a bacterial colonization proceeds coronally. If the implant apical cortical bone is thin or if there is an apical fenestration, the colonization may proceed through the thin or nonexistent bone through the covering mucosa, relieving inflammatory pressure to create an apical (retrograde) peri-implantitis. *Enterococcus faecalis* may be the prime culprit in these types of implant failures. After thorough debridement, the implant may be immediately placed after extraction of an endodontically failed tooth, and the patient treated with an appropriate antibiotic. Alternatively waiting for postextraction healing and subsequent implant placement can be done. Nevertheless, either way may allow for the formation of bacterial vegetative forms or biofilms. The implant surface may be colonized when the surface is exposed to the bacteria. Thorough debridement is crucial. Nonetheless, organisms may persist. Randomized controlled trials are needed to elucidate this issue.

Key Words: root canal, failed treatment, debridement, endodontic, dental implant, bacteria, colonization, foreign body

INTRODUCTION

There is some evidence that there is a higher implant failure rate in sites where endodontic treatment has failed, the tooth was extracted, the site allowed to heal, and an implant placed.¹ This may be especially true when the implant is placed into a site subsequent to failed apical surgery.¹ Endodontic therapy is mostly a successful treatment modality; rendered by general practitioners, it may be very successful at about 85%.² However, endodontic failures do occur for generalists and specialists.

Endodontically treated teeth fail for a variety of reasons: apical transportation, short/overextended fill, root fracture, poor coronal seal, or unfilled accessory canals. Extraction may be indicated. There are two basic methods for treating these teeth with dental implants. The tooth can be extracted and the site grafted (if necessary) and allowed to heal and the implant placed later, or the tooth can be extracted, the site debrided, and the implant placed immediately.

The object of this discussion is to review the issue of the placement of an implant into the site of an extracted endodontically failed tooth.

TYPICAL SCENARIO

Generally, when a failed endodontic tooth is extracted, the socket is debrided and may be grafted, or an implant is immediately placed. Residual bacteria remaining in the bone may colonize the implant surface; the implant will then fail to integrate. The implant can lose immobility early or late, and bone loss occurs (Figures 1 and 2). The implant may be exfoliated, and the patient may present with the implant fixture in hand. Alternatively, a retrograde peri-implantitis may occur.⁵³

Private practice, Willimantic, Conn.

Corresponding author, e-mail: dffdds@comcast.net

DOI: 10.1563/aaid-joi-D-15-00126

DISCUSSION

No endodontically treated tooth is aseptic at the apex.³ When an infected tooth is extracted, there may be residual bacterial planktonic forms or biofilms in the bone that subsequently may colonize the implant surface, a foreign body.^{3,4} The implant surface colonization may not be clinically evident for many postoperative weeks. Nevertheless, this may be clinically evident as an early, intermediate, or late failure.

It is assumed that the clinician performs a diligent debridement of the site before an osteotomy is performed. However, it may be possible that even after a diligent debridement, residual organisms persist and vegetate (Figure 3).

Rough surface implants may be more susceptible to detrimental bacterial colonization than machined surface implants.⁵ *Prevotella intermedia* can colonize rough surface implants and cause more bone loss in relation to implant contact as compared to machined surfaced implants.⁵

Endodontic treatment can fail for a variety of reasons, including apical transportation, root cracks and fractures, perforations, short or overfills, separated instruments, and inadequate debridement.⁶ These teeth may require extraction.

Antibiotic therapy is an important adjunct to endodontic therapy.⁷ Bacteriocidal agents such as penicillin and amoxicillin may be most appropriate, and for those allergic patients, clindamycin or quinolones for endodontic infections. However, *Enterococcus faecalis* can be resistant to clindamycin.⁷

Before and after endodontic therapy, the canal space contains bacteria. *E. faecalis* is commonly found about the apex of endodontically treated teeth.^{4,8} However, Gomes and co-workers found multiple species that included *Peptostreptococcus micros*, *Fusobacterium necrophorum*, *Fusobacterium nucleatum*, *Prevotella intermedia/nigrescens*, *Porphyromonas gingivalis*, and *Porphyromonas endodontalis*.⁹ Thus, a multiplicity of bacterial species can reside in and around these teeth and act in concert.

Bacterial competition may make a species domination a

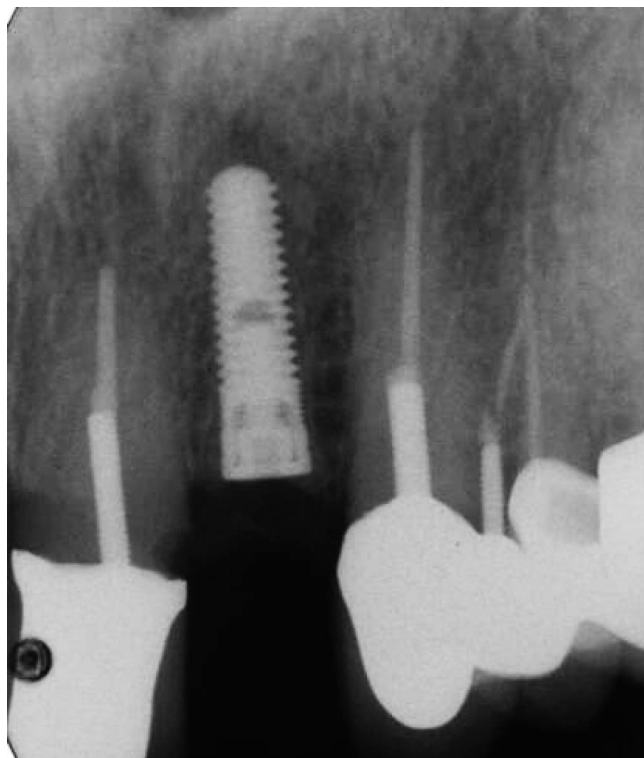


FIGURE 1. The left maxillary lateral incisor was extracted and an implant placed after healing.

dynamic issue. If an infected apical lesion remains untreated, the various bacterial species compete for nutrients and defend themselves from the antibiotics from other species. Thus, any domination of any particular species or group of synergistic species changes as the lesion remains untreated. The influence of plasmid transfer also may affect species domination.

Untreated teeth with apical infections have a mixed flora of gram-negative and gram-positive anaerobic species.¹⁰ However, failed root-filled teeth are usually found to have facultative anaerobic gram-positive species. After failed endodontic treatment, the infecting flora undergoes a change of population and metabolic character; typically, a subsequent mixed flora is common.¹⁰ This process may favor species that can more easily vegetate.

If an infected tooth is extracted and the pathogenic bacteria are not completely removed by debridement and chemotherapy, certain residual bacteria may assume a vegetative state in the alveolar cancellous bone.³ They surround themselves with a protective coating that may be impervious to antibiotics and antibodies. Immunity and antibiotic therapy during osseous healing may not completely eliminate these vegetative forms.^{1,3,6} After many weeks of osseous healing, if the site is drilled for an osteotomy and an endosseous implant is placed, the vegetative form may then be reactivated to colonize the implant surface.^{1,3,6} The implant surface colonization can continue, and the implant becomes mobile and fails. This implant failure may occur after several days, weeks, or months.

The bacteria in failed endodontically treated teeth can be found intra- and extraradicularly.⁶ Endodontic infections can

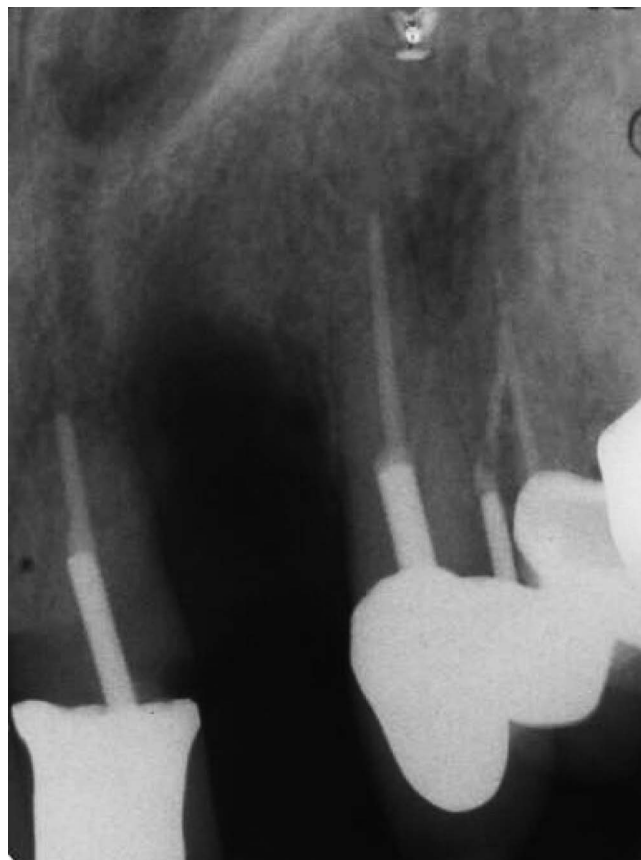

FIGURE 2. The implant subsequently failed to integrate.

diffuse into the surrounding alveolar bone. These now intraosseous endodontic infectious bacteria may infect the implant surface as biofilms and may be the primary cause of the implant failure.¹

There is a coterie of bacterial species that are associated with failed endodontic treatment.⁹ They are mostly gram-positive facultative anaerobes.^{1,9} *E. faecalis* can be the predominant species isolated. These endodontic associated infections are polymicrobial.^{1,9,11} Obligate anaerobes are usually found in the canal spaces of root filled teeth.^{1,9} This array of bacterial species infects the apical region of a failed endodontically treated tooth.¹¹ The definitive identification of infected root apices can now be done with DNA polymerase chain reaction testing. In one study, lesions were sampled from "primary endodontic infections associated with asymptomatic periradicular lesions, acute apical periodontitis, or acute periradicular abscesses and in samples from patients in whom endodontic therapy had failed."¹² *Propionibacterium propionicus* was identified in 58% of lesions from these failed endodontically treated teeth. Further, a recently identified species, *Actinomyces radidentis*, was found in 8% of these failed endodontically treated teeth lesions. *E. faecalis* was found in the minority.^{13,14} However, *E. faecalis* is a facultative anaerobe commonly found in failed endodontic lesions.¹⁵ Viable *E. faecalis* exhibits an unusual phenomenon in which they are found to be microscopically visible but may be nonculturable.¹⁶ Thus, their presence may be missed in any

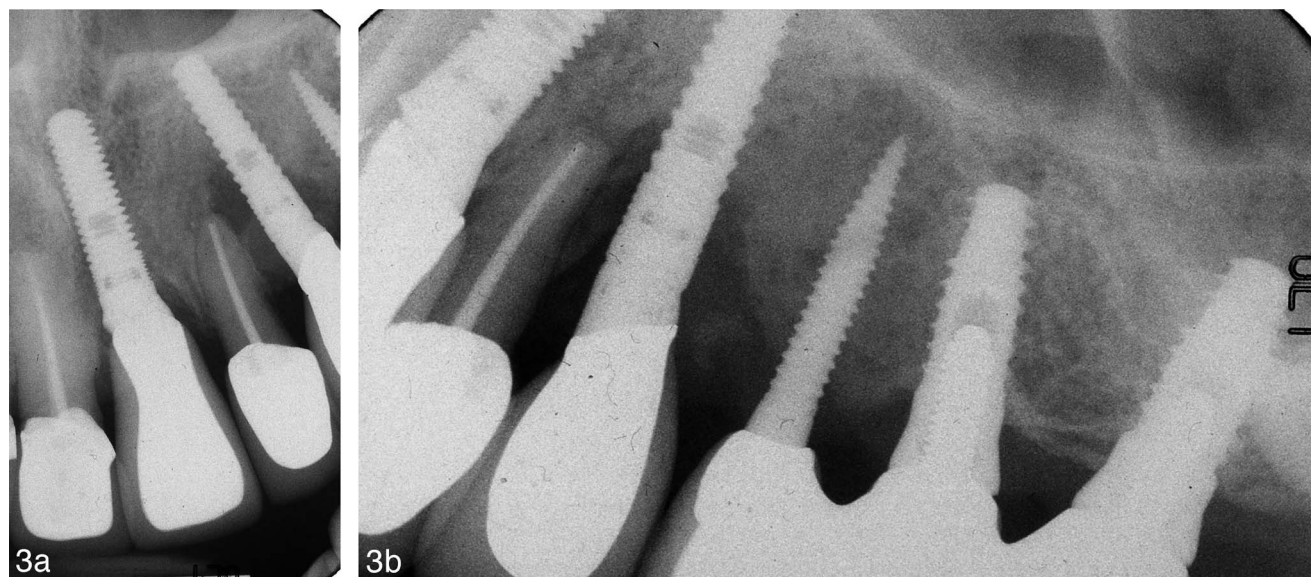


FIGURE 3. Adjacent septic apex seems to have infected the adjacent implant but residual bacteria may have vegetated after the extraction.

bacteriologic study of these apical lesions. They have an ability to adhere to human mucosa, but in the nonculturable phase, have a reduced adherence capability to 50–70%. Enterococci are able to survive very harsh environmental conditions, such as a pH of 9.6, bile salts, detergents, heavy metals, ethanol, azide, and desiccation.¹⁷ In tropical water, vegetative fecal bacteria can survive for some time and later recolonize.¹⁸ *E. faecalis* may be resistant to aminoglycosides, aztreonam, cephalosporins, clindamycin, the semisynthetic penicillins nafcillin and oxacillin, and trimethoprim-sulfamethoxazole.¹⁹

E. faecalis can survive long periods of nutritional deprivation.¹⁷ This species can bind to dentin and penetrate dentinal tubules for a safe haven. *E. faecalis* can alter the patient's immune response and suppress lymphocytes and resist the action of calcium hydroxide. Additionally, *E. faecalis* can form a biofilm that can protect it from antibiotics.¹⁷

E. faecalis can survive glucose starvation conditions. The bacterium produces a hydrophobic cell surface. There is also an upregulation of genes for stress response and biofilm formation. Thus, *E. faecalis* can persist in energy-starved conditions and withstand antibiotic attack. This ability may explain its presence in persistently failed root canal treatment.^{4,20} Therefore, *E. faecalis* may be able to vegetatively survive in trabecular bone and subsequently colonize an implant placed in a site where the vegetating bacteria are residing.

One study by Love postulated that the virulence of *E. faecalis* may be related to the ability of these cells to invade dentinal tubules and adhere to collagen.²¹ Collagen is a major component of bone. This ability to adhere to collagen was decreased for other bacteria, but enhanced for *E. faecalis* by the presence of human serum. Thus, it may be possible for this species to adhere to osseous collagen polymer chains and remain in a vegetative state, protected from serum antibodies and antibiotics. Kishen and co-workers found that, in vitro, *E. faecalis* had an ability to firmly adhere to dentin as a calcified biofilm.²²

A study by Vidana and colleagues found that the presence of *E. faecalis* infecting failed root filled teeth were not present in the patient's saliva.²³ They concluded that these infections may be of exogenous origin because genetic analysis demonstrated that the bacteria were not related to the patient's normal floral enterococci present in the gastrointestinal tract and saliva. Another study concluded that a patient may harbor different strains of *E. faecalis* in saliva and root infections.²⁴ Patients who bite their fingernails have a high enteric bacteria oral population.²⁵ Non-fingernail biters generally have little or no oral enteric forms. The source of these bacteria has not been studied, neither has infectious consequences to fingernail biting.

Some endodontic sealers are permeable to *E. faecalis* and allow dentinal tubule penetration.²⁶ This property may allow this species to penetrate into the root and precipitate endodontic therapeutic failure.

Generally, endodontic irrigants are very effective against endodontic pathogens except *E. faecalis*.^{27,28} Sodium hypochlorite, chlorhexidine, and calcium hydroxide can reduce *E. faecalis* bacterial counts but may not completely eliminate the pathogen from an infected site.²⁹ Alternating the use of sodium hypochlorite and (EDTA) root canal irrigants demonstrate an increased elimination of *E. faecalis*.³⁰ This sequence of irrigants may increase successful endodontic treatment and reduce the potential for a subsequent failed implant should the endodontic treatment indeed fail. Nevertheless, any surviving bacteria may proliferate and become a clinical problem.

There are other species not found as frequently in failed root filled teeth as *E. faecalis*. The strict anaerobes *Filifactor alocis*, *Tannerella forsythia*, and *Treponema denticola* may be found in primary and secondary root-infected canals with periapical lesions.¹⁰ These species are associated with pain, swelling, mobility, and tenderness to percussion, but not so much with failed endodontic treatment.

Actinomyces sp. is a gram-positive, facultative anaerobic bacterium that rarely infects the jaws but can penetrate

surrounding bone. It has, however, been found in persistent apical lesions as part of a multimicrobial infection.³¹ This species may indeed remain in bone and potentially colonize an implant surface.

Many oral bacteria and fungi are spore formers.³² The spore is a vegetative form that enables the bacterial species to survive inhospitable conditions. Conceivably, these forms may survive in bone after an extraction to colonize an implant later placed in that particular site.³³ Many spore-forming bacteria have insoluble proteinaceous coats and layers that are responsible for resistance to antibiotic attack, adhering properties, and pathogenicity.^{34,35} The layers are resistant to sterilants and disinfectants.³⁵ These layers and coats are important for the survival of the species, allowing the spore to germinate and revitalize when appropriately simulated for recolonization. There may be lag times for germination, depending on the species and the environmental conditions.³⁶ Ozone and ultraviolet radiation may be effective in inactivating spore forms but clinically impractical for intraosseous applications.^{37,38}

Cholesterol is a common finding in failed endodontically treated teeth and may be a contributing etiologic agent.³⁹ Cellular immunity cannot eliminate cholesterol crystals from apical lesions, and this may interfere with healing. The cholesterol crystals are irritating to the osseous tissue and this—as well as other agents—may prevent successful orthograde retreatment. Thus, physical removal of the crystals by extraction and debridement may be indicated.³⁹

Placing immediate implants into periodontally infected sites can be successful, but the bacterial flora in these cases generally consist of different species than in infected endodontic sites.⁴⁰ These species may not be effective intraosseous vegetative residents. However, many periodontal bacterial species have a low susceptibility to phagocytosis by polymorphonuclear leukocytes.⁴¹

It may be better to immediately place an implant after extraction to preclude a bacterial colonization rather than wait for socket healing.⁴² Immediate placement has long ago been shown to be a successful method for implant placement.⁴³ Immediate implant placement may reduce osseous resorption, whereas socket preservation may not prevent bone loss in anterior teeth and premolar sites.⁴⁴ Immediate implant placement into failed endodontic sites has shown to be successful when there is diligent debridement⁴⁵; nevertheless, complete and total bacterial elimination may not occur.

Immediate placement of an implant after tooth extraction may be an advantage in preventing bacterial colonization of the implant surface by potentially avoiding the vegetative phase.⁴⁵ Healing cytokines and neutrophils may act to inhibit bacterial colonization.^{42,46–48} The immediately placed implant surface may be a positive influence on cytokine and osteoblast activity.⁴⁹ Alternative surfaces, such as mineral trioxide aggregate, may have an enhanced influence on osseous regeneration as compared to titanium implant surfaces.⁴⁹

During healing, osteoblasts can be stimulated by bacterial lipopolysaccharides, and can produce abundant interleukin-type inflammatory cytokines that encourage bone formation.⁴⁹ Thus, the mere presence of some bacterial species may promote better healing. That said, immediate placement may

induce a compensatory metabolic reaction that outweighs any potential for bacterial colonization.⁴⁹

Retrograde peri-implantitis may be a result of placing implants into healed failed endodontic sites as opposed to immediate placement after the extraction of the failed endodontic tooth (Figure 4).^{50–53} Retrograde or apical peri-implantitis may be the result of colonization of vegetating bacteria on an implant apical surface.⁵² If an implant is placed in a healed site where vegetative bacteria are residing, the implant may have an early failure if the colonization proceeds coronally, causing a loss of osseous support.⁵⁴ If the implant apical cortical bone is thin or there is an apical osseous fenestration, the colonization may break through thin or nonexistent bone and into the facial soft tissue to create a radiolucent lesion at the implant apex.^{50,52,53} Treatment options are apical detoxification, implant apicoectomy, or implant removal.

In one recent study of retreatment resistant apical endodontic lesions, most lesions were found to be cysts and granulomas containing gram-positive strict anaerobes.⁵⁵ In this study, the most frequently found species in the cysts and granulomas were *Gemella morbillorum* and *Propionibacterium acnes*. It was concluded that some bacterial species can survive outside of the root canal space in the bone and persist as pathogens.^{1,55} The two most important parameters for successful endodontic treatment are a good apical seal and a definitive coronal restoration.⁵⁶

One study found in vitro bacterial antibiotic resistance among common peri-implant microbiota.⁵⁷ Bacterial specimen were cultivated from 160 dental implants with peri-implantitis. Substantial minorities of *Prevotella intermedia nigrescens* and *Streptococcus constellatus* were found to be resistant to clindamycin, amoxicillin, doxycycline, or metronidazole. Only 6.7% were resistant to both amoxicillin and metronidazole. Overall, 71.7% of patient peri-implantitis species were resistant in vitro to one or more of the tested antibiotics.⁵⁷ Thus, systemic antibiotic therapy alone may not be entirely effective in treating peri-implantitis; systemic and locally delivered high-dose antibiotic may be more appropriate.⁵⁸ Bacterial resistance and antibiotic accessibility may be important factors in resolving these infections. Nevertheless, treatment methodology of colonized dental implant surfaces remains controversial.^{1,58}

Many species may survive by self-encapsulated biofilms that resist antimicrobial treatment.^{1,3,20,59} Therefore, thorough debridement of a chronically infected extraction site is paramount prior to an immediate implant placement.⁶⁰ Even though *E. faecalis* may be in the minority of a failed endodontic lesion, the vegetative abilities of this organism may allow it to proliferate on a newly placed implant surface and become a substantial component of a bacterial population.

Antibiotic premedication 1 hour prior to implant surgery may render a higher success rate.⁶¹ This may preemptively address any potential bacterial colonization. Nevertheless, there are no reports that relate antibiotic premedication to failed endodontic treatment.^{61,62}

Flushing an extraction site with an antibiotic solution may not provide effective bacterial elimination.⁶³ Although several endodontic irrigating solutions are effective endodontic

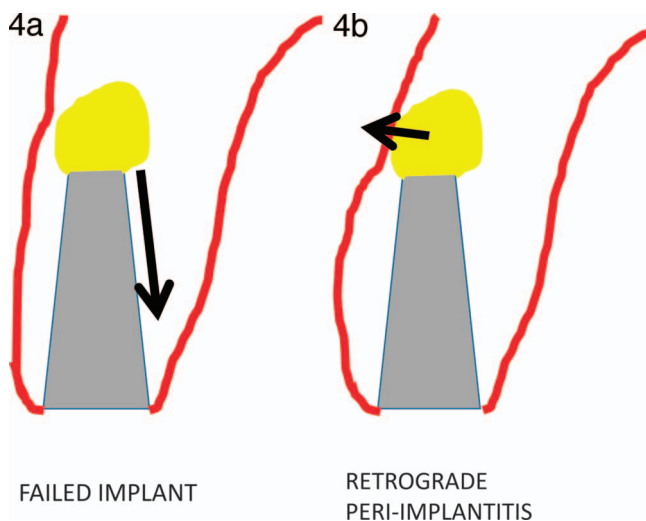


FIGURE 4. When the apical bone is thick or the apex of the implant is far from the cortical bone, bacterial colonization may advance occlusally and around the fixture, preventing osseointegration. If the apical cortex is thin or there is a fenestration, then an apical (retrograde) peri-implantitis may occur.

antimicrobials, these may not be effective in surgical sites.⁶⁴ Thus, an effective endodontic irrigation solution used to irrigate a surgical site may not give an adequate antibiotic effect to prevent a colonization of the implant surface.

There may be a different resistance to antimicrobials of *E. faecalis* in the planktonic state versus the biofilm state. Planktonic bacteria are effectively reduced by topical antimicrobials such as chlorhexidine. The biofilm state can be reduced but can rebound soon after treatment.⁶⁵

E. faecalis may induce the recruitment of polymorpholeukocytes that induce abscess formation.⁶⁵

E. faecalis is found in food that is consumed by patients. One study found that it can be as much as 30% of the isolated food. Since *E. faecalis* can be resistant to ciprofloxacin and gentamicin,⁶⁶ food would be an exogenous source for this bacteria.

E. faecalis can be found—albeit, in the minority—in treated teeth with apical periodontitis, but can be dominant in some lesions.⁶⁷ Even with accessory canals, short fills, transportation, zips, and other apical misadventures, endodontic treatment can be clinically successful. However, if there is an *E. faecalis* colonization, then these issues may be problematic for endodontic treatment success.⁶⁷

When endodontic treatment is failing, the decision must be made regarding monitoring the tooth, retreatment, or extraction.⁶⁸ Retrograde endodontic treatment may be an option, but there is a higher failure rate with this option than with orthograde treatment.⁶⁸ Endodontic candidates need to be thoroughly evaluated preoperatively for the potential for failure.^{69,70–72} *E. faecalis* appears to be a prime suspect in endodontic failures and highly suspicious in implant failures.

Postextraction debridement may be crucial to implant success.^{69,70–72} If an endodontically failed tooth is extracted and the socket is not thoroughly debrided, vegetative pathogens may remain in the site. These could then become imbedded in

the healed bone, waiting to colonize an implant. With immediate placement, debridement is also crucial. This may entail a full thickness flap to access the socket to gain a visual perspective to allow complete debridement.

Sandblasted acid-etched rough surface implants may colonize a greater biomass density with higher bacterial cell viability than would polished machined surface implants.⁷³ This makes debridement crucial.

Adjacent failing endodontic teeth may infect an implant.⁷⁴ The apical bone may contain vegetative bacteria in close proximity to or in contact with an implant. These can then colonize the implant surface.

Implants may be placed a second time in the same failed site with a high success rate. If there is a second failure, a third placement may have 100% success rate.⁷⁵

E. faecalis is most commonly associated with failed endodontic treatment and may colonize an implant surface. The abutment connection may become colonized as well. It may be necessary to disinfect the implant surface and the prosthesis and abutment to thoroughly treat the infection.⁷⁶

CONCLUSIONS

There may be an association of failed endodontic treatment and the failure of implants to osseointegrate in these sites. Incomplete debridement may be an issue. Implant failure in sites of endodontic failure may be infected by residual bacterial species vegetating in the healed osseous site. These may then colonize the subsequently placed implant surface, resulting in a failure to osseointegrate. While any number of species may vegetate and colonize the implant surface, *E. faecalis* may be a prime culprit in these failures. Alternatively, placing the implant immediately with thorough debridement of the extraction socket and antibiotic medication may not guarantee uneventful healing. The formation of vegetative forms of bacteria and subsequent implant surface colonization may occur in either circumstance. Thorough debridement is crucial, an unknown critical mass of vegetative bacteria may remain even after scrupulous debridement.

The threshold for the number of bacteria necessary for a successful colonization of an implant is unknown. Any one of various debridement techniques do not demonstrate superiority. Investigation is needed to determine a definitive debridement technique that would guarantee complete bacterial removal.

REFERENCES

- López-Martínez F, Gómez Moreno G, Olivares-Ponce P, et al. Implants failures related to endodontic treatment. An observational retrospective study. *Clin Oral Implants Res*. 2015;26:992–995.
- Peak JD. The success of endodontic treatment in general dental practice: a retrospective clinical and radiographic study. *Prim Dent Care*. 1994;1:9–13.
- Al-Ahmad A, Ameen H, Pelz K, et al. Antibiotic resistance and capacity for biofilm formation of different bacteria isolated from endodontic infections associated with root-filled teeth. *J Endod*. 2014;40:223–230.
- Ran SJ, E J, Zhu CL, He ZY, Liang JP. Effect of different stress conditions on growth and biofilm formation capability of *Enterococcus faecalis* [in Chinese]. *Zhonghua Kou Qiang Yi Xue Za Zhi*. 2013;48:529–534.

5. Yuan K, Chan YJ, Kung KC, Lee TM. Comparison of osseointegration on various implant surfaces after bacterial contamination and cleaning: a rabbit study. *Int J Oral Maxillofac Implants*. 2014;29:32–40.
6. Ricucci D, Siqueira JF Jr, Bate AL, Pitt Ford TR. Histologic investigation of root canal-treated teeth with apical periodontitis: a retrospective study from twenty-four patients. *J Endod*. 2009;35:493–502.
7. Skucaite N, Peculienė V, Vitkauskienė A, Machiulskienė V. Susceptibility of endodontic pathogens to antibiotics in patients with symptomatic apical periodontitis. *J Endod*. 2010;36:1611–1616.
8. Molander A, Reit C, Dahlen G, Kvist T. Microbiological status of root-filled teeth with apical periodontitis. *Int Endod J*. 1998;31:1–7.
9. Gomes BP, Pinheiro ET, Gadê-Neto CR, et al. Microbiological examination of infected dental root canals. *Oral Microbiol Immunol*. 2004;19:71–76.
10. Gomes BP, Jacinto RC, Pinheiro ET, et al. Molecular analysis of *Filifactor alocis*, *Tannerella forsythia*, and *Treponema denticola* associated with primary endodontic infections and failed endodontic treatment. *J Endod*. 2006;32:937–940.
11. Pinheiro ET, Gomes BP, Ferraz CC, Sousa EL, Teixeira FB, Souza-Filho FJ. Microorganisms from canals of root-filled teeth with periapical lesions. *Int Endod J*. 2003;36:1–11.
12. Siqueira JF Jr, Rôças IN. Polymerase chain reaction detection of *Propionibacterium propionicum* and *Actinomyces radidentis* in primary and persistent endodontic infections. *Oral Surg Oral Med Oral Pathol Oral Radiol Endod*. 2003;96:215–222.
13. Carr GB, Schwartz RS, Schaudinn C, Gorur A, Costerton JW. Ultrastructural examination of failed molar retreatment with secondary apical periodontitis: an examination of endodontic biofilms in an endodontic retreatment failure. *J Endod*. 2009;35:1303–1309.
14. Kalfas S, Figdor D, Sundqvist G. A new bacterial species associated with failed endodontic treatment: identification and description of *Actinomyces radidentis*. *Oral Surg Oral Med Oral Pathol Oral Radiol Endod*. 2001;92:208–214.
15. Ozbek SM, Ozbek A, Erdorgan AS. Analysis of *Enterococcus faecalis* in samples from Turkish patients with primary endodontic infections and failed endodontic treatment by real-time PCR SYBR green method. *J Appl Oral Sci*. 2009;17:370–374.
16. Pruzzo C, Tarsi R, Lleò MM, et al. In vitro adhesion to human cells by viable but nonculturable *Enterococcus faecalis*. *Curr Microbiol*. 2002;45:105–110.
17. Stuart CH, Schwartz SA, Beeson TJ, Owatz CB. *Enterococcus faecalis*: its role in root canal treatment failure and current concepts in retreatment. *J Endod*. 2006;32:93–98.
18. Wright RC. The survival patterns of selected faecal bacteria in tropical fresh waters. *Epidemiol Infect*. 1989;103:603–611.
19. Arias CA, Contreras GA, Murray BE. Management of multidrug-resistant enterococcal infections. *Clin Microbiol Infect*. 2010;16:555–562.
20. Ran SJ, Jiang W, Zhu CL, Liang JP. Exploration of the mechanisms of biofilm formation by *Enterococcus faecalis* in glucose starvation environments. *Aust Dent J*. 2015;60:143–153.
21. Love RM. *Enterococcus faecalis*—a mechanism for its role in endodontic failure. *Int Endod J*. 2001;34:399–405.
22. Kishen A, George S, Kumar R. *Enterococcus faecalis*-mediated biomineralized biofilm formation on root canal dentine in vitro. *J Biomed Mater Res A*. 2006;77:406–415.
23. Vidana R, Sullivan A, Billström H, Ahlquist M, Lund B. *Enterococcus faecalis* infection in root canals—host-derived or exogenous source? *Lett Appl Microbiol*. 2011;52:109–115.
24. Zhu X, Wang Q, Zhang C, Cheung GS, Shen Y. Prevalence, phenotype, and genotype of *Enterococcus faecalis* isolated from saliva and root canals in patients with persistent apical periodontitis. *J Endod*. 2010;36:1950–1955.
25. Baydas B, Uslu H, Yavuz I, Ceylan I, Dağsuyu IM. Effect of a chronic nail-biting habit on the oral carriage of *Enterobacteriaceae*. *Oral Microbiol Immunol*. 2007;22:1–4.
26. Bortolini MC, Ferreira dos Santos SS, Habitante SM, Rodrigues JR, Vance R, Jorge AO. Endodontic sealers: intratubular penetration and permeability to *Enterococcus faecalis*. *Indian J Dent Res*. 2010;21:40–43.
27. Dornelles-Morgental R, Guerreiro-Tanomaru JM, Faria-Júnior NB, Hungaro-Duarte MA, Kuga MC, Tanomaru-Filho M. Antibacterial efficacy of endodontic irrigating solutions and their combinations in root canals contaminated with *Enterococcus faecalis*. *Oral Surg Oral Med Oral Pathol Oral Radiol Endod*. 2011;112:396–400.
28. Mohammadi Z, Dummer PM. Properties and applications of calcium hydroxide in endodontics and dental traumatology. *Int Endod J*. 2011;44:697–730.
29. Ma Z, Wang Y, Zhu X, et al. Role of polymorphonuclear neutrophils in the clearance of *Enterococcus faecalis* derived from saliva and infected root canals. *J Endod*. 2011;37:346–352.
30. Soares JA, Roque de Carvalho MA, Cunha Santos SM, et al. Effectiveness of chemomechanical preparation with alternating use of sodiumhypochlorite and EDTA in eliminating intracanal *Enterococcus faecalis* biofilm. *J Endod*. 2010;36:894–898.
31. Tseng SK, Tsai YL, Li UM, Jeng JH. Radicular cyst with actinomycotic infection in an upper anterior tooth. *J Formos Med Assoc*. 2009;108:808–813.
32. Zhao H, Msadek T, Zapf J, Madhusudan, Hoch JA, Varughese KI. DNA complexed structure of the key transcription factor initiating development in sporulating bacteria. *Structure*. 2002;10:1041–1050.
33. Adrianopoulos A. Control of morphogenesis in the human fungal pathogen *Penicillium marneffeii*. *Int J Med Microbiol*. 2002;292:331–347.
34. Abhyankar W, Hossain AH, Djajasaputra A, et al. In pursuit of protein targets: proteomic characterization of bacterial spore outer layers. *J Proteome Res*. 2013;12:4507–4521.
35. Leggett MJ, McDonnell G, Denyer SP, Setlow P, Maillard JY. Bacterial spore structures and their protective role in biocide resistance. *J Appl Microbiol*. 2012;113:485–498.
36. Stringer SC, Webb MD, Peck MW. Lag time variability in individual spores of *Clostridium botulinum*. *Food Microbiol*. 2011;28:228–235.
37. Cinquemani C. Human pathogens, nosocomial infections, heat-sensitive textile implants, and an innovative approach to deal with them. *J Ind Microbiol Biotechnol*. 2011;38:29–37.
38. Rutala WA, Gergen MF, Weber DJ. Room decontamination with UV radiation. *Infect Control Hosp Epidemiol*. 2010;31:1025–1029.
39. Nair PN. Cholesterol as an aetiological agent in endodontic failures—a review. *Aust Endod J*. 1999;25:19–26.
40. Tehemar S, Hanes P, Sharawy M. Enhancement of osseointegration of implants placed into extraction sockets of healthy and periodontally diseased teeth by using graft material, an ePTFE membrane, or a combination. *Clin Implant Dent Relat Res*. 2003;5:193–211.
41. Nomura R, Hamada M, Nakano K, Nemoto H, Fujimoto K, Ooshima T. Repeated bacteraemia caused by *Streptococcus mutans* in a patient with Sjogren's syndrome. *J Med Microbiol*. 2007;56(Pt 7):988–992.
42. Pecora G, Andreana S, Covani U, De Leonardi D, Schifferle RE. New directions in surgical endodontics; immediate implantation into an extraction site. *J Endod*. 1996;22:135–139.
43. Cosci F, Cosci B. A 7-year retrospective study of 423 immediate implants. *Compend Contin Educ Dent*. 1997;18:940–946.
44. TenHeggelr JMAG, Slot DE, Van der Weijden. Effect of socket preservation therapies following tooth extraction in non-molar regions in humans: a systematic review. *Clin Oral Impl Res*. 2011;22:779–788.
45. Naves MM, Horbylon BZ, Gomes CF, Menezes HH, Batagliion C, Magalhães Dd. Immediate implants placed into infected sockets: a case report with 3-year follow-up. *Braz Dent J*. 2009;20:254–258.
46. Allan B, Buchanan RM, Hauta S, van den Hurk J, Wilson HL. Innate immune cocktail partially protects broilers against cellulitis and septicemia. *Avian Dis*. 2012;56:659–669.
47. van den Berg S, Laman JD, Boon L, et al. Distinctive cytokines as biomarkers predicting fatal outcome of severe *Staphylococcus aureus* bacteremia in mice. *PLoS One*. 2013;8:e59107.
48. Gollwitzer H, Dombrowski Y, Prodinge PM, et al. Antimicrobial peptides and proinflammatory cytokines in periprosthetic joint infection. *J Bone Joint Surg Am*. 2013;95:644–651.
49. Deller-Quinn M, Perinpanayagam H. Osteoblast expression of cytokines is altered on MTA surfaces. *Oral Surg Oral Med Oral Pathol Oral Radiol Endod*. 2009;108:302–307.
50. Chan HL, Wang HL, Bashutski JD, Edwards PC, Fu JH, Oh TJ. Retrograde peri-implantitis: a case report introducing an approach to its management. *J Periodontol*. 2011;82:1080–1088.
51. Ayangco L, Sheridan PJ. Development and treatment of retrograde peri-implantitis involving a site with a history of failed endodontic and apicoectomy procedures: a series of reports. *Int J Oral Maxillofac Implants*. 2001;16:412–417.
52. Zhou W, Han C, Li D, Li Y, Song Y, Zhao Y. Endodontic treatment of teeth induces retrograde peri-implantitis. *Clin Oral Implants Res*. 2009;20:1326–1332.
53. Flanagan D. Apical (retrograde) peri-implantitis: a case report of an active lesion. *J Oral Implantol*. 2002;28:92–96.
54. Martin MV, Longman LP, Hill JB, Hardy P. Acute dentoalveolar

infections: an investigation of the duration of antibiotic therapy. *Br Dent J*. 1997;183:135–137.

55. Signorette FG, Gomes BP, Montagner F, Jacinto RC. Investigation of cultivatable bacteria isolated from longstanding retreatment-resistant lesions of teeth with apical periodontitis. *J Endod*. 2013;39:1240–1244.

56. Tsesis I, Goldberger T. The dynamics of periapical lesions in endodontically treated teeth that are left without intervention: a longitudinal study. *J Endod*. 2013;39:1510–1515.

57. Rams TE, Degener JE, van Winkelhoff AJ. Antibiotic resistance in human peri-implantitis microbiota. *Clin Oral Implants Res*. 2014;25:82–90.

58. Javed F, Alghamdi AS, Ahmed A, Mikami T, Ahmed HB, Tenenbaum HC. Clinical efficacy of antibiotics in the treatment of peri-implantitis. *Int Dent J*. 2013;63:169–176.

59. Lemire P, Houde M, Segura M. Encapsulated group B Streptococcus modulates dendritic cell functions via lipid rafts and clathrin-mediated endocytosis. *Cell Microbiol*. 2012;14:1707–1719.

60. Lindeboom JA, Tjiook Y, Kroon FH. Immediate placement of implants in periapical infected sites: a prospective randomized study in 50 patients. *Oral Surg Oral Med Oral Pathol Oral Radiol Endod*. 2006;101:705–710.

61. Chrcanovic BR, Albrektsson T, Wennerberg A. Prophylactic antibiotic regimen and dental implant failure: a meta-analysis. *J Oral Rehabil*. 2014;41:941–956.

62. Chrcanovic BR, Albrektsson T, Wennerberg A. Reasons for failures of oral implants. *J Oral Rehabil*. 2014;41:443–476.

63. Chrcanovic BR, Martins MD, Wennerberg A. Immediate placement of implants into infected sites: a systematic review. *Clin Implant Dent Relat Res*. 2015;17(Suppl 1):e1–e16.

64. Ferrer-Luque CM, González-Castillo S, Ruiz-Linares M, Arias-Moliz MT, Rodríguez-Archilla A, Baca P. Antimicrobial residual effects of irrigation regimens with maleic acid in infected root canals. *J Biol Res (Thessalon)*. 2015;22:1.

65. Ma J, Tong Z, Ling J, Liu H, Wei X. The effects of sodium hypochlorite and chlorhexidine irrigants on the antibacterial activities of

alkaline media against *Enterococcus faecalis*. *Arch Oral Biol*. 2015;60:1075–1081.

66. Vidana R, Rashid M, Özenci V, Weintraub A, Lund B. The origin of endodontic *Enterococcus faecalis* explored by comparison of virulence factor patterns and antibiotic resistance to that of isolates from stool samples, blood cultures and food. *Int Endod J*. In press.

67. Antunes HS, Rôças IN, Alves FR, Siqueira JF Jr. Total and specific bacterial levels in the apical root canal system of teeth with post-treatment apical periodontitis. *J Endod*. 2015;41:1037–1042.

68. Van Nieuwenhuysen JP, Aouar M, D'Hoore W. Retreatment or radiographic monitoring in endodontics. *Int Endod J*. 1994;27:75–81.

69. Rocas IN, Siquiera JF Jr., Santos KR. Association of *Enterococcus faecalis* with different forms of periradicular diseases. *J Endod*. 2004;30:315.

70. Ricucci D, Siqueira JF Jr. Fate of the tissue in lateral canals and apical ramifications in response to pathologic conditions and treatment procedures. *J Endod*. 2010;36:1–15.

71. Qu C, Meng H, Han J. Implant periapical lesion—a review and a case report with histological evaluation. *Clin Oral Implants Res*. 2014;25:1099–1104.

72. Palmer R. Evidence for survival of implants placed into infected sites is limited. *J Evid Based Dent Pract*. 2012;12(Suppl 3):187–188.

73. Souza JCM, Tavares FP, Lima KC, Carriero AFP, Henriques B, Pereira J. Relation between dental implant joint surfaces and biofilm formation. *Dentistry*. 2015;5:296–302.

74. Yip K H-K, Mui SF, Smales RJ, Newsome PRH, Chow TW, Sham ASK. *Implant Dentistry*. 2002;11:349–355.

75. Kim YK, Park JY, Kim SG, Lee HJ. Prognosis of the implants replaced after removal of failed dental implants. *Oral Surg Oral Med Oral Radiol*. 2010;110:281–286.

76. Canullo L, Rossetti PHO, Penarrocha D. Identification of *Enterococcus faecalis* and *Pseudomonas aeruginosa* and in implants in individuals with peri-implant disease: a cross sectional study. *Int J Oral Maxillofac Implants*. 2015;30:583–606.