

# Treatment of Labial Mucosal Recession Around Maxillary Anterior Implants With Tenting Screws, Particulate Allograft, and Xenogenic Membrane: A Case Report

Le Bach, DDS, MD<sup>1,2\*</sup>

Ali Borzabadi-Farahani, DDS, MScD<sup>3,4</sup>

## INTRODUCTION

Soft-tissue recession around dental implants often results in metal exposure. While this is not, in itself, of primary significance in functional posterior jaw locations, visible mucosal recessions in maxillary anterior jaw locations can be a major esthetic problem,<sup>1</sup> especially if it results in exposure of the gray titanium metal.<sup>2,3</sup> Unfortunately, soft-tissue recession around implants have been frequently observed.<sup>4</sup> One study reported that recessions greater than 1 mm in the midfacial mucosal aspects of implants were present in 61% of the cases.<sup>5</sup> Treatment of peri-implant soft-tissue recessions can be challenging despite reports in the literature that indicate that recession up to 2 mm can be successfully grafted with a combination of coronally advanced flap and subepithelial connective tissue grafts.<sup>1,3</sup> Long-term data on the success of these grafting techniques are limited.<sup>3,6,7</sup>

A recent systematic review<sup>8</sup> reported that the combination of an apically positioned flap/ vestibuloplasty and soft-tissue augmentation using a free gingival graft, subepithelial connective tissue graft, or collagen matrix resulted in a 1.4- to 3.3-mm increase in keratinized tissue. Overall, soft-tissue connective tissue augmentation resulted in the best gains in soft-tissue volume at implant and partially edentulous sites and a combination of better papilla fill and higher marginal mucosal levels as compared with nongrafted sites around immediately placed dental implants.<sup>8</sup> Another systemic review<sup>9</sup> did not find a single acceptable randomized clinical trial in the literature to recommend the best incision designs, suturing techniques, or materials to correct or augment peri-implant soft tissues.

The treatment of bone loss and associated gingival recession around implants in the esthetic zone often require, a combination of guided bone regeneration (GBR)<sup>10</sup> and soft-tissue augmentation<sup>11,12</sup> is. When multiple implants are placed in the esthetic zone, vertical and horizontal bone augmentation of more than 2 mm from the implant platform is often

necessary to overcome the normal pattern of bone remodeling and soft-tissue recession.<sup>13</sup> The use of coronally advanced flaps and connective tissue grafts can sometimes jeopardize the esthetic appearance of the treatment site by altering the color and thickness of the transplanted tissues.<sup>14</sup>

The use of a particulate mineralized bone allograft covered with a xenogenic collagen membrane (GBR) for the correction of gingival recession has not been previously reported in the dental literature. This case report demonstrates an innovative surgical technique to restore hard tissue and increase mucosal width and keratinized gingival height around multiple maxillary implants in the esthetic zone.

## CASE REPORT

A healthy 22-year old male nonsmoker with a history of traumatic injury to his maxillary right lateral and central incisors and maxillary left central incisors was referred for treatment. The 3 fractured teeth were extracted with immediate placement of 3 external hex dental implants (Biomet 3i Dental, Palm Beach Gardens, Fla). Three years after definitive restoration, the patient presented with complaints of long maxillary crowns, visible abutment metal, thin soft-tissue biotype, and a dark shadow along the gingival sulcus (Figure 1a). Initial evaluations included a discussion to understand the patient's desires and expectations. Clinical and radiographic evaluations were conducted to assess the patient's soft-tissue health, implant position, emergence profile of the implant relative to the labial plate and adjacent teeth, gingival contour, smile line, and the shapes of the prosthetic and clinical crowns.

On the day of surgery, the patient was asked to rinse with 0.12% chlorhexidine gluconate (15 mL) prior to intravenous sedation. A crestal incision and a distal, curvilinear, vertical incision that followed the gingival margin of the distal proximal tooth were made. A full-thickness, subperiosteal "open book" flap<sup>15</sup> was elevated to the labial aspect of the implant. A wide subperiosteal reflection was made to expose the treatment area, and the papilla was reflected on the mesial side of the implant site (Figure 1b). The peri-implant soft tissue was released and advanced by scoring the periosteum so that tension-free closure could be achieved around the neck of the implant. This was done because moderate graft resorption could occur if there were an inadequate tissue seal around the implant neck or if tension-free closure was not achieved. To

<sup>1</sup> Department of Oral & Maxillofacial Surgery, The Herman Ostrow School of Dentistry of USC, Los Angeles County/USC Medical Center, Los Angeles, Calif.

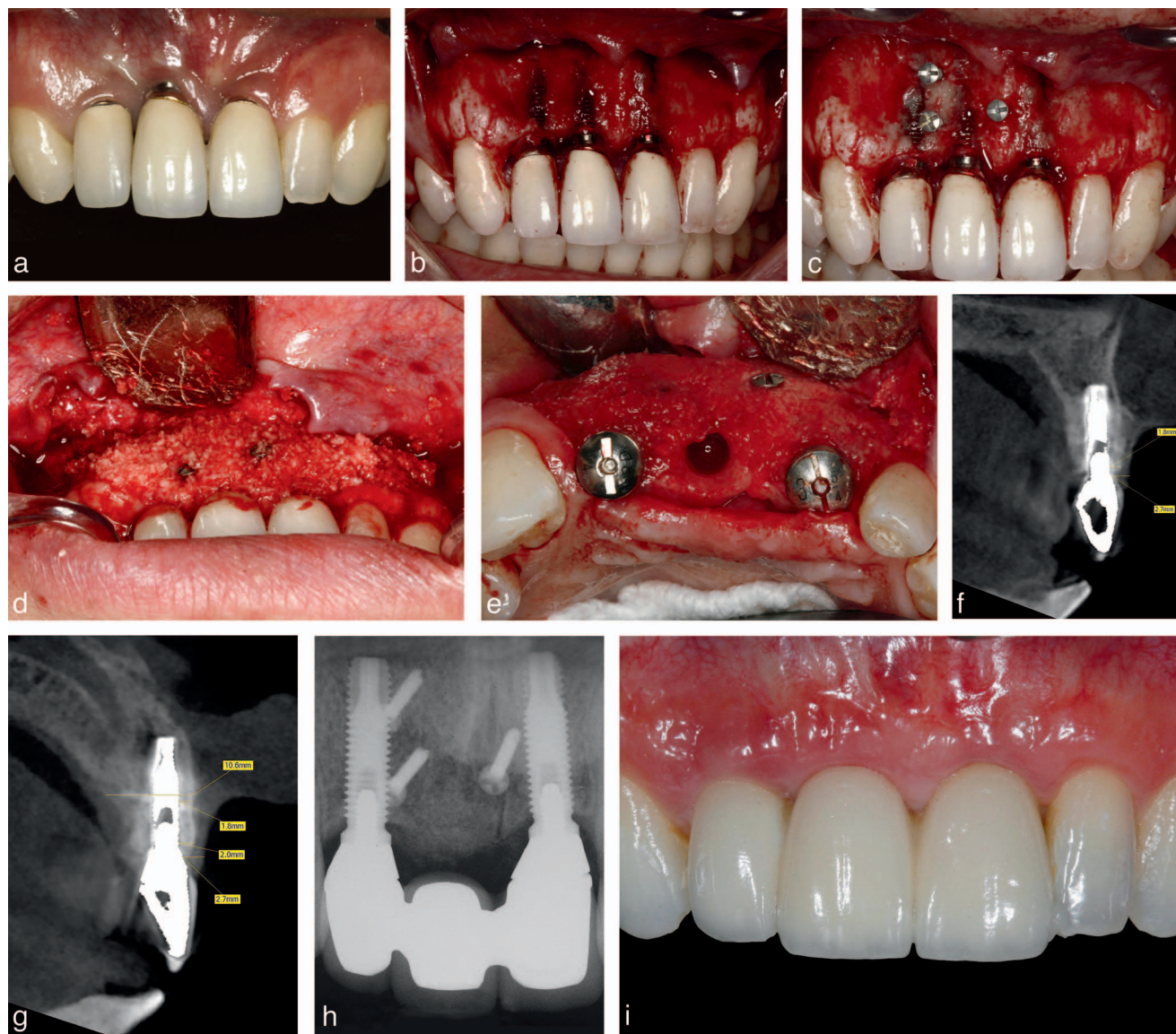
<sup>2</sup> Private practice, Whittier, Calif.

<sup>3</sup> Warwick Medical School, University of Warwick, Coventry, UK.

<sup>4</sup> Orthodontics, Department of Clinical Sciences and Translational Medicine, University of Rome Tor Vergata, Rome, Italy.

\* Corresponding author, e-mail: leb97201@yahoo.com

DOI: 10.1563/aaid-joi-D-16-00019



**FIGURE 1.** Patient with gingival recession and discoloration due to exposure of the underlying dental implant in maxillary right lateral and central incisors as well as maxillary left central incisor locations. (a) Three years after implant placement. (b) Flap elevation illustrating labial bone dehiscence and implant exposure. (c) Placement of 3 roughened titanium tenting screws placed 3–4 mm below planned gingival margin. (d) Placement of allograft material. (e) Middle implant in the maxillary right central incisor area was removed in the second surgery to create a pontic site. (f–h) Cone beam computerized tomography and periapical views at 8 years after guided bone regeneration (GBR) procedure. (i) Final restoration at 8 years after GBR procedure.

reduce intraoperative bleeding at the graft site, periosteal release was the last step before graft placement. Subperiosteal reflection revealed that the patient had bone loss confined to the labial surface of the implants. Decontamination of the implant surfaces was not performed because the patient did not exhibit signs of peri-implantitis-related infection, or purulence around the peri-implant gingival sulci.

Prior to graft placement, 3 roughened titanium tenting screws were placed 3–4 mm below the implant platforms to create a tenting effect over the graft site and help to hold the particulate material in place (Figure 1c). Mineralized bone allograft (Puros Cancellous Bone Allograft, Zimmer Biomet Dental) was packed into the defect sites and overcontoured by

approximately 20%–30% to compensate for the anticipated apical migration and partial resorption of the augmentation material during remodeling (Figure 1d). Prior to use, the allograft material was hydrated according to the manufacturer’s directions and mixed with the patient’s blood, which served as a coagulant. After graft placement, the material was covered with a resorbable xenogenic collagen membrane (CopiOs Pericardium Xenograft, Zimmer Biomet Dental), and healing abutments were connected to the implants.

The mucoperiosteal flap was approximated and sutured in place. The patient was provided with an interim prosthesis to be worn during 4 months of healing and was dismissed with postoperative instructions, antibiotics, and analgesics until the

follow-up visit 7–10 days later. After the 4-month healing period, implants were provisionally restored for 4–5 months with a screw-retained prosthesis (Figure 1f) and then definitively restored with a screw-retained restoration (Figure 1g).

The middle implant in the maxillary right central incisor area (tooth  $\neq$  11) was removed in the second surgery to create a pontic site so that only 2 implants were treated with the GBR technique (Figure 1e). Additional bone allograft (Puros Cancellous Bone Allograft, Zimmer Biomet Dental) was added around the labial surface of the alveolar ridge and covered with a cross-linked collagen membrane (Ossix Plus, OraPharma, Horsham, Pa). Cone beam computerized tomography and periapical views (Figure 1f through h) and final restoration with soft-tissue profile 8 years after the GBR procedure are shown (Figure 1i). There were no complications or adverse events during surgery or postoperative healing. The preoperative crestal bone thickness for both implants increased to 1.8 mm and 2 mm, respectively, approximately 8 years after treatment. Significant increases in soft-tissue thickness, keratinized tissue width, and gingival height were also unexpectedly achieved and maintained through 8 years of follow-up.

#### DISCUSSION

This clinical case letter reports on unexpected improvements in peri-implant soft-tissue dimensions after GBR procedures to correct labial dehiscences around implants in the maxillary anterior jaw. Peri-implant bone loss can result in soft-tissue resorption followed by plaque attachment at or near the implant-abutment interface. This, in turn, can trigger soft-tissue inflammation with additional bone loss and gingival recession.<sup>16–20</sup> It has been reported that gingival margin levels may be affected by the thickness of the gingival tissues and that a thin tissue biotype may favor apical displacement of the soft-tissue margin.<sup>21</sup> To maintain gingival health, maintaining an adequate width (~2 mm) of keratinized gingiva around dental implants has been suggested<sup>16,19,21</sup>; however, this has been disputed.<sup>22</sup> A correlation has been reported between the presence of keratinized tissue and plaque levels and the incidence of mucositis.<sup>20</sup> It has been suggested that sites with minimal keratinized tissue might be prone to a lower incidence of periodontal pocket formation.<sup>20,23</sup>

In the anterior maxilla, as labial bone thickness resorbs, there is a corresponding loss in labial soft-tissue thickness around the implant.<sup>24</sup> Moderate recession can make thin, pink gingival tissues appear dark due to the presence of the underlying metal abutment and implant, and further bone loss can cause unsightly metal exposure above the gingival margin. In general, implants carry a higher risk of soft-tissue complications when placed in thin-tissue biotypes or with labial inclinations when the labial plate thickness is <2 mm.<sup>24,25</sup> Use of an opaque abutment, such as zirconia, has been reported to produce the least amount of gingival color change when gingival thickness was <2 mm, whereas any abutment material resulted in satisfactory esthetics when gingival tissue thickness was >2 mm.<sup>24,26</sup>

The goal of the GBR procedures in the present case was to treat the facial bone defects as well as restore the esthetic gingival margin. The efficacy of allografts and GBR surgical

protocols in repairing alveolar defects is documented in the dental literature.<sup>27–29</sup> While some allogenic<sup>30,31</sup> and xenogenic<sup>32</sup> tissues have demonstrated efficacy in soft-tissue augmentation, the use of pericardium membranes for soft-tissue augmentation is not well documented. In the present case report, use of the pericardium membrane in combination with a mineralized bone allograft resulted in gain in keratinized tissue width and gingival height.

While the goal of the GBR procedure in this case, using mineralized allograft and 1.5-mm titanium screws,<sup>33</sup> was to treat bone defects, improvements were coincidentally observed not only in the soft-tissue dehiscence but also in the keratinized tissue width and soft-tissue thickness. Although there are no reports of a GBR procedure resulting in clinical increases in both of the latter soft-tissue dimensions, a limited number of retrospective studies<sup>24,34</sup> have reported an increase in soft-tissue thickness around dental implants after increasing the thickness of the facial bone through GBR. The use of a pericardium membrane placed over the particulate graft in the present clinical case was essentially a collagen matrix similar to a connective tissue graft, contributing to the thickness of the overlying tissue.<sup>35</sup> Aggressive scoring may also result in scar tissue formation that augments the soft-tissue profile. The present technique is not ideal for restoring the gingival margins for poorly positioned implants or when there is significant thread exposure. For example, implants placed outside of the alveolar housing or with significant labial inclination associated with labial bone loss should be excluded.

Zucchelli et al<sup>36</sup> reported on a surgical-prosthetic treatment for implants with buccal soft-tissue dehiscence defects in the esthetic zone. The technique involved removing the crown, shortening the abutment, and then treating the dehiscence defect with a coronally advanced flap and connective tissue graft.<sup>36</sup> After 1 year, mean soft-tissue dehiscence coverage was 96.3%, with complete coverage in 75% of the treatment sites.<sup>36</sup> While patients were satisfied during short-term follow-up, the ability to camouflage a bony defect with or without exposed implant threads is highly limited without the support of the underlying bone, which is the main cause of soft-tissue recession.<sup>24,37,38</sup> In addition to soft-tissue recession, marginal bone loss has been associated with increased peri-implant stress concentrations in the crestal bone region. Over time, elevated stress concentrations can trigger additional bone loss and further soft-tissue recession.<sup>39</sup> If left untreated, increased stresses can result in screw loosening, metal fatigue, and component fracture over time.<sup>39,40</sup> Implants placed in the anterior maxillary jaw with thin buccal plates are highly susceptible to the adverse effects of marginal bone loss.<sup>39,40</sup>

In summary, the use of solvent-dehydrated, mineralized bone allograft and xenogenic pericardium membrane effectively increased alveolar hard and soft-tissue dimensions in the esthetic zone of the anterior maxilla. Restoring the missing buccal bone decreased the risk of developing peri-implantitis from bacterial biofilm attachment to the exposed implant-abutment crevice and roughened implant surface. Second, the soft-tissue thickness was increased, which made the restored tissues more resistant to future recession and mask the underlying titanium components.<sup>31,40,41</sup> Third, GBR also unexpectedly increased the width of keratinized tissue, which has

also been reported to help provide a peri-implant soft-tissue seal against bacterial invasion, in addition to providing resistance against recession.<sup>33</sup> While increases in soft-tissue thickness and keratinized tissue width have been reported after placement of connective tissue and free gingival grafts,<sup>33</sup> this phenomenon has not been previously reported after GBR procedures around dental implants.

The value of individual clinical case reports is that their anecdotal data can provide preliminary evidence for developing new hypotheses that lead to larger randomized clinical trials,<sup>42</sup> which are needed to determine if the present approach will effectively serve as an alternative for soft-tissue augmentation in instances in which tissue thickening is needed. The retrospective nature of this case report and the fact that it presents the lowest level of clinical evidence as well as the lack of the information in a form of a control group or information on the long-term outcome of the procedure in a form of case series with wider age are some of the limitations of the present report. The multiple methods that were used is another limitation of this case report, making highlighting the contribution of each of the methods difficult (ie, the tenting screw or pericardium membrane). Ideally, a prospective clinical trial with a control group is needed to assess whether this technique is in fact an improvement in handling gingival recession for implants placed in the esthetic zone as compared with standard surgical methods.

#### ABBREVIATION

GBR: guided bone regeneration

#### REFERENCES

- Fickl S. Peri-implant mucosal recession: clinical significance and therapeutic opportunities. *Quintessence Int.* 2015;46:671–676.
- Kohal RJ, Att W, Bachle M, Butz F. Ceramic abutments and ceramic oral implants: an update. *Periodontology 2000.* 2008;4:224–243.
- Rocuzzo M, Gaudio L, Bunino M, Dalmasso P. Surgical treatment of buccal soft tissue recessions around single implants: 1-year results from a prospective pilot study. *Clin Oral Implants Res.* 2014;25:641–646.
- Hidaka T, Ueno D. Mucosal dehiscence coverage for dental implant using spirit pouch technique: a two-stage approach. *J Periodontol Implant Sci.* 2012;42:105–109.
- Oates TW, West J, Jones J, Kaiser D, Cochran DL. Long-term changes in soft tissue height on the facial surface of dental implants. *Implant Dent.* 2002;11:272–279.
- Burkhardt R, Joss A, Lang NP. Soft tissue dehiscence coverage around endosseous implants: a prospective cohort study. *Clin Oral Implants Res.* 2008;19:451–457.
- Zucchelli G, Mazzotti C, Mounssif I, Mele M, Stefanini M, Montebugnoli L. A novel surgical-prosthetic approach for soft tissue dehiscence coverage around single implant. *Clin Oral Implants Res.* 2013;24:957–962.
- Thoma DS, Buranawat B, Hämmerle CHF, Held U, Jung RE. Efficacy of soft tissue augmentation around dental implants and in partially edentulous areas: a systematic review. *J Clin Periodontol.* 2014;41(suppl 15):S77–S79.
- Esposito M, Maghaireh H, Grusovin MG, Ziouas I, Worthington HV. Interventions for replacing missing teeth: management of soft tissues for dental implants. *Cochrane Database Syst Rev.* 2012;CD006697.
- Schwarz F, Sahm N, Becker J. Impact of the outcome of guided bone regeneration in dehiscence-type defects on the long-term stability of peri-implant health: clinical observations at 4 years. *Clin Oral Implants Res.* 2012;23:191–196.

- Tinti C, Parma-Benfenati S. Minimally invasive technique for gingival augmentation around dental implants. *Int J Periodontics Restorative Dent.* 2012;32:187–193.
- Schlee M, Esposito M. Human dermis graft versus autogenous connective tissue grafts for thickening soft tissue and covering multiple gingival recessions: 6-month results from a preference clinical trial. *Eur J Oral Implantol.* 2011;4:119–125.
- Ishikawa T, Salama M, Funato A, Kitajima H, Moroi H, Salama H, Garber D. Three-dimensional bone and soft tissue requirements for optimizing esthetic results in compromised cases with multiple implants. *Int J Prosthodontics Restorative Dent.* 2010;30:503–511.
- Zucchelli G, Mounssif I, Mazzotti C, et al. Does the dimension of the graft influence patient morbidity and root coverage outcomes? A randomized controlled clinical trial. *J Clin Periodontol.* 2014;41:708–716.
- Le BT, Borzabadi-Farahani A. Simultaneous implant placement and bone grafting with particulate mineralized allograft in sites with buccal wall defects, a three-year follow-up and review of literature. *J Craniomaxillofac Surg.* 2014;42:552–559.
- Hof M, Pommer B, Ambros H, Jesch P, Vogl S, Zechner W. Does timing of implant placement affect implant therapy in the esthetic zone? A clinical, radiological, aesthetic, and patient-based evaluation. *Clin Implant Dent Relat Res.* 2015;17:1188–1199.
- Cairo F, Pagliary U, Nieri M. Soft tissue management at implant sites. *J Clin Periodontol.* 2008;35(suppl 8):163–167.
- Beagle JR. Developing keratinized mucosa around nonsubmerged dental implants. Part II: the use of non-vascularized soft-tissue grafts. *Periodontol Practice Today.* 2005;2:259–266.
- Kosinski T. No attached keratinized gingiva? A clinical solution for the clinician. *Dent Today.* 2013;32:132–135.
- Chung DM, Oh TJ, Shotwell JL, Misch CE, Wang HL. Significance of keratinized mucosa in maintenance of dental implants with different surfaces. *J Periodontol.* 2006;77:1410–1420.
- Lang NP, Löe H. The relationship between the width of keratinized gingiva and gingival health. *J Periodontol.* 1972;43:623–627.
- Bengazi F, Wennström JL, Lekholm U. Recession of the soft tissue margin at oral implants: a 2-year longitudinal prospective study. *Clin Oral Implants Res.* 1996;7:303–310.
- Bouri A Jr, Bissada N, Al-Zahrani MS, Faddoul F, Nouneh I. Width of keratinized gingiva and the health status of the supporting tissues around dental implants. *Int J Oral Maxillofac Implants.* 2008;23:323–326.
- Le B, Borzabadi-Farahani A. Labial bone thickness in area of anterior maxillary implants associated with crestal labial soft tissue thickness. *Implant Dent.* 2012;21:406–410.
- Evans CS, Chen ST. Esthetic outcomes of immediate implant placements. *Clin Oral Implants Res.* 2008;19:73–80.
- Jung RE, Sailer I, Hämmerle CH, et al. In vitro color changes of soft tissues caused by restorative materials. *Int J Periodontics Restorative Dent.* 2007;27:251–257.
- Le B, Burstein J, Sedghizadeh PP. Cortical tenting grafting technique in the severely atrophic alveolar ridge for implant site development. *Implant Dent.* 2008;17:40–50.
- Le B, Burstein J. Esthetic grafting for small volume hard and soft tissue contour defects for implant site development. *Implant Dent.* 2008;17:136–141.
- Retzepi M, Donos N. Guided bone regeneration: biological principle and therapeutic applications. *Clin Oral Implants Res.* 2010;21:567–576.
- Schlee M, Esposito M. Human dermis graft versus autogenous connective tissue grafts for thickening soft tissue and covering multiple gingival recessions: 6-month results from a preference clinical trial. *Eur J Oral Implantol.* 2011;4:121–127.
- Barker TS, Cueva MA, Rivera-Hidalgo F, et al. A comparative study of root coverage using two different acellular dermal matrix products. *J Periodontol.* 2010;81:1596–1603.
- Froum SJ, Khouly I, Tarnow DP, et al. The use of a xenogeneic collagen matrix at the time of implant placement to increase the volume of buccal soft tissue. *Int J Periodontics Restorative Dent.* 2015;35:179–189.
- Le B, Rohrer MD, Prasad HS. Screw “tent-pole” grafting technique for reconstruction of large vertical alveolar ridge defects using human mineralized allograft for implant site preparation. *J Oral Maxillofac Surg.* 2010;68:428–435.
- Kheur MG, Kantharia NR, Kheur SM, Acharya A, Le B, Sethi T. Three-dimensional evaluation of alveolar bone and soft tissue dimensions of maxillary central incisors for immediate implant placement; a cone-beam computed tomography assisted analysis. *Implant Dent.* 2015;24:407–415.

35. Mandelaris GA, Lu M, Rosenfeld AL. The use of a xenogeneic collagen matrix as an interpositional soft-tissue graft to enhance peri-implant soft-tissue outcomes: a clinical case report and histologic analysis. *Clin Adv Periodontics*. 2011;1:193–198.
36. Zucchelli G, Mazzotti C, Mounssif I, Mele M, Stefanini M, Montebugnoli L. A novel surgical-prosthetic approach for soft tissue dehiscence coverage around single implant. *Clin Oral Implants Res*. 2013;25:957–964.
37. Fu J-H, Lee A, Wang H-L. Influence of tissue biotype on implant esthetics. *Int J Oral Maxillofac Implants*. 2011;26:499–508.
38. Borzabadi-Farahani A. A review of the oral health-related evidence that supports the orthodontic treatment need indices. *Prog Orthod*. 2012;13:314–325.
39. Spray JR, Black CG, Morris HF, Ochi S. The influence of bone thickness on facial marginal bone response: stage 1 placement through stage 2 uncovering. *Ann Periodontol*. 2000;5:119–128.
40. Ormianer Z, Palti A, Demiralp B, Heller G, Lewinstein I, Khayat PG. Implant-supported first molar restorations: correlation of finite element analysis with clinical outcomes. *Int J Oral Maxillofac Implants*. 2012;27:e1–e12.
41. Kao RT, Fagan MC, Conte GJ. Thick vs thin gingival biotypes: a key determinant in treatment planning for dental implant. *J Calif Dent Assoc*. 2008;36:193–198.
42. Elamin MB, Montori VM. The hierarchy of evidence: from unsystematic clinical observations to systematic reviews. In: Burneo JC, Demaerschalk BM, Jenkins ME, eds. *Neurology: An Evidence-Based Approach*. New York, NY: Springer; 2012:368–391.