

Soft Liner/Clip Attachment for Bar-Retained Implant Overdentures: A Technical Note

Moustafa Abdou ELSyad, BDS, MSc, PhD

INTRODUCTION

According to the McGill Consensus Statement,¹ mandibular 2-implant-retained overdentures should become the standard of care for the edentulous patient. Compared with conventional dentures, such overdentures provide increased retention and stability, improved patient satisfaction, better masticatory function, and lower rates of residual ridge resorption.²⁻⁴ The implant-retained overdentures can be connected to various attachments including bars and clips, ball anchors, magnets and telescopic crowns.⁵ The advantages of bar attachments compared with solitary anchors are splinting, better stress distribution between the implants,⁶ better retention, and less clinical complications.⁷ However, bar attachments have several drawbacks. Free spaces around the bar attachments should be made in the fitting surface of bar-retained overdentures in order to enhance free rotation of the prosthesis during function. These unobturated spaces around the bars and abutments enhance soft tissue proliferation,⁸ plaque accumulation, and microbial colonization that may induce peri-implant tissue inflammation and bone loss.⁹ Moreover, oral hygiene procedures are complicated especially around abutments and underneath the bar.¹⁰

The use of soft liners as permanent attachments over the bars of implant-retained overdentures have been reported previously.^{8,11,12} These liners have several merits including minimal wear, space obturation around the bar, patient comfort, absorption of masticatory loads, and distribution of these loads to the implants and the residual ridge.^{8,11}

When used as an attachment for bar-retained implant overdentures, the soft liners are associated with improved peri-implant tissue health,¹² equal patient satisfaction, lower prosthodontic complications, reduced costs, minimal soft tissue complications,¹³ reduced maxillary bone resorption, decreased incidence of maxillary flabby ridges, and fewer relining times of maxillary denture¹⁴ compared with plastic clips. However, plastic clips provide more denture stability, ease of prosthesis handling, ease of biting/chewing food, and less relining incidence compared with soft liners.¹³

This article describes a new method for fabrication of a soft liner-clip attachment for bar-retained implant overdentures. This technique combines the advantages of plastic clips and soft liners when used as a female housing for the bar joint of 2-implant-retained overdentures.

Department of Removable Prosthodontics, Faculty of Dentistry, Mansoura University, Eldakahlia, Egypt
Corresponding author, e-mail: m_syad@mans.edu.eg
DOI: 10.1563/aid-joi-D-16-00022

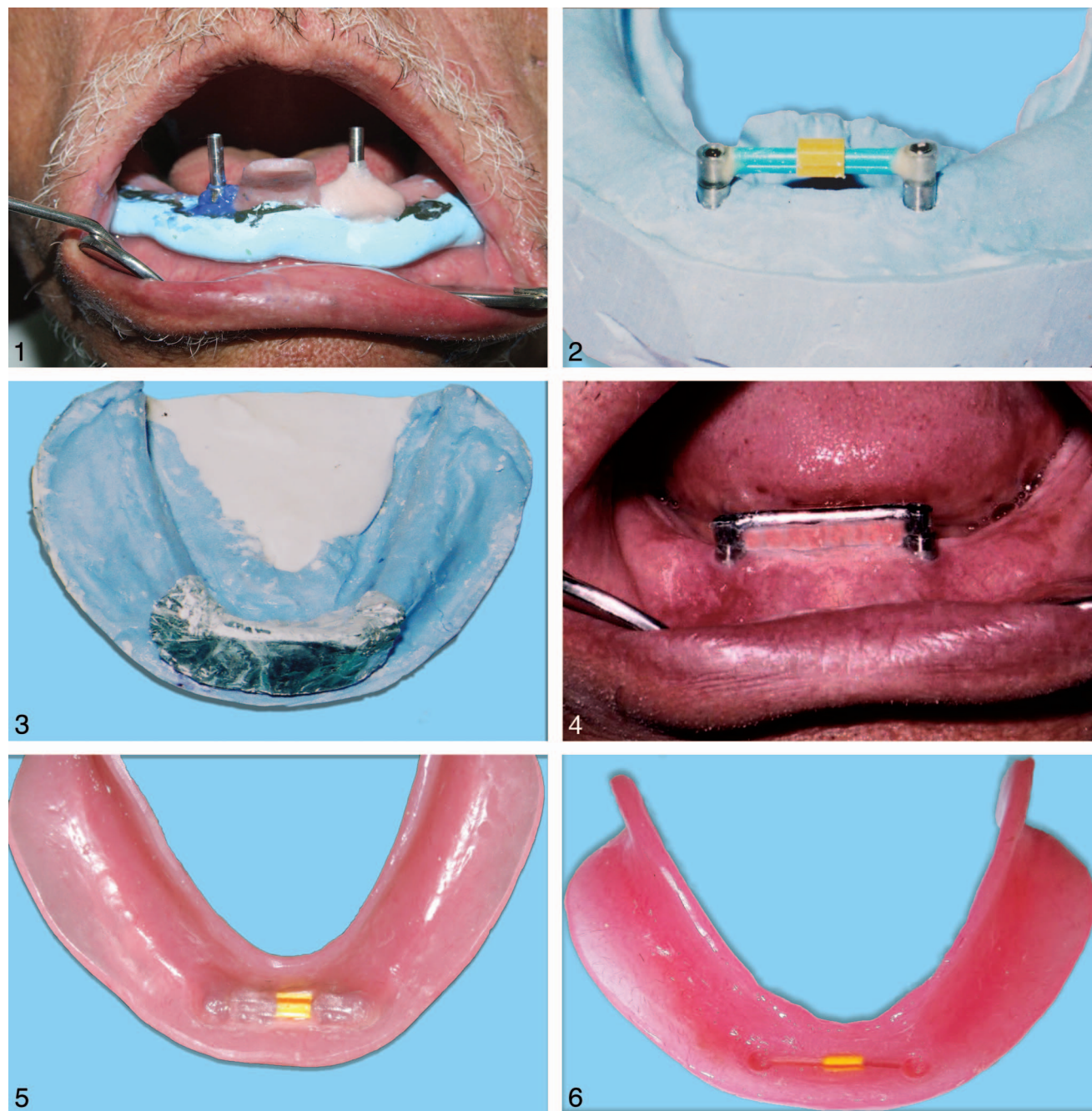
MATERIALS AND METHODS

For a completely edentulous patient, 2 implants (Zimmer Inc, TSV, Carlsbad, Calif) were inserted bilaterally in the cuspid regions of the mandible. The implants were exposed, and the healing abutments were placed after 3 months. Preliminary impressions were made with irreversible hydrocolloid material (Lascod S.p.A., Firenze, Tuscany, Italy). The impressions were poured to obtain diagnostic casts. Mandibular custom-made trays were fabricated with holes over the implant regions using autopolymerizing acrylic resin (Super acryl, Sofa Dental, Praha, Czechoslovakia). The borders of the maxillary and mandibular trays were molded using a green stick modeling plastic impression compound (Kerr Mfg.Co., Romulus, Mich), and the final impressions were completed using a zinc oxide eugenol paste (ZnOE, Cavex, Holland and IRM, Dentsply, Haarlem, Netherlands). The mandibular impression tray was retrieved from the patient's mouth, and the excess impression material was excised from the holes with a sharp scalpel.

The long transfer impression copings were screwed into the implants using the long fixation screws. The tray was carefully replaced in the mouth, and a light-bodied elastomeric material (Speedex, Coltene, Cuyahoga Falls, Ohio) was injected around the impression transfers while posterior portions of the tray were held under finger pressure. The impression copings were picked up to the tray with self-cure acrylic resin,¹⁵ which also covers the light-body elastomeric material (Figure 1). The implant analogues were attached to the transfer copings, and the impression was poured with extra-hard type IV stone (Polidental, São Paulo, SP, Brazil).

The bar abutments were screwed to the implant analogues on the master cast. The plastic pattern of a resilient bar (OT bar multiuse, RHEIN 83, Bologna, Italy) was luted to the plastic portions of bar abutments allowing a space of 2 mm between the bar and the ridge for oral hygiene purposes (Figure 2). The bar assembly was invested and casted with cobalt-chromium alloy and then finished and polished. The bar was tried to verify its passive fit. Maxillary and mandibular record bases were constructed and used to record the maxilla-mandibular relationship. The casts were mounted to the articulator (HANAU Wide, Whip Mix Corporation, Louisville, Ky) in centric relation. Functional and esthetic teeth arrangement were completed.

Two-millimeter-thick aluminum foil sheets¹⁶ were applied over and around the bar to provide a room for the soft liner (Figure 3), and denture processing was completed in the usual manner. The bar assembly was tightened to the bar abutments intraorally using a 20-Ncm torque. The space between the bar and the ridge was blocked out with wax intraorally (Figure 4).



FIGURES 1–6. **FIGURE 1.** Pick up of the transfer copings to the polished surface of the tray. **FIGURE 2.** The plastic pattern of the resilient bar luted to the plastic portions of bar abutments. **FIGURE 3.** Aluminum foil sheets applied over and around the bar. **FIGURE 4.** The space between the bar and the ridge blocked out with wax intraorally. **FIGURE 5.** Pick up of the plastic clip to the fitting surface of mandibular denture. **FIGURE 6.** Relining the mandibular denture with the soft liner.

The plastic clip (OT bar multiuse, RHEIN 83, Italy) was placed on the middle of the bar. The plastic clip was picked up to the mandibular denture with autopolymerizing acrylic resin (Super acryl, Sofa Dental) while the patient occlude in centric relation (Figure 5). The mandibular denture was removed, and the excess acrylic resin around the clip was trimmed.

The tissue surface of the mandibular denture around the bar was painted with soft liner adhesive. The autopolymerized silicone softliner (Softliner, Promedica GmbH, Neumünster,

Germany) was mixed and loaded in the space created by the aluminum foil sheets. The mandibular denture was relined with the soft liner around the bar using a closed mouth technique (Figure 6). The mandibular overdenture was removed, and the excess soft lining material was trimmed with a sharp scalpel. The base and the catalyst of the glaze were mixed, and the mixture was painted to the soft liner to seal the surface roughness. The dentures were delivered to the patient with emphasis on adequate oral hygiene procedures.

DISCUSSION

The presented technique combines the advantages of plastic clips and soft liners when used as a female housing for bar joint implant-retained mandibular overdentures. The advantages of plastic clips include resiliency, ease of replacement if retention diminished, cost effectiveness, and reduced bar wear compared with metal clips. The advantages of soft liners include greater range of overdenture movement, energy absorption, and equal force distribution to the implants and edentulous ridge.^{8,11} The soft liner encircles the bar and completely obturates the spaces around it.⁸ The contact between these liners and the bar decreases plaque and bacterial adhesion that may cause peri-implant mucosal inflammation. The continuous cleaning of the bar and abutments by soft liners during insertion and removal of the denture prevents plaque accumulation around the bar regardless of oral hygiene practice.¹² When these liners are placed around the implants, they engage the abutment and ridge undercuts, resulting in additional retention of the prosthesis.¹⁷ Furthermore, the presence of the soft liners compensates for the acrylic resin contraction that may occur during denture processing. This prevents the implants and the bar from coming into direct contact with the acrylic resin, and minimizes implant overloading.¹⁷ Finally, Shaygan et al¹⁸ found greater retention with soft liners than clip attachments of implant-retained overdentures. Therefore, these liners can also be used to compensate for clip wear.

The use of additional silicone soft liners reduces candida adhesion,¹⁹ maintains long-term viscoelastic properties^{2,0} and decreases water sorption and solubility²¹ compared with acrylic resin soft liners. However, it should be mentioned that long-term stability (adhesion) between the soft liner and acrylic resin requires additional research.

CONCLUSIONS

A new attachment for implant retained mandibular overdentures with bar connectors has been described. This attachment combines the advantages of plastic clips and soft liners when used as a female housing for bar joint of 2-implant retained overdentures. This attachment is simple, easy to fabricate, and eliminates several problems associated with conventional bar and clip attachments.

ACKNOWLEDGMENT

The author thanks Dr Dina Magdy Elkerdawy for the artwork preparation.

REFERENCES

1. Feine JS, Carlsson GE, Awad MA, et al. The McGill Consensus

Statement on Overdentures. Montreal, Quebec, Canada. May 24-25, 2002. *Int J Prosthodont.* 2002;15:413-414.

2. MacEntee MI, Walton JN, Glick N. A clinical trial of patient satisfaction and prosthodontic needs with ball and bar attachments for implant-retained complete overdentures: three-year results. *J Prosthet Dent.* 2005;93:28-37.

3. Meijer HJ, Raghoobar GM, Van 't Hof MA. Comparison of implant-retained mandibular overdentures and conventional complete dentures: a 10-year prospective study of clinical aspects and patient satisfaction. *Int J Oral Maxillofac Implants.* 2003;18:879-885.

4. Naert I, Alsaadi G, van Steenberghe D, Quirynen M. A 10-year randomized clinical trial on the influence of splinted and unsplinted oral implants retaining mandibular overdentures: peri-implant outcome. *Int J Oral Maxillofac Implants.* 2004;19:695-702.

5. Bernhart G, Koob A, Schmitter M, Gabbert O, Stober T, Rammelsberg P. Clinical success of implant-supported and tooth-implant-supported double crown-retained dentures. *Clin Oral Investig.* 2012;16:1031-1037.

6. Naert I, Quirynen M, Hooghe M, van Steenberghe D. A comparative prospective study of splinted and unsplinted Branemark implants in mandibular overdenture therapy: a preliminary report. *J Prosthet Dent.* 1994;71:486-492.

7. Naert I, Gizani S, Vuylsteke M, Van Steenberghe D. A 5-year prospective randomized clinical trial on the influence of splinted and unsplinted oral implants retaining a mandibular overdenture: prosthetic aspects and patient satisfaction. *J Oral Rehabil* 1999;26:195-202.

8. Adrian ED, Krantz WA, Ivanhoe JR. The use of processed silicone to retain the implant-supported tissue-borne overdenture. *J Prosthet Dent.* 1992;67:219-922.

9. Lachmann S, Kimmerle-Muller E, Gehring K, et al. A comparison of implant-supported, bar- or ball-retained mandibular overdentures: a retrospective clinical, microbiologic, and immunologic study of 10 edentulous patients attending a recall visit. *Int J Prosthodont.* 2007;20:37-42.

10. Reitz PV, Weiner MG, Levin B. An overdenture survey: second report. *J Prosthet Dent.* 1980;43:457-462.

11. Kiat-Amnuay S, Khan Z, Gettleman L. Overdenture retention of four resilient liners over an implant bar. *J Prosthet Dent.* 1999;81:568-573.

12. Elsyad MA, Shoukoui AH. Resilient liner vs. clip attachment effect on peri-implant tissues of bar-implant-retained mandibular overdenture: a 1-year clinical and radiographical study. *Clin Oral Implants Res.* 2010;21:473-480.

13. Elsyad MA. Prosthetic aspects and patient satisfaction with resilient liner and clip attachments for bar- and implant-retained mandibular overdentures: a 3-year randomized clinical study. *Int J Prosthodont.* 2012; 25:148-156.

14. Elsyad MA, Ashmawy TM, Faramawy AG. The influence of resilient liner and clip attachments for bar-implant-retained mandibular overdentures on opposing maxillary ridge. A 5-year randomised clinical trial. *J Oral Rehabil.* 2014;41:69-77.

15. Gregory-Head B, LaBarre E. Two-step pick-up impression procedure for implant-retained overdentures. *J Prosthet Dent.* 1999;82:615-616.

16. Wright PS. Soft lining materials: their status and prospects. *J Dent.* 1976;4:247-256.

17. Cain JR, Mitchell DL. Soft liner-retained, implant-supported overdenture: a technical note. *Int J Oral Maxillofac Implants.* 1998;13:857-860.

18. Shaygan F, Khan Z, Gettleman L. Retention and longevity of resilient denture liners in implant overdentures. *J Dental Res.* 1993;72:272.

19. Waters MG, Williams DW, Jagger RG, Lewis MA. Adherence of *Candida albicans* to experimental denture soft lining materials. *J Prosthet Dent.* 1997;77:306-312.

20. Murata H, Haberham RC, Hamada T, Taguchi N. Setting and stress relaxation behavior of resilient denture liners. *J Prosthet Dent.* 1998;80:714-722.

21. El-Hadary A, Drummond JL. Comparative study of water sorption, solubility, and tensile bond strength of two soft lining materials. *J Prosthet Dent.* 2000;83:356-361.