

Comparative Evaluation of Bioactive Glass (Putty) and Platelet Rich Fibrin in Treating Furcation Defects

Shriparna Biswas, MDS¹
 Savita Sambashivaiah, MDS¹
 Rithesh Kulal, MDS¹
 Shivaprasad Bilichodmath, MDS¹
 Gregori M. Kurtzman, DDS^{2*}

The aim of this study was to compare a second-generation bioactive glass putty biomaterial against platelet rich fibrin in treating grade II furcation defects. Subjects were 15 systemically healthy patients (10 males and 5 females, ages 20–50 with a mean age of 38.33) with 20 mandibular molar class II furcation defects according to Glickman's classification. The 20 mandibular molar furcation defects were randomly allocated as follows: Group I, 10 furcation defects were treated using bioactive glass (NovaBone) bone graft putty material; Group II, 10 furcation defects were treated using platelet rich fibrin (PRF). Customized acrylic stents were fabricated on study casts and trimmed to the height contour of the teeth to serve as a fixed reference point for measurements. The following measurements were collected: gingival index, plaque index, vertical probing depth (from gingival margin to base of the pocket), clinical attachment level (CEJ to the base of the pocket), and horizontal probing depth of furcation involvement (using stent). Results showed that both groups had improvement in gingival index (GI) and plaque index (PI) at the recall intervals. There was an overall reduction in both vertical and horizontal probing depth in both groups; however, the Putty group (Group I) showed consistently more vertical probing depth reduction than the PRF group (Group II) at the end of third month (P -value = 0.0004), sixth month (P -value = 0.00001), and ninth month (P -value = 0.0004). Our conclusion was that use of bioactive glass osteostimulative biomaterial yields superior clinical results, including increased pocket depth reduction of class II furcation defects as compared to an autologous platelet concentrate. The clinical significance of our findings include the ease of use and superior biologic performance of second-generation putty bioglass biomaterials in furcation defects.

Key Words: periodontal regeneration, periodontitis, bioactive glass, putty

INTRODUCTION

Periodontal Regenerative aims to regenerate the attachment apparatus: bone, cementum, and periodontal ligament. Clinical outcomes defining successful regenerative therapy include reduction in probing depth, gain in clinical attachment level, and radiographic evidence of bone fill.¹ Management of furcation presents one of the major challenges in periodontal treatment. Teeth with furcation involvement undergo more extensive, rapid clinical attachment loss and are lost with greater frequency than single-rooted teeth.²

A wide range of graft materials have been applied and evaluated clinically, including allografts, xenografts, and synthetic/semi-synthetic materials.² Platelet rich fibrin (PRF) is an autologous biomaterial containing leukocytes, platelets, and a wide range of key healing proteins within a dense fibrin matrix. PRF holds promise as a regenerative material as it releases high amounts of growth factors (TGF β 1, PDGF-AB, VEGF) and matrix glycoproteins. Thus it may enhance proliferation of different

cell types, including fibroblasts, osteoblasts, adipocytes, and keratinocytes.³

Alloplastic biomaterials are biocompatible inorganic synthetic bone grafting materials; types include nonporous and porous hydroxyapatite, beta tricalcium phosphate, polymethylmethacrylate, hydroxyethylmethacrylate polymers, and bioactive glasses. The outcome of alloplastic bone grafting materials is dependent primarily on their chemical composition, structure, and physical properties.^{4,5} Recently, putty formulations of bioactive glass with glycerin and polyethylene glycol as an additive have received significant attention due to the combination of their osteostimulative and osteoconductive properties with superior handling characteristics and ease of use in grafting osseous defects.^{5,6} This putty form of bioactive glass enhances the handling characteristics of the graft.^{5–7} It is a premixed composite of bioactive calcium phosphosilicate particulate and a synthetic, absorbable binder. The bioactive particulate is composed solely of elements that exist naturally in native bone (Ca, P, Na, Si, O).⁷

MATERIALS AND METHODS

The present study was conducted in the Department of Periodontology, Rajarajeswari Dental College and Hospital, Bangalore, India, and the study design was approved by the

¹ Department of Periodontology, Rajarajeswari Dental College and Hospital, Karnataka, India.

² Private practice, Silver Spring, Md.

* Corresponding author, e-mail: drimplants@aol.com

DOI: 10.1563/aaid-joi-D-16-00023

TABLE 1

Comparison of group I and group II with respect to gingival index (GI) and plaque index (PI) scores at baseline, 3-month, 6-month, and 9-month time intervals†

	GI				PI			
	Baseline	3 Months	6 Months	9 Months	Baseline	3 Months	6 Months	9 Months
Group I (NovaBone)	1.37 ± 0.27	1.22 ± 0.23	1.03 ± 0.21	0.86 ± 0.12	1.46 ± 0.17	1.24 ± 0.13	1.000 ± 0.09	0.830 ± 0.11
Group II (PRF)	1.37 ± 0.27	1.25 ± 0.20	1.00 ± 0.19	0.84 ± 0.10	1.46 ± 0.17	1.26 ± 0.14	0.95 ± 0.12	0.68 ± 0.08
P-value	1.0000	0.6173	0.8468	0.7482	1.0000	0.8467	0.2978	0.0049*

*P < .05.

†PRF indicates platelet rich fibrin.

Ethical Committee of Rajarajeswari Dental College and Hospital. Fifteen systemically healthy patients were selected for the study (10 males, 5 females, ages 20–50 years with a mean age of 38.33) with 20 mandibular molar class II furcation defects, according to Glickman’s classification.

The inclusion criteria for the study was presence of Glickman’s grade II furcation defects in mandibular molars, with a radiolucency in the furcation area, a probing depth (PD) ≥5 mm and horizontal PD ≥3 mm. The patients were in good systemic health and had not undergone any periodontal surgery in the areas to be treated within the prior 12 months. The participants had with no known allergy to materials/drugs used or prescribed in this study.

We excluded patients who were smokers, used alcohol, on any medications taken within the prior 6 months that could alter the periodontal status, and pregnant or lactating mothers.

The 20 mandibular molar furcation defects that were selected were randomly allotted to one of the 2 groups:

- Group I: 10 furcation defects were treated using bioactive glass (NovaBone) bone graft putty material.
- Group II: 10 furcation defects were treated using platelet rich fibrin (PRF).

Informed consent was procured from each patient, and each was scheduled for surgery following an initial phase of therapy, including oral hygiene instructions and scaling/root planing. Occlusal adjustments were performed whenever necessary.

Clinical measurements

Customized acrylic stents were fabricated on study casts and trimmed to the height of contour of the teeth, to serve as a

fixed reference point to take measurements. All measurements in this study were performed using a UNC-15 periodontal probe and a graduated Naber’s probe. All measurements were rounded off to the nearest millimeter, and clinical measurements were performed by a single examiner to avoid interexaminer variation.

The following clinical parameters were recorded at baseline, 3, 6, and 9 months postsurgery:

- Gingival index (Loe & Silness, 1963).
- Plaque index (Silness & Loe, 1964).

Soft tissue parameters:

- Vertical probing depth (from gingival margin to base of the pocket).
- Clinical attachment level (CEJ to the base of the pocket).
- Gingival margin position (using stent).

Hard tissue parameters: horizontal probing depth of furcation involvement (using stent).

Surgical protocol

The patient rinsed with 0.2% chlorhexidine digluconate mouth rinse for 30 seconds prior to surgery. Local anesthesia was obtained using 2% xylocaine. Sulcular incisions were made on the buccal and lingual. A full thickness mucoperiosteal flap was raised to provide access to the defect and the surrounding alveolar bone. Debridement of granulation tissue from the osseous defect and furcation with ultrasonic, hand scaling, and root planing of all the exposed root surfaces was performed. Furcation defects were thoroughly scaled/root planed with hand instruments and ultrasonic scalers. Following removal of granulation tissue, the surgical area was irrigated with normal

TABLE 2

Comparison of group I and group II with respect to vertical probing depth and horizontal probing depth at baseline, 3-month, 6-month, and 9-month time intervals†

	Vertical Probing Depth (mm)				Horizontal Probing Depth (mm)			
	Baseline	3 Months	6 Months	9 Months	Baseline	3 Months	6 Months	9 Months
Group I (NovaBone)	7.40 ± 0.70	6.30 ± 0.67	5.30 ± 0.48	4.30 ± 0.48	4.00 ± 0.67	3.40 ± 0.52	2.80 ± 0.42	1.90 ± 0.57
Group II (PRF)	6.90 ± 0.74	5.10 ± 0.57	3.20 ± 0.63	3.20 ± 0.63	3.90 ± 0.74	3.20 ± 0.42	2.40 ± 0.52	1.60 ± 0.70
P-value	0.1373	0.0004*	0.00001*	0.0004*	0.7541	0.3553	0.0739	0.3061

*P < .05.

†PRF indicates platelet rich fibrin.

TABLE 3

Comparison of group I and group II with respect to gingival margin position and clinical attachment level at baseline, 3-month, 6-month, and 9-month time intervals†

	Gingival Position From Reference Point (mm)				Clinical Attachment Levels			
	Baseline	3 Months	6 Months	9 Months	Baseline	3 Months	6 Months	9 Months
Group I (NovaBone)	4.50 ± 0.53	4.20 ± 0.42	4.30 ± 0.48	4.50 ± 0.53	6.60 ± 0.97	5.60 ± 0.97	4.50 ± 0.85	3.70 ± 0.67
Group II (PRF)	4.50 ± 0.53	4.10 ± 0.32	3.90 ± 0.32	3.50 ± 0.53	6.20 ± 0.63	4.10 ± 0.57	2.50 ± 0.53	2.50 ± 0.53
P-value	1.0000	0.5416	0.0448*	0.0021*	0.3246	0.0013*	0.0001*	0.0013*

* $P < .05$.

†PRF indicates platelet rich fibrin.

saline and carefully inspected for any remaining granulation tissue or deposits; reinstrumentation was performed if required. The defects were filled with PRF at the control sites.

At the experimental site, the defects were filled with bone graft material. The required quantity of bioactive graft material was transferred from syringe and delivered into the defects. In both cases, small increments of graft material were added and properly condensed until the defect was completely filled. Flaps were repositioned and secured in place using 3-0 nonabsorbable silk in an interrupted pattern. Surgical sites were protected with a non-eugenol periodontal dressing (Coe-Pak, GC America, Alsip, Ill). All patients were prescribed systemic Amoxicillin 500 mg for 3 days, thrice daily, along with ibuprofen tablets. Postoperative instructions were given, and patients were instructed to report back 24 hours after surgery and again after 10 days.

At 10 days postsurgery the sutures were removed. The patients were evaluated clinically and radiographically at 3-, 6-, and 9-month intervals. The customized acrylic stent was placed on each defect site. Using UNC-15 graduated periodontal probe and Naber's probe, measurements of attachment gain, pocket depth, and furcation depth were retaken, similar to the presurgical measurements.

Statistical analysis

Clinical parameters were recorded at baseline and at 9 months postsurgery, and suitable statistical analyses were performed to compare the parameters. Intergroup comparisons of all the clinical parameters between Group I and Group II (except for bone density changes) were made using Mann-Whitney U test, and the intragroup comparison of clinical parameters was performed using the Wilcoxon matched pair test. The

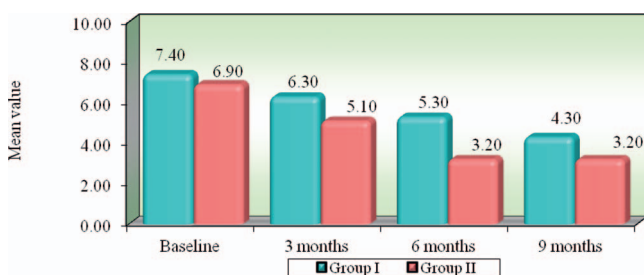


FIGURE 1. Comparison of Group I and Group II with respect to vertical probing depth (mm) scores at baseline, 3-month, 6-month, and 9-month time intervals.

intergroup comparison of the bone density changes was analyzed using Student's t -test.

RESULTS

Both treatments showed improvement in gingival index (GI) and plaque index (PI) at the recall intervals, and the PI scores at the 9-month interval of Group II (NovaBone) showed better reduction than that of Group I (PRF). There was an overall reduction in both vertical and horizontal probing depth in both groups; however, vertical probing depth reduction in Group II showed better statistically significant results than did Group I at the end of 3 months ($P = 0.0004$), 6 months ($P = 0.00001$), and 9 months ($P = 0.0004$). Reduction in horizontal probing depth intergroup showed no statistically significant difference. However, the intergroup showed statistically significant improvement in the gingival margin position and improvement in clinical attachment in Group II when compared to Group I. Radiographically, the bioactive glass putty group showed better improvement in bone fill over the sites treated with PRF with statistically significant differences at 6- and 9-month intervals (Tables 1 through 3, Figures 1 through 4).

DISCUSSION

In the present study, 20 grade II mandibular furcation defect patients were included and randomly allotted into 2 groups of 10 defects each, treated with either PRF (Group I) or bioactive glass NovaBone Putty (Group II) as a graft material. The PI and GI scores showed a statistically significant reduction in both groups at 9 months postoperatively.

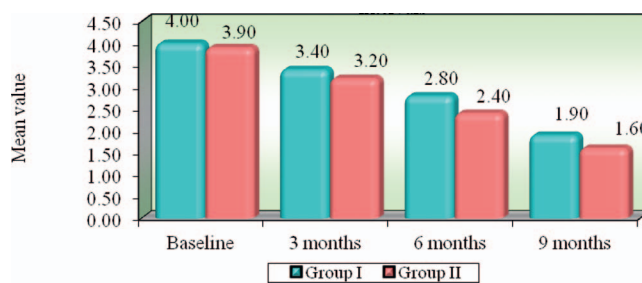


FIGURE 2. Comparison of Group I and Group II with respect to horizontal probing depth (mm) scores at baseline, 3 months, 6 months, and 9 months.

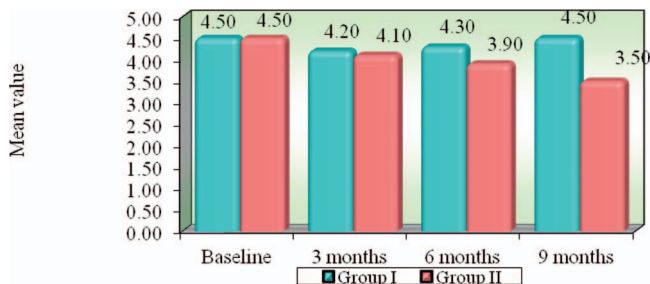


FIGURE 3. Comparison of Group I and Group II with respect to gingival position from reference point (mm) scores at baseline, 3-month, 6-month, and 9-month time intervals.

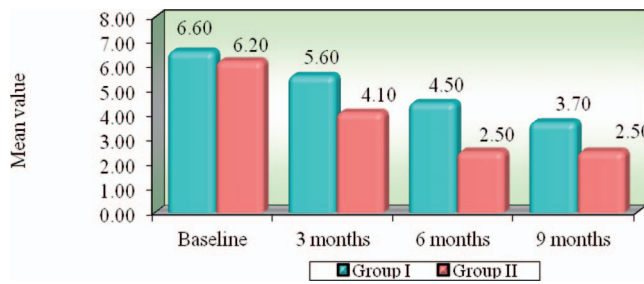


FIGURE 4. Comparison of Group I and Group II with respect to clinical attachment levels at baseline, 3-month, 6-month, and 9-month time intervals.

The present study showed improvement in horizontal probing depth at all time intervals in both groups that was statistically significant when compared to the baseline values. Although the intergroup difference was not statistically significant, the mean values of Group II (NovaBone) were better than Group I (PRF). This improvement was in accordance to Froum et al, who had compared the repair response of bioactive glass synthetic bone graft particles and open debridement in the treatment of human periodontal osseous defects, which included both intrabony and furcation defects. The authors concluded that defect fill in the bifurcation area demonstrated a significant difference with better results in the test group after 9 months of follow-up. They suggested that grade II furcations show a more favorable osseous response when treated with the bioactive glass particles.⁸

There was a gain in clinical attachment level (CAL) in both groups; when compared to Group I, Group II (NovaBone) showed statistically significant improvement at all time intervals ($P = 0.0013$, $P = 0.0001$, $P = 0.0013$, at 3, 6, and 9 months from baseline, respectively). Previous studies like that of Humagain et al found a gain in CAL (2.90 mm), and change in gingival recession (0.30 mm) was not significant in the furcation defects treated with bioactive glass. Mean recession observed in the past studies with the use of bone grafts in class II furcation defects ranged from 0.2 mm to 1.7 mm.⁹

Increase in the density (grayscale unit) at the defect sites was evident in both groups and was statistically significant at all respective time intervals. The intergroup comparison showed better gain in bone density in Group II (NovaBone) when compared to Group I (PRF) with statistically significant difference at 6 months ($P = 0.0448^*$) and 9 months ($P = 0.0021$). This is similar to results reported by El-Haddad et al that showed a mean gray level gain in the density of grade II furcation defects that were 28 and 30 scales for Group I (treated by bioactive glass) and Group II (treated using autogenous bone graft particles), respectively.¹⁰ However, this finding was in contrast to a case report by Shruthi et al in which the furcation area treated with PRF showed a slightly improved radiographic bone fill in comparison to the area treated with bioactive glass.¹¹

Healing of the defects in the present study was uneventful in both the groups. There was an overall improvement in both soft and hard tissue parameters in all the treated furcation defects.

Calcium phosphosilicate materials belong to the class of

bioactive glasses and have been reported to release ions, activate osteoblast gene expression, and enhance osteoblast proliferation. These properties have been reported in cases with the use of PRF as well. Osteostimulation results in new bone formation within and adjacent to the grafted site. Wang et al reported that modification of particulate form into a putty-like consistency during use showed a clear handling advantage for surgical operation as compared with particulates, making placement easier.¹²

Considering these properties of bioactive glass particles—along with previous evidence supporting the osteostimulative properties of bioactive glass^{5,13,14}—the present study evaluated the efficacy of the putty form of bioactive glass (NovaBone Putty) in comparison to that of PRF, in treatment of grade II furcation defects. Both graft materials were equally effective as a regenerative material in the nine-month follow-up. NovaBone Putty showed certain advantages over PRF, such as better handling properties and abundant availability. Additionally, being a “bottled” product, issues with retrieval of the material noted with PRF (blood drawing and centrifuging) are eliminated while providing similar clinical results with regard to graft development.

CONCLUSION

Within the limits of the study, it can be concluded that both groups showed significant improvement in all the clinical parameters by the end of the study. Bioactive glass putty was well tolerated by the gingival tissue and had better handling properties than PRF; the bioactive glass putty also eliminated the more complicated methods needed to create material for the graft in the clinical setting associated with PRF. Further studies with a larger sample size are required to clarify the beneficial effects of bioactive glass putty in treating various periodontal defects.

ABBREVIATIONS

- CAL: clinical attachment level
- GI: gingival index
- PD: probing depth
- PI: plaque index
- PRF: platelet rich fibrin

REFERENCES

1. Reynolds MA, Aichelmann-Reidy ME, Branch-Mays GL. Regeneration of periodontal tissue: bone replacement grafts. *Dent Clin N Am.* 2010;54:55–71.
2. Garrett S. Periodontal regeneration around natural teeth. *Ann Periodontol.* 1996;1:621–666.
3. Corso MD, Toffler M, Dohan DM. Use of an autologous leukocyte and platelet rich fibrin (L-PRF) membrane in post avulsion sites: an overview of Choukroun's PRF. *J Implant Adv Clin Dent.* 2010;1:27–35.
4. Reynolds M, Reidy MA. Regeneration of periodontal tissue: bone replacement grafts. *Dent Clin N Am.* 2010;54:55–71.
5. Kotsakis GA, Salama M, Chrepa V, Hinrichs J, Gaillard P. A randomized, blinded, controlled clinical study of particulate anorganic bovine bone mineral and calcium phosphosilicate putty bone substitutes for alveolar ridge preservation. *Int J Oral Maxillofac Implants.* 2014;29:141–151.
6. Konstantinides J, Kumar T, Kher U, Stanitsas P, Hinrichs JE, Kotsakis GA. Clinical results of implant placement in resorbed ridges using simultaneous guided bone regeneration: a multi-center case series. *Clin Oral Investig.* 2015;19:553–559.
7. Kotsakis GA, Joachim F, Saroff SA, Mahesh L, Prasad H, Rohrer M. Histomorphometric evaluation of a calcium-phosphosilicate bone substitute in extraction sockets. *Int J Periodontics Restorative Dent.* 2014;34:233–239.
8. Froum S, Weinberg M, Tarnow D. Comparison of bioactive glass synthetic bone graft particles and open debridement in the treatment of human periodontal defects. a clinical study. *J Periodontol.* 1998;69:698–709.
9. Humagain M, Nayak D, Uppoor A. A clinical evaluation of bioactive glass particulate in the treatment of mandibular class II furcation defects. *Braz J Oral Sci.* 2007;6:1450–1456.
10. El-Haddad SA, El Razzak MY, Saudi HI, El Ghorab NM. Evaluation of bioactive glass and autogenous bone in the treatment of grade II furcation involvement: a randomized controlled trial. *Journal of Interdisciplinary Dentistry.* 2014;4:13–23.
11. Shruthi S, Gujjari S, Gaekwad S, Shah M. The potential use of platelet rich fibrin versus an alloplast in the regeneration of intrabony defect and furcation involvement—a case report. *International Journal of Basic and Applied Medical Sciences.* 2013;3:205–209.
12. Wang Z, Lu B, Chen L, Chang J. Evaluation of an osteostimulative putty in the sheep spine. *J Mater Sci Mater Med.* 2011;22:185–191.
13. Ioannou A, Kotsakis GA, Kumar T, Hinrichs JE, Romanos G. Evaluation of the bone regeneration potential of bioactive glass in implant site development surgeries: a systematic review. *Clin Oral Investig.* 2015;19:181–191.
14. Mahesh L, Venkataraman N, Shukla S, Prasad H, Kotsakis GA. Ridge preservation with the socket-plug technique utilizing an alloplastic putty bone substitute or a particulate xenograft: a histological pilot study. *J Oral Implantol.* 2015;41:178–183.