

# Management and Restoration of an Implant With Irreversibly Damaged Internal Threads: A Clinical Report

Mohammad Hossein Dashti, DMD\*  
Shatha Abdulrahman Alshali, DDS  
Michael J. Haddad

This report describes a method to restore an implant with irreversibly damaged internal threads. The remaining fractured post from the previous restoration was removed using a combination of an impression coping and an end-cutting bur. An elastomeric impression of the internal surface of the damaged implant, as well as the position of the adjacent implant, was made for fabrication of a new cast post and core and an implant supported 2-unit ceramometal splinted prosthesis.

**Key Words:** fractured post, implant-supported prosthesis, damaged implant

## INTRODUCTION

When the internal threads of an implant are damaged to the extent that the abutment screw cannot engage and provide the optimum clamping force for the abutment and the prosthesis retention, restoration of that implant becomes challenging, if not impossible.<sup>1,2</sup> The internal threads of an implant can be damaged as a result of the introduction of a rotary instrument into the area in an attempt to retrieve a cross-threaded or otherwise damaged abutment screw. The internal surfaces of an implant can be further damaged through future attempts to remove any cemented abutments or posts, if deemed necessary. In such instances, one of the available solutions is to replace the abutment and its screw with a cast post and core.<sup>3</sup>

Difficult access to the internal surfaces and the complex geometries of the connection modules of implants make their accurate reproduction questionable.<sup>4,5</sup> In this clinical report, the management and restoration of an implant with irreversibly damaged internal threads is described.

## CLINICAL REPORT

The patient was a 62-year-old white woman with a noncontributory medical history. She presented with multiple missing maxillary posterior teeth, which had been replaced by implant-supported fixed prostheses. Her chief complaint was a dislodged implant-supported crown replacing her maxillary right first bicuspid.

The supporting implant was a 4 mm × 13 mm internal connection (Certain, Biomet 3i, Warsaw, Ind) with a history of irreversible damage to its internal threads. It had been

subsequently restored with a cemented cast post and core and a crown.

A periapical radiograph revealed a fractured post inside the implant. The treatment plan consisted of removal of the fractured post, and restoration of the damaged implant with a new cast post and core and definitive implant-supported cement-retained ceramometal prosthesis. The 2 adjacent implant-supported crowns would be splint to achieve better stress distribution.

Use of the manufacturer's screw removal kit (Certain ISRT 10, Biomet 3i) was rendered impractical because access to the implant had been impeded by the soft tissue and the adjacent natural tooth, alloy hardness, and retention mode of the post. The use of an ultrasonic device (Cavitron, Dentsply, York, Pa) was not effective in dislodging the fractured post.

## Removal of the fractured post

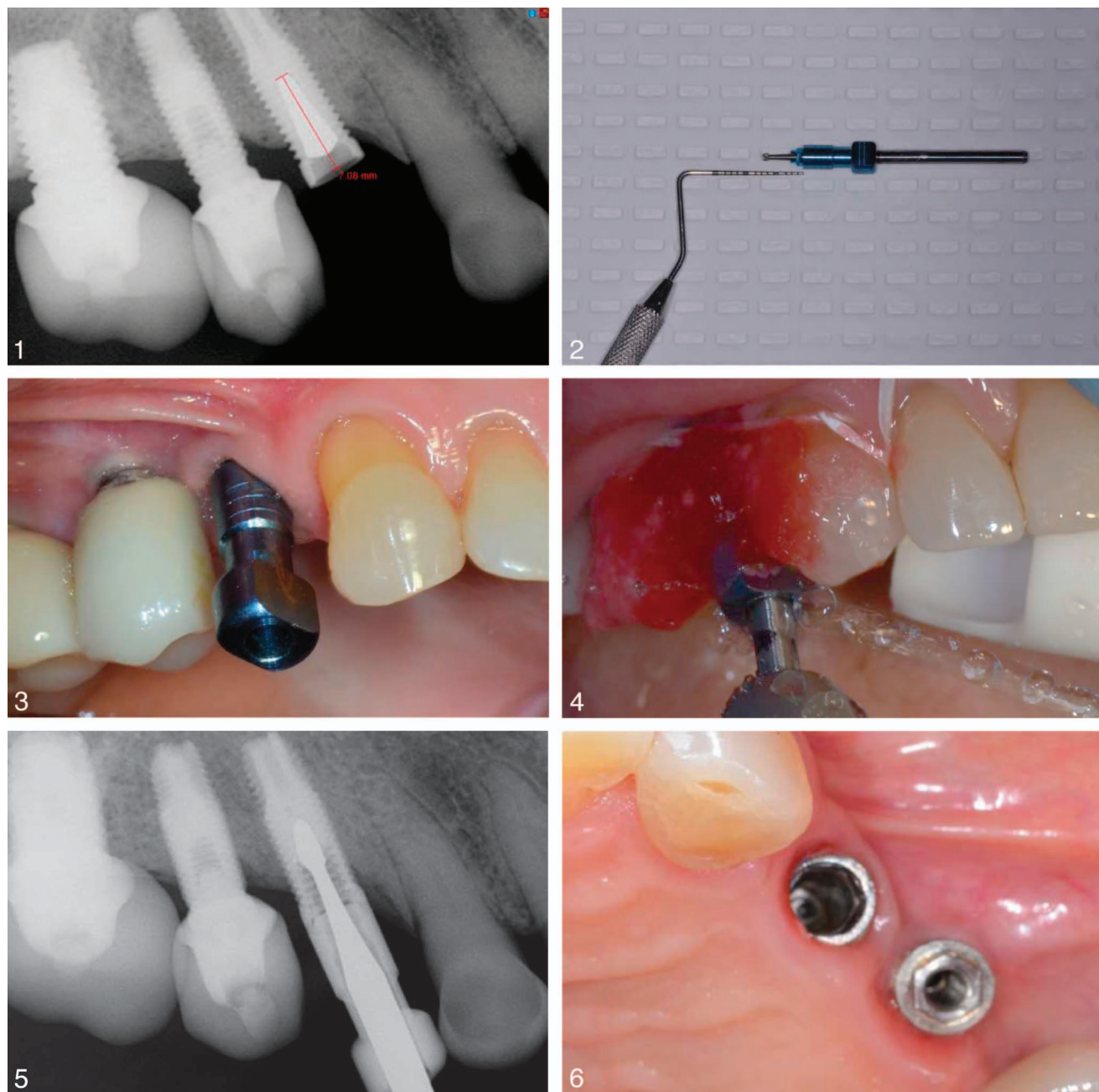
The distance between the implant platform and the tip of the fractured post was measured on the periapical radiograph (Fig. 1). An end-cutting straight bur (Brasseler USA, Savannah, Ga) was passed through an open-tray impression coping (Biomet 3i) to the length corresponding to the above measurement using a periodontal probe. The shank of the bur was marked with an indelible marker to indicate the required drilling depth (Fig. 2). The impression coping was secured to the adjacent clinical crowns using acrylic resin (Pattern Resin, GC Inc, Tokyo, Japan; Figures 3 and 4).

The bur was passed through the screw hole of the impression coping, and the post was gently drilled out until the predetermined depth was reached. A steady stream of water was sprayed by the assistant throughout the drilling process to cool the bur and the implant (Figure 5). Caution was exercised to avoid any deviation of the bur by ensuring the stability of the assembly and by radiographic verifications (Figure 6).

Henry M. Goldman School of Dental Medicine, Boston University, Boston, Mass.

\* Corresponding author, e-mail: mhdashti@bu.edu

DOI: 10.1563/aaid-joi-D-16-00045

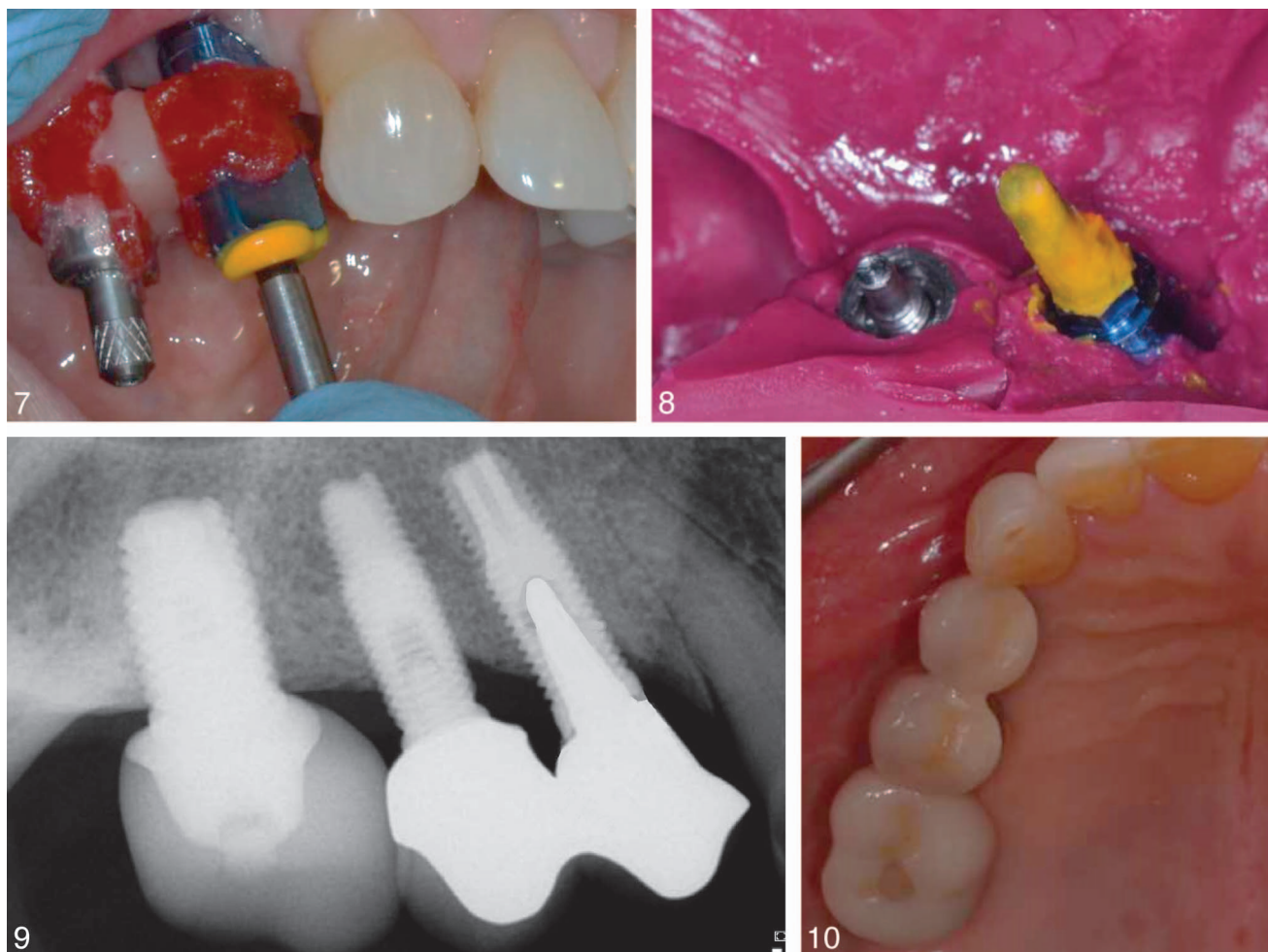

**FIGURES 1–6.** **FIGURE 1.** Periapical radiograph showing measurement of fractured post inside implant. **FIGURE 2.** Calibration of end-cutting bur to depth shown in Figure 1. **FIGURE 3.** Impression coping in place. **FIGURE 4.** Clinical view of fractured post removal. Black mark on bur shank shows penetration limit. **FIGURE 5.** Radiographic view of fractured piece removal. **FIGURE 6.** Clinical view after post removal showing 2 adjacent implants.

**Impression procedure**

Using an implant analogue (Biomet 3i) to simulate the actual implant, a prefabricated post drill (ParaPost Plus, Coltene/Whaledent, Altstätten, Switzerland) was selected to match its internal diameter. An impression coping was tightened to the adjacent implant by its corresponding screw; the impression coping of the damaged implant could not receive a screw, so it was connected to the damaged

implant by acrylic resin. The connection was separated and then reconnected with light-cured composite resin (Premise Flowable, Kerr, Orange, Calif) to neutralize the polymerization shrinkage.<sup>6,7</sup> Low-viscosity addition reaction polyvinyl siloxane (PVS) impression material (Aquadent, Dentsply) was injected into the impression coping by a narrow syringe tip. The post drill was immediately pressed into the coping, further guiding the material toward the implant (Figure 7).



**FIGURES 7–10.** **FIGURE 7.** Clinical view showing low-viscosity polyvinyl siloxane material inside impression coping. **FIGURE 8.** Completed impression. **FIGURE 9.** Periapical radiograph of completed prosthesis. **FIGURE 10.** Clinical view of completed prosthesis on right.

An open-tray impression was then made with a medium-viscosity PVS material (Figure 8).

#### **Laboratory procedures**

Nickel-chromium alloy (Biobond2, Dentsply) was used for the cast post and core because of its high modulus of elasticity. Metal copings were fabricated for both crowns, leaving a 0.3-mm gap between them to make a soldering index at the time of intraoral try in.<sup>8</sup>

#### **Prosthesis insertion**

The cast post and core was cemented with a resin cement (Panavia SA, Kuraray, New York, NY); the metal copings were tried in individually and joined by acrylic resin. The framework was verified in the mouth after soldering, and a pickup impression was made. After the porcelain application, the final restoration was clinically and radiographically evaluated, glazed, and cemented with a temporary cement (Temp Bond, Kerr). The patient expressed her satisfaction at the time of cementation of the prosthesis and at the follow-up appointments (Figures 9 and 10).

#### **DISCUSSION**

Clinical management and restoration of a damaged implant and a dislodged crown were presented. The described treatment was selected because the patient was not willing to replace the damaged implant to avoid additional surgical procedures, increased treatment time, and added cost. An alternative treatment option would have consisted of submerging the damaged implant and using a cantilever pontic for the first bicuspid. However, the potential biomechanical disadvantages of a cantilever pontic and the need for including the distal implant to fabricate a 3-unit fixed prosthesis made this option less desirable. Nevertheless, it can be considered a viable alternative in the future, if the present restoration fails.

In the post removal procedure, the passive fit of the bur within the impression coping was important for its smooth rotation. To the authors' knowledge, most impression copings in the market meet this requirement, albeit the need for minor adjustments. Unstable orientation of the rotary instrument within the confines of the internal threads may lead to further damage, and even perforation, of the implant body. For a safer

drilling process, it is recommended to use the manufacturer's screw removal kit whenever possible.

**SUMMARY**

A clinical case of a patient with a fractured cast post inside an implant with irreversibly damaged internal threads was reported. Removal of the fractured post, impression procedures from the internal aspect of the damaged implant, and fabrication of a new restoration were described.

**ABBREVIATION**

PVS: polyvinyl siloxane

**ACKNOWLEDGMENT**

The authors wish to thank the personnel at Advanced Dental Technologies (ADT).

**REFERENCES**

1. Walia MS, Arora S, Luthra R, Walia PK. Removal of fractured dental implant screw using a new technique: a case report. *J Oral Implantol*. 2012; 38:747-750.
2. Gooty JR, Palakuru SK, Guntakaka PR, Nera M. Noninvasive method for retrieval of broken dental implant abutment screw. *Contemp Clin Dent*. 2014;5:264-267.
3. Froum SJ. *Dental Implant Complications: Etiology, Prevention and Treatment*. 2nd ed. Hoboken, NJ: Wiley-Blackwell; 2015.
4. Jivarj S, Chee W. Treatment planning of implants in posterior quadrants. *Br Dent J*. 2006;201:13-23.
5. Van Staden RC, Guan H, Loo YC, Johnson LW, Nell N. Comparative analysis of internal and external hex crown connection systems: a finite element study. *J Biomed Sci Eng*. 2008;1:10-14.
6. Rajagopal P, Chitre V, Aras MA. A comparison of the accuracy of patterns processed from an inlay casting wax, an auto-polymerized resin and a light-cured resin pattern material. *Indian J Dent Res*. 2012;23:152-156.
7. Gibbs SB, Versluis A, Tantbirojn D, Ahuja S. Comparison of polymerization shrinkage of pattern resins. *J Prosthet Dent*. 2014;4:293-298.
8. Shillingburg HT, Sather DA, Wilson EL, et al. *Fundamentals of Fixed Prosthodontics*. 4th ed. Chicago, Ill: Quintessence; 2012.