

Quantitation of Mandibular Symphysis Bone as Source of Bone Grafting: Description in Class I and Class III Skeletal Conditions

Humberto Velásquez, DDS¹
 Sergio Olate, DDS, MS, PhD^{2,3*}
 César Díaz, DDS⁴
 Pablo Navarro, MS⁵
 Eduardo Borie, DDS, MS, PhD⁵
 Márcio de Moraes, DDS, MS, PhD⁶

The aim of this study was to quantify the cortical and cancellous bone in the mandibular symphysis and relate it to the teeth and to the skeletal class. A descriptive study was conducted using cone beam computerized tomography (CBCT). Class I and class III subjects were included, defined according to dental occlusion and cephalogram results. Linear measurements were taken on the CBCT of the mandibular canines, lateral incisors, and central incisors, where the analysis was related to the axial and apical axes considering the bone in relation to the dental area. With previous definitions, an observer took 2 measurements of the height of the mandibular symphysis, cortical bone of the buccal and lower region, and thickness of cancellous bone at different levels; the correlation coefficient between the first and second measurement was 0.99 and presented $P = .001$. The results were analyzed with analysis of variance and Tukey's honest significant difference test, with $P < .05$ being statistically significant. The symphysis height was significantly greater in class III subjects. The cortical bone was an average 1.67 ± 0.44 mm in vertical distance in the skeletal class I group and 1.74 ± 0.47 mm in the class III group. The cancellous bone had an average width of 5.03 ± 1.94 mm in the skeletal class I group and 4.74 ± 2.05 mm in the class III group. It was observed that cancellous bone was significantly thicker at the incisor level than at the canine level. There were anatomical differences between skeletal class I and class III subjects, although the clinical significance may be questionable. With the values from these analyses, it may be concluded that there are no significant differences in quantitation of the cortical and cancellous bone in the anterior mandibular symphysis.

Key Words: bone graft, mandibular symphysis, bone transplantation

INTRODUCTION

The mandibular symphysis has been widely used to harvest bone grafts as it has a suitable, fast, and efficient surgical approach in terms of bone quantity and quality.¹

The morbidity associated with the osteotomy and bone removal in the mandibular symphysis region has caused some controversy regarding its use.^{2,3} It has been reported that the morbidity related mainly to postoperative paresthesia and

altered sensitivity may be related to the depth and approach of the osteotomy to the cancellous bone; an alternative to reduce this complication would be to decrease the depth of the osteotomy in the area of mandibular symphysis.⁴ Other authors have described the use of piezoelectric systems to reduce the associated morbidity.⁵ Nevertheless, this anatomical sector continues to be used in preimplantation reconstructive surgeries.

Some studies have endeavored to identify the anatomical features of the mandibular symphysis and peripheral sites to relate them to their implications as a donor site.^{6,7} Bone characteristics, safety margins, and bone volumes have been quantified to recognize a viable surgical area and its repair using cadaver mandibles,⁸ computed tomography,⁹ and 2-dimensional (2D) X rays¹⁰; however, analyses related to the subjects' skeletal characteristics were not observed, and cortical/cancellous bone ratios have not been assessed.

Facial and dental malocclusions are related to differences in the skeletal condition in terms of proportion and growth of the maxilla and/or mandible.¹¹ Some articles report differences in the presence of systemic pathologies,¹² upper airway volume,¹³

¹ Dental Sciences Program, Dental School, Universidad de La Frontera, Temuco, Chile.

² Division of Oral and Maxillofacial Surgery & Center for Morphological and Surgical Studies, Universidad de La Frontera, Temuco, Chile.

³ Center for Biomedical Research, Universidad Autónoma de Chile, Temuco, Chile.

⁴ Facultad de Odontología, Universidad San Sebastián, Lago Panguipulli, Puerto Montt, Chile.

⁵ Department of Dentistry, Universidad de La Frontera, Temuco, Chile.

⁶ Division of Oral and Maxillofacial Surgery, Piracicaba Dental School, State University of Campinas, Campinas, Brazil.

* Corresponding author, e-mail: sergio.olate@ufrontera.cl

DOI: 10.1563/aaid-joi-D-16-00150

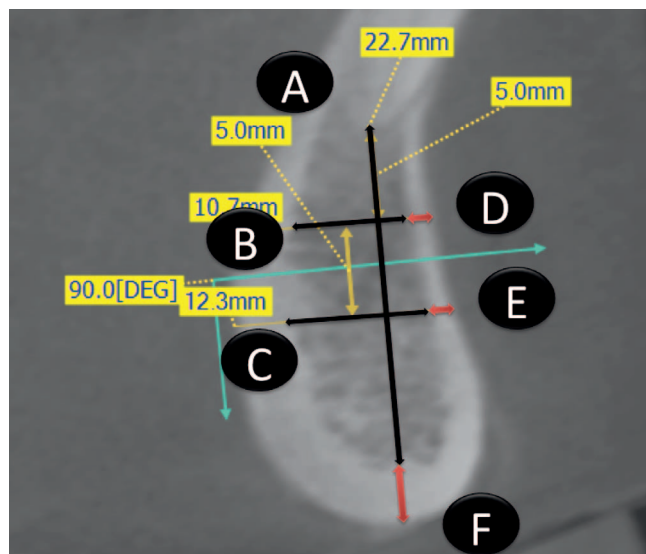


FIGURE. Lines used to establish measurements in the symphysis region related to each tooth.

and tooth angulations¹⁴; in this sense, Veli et al¹⁵ reported significant differences between dental class I and class II subjects when comparing the sagittal size of the cortical bone using computerized tomography (CT). It may therefore be possible to observe differences in bone quantity as a source for bone graft related to skeletal conditions.

Thus, the aim of this research was to assess the cortical and cancellous bone present in the mandibular symphysis anterior sector and relate it to the teeth and skeletal class.

MATERIALS AND METHODS

A descriptive study was conducted to measure the width of buccal cortical bone, inferior cortical bone, cancellous bone, and height of the mandibular symphysis in adult subjects between 18 and 30 years with dental class I (Angle's class I) and class III (Angle's class III)¹⁶ with mandibular prognathism. Inclusion criteria were associated with dental occlusion (Angle's type I or III), overjet (2–4 mm of sagittal relation for Angle's class I; –1 mm or less for Angle's class III) and definition of ANB angle (0° to 4° for skeletal class I; 0° or less for skeletal class III). Exclusion criteria were subjects who had bone pathology such as osteoporosis, another dental and/or skeletal class, facial malformations, facial asymmetries with chin deviation greater than 5 mm from the midline, or previous dental extractions or surgeries in the area of interest.

The size of the sample was consistent with other papers published in this field, and the subjects were recruited in the Division of Oral and Maxillofacial Surgery at the Universidad de La Frontera and agreed to participate in the study by signing an informed consent. This study was approved by the Ethics Committee of the Universidad de La Frontera with Protocol 052/2015.

To make a diagnosis or ascertain treatment requirements (plan for orthognathic surgery or mandibular symphysis bone harvest for graft), all subjects were analyzed using cone beam

CT (CBCT) taken in the maximum intercuspation position using the PlanMeca device (PlanMeca, Helsinki, Finland); the same examination (CBCT) was used in this research considering an image analysis with the EZ3D Plus software (Vatech Co, Hwaseong-si, Gyeonggi-do, Korea) by a single observer who took the measurements at 2-week intervals; the correlation coefficient between the first and second measurement was 0.99 and presented $P = .001$.

For the measurements, the 3D image was positioned to establish the mandibular midline, setting the central bone point between the right and left lower central incisors, coinciding in its lower part with the mandibular midline. The 2D image was obtained from that position; then, for each tooth of interest, the image was moved from this central location until positioned on the tooth's axial axis that came in contact with the dental apex so that each study area was kept at the same tilt and angulation.

The measurements were taken on the lower right canine (RC) and left canine (LC), lower right lateral incisor (RLI) and left lateral incisor (LLI), lower right central incisor (RCI), and left lateral incisor (LLI); on each tooth, 6 linear measurements were taken that interpreted the bone height in the area, the cortical bone thickness, and the thickness of cancellous bone as follows (the Figure). Line A is straight line from the tooth apex to the lowest point of the basilar area (in the cortical bone) of the tooth. Line B is 5 mm below the apex of each tooth. A perpendicular line was made to line A from the lingual to the buccal cortical bone. Line B corresponds to the width of cancellous bone measured between the internal point of the medial lingual cortical bone and the internal point of the buccal cortical bone. Line C is 10 mm below the apex of each tooth. A second perpendicular line was made related to line A from the lingual to the buccal cortical bone. Line C corresponds to the width of cancellous bone measured between the internal point of the medial lingual cortical bone and the internal point of the buccal cortical bone. Line D is in the same direction as line B; the distance was established between the most posterior and anterior point of the buccal cortical bone. Line E has the same direction as line C; the distance was established between the most posterior and anterior point of the buccal cortical bone. Line F is in the same direction as line A, and the distance was established between the highest and lowest point of the inferior cortical bone.

Each result was expressed in millimeters, and the data were analyzed with a 1-way analysis of variance and Tukey's honest significant difference test, considering $P < .05$ as statistical significant using the SPSS 18.0 for Windows (SPSS Inc, IBM Corp, Chicago, Ill).

RESULTS

Features of class I subjects

Eighteen subjects were included in this group with an age average of 23 ± 4.5 years; 12 (66.6%) were women and 6 (33.3%) were men.

The results for this group are summarized in Table 1. The symphysis height (line A) revealed increasing values from the canine to central incisor, noting differences close to 3.5 mm

TABLE 1

Distribution of the measurement in the skeletal class I group (n = 18)

Tooth Area	Vertical Distance Symphysis (A)		Cancellous Bone Upper Area (B)		Cancellous Bone Lower Area (C)		Cortical Bone Upper Area (D)		Cortical Bone Lower Area (E)		Cortical Bone Basilar Area (F)	
	Average	SD	Average	SD	Average	SD	Average	SD	Average	SD	Average	SD
Right												
Canine	16.28	2.19	4.46	1.59	4.02	1.71	1.47	0.25	1.83	0.60	3.57	1.27
Lateral incisor	19.06	2.27	4.76	1.92	5.07	1.86	1.53	0.24	1.58	0.31	3.09	0.57
Central incisor	19.08	4.30	5.20	1.79	6.36	1.39	1.52	0.34	1.84	0.61	2.66	0.68
Left												
Central incisor	20.19	2.50	5.66	1.92	6.42	1.89	1.45	0.24	1.82	0.44	2.42	0.56
Lateral incisor	18.95	2.03	5.04	1.94	5.29	1.38	1.51	0.22	1.67	0.46	3.00	0.68
Canine	15.36	2.13	4.86	1.54	3.24	1.78	1.59	0.33	2.24	0.50	3.37	0.86
Average	18.15	3.20	5.00	1.84	5.07	2.05	1.51	0.28	1.83	0.54	3.02	0.90

between the canine and lateral incisor and almost 4 mm between the canine and central incisor. The height observed according to the areas ranged from 15.36 to 20.19 mm, with significant differences between the dentate areas ($P = .003$).

The average cortical bone thickness in line D was 1.51 mm, with variations among teeth of only 0.14 mm between the areas of least and greatest thickness. The standard deviation also remained very similar. In line E, an average of 1.83 mm was observed, with differences of 0.66 mm. No significant differences were observed in these study areas ($P > .05$). Line F averaged a thickness of 3.02 mm, with a difference of 1.15 mm between the different dentate areas; significant differences were observed that indicated a much greater thickness in the canine than the central incisor region ($P = .000$).

With respect to the cancellous bone, an average of 5 mm was observed in line B, with a difference of 1.2 mm between the dentate areas, because at the central incisor level, the cancellous bone was thicker with no significant differences ($P = .012$). The average thickness of line C was 5.07 mm, with a difference of 3.18 mm between the highest and lowest values; a larger amount of cancellous bone was consistently observed at the central incisor level compared with the canine level ($P = .002$).

Features of class III subjects

Twenty-nine subjects were included in this group, with an average age of 22 ± 5.2 years; 20 (71.4%) were women and 9 (28.6%) were men.

All the results are summarized in Table 2. It was identified that the symphysis height (line A) averaged 18.8 mm, where the greatest height was at the central incisor level, with an average of 20.66 mm, and the lowest level was in relation to the canines, with an average height of 16.62 mm. This difference was statistically significant ($P = .031$).

For the cortical bone analyses, line D had an average thickness of 1.54 mm, with differences of 0.26 mm between the areas of least and greatest thickness ($P > .05$). The region of line E presented an average of 1.93 mm, with a difference of 0.48 mm, showing significant differences between some study areas ($P = .041$). Line F presented average values of 3.03 mm, with a difference of 1.12 mm among the different dentate areas; the central incisor region consistently had a smaller line F than the canine region ($P = .000$).

The cancellous bone in line B presented an average of 4.57 mm with a difference of 0.38 mm, without identifying significant differences ($P > .05$). It was also observed that, in the area of line C, the thickness there was an average of 4.92

TABLE 2

Distribution of the measurement in the skeletal class III group (n = 29)

Tooth Area	Vertical Distance Symphysis (A)		Cancellous Bone Upper Area (B)		Cancellous Bone Lower Area (C)		Cortical Bone Upper Area (D)		Cortical Bone Lower Area (E)		Cortical Bone Basilar Area (F)	
	Average	SD	Average	SD	Average	SD	Average	SD	Average	SD	Average	SD
Right												
Canine	16.95	2.35	4.38	1.80	4.06	1.40	1.60	0.34	1.95	0.40	3.53	0.82
Lateral incisor	18.89	4.35	4.43	2.05	4.77	1.43	1.61	0.31	1.79	0.41	3.13	1.12
Central incisor	20.58	3.13	4.65	2.28	6.23	2.08	1.38	0.35	1.81	0.43	2.41	0.40
Left												
Central incisor	20.74	3.10	4.76	2.23	6.02	2.00	1.47	0.28	1.92	0.32	2.55	1.19
Lateral incisor	19.32	2.84	4.50	2.12	4.97	1.59	1.56	0.33	1.87	0.42	2.99	0.77
Canine	16.30	2.70	4.69	1.90	3.47	1.83	1.64	0.34	2.27	0.74	3.55	1.28
Average	18.15	3.20	4.57	2.08	4.92	2.00	1.54	0.34	1.93	0.50	3.03	1.12

TABLE 3

Comparison and average of measurement in the skeletal class I and class III groups

Tooth Area	Skeletal Class I						Skeletal Class III					
	Anterior Cortical Bone (D + E)		Cancellous Bone (B + C)		Cortical Bone Basilar Area		Anterior Cortical Bone (D + E)		Cancellous Bone (B + C)		Cortical Bone Basilar Area	
	Average	SD	Average	SD	Average	SD	Average	SD	Average	SD	Average	SD
Right												
Canine	1.65	0.5	4.24	1.69	3.57	1.31	1.77	0.42	4.22	1.63	3.53	0.83
Lateral incisor	1.56	0.28	4.92	1.92	3.09	0.59	1.70	0.38	4.60	1.79	3.13	1.14
Central incisor	1.68	0.53	5.78	1.73	2.66	0.70	1.60	0.45	5.44	2.34	2.41	0.41
Left												
Central incisor	1.63	0.41	6.04	1.97	2.42	0.58	1.69	0.37	5.39	2.23	2.55	1.21
Lateral incisor	1.59	0.37	5.16	1.71	3.00	0.70	1.72	0.41	4.73	1.91	2.99	0.78
Canine	1.91	0.54	4.05	1.88	3.37	0.89	1.96	0.66	4.08	1.98	3.55	1.30
Average	1.67	0.44	5.03	1.94	3.02	0.80	1.74	0.47	4.74	2.05	3.03	1.07

mm, with the central region maintaining greater thickness (average of 6.13 mm) and in the canine region maintaining less thickness (average of 3.77 mm), with a difference of 2.76 mm; these differences were significant ($P = .001$).

Comparison between class I and class III

In this sample, sex and age were not related to bone measurement ($P > .05$), and no influence could be observed in cortical or cancellous bone in class I or class III groups. Table 3 shows average comparisons of the different regions, establishing relations between cortical and cancellous bone. For the cortical bone (lines D + E), the subjects in the class I group presented an average of 1.67 ± 0.44 mm and those in the class III group presented an average of 1.74 ± 0.47 mm with no significant differences.

The cancellous bone analysis compared the sum of the two measurements (lines B + C), revealing that the class I group averaged thicknesses of 5.03 ± 1.94 mm and those in class III group averaged thicknesses of 4.74 ± 2.05 mm. Significant differences were observed between the groups in the average measurements of cortical bone and cancellous bone ($P = .003$). The symphysis height presented differences ($P = .0041$), with an average of 18.15 mm for skeletal class I and 18.80 mm for skeletal class III.

DISCUSSION

This study was developed according to a protocol defined by the authors to take measurements of the symphysis region and to study their implications in harvesting mandibular symphysis bone grafts. In this context, the use of CBCT has been consistent in the diagnosis and morphologic considerations of the symphysis area.⁹

Our results show values defined for 2 skeletal formations present in the population. Initially, our results showed limited difference in size of the cortical bone in the anterior zone of the mandible in class I and class III groups, and the presence of deeper cancellous bone in the center (central incisors) than on the periphery (canine) of the symphysis was also worthy of note. There are variables that can influence the variations in

cortical bone size, as well as tooth position and ridge width¹⁷; the cortical structure also depends on normal physiologic conditions, where the sex or the amount of testosterone¹⁸ can have a substantial influence.¹⁹ In this context, Lee et al²⁰ indicated that the size of the symphysis cortical bone may be related to the patient's sex but not to the patient's age. Nevertheless, our results show neither sex nor age of the subjects has any influence on these results.

Lee et al²¹ conducted an interesting study, observing subjects with dental occlusion with no position anomalies; they reported that at the central incisor level, the buccal cortical bone size was 1.8 mm, at the lateral incisor level was 2.0 mm, and at the canine level was 2.3 mm. Our results did not show any buccal cortical bone thicker than 2 mm, which may be associated with the sample. In edentulous subjects, however, Flanagan²² reported that the buccal cortical bone was 1.79 mm, whereas Genisa et al²³ stated that, in 10 subjects assessed with CBCT, the buccal cortical bone presented thicknesses of approximately 1.34 mm.

Our results show that, in subjects with skeletal class I, the anterior cortical bone on the upper level presents a difference of 0.14 mm (minimum of 1.45 mm and maximum of 1.59 mm), and the anterior cortical bone on the lower level was 0.66 mm (minimum of 1.58 mm and maximum of 2.24 mm), whereas type III differences were 0.26 mm (minimum of 1.38 mm and maximum of 1.6 mm) and 0.48 mm (minimum of 1.79 mm and maximum of 2.27 mm) for the upper and lower levels, respectively; some of these relationships have proven statistically significant, but the clinical significance of differences of 0.5 mm may not be relevant.

In terms of the relation of cancellous bone at the upper level (line B) in skeletal class I subjects, the difference observed between the dentate areas analyzed at the upper level was 1.2 mm (minimum of 4.46 mm and maximum of 5.66 mm) and in the lower level (line C) was 2.4 mm (minimum of 3.24 mm and maximum of 6.42 mm), whereas subjects with a skeletal class III relation presented a difference of 0.38 mm (minimum of 4.38 mm and maximum of 4.76 mm) at the upper level and a 2.76-mm difference (minimum of 3.47 mm and maximum of 6.23 mm) at the lower level, where clinically significant differences are found for harvesting bone grafts.

Pozzer et al¹¹ and Olate et al²⁴ concluded that for the different skeletal classes (type II or III) there are differences in the size of the mandible, and all are proportional in comparisons made between the mandibular ramus, mandibular body, and symphysis. However, Veli et al,¹⁵ performing more specific studies, reported significant differences between dental class I and II subjects in terms of the sagittal size of the cortical bone in CT; they confirmed that class III subjects have smaller anterior cortical bone in areas close to the tooth. Our analysis did not measure teeth directly, but this demonstrates the presence of significant differences in some areas when comparing cortical bone or cancellous bone in skeletal class I or III subjects. It is possible, however, for there to be no clinical significance; the type of subjects included in the sample may be important, as the magnitude of the class III deformity could be relevant to this analysis, but this was not considered in the initial variables.

The symphysis area provides good options for harvesting grafts with different volumes. Verdugo et al²⁵ conducted a study where they obtained 2.3 mL of graft from the chin. Yavuz et al⁹ presented mandibular symphysis volumes of 3491 mm³, Gungormus et al²⁶ reported a removal of 4.5 mL from the symphysis in cadavers, and Montazem et al¹ presented a volume of 4.7 mL in the removal from this area. Brockhoff et al²⁷ studied the anatomical condition in the harvesting of bone grafts from the mandibular symphysis of cadavers and stated that the bone volume obtained in this area presented no differences between men and women or dentate or edentulous subjects. They further indicated differences in the size of the buccal cortical bone in subjects with or without teeth, with this difference being greater in the dentate subjects. To assess these volumes, Yates et al⁸ analyzed different donor sites, establishing that the depth of osteotomy to remove bone blocks from the symphysis was close to 7.82 mm. Considering both groups and all the dentate areas, our results indicate an average depth of both cancellous and cortical bone of 6.77 mm, which is almost 1 mm shorter than that observed by Yates et al⁸; the sectorial analysis revealed less depth reached at canine level (considering both groups), even though at the central incisor level there was a depth of 7.56 mm and at the canine level there was a depth of 5.93 mm, revealing differences of 1.63 mm between the two. The volumes that can be obtained under these conditions are less than those described in the literature due to the smaller depth of the possible osteotomy. Verdugo et al²⁵ determined a width of cancellous tissue of 8.2 mm and a width of cortical tissue of 2.2 mm, which decreased in the canine area with a depth of cancellous tissue of 6.8 mm and a depth of cortical tissue of 2.1 mm. Variations in the results may be related to orientations in the measurement, anatomical considerations, or population features with differences in the subjects, but it is certain that Verdugo et al²⁵ showed a similar trend in the decrease of cortical bone from the central incisor position to the canine position.

Clearly, greater volumes can be obtained with deeper osteotomies, which may be limited by the presence of the incisive nerve. It is possible for the results related to the alterations in regional sensitivity to decrease if the incisive nerve is not altered. Pereira-Maciél et al²⁸ demonstrated the

presence of the incisive canal in 100% of the evaluations, and Zeltner et al²⁹ described a study indicating the detection of the incisive nerve in almost all the cases reviewed; Al-Ani et al³⁰ showed that the incisive nerve was present in 100% of the tomography scans studied and that this was at a distance of only 3.15 mm from the bone margin of the buccal cortical bone. With these results, the safety margin in terms of osteotomy depth in the zone of the incisive nerve would be only 3 mm deep, and the previously described volumes could not be obtained.

Given these anatomical limitations, the complications associated with the postoperative sensitivity observed in obtaining grafts in this zone can be seen.² In fact, a recent systematic review by Reininger et al³¹ demonstrated that the highest alteration rates and postoperative sequelae were associated with sensitivity.

On the other hand, osteotomies require at least 5 mm from any other anatomical structure (dental apex, mental foramen, or mandibular base) to reduce the morbidity in the harvesting of the graft, since Misch in 1992 proposed a surgical technique to harvest a bone block graft from the symphysis, which helps prevent injury to the neurovascular components of the mandibular symphysis region. All the bone cuts should be perpendicular to the cortex at a right angle to the vestibular plain of the symphysis,³² and Pommer et al⁴ modified some limits for the cuts. The average inferior cortical bone observed in skeletal class I subjects was 3.02 ± 0.8 mm and in skeletal class III subjects was 3.03 ± 1.07 mm; Zeltner et al²⁹ used a methodology to analyze symphysis bone volume, considering a distance of 2 mm from the lower limit of the symphysis cortical bone, which involved an osteotomy in this cortical area. Although there are no data regarding the mechanical response to the removal of bone grafts, this condition can cause a decrease in the mechanical resistance of the anterior area of the mandible³³.

Altıparmak et al⁵ developed a study with the upper limit of the osteotomy 5 mm below the dental apex, reporting the result of 4 teeth (1.4%) with postoperative endodontic treatment and 40 teeth (13.8%) with the negative vitality test. Weibull et al,³⁴ using the same technique, presented 5 teeth with apical pathology (1.2%). Two relevant aspects are related to these alterations: distance of the osteotomy from the dental apex and the depth of the osteotomy. Pommer et al⁴ evaluated 50 CT scans of dentate mandibles, concluding that the safety margins should place the osteotomy 8 mm below the dental apex.

Thus, the distances that appear viable for harvesting the bone graft with low morbidity are limited; in fact, in the methodology of Ersanil et al,³⁵ the selection of the symphysis or chin donor site was related, among other things, to the proximity of tooth roots to the osteotomy site. Based on these arguments, 8 mm below the apex and 5 mm on the basilar margin, that is, 13 mm, would be the minimum to maintain when harvesting grafts in this area. The symphysis bone height between the basal bone and dental apex in subjects with skeletal class I is on average 18.15 mm and those of class III were on average 18.80 mm (difference of 0.65 mm), which implies that only 5.15–5.80 mm could be useful for graft harvesting, which limits the volumetric outcomes. On the other

hand, the height in the canine area was almost 4 mm less than that observed in the central incisor area (average height of central incisors was 20.12 mm and of canines was 16.22 mm), which limits the options of graft harvesting in the canine area even more, maintaining only 3 mm of viable height to harvest the graft while respecting the safety margins in the canine region. These conditions make it possible to anticipate that the most viable areas for this procedure are related exclusively to the lateral and central incisors.

On the other hand, removing a large of volume of bone could compromise the regeneration of the mandibular symphysis area. Weibull et al³⁴ reported that complete bone regeneration in symphysis donor sites was 8.9%; 28.8% presented even smaller cavities, whereas 62.2% presented clear concavities with limited repair of the area. Noia et al¹⁰ also reported that after 1 year, cavities were still observed in the symphysis area, with an area of up to 50% lacking bone repair.

Some limitations in this research related to the sample selection including age (patients involved in bone graft surgery are usually older than 30 years of age) and variations in the deformities (vertical deformities, facial asymmetry, and others were not included) could have an important influence in our results. However, this research can serve as a starting point in the discussion about the influence of facial and dental morphology on the bone characteristics applied to oral surgery.

CONCLUSION

On the basis of our results, it may be concluded that there are no significant differences in the symphysis morphology of skeletal class I and III subjects. Also, each dental area presents important individualities that must be taken into consideration if bone is to be obtained from this anatomical area.

ABBREVIATIONS

CBCT: cone beam computerized tomography
 CT: computerized tomography
 LC: left canine
 LLI: left lateral incisor
 RC: right canine
 RCI: right central incisor

NOTE

The authors report no conflicts of interest

REFERENCES

- Montazem A, Valauri D, St-Hilaire H, Buchhinder D. The mandibular symphysis as a donor site in maxillofacial bone grafting. *J Oral Maxillofac Surg.* 2000;58:1368–1371.
- Noia CF, Ortega-Lopes R, Olate S, Duque TM, de Moraes M, Mazzonetto R. Prospective clinical assessment of morbidity after chin bone harvest. *J Craniofac Surg.* 2011;22:2195–2198.
- Clavero J, Lundgren S. Ramus or chin grafts for maxillary sinus inlay and local onlay augmentation: comparison of donor site morbidity and complications. *Clin Implant Dent Res.* 2003;5:154–160.
- Pommer B, Tepper G, Gahlleitner A, Zechner W, Watzek G. New safety margins for chin bone harvesting based on the course of the mandibular incisive canal in CT. *Clin Oral Implants Res.* 2008;19:1312–1316.
- Altıparmak N, Soydan SS, Uckan S. The effect of conventional surgery and piezoelectric surgery bone harvesting techniques on the donor site morbidity of the mandibular ramus and symphysis. *Int J Oral Maxillofac Surg.* 2015;44:1131–1137.
- Couto-Filho CEG, de Moraes PHA, Alonso MBC, Haiter-Neto F, Olate S, Albergaria-Barbosa JR. Accuracy in the diagnosis of the mental nerve loop. A comparative study between panoramic radiography and cone beam computed tomography. *Int J Morphol.* 2015;33:327–332.
- Vu DD, Brockhoff HC 2nd, Yates DM, Finn R, Phillips C. Course of the mandibular incisive canal and its impact on harvesting symphysis bone graft. *J Oral Maxillofac Surg.* 2015;73:258.e1–258.e12.
- Yates D, Brockhoff HC, Finn R, Phillips C. Comparison of intraoral harvest site for cortico cancellous bone grafts. *J Oral Maxillofac Surg.* 2013;71:497–504.
- Yavuz MS, Buyukkurt MC, Tozoglu S, Dagsuyu IM, Kantarci M. Evaluation of volumetry and density of mandibular symphysis bone grafts by three-dimensional computed tomography. *Dent Traumatol.* 2009;25:475–479.
- Noia CF, Ortega-Lopes R, Sato FRL, Olate S, Mazzonetto R. Radiographic prospective study of osseous repair in mandibular symphysis after chin bone remove. *Int J Morphol.* 2012;30:100–104.
- Pozzer L, Olate S, Asprino L, de Moraes M. Are there differences in the mandibular morphometry in patients who are candidates for orthognathic surgery? Part 1: influences of facial class. *Int J Morphol.* 2009;27:751–756.
- Joshi N, Hamdan AM, Fakhouri WD. Skeletal malocclusion: a developmental disorder with a life-long morbidity. *J Clin Med Res.* 2014;6:399–408.
- Neelapu BC, Kharbanda OP, Sardana HK, et al. Craniofacial and upper airway morphology in adult obstructive sleep apnea patients: a systematic review and meta-analysis of cephalometric studies. *Sleep Med Rev.* 2016;31:79–90.
- Pereira-Stabile CL, Ochs MW, de Moraes M, Moreira RW. Preoperative incisor inclination in patients with class III dentofacial deformities treated with orthognathic surgery. *Br J Oral Maxillofac Surg.* 2012;50:533–536.
- Veli I, Uysal T, Baysal A, Karadede I. Buccal cortical bone thickness at miniscrew placement sites in patients with different vertical skeletal patterns. *J Orofac Orthop.* 2014;75:417–429.
- Angle EH. Classification of malocclusion. *Dent Cosmos.* 1899;41:248–264.
- Garlock DT, Buschang PH, Araujo EA, Behrenys RG, Kim KB. Evaluation of marginal alveolar bone in the anterior mandible with pretreatment and posttreatment computed tomography in nonextraction patients. *Am J Orthod Dentofacial Orthop.* 2016;149:192–201.
- Wang Q, Kessler MJ, Kensler TB, Dechow PC. The mandibles of castrated male rhesus macaques (*Macaca mulatta*): the effects of orchidectomy on bone and teeth. *Am J Phys Anthropol.* 2016;159:31–51.
- Attili S, Surapaneni H, Kasina SP, Balusu S, Barla SC. To evaluate the bone mineral density in mandible of edentulous patients using computed tomography: an in vivo study. *J Int Oral Health.* 2015;7:22–26.
- Lee KA, Kim MS, Hong JY, et al. Anatomical topography of the mandibular symphysis in the Korean population: a computed tomography analysis. *Clin Anat.* 2014;27:592–597.
- Lee JE, Lee YJ, Jin SH, et al. Topographic analysis of the mandibular symphysis in a normal occlusion population using cone-beam computed tomography. *Exp Ther Med.* 2015;10:2150–2156.
- Flanagan D. A comparison of facial and lingual cortical thicknesses in edentulous maxillary and mandibular sites measured on computerized tomograms. *J Oral Implantol.* 2008;34:256–258.
- Genisa M, Rajion Z, Pohchi A, Yap J, Rafiq M. Preoperative bone assessment using cone beam computed tomography. *Int Med J.* 2014;21:412–415.
- Olate S, Pozzer L, Sawazaki R, Asprino L, de Moraes M. Are there differences in the mandibular morphometry in patients who are candidate for orthognathic surgery? Part 2: influences of gender. *Int J Morphol.* 2009;27:751–756.
- Verdugo F, Simonian K, Raffaelli L, D'Addona A. Computer-aided design evaluation of harvestable mandibular bone volumen: a clinical and tomographic human study. *Clin Implant Dent Relat Res.* 2014;16:348–355.
- Gungormus M, Yilmaz AB, Ertas U, Akgul HM, Yavuz MS, Harorli A.

Evaluation of the mandible as an alternative autogenous bone source for oral and maxillofacial reconstruction. *J Int Med Res.* 2002;30:260–264.

27. Brockhoff HC 2nd, Yates DM, Finn R, Phillips C. Comparison of intraoral harvest sites in the edentulous versus dentate specimen. *Oral Surg Oral Med Oral Pathol Oral Radiol.* 2014;117:575–580.

28. Pereira-Maciel P, Tavares-de-Sousa E, Oliveira-Sales MA. The mandibular incisive canal and its anatomical relationships: a cone beam computed tomography study. *Med Oral Patol Oral Cir Bucal.* 2015;20:e723–e728.

29. Zeltner M, Flückiger LB, Hämmerle C, Hüsler J, Benic G. Volumetric analysis of chin and mandibular retromolar region as donor sites for cortico-cancellous bone blocks. *Clin Oral Impl Res.* 2016;27:999–1004.

30. Al-Ani O, Nambiar P, Ha KO, Ngeow WC. Safe zone for bone harvesting from interforaminal region of the mandible. *Clin Oral Impl Res.* 2013;24(Suppl A100):115–121.

31. Reiningger D, Cobo-Vázquez C, Monteserín-Matesanz M, López-

Quiles J. Complications in the use of mandibular body, ramus and symphysis as donor sites in bone graft surgery. A systematic review. *Med Oral Pathol Oral Cir Bucal.* 2016;21:e241–e249.

32. Misch CM, Misch CE, Resnik, Ismail YH. Reconstruction of maxillary alveolar defects with mandibular symphysis grafts for dental implants: a preliminary procedural report. *Int J Oral Maxillofacial Implants.* 1992;7:360–366.

33. Van Eijden TMGJ. Biomechanics of the mandible. *Crit Rev Oral Biol Med.* 2000;11:123–136.

34. Weibull L, Widmark G, Ivanoff CJ, Borg E, Rasmusson L. Morbidity after chin bone harvesting: a retrospective long-term follow-up study. *Clin Implant Dent Relat Res.* 2009;11:149–157.

35. Ersanil S, Arisan V, Bedelogllu E. Evaluation of the autogenous bone block transfer for dental implant placement: symphyseal or ramus harvesting? *BMC Oral Health.* 2016;16:4.