

# Histological and Histomorphometrical Analysis on a Loaded Implant With Platform-Switching and Conical Connection: A Case Report

Giovanna Iezzi, DDS, PhD<sup>1</sup>  
 Flavia Iaculli, DDS, PhD<sup>1\*</sup>  
 Roberta Calcaterra, MD, PhD<sup>2</sup>  
 Adriano Piattelli, MD, DDS<sup>1</sup>  
 Michele Di Girolamo, DDS<sup>3</sup>  
 Luigi Baggi, DDS<sup>2,3</sup>

The association of Morse taper implant-abutment design with the use of a smaller abutment diameter (platform switching) may improve dental implant success rate and prevent peri-implant bone loss. The aim of the present study was to histologically and histomorphometrically evaluate the behavior of peri-implant tissues around an implant with a conical connection associated with platform switching. A platform-switched Morse-cone connection implant was inserted in the left posterior mandible of a 61-year-old patient. The implant was inserted at the level of the alveolar crest. After 11 months from placement and 6 months of loading, the implant was retrieved for psychological reasons and processed for histological evaluation. The retrieved implant was wholly surrounded by bone tissue, except for a small area in the apical portion. At higher magnification, in the coronal portion of the implant, it was possible to observe bone directly at the implant platform level. No resorption of the coronal bone was present, except for 0.2 mm on the vestibular aspect. Crestally, bone remodeling with areas of newly formed bone was detected; the bone-implant contact was 73.9%. Apposition of bone was detected even upon the platform. Peri-implant crestal bone preservation can be achieved with the combination of Morse taper conical internal implant-abutment connection with the use of a smaller abutment diameter (platform-switching).

**Key Words:** *implant success, marginal bone loss, Morse taper connection, platform-switching*

## INTRODUCTION

Implant-supported restorations represent an accepted technique for the rehabilitation of partial or full edentulous jaws, providing high success rates in the middle<sup>1,2</sup> and long term.<sup>3,4</sup> Marginal bone loss is considered the key factor in the stability and longevity of dental implants, as well as in the maintenance of the peri-implant soft tissues. Although a certain degree of marginal bone loss is considered physiological and in the range of acceptability (ie, a vertical bone loss of ~1.5 mm in the first year, and <0.2 mm annually),<sup>5</sup> biological, clinical, and mechanical factors,<sup>6</sup> such as bacterial infection, overloading, and peri-implantitis are involved in crestal bone resorption.<sup>7</sup> A recent finite-element analysis<sup>8</sup> showed that a progressive marginal bone loss would lead to a progressive increase in stress intensity at the peri-implant interface that, in turn, may contribute to a further overload-induced bone loss, jeopardiz-

ing clinical effectiveness and durability of the prosthetic treatment.

It has been hypostasized that implant-abutment connection may contribute to stability of the peri-implant bone level. Specifically, implant-abutment geometry influences both bacterial and yeast colonization inside the implants.<sup>9</sup> The Morse taper conical internal connection showed better results in terms of prevention of microbial penetration, sealing performance, and implant stability.<sup>10-12</sup> The lesser marginal gap between the implant and abutment in the conical connection induces a decrease in bacterial penetration, thus preventing marginal bone loss.<sup>12</sup> However, when a matching implant-abutment diameter is used, the inflammatory infiltrate is always located at the level of the implant-abutment interface and in tight contact with crestal bone, causing resorption of marginal bone. The platform-switching concept (implant-abutment mismatch) was introduced to overcome the limits of the platform-matched implants and demonstrated a better maintenance of crestal bone level over time.<sup>6,13,14</sup> Moreover, platform-switching implants might also be used in areas of limited bone height<sup>15</sup> and showed a failure rate comparable to that of conventional platform implants,<sup>16</sup> although studies with a longer follow-up period are needed to confirm the results over time. The association of Morse taper implant-abutment

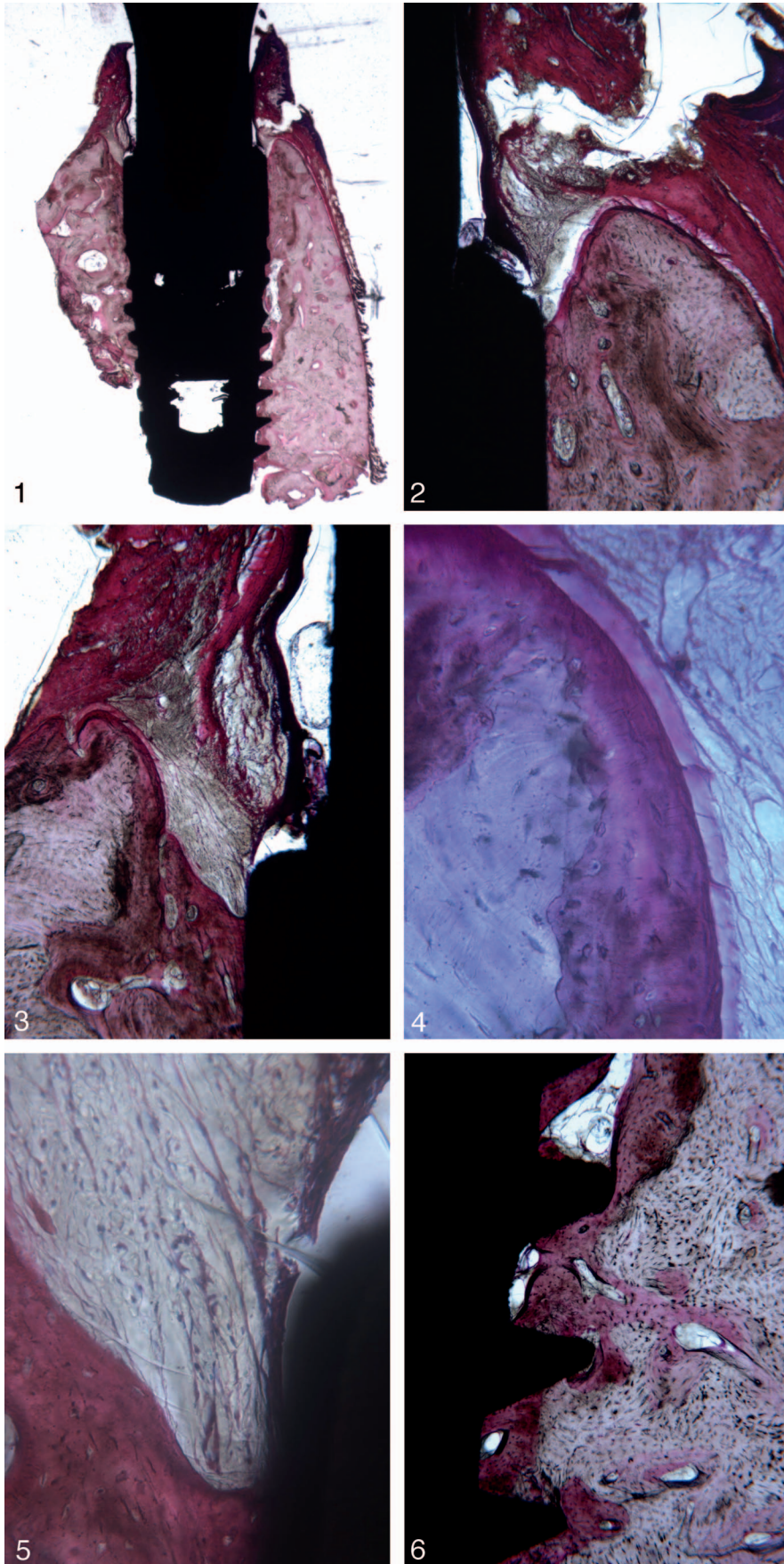
<sup>1</sup> Department of Medical, Oral and Biotechnological Sciences, University "G. d'Annunzio" of Chieti-Pescara, Chieti, Italy.

<sup>2</sup> Department of Social Dentistry, National Institute for Health, Migration and Poverty, Rome, Italy.

<sup>3</sup> School of Dentistry, University of Rome Tor Vergata, Rome, Italy.

\* Corresponding author, e-mail: f.iaculli@unich.it

DOI: 10.1563/aaid-joi-D-16-00182



design with the use of a smaller abutment diameter allows for preservation of more peri-implant bone, stabilization of peri-implant soft tissues, reduction of the microgap size, and a proper geometry for narrower mesiodistal edentulous spaces.<sup>17</sup>

The aim of the present study was to histologically and histomorphometrically evaluate the behavior of the peri-implant tissues around an implant with a conical connection associated with platform switching.

#### MATERIALS AND METHODS

A 61-year-old female patient received 1 implant (3.3 mm in diameter and 7.5 mm in length, GTB- Plan1Health, Amaro, Italy) in the left posterior mandible (3.7 position). The implant was positioned according to the suggested procedures provided by the manufacturer. In particular, the implant was placed in crestal position using a one-stage technique with a healing abutment at an adequate gingival height.

At week 1 the surgical sutures were removed; after 2 months the healing abutment was removed as well, and a specific abutment (Easy Abutment Slim GTB Plan 1Health) was placed, and then the implant received a cemented (Tempbond NE, Kerr, KaVo Kerr Group, Orange, Calif) temporary acrylic crown.

At month 5, a definitive (abutment level) impression on the abutment was performed. After a week, a definitive gold alloy-resin crown was cemented with a self-curing zinc-oxide eugenol-based cement (Tempbond NE, Kerr, KaVo Kerr Group).

Eleven months after the implant placement and 6 months after the functional loading, the implant was stable, although it was removed for psychological distress reasons. The retrieval was performed with a 5-mm-wide trephine bur under copious saline irrigation; once retrieved, the whole implant, the prosthetic crown, and the surrounding hard and soft tissues were immediately stored in 10% buffered formalin and sent to the Implant Retrieval Center of the Department of Medical, Oral and Biotechnological Sciences of the University of Chieti-Pescara (Italy) for the histological evaluation. The specimen was processed as previously described by Bako et al<sup>18</sup> and according to the resin manufacturer's instruction; briefly, the sample was dehydrated in an ascending series of alcohol rinses (70%, 80%, 90%, and 100% ethanol) followed by an intermediate phase with xylene; it was then embedded in methyl-methacrylate resin (Technovit 9100 New, Heraeus Kulzer GmbH, Hanau, Germany). Technovit 9100 New base solution was destabilized using a chromatography column filled with 50 g of Al<sub>2</sub>O<sub>3</sub>. Before infiltration, the sample was pre-embedded in 3 steps. Solution for preinfiltration 1 was prepared with xylene and destabilized base solution (1:1). For the preinfiltration 2 and

3 solutions, 1 g of dibenzoyl peroxide (hardener 1) was added to 200 mL of stabilized and destabilized base solution, respectively. For the infiltration solution, 200 mL of destabilized base solution was mixed with 1 g of hardener 1 in a glass container (using a magnetic stirrer). Then, 20 g of polymethyl-methacrylate powder was added to the solution until the powder did not completely dissolve. Thus, the sample was polymerized in a vacuum-sealed condition and in the range of -2°C to -20°C; the polymerization solution was mixed immediately before using cooled stock solutions A and B (obtained according to manufacture instruction) in a ratio of 9:1.

After polymerization, the specimen was sectioned longitudinally along the major axis of the implants with a high-precision diamond disc at about 150 µm and ground down to about 30 µm with Precise 1 Automated System (Assing, Rome, Italy). The obtained slides were stained with basic fuchsin and toluidine blue. Histomorphometry of bone-implant contact percentage was carried out using a light microscope (Laborlux S, Leitz, Wetzlar, Germany) connected to a high resolution video camera (3CCD, JVC KY-F55B, JVC, Kanagawa-ku, Yokohama, Japan) interfaced to a monitor and personal computer (Intel Pentium III 1200 MMX, Intel, Santa Clara, Calif). This optical system was associated with a digitizing pad (Matrix Vision GmbH) and a histometry software package with image-capturing capabilities (Image-Pro Plus 4.5, Media Cybernetics Inc, Immagini & Computer Snc, Milan, Italy).

#### RESULTS

Histologically, the specimen was represented by the implant surrounded by bone tissue and the abutment with the prosthetic crown. At lower magnification, bone was present around the whole implant surface, except for a small area in the apical portion of the implant, where a small amount seemed to be lost, probably during the retrieval procedure. Gingival tissue was partially in contact with the implant abutment (Figure 1).

At higher magnification, in the coronal portion of the implant, it was possible to observe bone directly at the implant platform level, both vestibularly (Figure 2) and lingually. No resorption of the coronal bone was present, except for 0.2 mm on the vestibular aspect, and in this area no osteoclasts could be detected (Figure 3). Crestally, bone remodeling with areas of newly formed bone and numerous cement lines with several degree of affinity to acid fuchsin were present (Figure 4).

Only a few inflammatory cells, some spindle-shaped cells, and blood vessels were observed in the soft tissues around the implant platform (Figure 5). No gaps or fibrous connective tissue were found at the bone-implant interface, and many

←  
**FIGURES 1–6.** **FIGURE 1.** Bone was present around the whole implant surface, except for a little area in the apical portion of the implant. Acid fuchsin-toluidine blue, original magnification ×12. **FIGURE 2.** Bone was present in the coronal portion of the implant on both the vestibular and lingual side. Acid fuchsin-toluidine blue, original magnification ×40. **FIGURE 3.** A little area of resorption could be observed on the vestibular side of the crestal bone, but no osteoclasts were visible. Acid fuchsin-toluidine blue, original magnification ×40. **FIGURE 4.** In the coronal portion, newly formed bone with wide osteocyte lacunae is evident. Acid fuchsin-toluidine blue, original magnification ×200. **FIGURE 5.** On the implant shoulder, a small portion of soft tissue could be observed. Acid fuchsin-toluidine blue, original magnification ×200. **FIGURE 6.** Many remodeling areas were observed along the implant body, mainly in the concavities and convexities of the implant threads. Acid fuchsin-toluidine blue, original magnification ×100.



remodeling areas were observed along the implant body (Figure 6). Inside some implant threads, osteons could be detected in tight contact with the implant surface. The bone-implant contact was 73.9%.

### Discussion

The present study evaluated a platform-switched Morse-cone connection implant retrieved after 11 months from placement and 6 months of functional loading. The histological analysis showed that the implant was wholly surrounded by bone tissue, and it was possible to detect bone directly in contact with and upon the implant platform.

These results are very promising since the implant had a limited loading period (6 months) and an initial equicrestal implant position. Indeed, according to the literature, the subcrestal placement of an implant is strongly recommended to preserve the crestal bone level. Degidi et al<sup>19</sup> showed that Morse-cone implants placed subcrestally in 89.9% of patients were able to maintain the bone crest 1 year after loading, with a 9.7% incidence of loss sites (bone loss >0.5 mm) after at least 3 years of follow-up. Moreover, results comparable with the present report, in which bone was located above the implant platform, were reported in subcrestally placed implants.<sup>20</sup> Probably, the combination of Morse taper conical internal connection with platform-switching leads to crestal bone preservation regardless of the implant position and provides advantages in terms of mechanical and biological behavior.

The importance of bone support in the maintenance of osseointegration over time as well as bone preservation are crucial issues in the evaluation of implant success and survival rates. In the present study, no resorption of the coronal bone was reported, except for 0.2 mm on the vestibular aspect, which might be considered physiological.<sup>5</sup>

Implant-abutment systems with tube-in-tube interfaces avoided microbiologic leakage<sup>21</sup> and seemed not to induce an immune response by the surrounding epithelial cells due to the position of the gap at the implant-abutment interface.<sup>22</sup>

A recent meta-analysis reported that platform-switched implants showed significantly less peri-implant marginal bone loss compared with conventional platform-matched ones.<sup>14</sup> Rocha et al<sup>6</sup> evaluated the clinical performance and crestal bone levels between platform-matched and platform-switched implants after 3 years, and demonstrated a mean bone loss of  $0.68 \pm 0.64$  mm and  $0.28 \pm 0.56$  mm, respectively, with a statistically significant difference in favour of the platform switching group<sup>6</sup>. Accordingly, Cassetta et al<sup>23</sup> reported a mean marginal bone remodeling of 0.56 mm in 576 Morse taper connection implants with platform switching after 36-months of follow-up. In addition, in the same prospective cohort study,<sup>23</sup> the authors described a statistically significant higher marginal bone loss for subcrestal implants inserted into the maxilla for implants inserted into patients older than 50 years and for early delayed implants inserted into patients older than 50 years.

A histological and histomorphometrical report<sup>24</sup> of an immediately loaded implant with a conical implant abutment connection and platform switching after a 1-month loading period showed results comparable with those of the present

study, demonstrating the presence of newly formed bone in direct contact with the implant surface and bone tissue above the level of the implant platform, in addition to the absence of bone resorption and inflammatory infiltrate. The bone-implant contact percentage was  $65.3\% \pm 4.8\%$ , slightly less than that shown in the present report (73,9%).

The internal Morse taper implant-abutment design, in combination with abutments smaller than the diameter of the implant body (platform switching), appears to clinically reduce marginal bone loss, to allow the stabilization of the surrounding hard and soft tissues and to maintain the implant success over time.

### CONCLUSIONS

Within the limitation of the present study, peri-implant crestal bone preservation can be achieved with the combination of a Morse taper conical internal implant-abutment connection and use of a smaller abutment diameter (platform switching). Further studies are needed to confirm these preliminary results with a larger sample size and in the long term.

### NOTE

The authors claim to have no financial interest, either directly or indirectly, in the products or information listed in the article. The authors declare no conflicts of interest.

### REFERENCES

1. Misch CE, Degidi M. Five-year prospective study of immediate/early loading of fixed prostheses in completely edentulous jaws with a bone quality-based implant system. *Clin Implant Dent Relat Res.* 2003;5:17–28.
2. Degidi M, Nardi D, Piattelli A. 10-year follow-up of immediately loaded implants with TiUnite porous anodized surface. *Clin Implant Dent Relat Res.* 2012;14:828–838.
3. Iezzi G, Piattelli A, Mangano C, et al. Periimplant bone response in human-retrieved, clinically stable, successful, and functioning dental implants after a long-term loading period: a report of 17 cases from 4 to 20 years. *Implant Dent.* 2016;25:380–386.
4. Mangano C, Iaculli F, Piattelli A, Mangano F. Fixed restorations supported by Morse-taper connection implants: a retrospective clinical study with 10–20 years of follow-up. *Clin Oral Implants Res.* 2015;26:1229–1236.
5. Albrektsson T, Zarb G, Worthington P, Eriksson AR. The long-term efficacy of currently used dental implants: a review and proposed criteria of success. *Int J Oral Maxillofac Implants.* 1986;1:11–25.
6. Rocha S, Wagner W, Wiltfang J, et al. Effect of platform switching on crestal bone levels around implants in the posterior mandible: 3 years results from a multicentre randomized clinical trial. *J Clin Periodontol.* 2016;43:374–382.
7. Albrektsson T, Canullo L, Cochran D, De Bruyn H. “Peri-Implantitis”: a complication of a foreign body or a man-made “disease”. Facts and fiction. *Clin Implant Dent Relat Res.* 2016;18:840–849.
8. Baggi L, Di Girolamo M, Vairo G, Sannino G. Comparative evaluation of osseointegrated dental implants based on platform-switching concept: influence of diameter, length, thread shape, and in-bone positioning depth on stress-based performance. *Comput Math Methods Med.* 2013;2013:250929.
9. Baggi L, Di Girolamo M, Mirisola C, Calcaterra R. Microbiological evaluation of bacterial and mycotic seal in implant systems with different implant-abutment interfaces and closing torque values. *Implant Dent.* 2013;22:344–350.
10. Tripodi D, Vantaggiato G, Scarano A, et al. An in vitro investigation

concerning the bacterial leakage at implants with internal hexagon and Morse taper implant-abutment connections. *Implant Dent.* 2012;21:335–339.

11. Assenza B, Tripodi D, Scarano A, et al. Bacterial leakage in implants with different implant-abutment connections: an in vitro study. *J Periodontol.* 2012;83:491–497.

12. Schmitt CM, Nogueira-Filho G, Tenenbaum HC, et al. Performance of conical abutment (Morse Taper) connection implants: a systematic review. *J Biomed Mater Res Part A.* 2014;102A:552–574.

13. Annibaldi S, Bignozzi I, Cristalli MP, Graziani F, La Monaca G, Polimeni A. Peri-implant marginal bone level: a systematic review and meta-analysis of studies comparing platform switching versus conventionally restored implants. *J Clin Periodontol.* 2012;39:1097–1113.

14. Aslam A, Ahmed B. Platform-switching to preserve peri-implant bone: a meta-analysis. *J Coll Physicians Surg Pak.* 2016;26:315–319.

15. Cappiello M, Luongo R, Di Iorio D, Bugea C, Cocchetto R, Celletti R. Evaluation of peri-implant bone loss around platform-switched implants. *Int J Periodontics Restorative Dent.* 2008;28:347–355.

16. Santiago JF Jr, de Souza Batista VE, Verri FR, et al. Platform-switching implants and bone preservation: a systematic review and meta-analysis. *Int J Oral Maxillofac Surg.* 2016;45:332–345.

17. Macedo JP, Pereira J, Vahey BR, et al. Morse taper dental implants and platform switching: the new paradigm in oral implantology. *Eur J Dent.* 2016;10:148–154.

18. Bako P, Bassiouni M, Eckhard A, et al. Methyl methacrylate

embedding to study the morphology and immunohistochemistry of adult guinea pig and mouse cochleae. *J Neurosci Methods.* 2015;254:86–93.

19. Degidi M, Daprile G, Piattelli A. Marginal bone loss around implants with platform-switched Morse-cone connection: a radiographic cross-sectional study. *Clin Oral Implants Res.* In press.

20. Degidi M, Perrotti V, Shibli JA, Novaes AB, Piattelli A, Iezzi G. Equicrestal and subcrestal dental implants: a histologic and histomorphometric evaluation of nine retrieved human implants. *J Periodontol.* 2011;82:708–715.

21. Calcaterra R, Di Girolamo M, Mirisola C, Baggi L. Effects of repeated screw tightening on implant abutment interfaces in terms of bacterial and yeast leakage in vitro: one-time abutment versus the multiscrewing technique. *Int J Periodontics Restorative Dent.* 2016;36:275–280.

22. Calcaterra R, Di Girolamo M, Mirisola C, Baggi L. Expression of pattern recognition receptors in epithelial cells around clinically healthy implants and healthy teeth. *Implant Dent.* 2016;25:348–352.

23. Cassetta M, Di Mambro A, Giansanti M, Brandetti G, Calasso S. A 36-month follow-up prospective cohort study on peri-implant bone loss of Morse Taper connection implants with platform switching. *J Oral Sci.* 2016;58:49–57.

24. Degidi M, Iezzi G, Scarano A, Piattelli A. Immediately loaded titanium implant with a tissue-stabilizing/maintaining design ('beyond platform switch') retrieved from man after 4 weeks: a histological and histomorphometrical evaluation. A case report. *Clin Oral Implants Res.* 2008;19:276–282.