

Facial Alveolar Bone Width at the First and Second Maxillary Premolars in Healthy Patients: A Cone Beam Computed Tomography Study

Julio Rojo-Sanchis, DDS

Jose Viña-Almunia, DDS, PhD

David Peñarrocha-Oltra, DDS, PhD

Miguel Peñarrocha-Diago, MD, PhD*

The purpose of this study was to analyze the thickness of the facial alveolar bone at the first and second maxillary premolars and determinate the percentage of premolars that reached 2 mm in width. A retrospective study was performed, analyzing cone beam computed tomography scans from the database of the Oral Surgery Unit of the University of Valencia. Patients with periodontal disease, orthodontic treatment, absence among the first maxillary molars, premolars with endodontic treatment, or prosthetic restorations were excluded. The facial alveolar bone width was measured at 1, 2, 3, and 5 mm apical to the vestibular bone peak. A total of 44 patients were included in the study, with 72 first premolars and 72 second premolars analyzed. A descriptive analysis was performed and the normal means were assessed using the Kolmogorov-Smirnov test. The average width of the facial alveolar bone at first and second maxillary premolars was respectively: 1.41 ± 0.50 and 1.72 ± 0.56 at 1 mm, 1.68 ± 0.72 and 2.23 ± 0.66 at 2 mm, 1.71 ± 0.89 and 2.43 ± 0.82 at 3 mm, 1.44 ± 1.00 and 2.31 ± 1.06 at 5 mm from the vestibular bone peak. The facial alveolar bone width at the second maxillary premolars was greater than at the first maxillary premolars at all points measured. This information should be taken in account when planning immediate implants. Further studies are needed to analyze bone resorption at maxillary premolars to better understand facial alveolar bone width influence in implant treatment.

Key Words: facial bone thickness, alveolar crest, buccal bone, CBCT, premolars

INTRODUCTION

The alveolar process is a tooth-dependent structure, and its development is strictly connected to dental eruption.¹ It is well known that marked volumetric alterations occur at the edentulous site following tooth extraction; not only the facial alveolar bone (FAB) is reabsorbed but, in consequence, the buccal-lingual/palatal dimension is reduced.² Such resorption is related with the width of the FAB. When FAB width is <1 mm, a mean height loss of 7.5 mm has been observed after tooth extraction, while in the case of a width of ≥ 1 mm, the mean height loss was found to be 1.1 mm.³ Thus, the thickness of the FAB in the anterior maxilla is crucial for the selection of the appropriate implant treatment approach.⁴

Several studies using CBCT images have analyzed FAB of dentate patients at different levels below the alveolar bony crest.⁵⁻⁸ CBCT provides a highly accurate method to evaluate bone architecture.⁹ Most studies focus on measurements referred to the incisors and canines, but relatively few studies¹⁰⁻¹² analyze FAB width at the first and second premolar,

which also belong to the aesthetic zone. Authors who have measured anterior and posterior areas have reported a significant decrease in thickness from premolars to anterior teeth.^{4,11} The literature does not fully clarify the width of the FAB at the maxillary premolars. These values also vary according to the measurement method and the level below the bone crest at which measurement is carried out, but it seems that FAB at first maxillary premolars is thinner than that at second maxillary premolars.^{8,12} To our knowledge, no studies have focused on and analyzed the FAB width in detail at the first and second maxillary premolars.

The aim of the present study was to evaluate and compare the FAB width at the first and second maxillary premolars. A further aim was to analyze the percentage of first and second premolars in which the width of this cortical bone is greater than 2 mm.

MATERIAL AND METHODS

The study protocol was submitted to and approved by the Ethics Committee of the University of Valencia, Spain (procedure no. H145639215058). The CBCT images were retrospectively obtained from the database of the Unit of Oral Surgery in the University of Medicine and Odontology of Valencia. All

Department of Stomatology, Valencia University Medical and Dental School, Valencia, Spain.

* Corresponding author, e-mail: miguel.penarrocha@uv.es

DOI: 10.1563/aaid-joi-D-16-00195

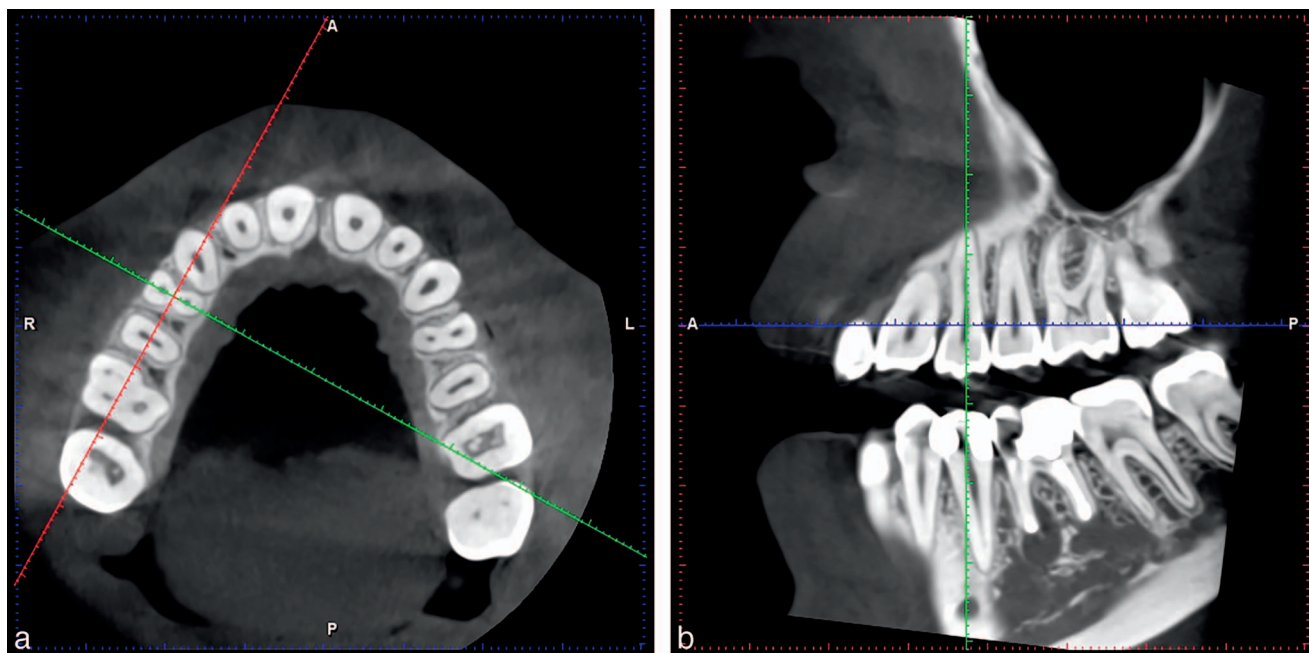


FIGURE 1. (a) Slice location in the axial plane was along the center of the premolar’s root, at the height of the bone ridge. (b) Slice location in the sagittal plane was along the long axis of the premolar’s root.

CBCT scans had been performed for diagnostic or treatment purposes between September 2014 and February 2016. None of the scans were made for purely scientific reasons.

Inclusion criteria

The subjects meeting the inclusion criteria were men and women between ages 18 and 60 years, with all teeth present from central incisors to first molars bilaterally, and who had no history of orthodontic treatment. In addition, the distance between cemento enamel junction (CEJ) and the vestibular bone peak at premolars was <3.5 mm.

Exclusion criteria

Patients with periodontal disease, orthodontic treatment, absence among the first maxillary molars, premolars with endodontic treatment, caries or prosthetic restorations were excluded.

Patient data collection

The following variables were collected for each patient using a predetermined study protocol: sex, age, smoking habits, and the reason for having the CBCT scan performed.

Radiographic image analysis

The CBCT images were acquired using Planmeca ProMax 3D (Helsinki, Finland) Software 2.3.1. R TM Planmeca Romexis with a voxel size of 150 mSv, 90 kV, 10.0 mA, and a field of view (FOV) of 4 × 4 cm. The scans were uni or bilateral depending on their diagnostic purpose. All images were analyzed with the same computer and same monitor (Eizo Nanao Flexscan with a resolution of 1280 × 1024 pixels). To detect the slice location to perform the measurements, we proceeded as follows: The alveolar crest was located at the axial plane, and a buccolingual

slice was traced at the middle of the root. Then, the long axis of the root was determined at the sagittal slice (Figure 1). The measurements from the CEJ to the vestibular bone peak and of the thickness of the FAB were performed at the coronal plane. In this sense, four measurements were then made parallel to this perpendicular line 1, 2, 3, and 5 mm apical to the vestibular bone peak (Figure 2).

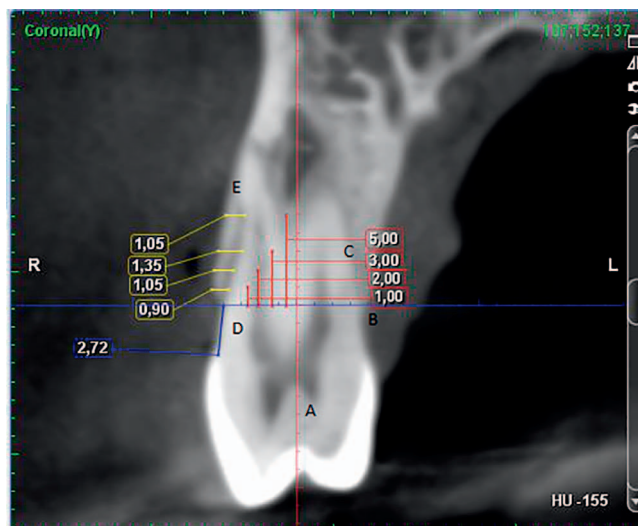


FIGURE 2. Measurements at the coronal slice. Line A: line of reference along the longitudinal axis of the premolar. Line B: line of reference perpendicular to the long axis of the premolar at the level of bone crest. Lines C: lines of reference 1, 2, 3, and 5 mm apical to the bone crest and parallel to line A. Line D: measurement from the CEJ to the vestibular bone peak. Lines E: measurements of the facial alveolar bone thickness, parallels to line B, and with reference to lines C.

TABLE 1

Sample description according first or second premolar, type of CBCT scan and its purpose and smoking habits*

Patients included in the study: 44										
First premolars	Second premolars	CBCT scans		CBCT purpose				Smokers		
		Unilateral	Bilateral	Palatally impacted canines	Impacted wisdom molars	Apical surgery	Implant planning	No	Light (≤ 10 cigarettes/day)	Heavy (> 10 cigarettes/day)
72	72	16	28	9	16	7	12	23	12	9

*CBCT indicates cone beam computerized tomography.

Statistical analysis

A descriptive analysis was made, based on the most relevant statistics: mean, standard deviation, maximum, minimum, and median. Statistical software used was Statistical Package for the Social Sciences, SPSS 15.0 (SPSS Inc, Chicago, Ill). The normality of the measures was assessed by means of the Kolmogorov-Smirnov test, obtaining a confirmatory result for most of the measures ($P > .05$).

The mean bone width and standard deviation per tooth and per patient were recorded based on 4 measurements at various depths. Measurements were compared between right maxillary first and second premolars, between left maxillary first and second premolars, and between all first and second maxillary premolars. The related measures t test was used for comparing means. The significance level used in the analysis was 5% ($\alpha = .05$), but Bonferroni's correction was applied to control the propagation of type I error. In that case, the reference level would be 0.004 ($= 0.05/12$, where 12 is the total number of contrasts). A t test had a power of 90% to detect a moderate effect ($d = .5$), which is equivalent to detecting a mean difference in bone width between first and second premolars of 0.35 mm with a standard deviation of ± 0.70 mm.

RESULTS

Sample description

The study population consisted of 44 patients, 25 men and 19 women between ages 18 and 60 years. Nine patients were heavy smokers (> 10 cigarettes/day), 12 were light smokers (≤ 10 cigarettes/day), and 23 were nonsmokers.

Sixteen CBCT scans were unilateral and 28 were bilateral. Thus, a total of 72 upper first premolars and 72 upper second premolars were analyzed (Table 1).

Radiographic outcomes

The mean distance between the CEJ and the vestibular bone peak was 2.34 ± 0.82 (0.95–3.5 mm) at the first premolars and 1.82 ± 0.72 (0.62–3.48 mm) at the second premolars, with a statistically significant difference ($P < .001$).

The FAB width at the 4 levels below the vestibular bone crest (1, 2, 3, and 5 mm) for first and second maxillary premolars is reported in Table 2 and Figure 3. All comparisons showed statistically significant differences with higher values at the second premolar.

Moreover, most of second premolars reached 2 mm FAB

TABLE 2

FAB of all first and second premolars at 1, 2, 3, and 5 mm apical distance from the vestibular bone peak†

Distance from the bone peak	Premolar	Mean (SD; range)			t test (P -value)
		Left ($n = 35$)	Right ($n = 37$)	Whole sample ($n = 72$)	
1 mm	First	1.39 (0.51; 0.62–3.3)	1.43 (0.49; 0.45–3)	1.41 (0.5; 0.45–3.3)	Left: .003** Right: .002** Whole sample: $< .001$ ***
	Second	1.68 (0.52; 0.9–3.3)	1.76 (0.59; 0.75–4.06)	1.72 (0.56; 0.75–4.06)	Left: $< .001$ *** Right: $< .001$ *** Whole sample: $< .001$ ***
2 mm	First	1.68 (0.7; 0.47–3.9)	1.68 (0.74; 0.6–3.63)	1.68 (0.72; 0.47–3.9)	Left: $< .001$ *** Right: $< .001$ *** Whole sample: $< .001$ ***
	Second	2.22 (0.56; 1.20–4.05)	2.25 (0.75; 0.75–4.66)	2.23 (0.66; 0.75–4.66)	Left: $< .001$ *** Right: $< .001$ *** Whole sample: $< .001$ ***
3 mm	First	1.70 (0.85; 0.45–4.05)	1.72 (0.93; 0.45–3.93)	1.71 (0.89; 0.45–4.05)	Left: $< .001$ *** Right: $< .001$ *** Whole sample: $< .001$ ***
	Second	2.48 (0.75; 0.45–4.5)	2.37 (0.9; 0.6–4.51)	2.43 (0.82; 0.45–4.51)	Left: $< .001$ *** Right: $< .001$ *** Whole sample: $< .001$ ***
5 mm	First	1.39 (0.84; 0.3–4.05)	1.5 (1.13; 0.3–5.25)	1.44 (1.00; 0.3–5.25)	Left: $< .001$ *** Right: $< .001$ *** Whole sample: $< .001$ ***
	Second	2.39 (1.06; 0.3–5.85)	2.23 (1.06; 0.6–4.51)	2.31 (1.06; 0.3–5.85)	Left: $< .001$ *** Right: $< .001$ *** Whole sample: $< .001$ ***

* $P < .05$.** $P < .01$.*** $P < .001$.

†FAB indicates facial alveolar bone.

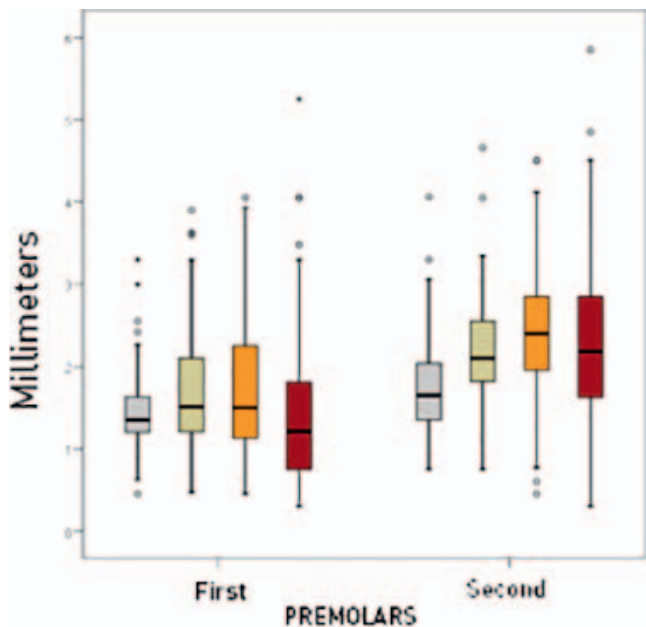


FIGURE 3. Graphic of facial alveolar bone thickness of all maxillary premolars at the different levels under the bone crest.

width, while very few of the first premolars analyzed reached it. Data are reported in Table 3.

DISCUSSION

The main purpose of this study was to analyze and compare the FAB width at different locations apical to the CEJ of the first and second maxillary premolars and to determine the percentage of cases in which the width reached 2 mm.

This study describes the mean FAB thickness observed in a sample of 44 patients with healthy dentition. The FAB width was greater at the second premolars, and a width of at least 2 mm was more frequently observed at second premolars. Another finding of the present study refers to the distance from the CEJ to the bone crest, which was significantly greater in the case of the first premolars. These results are in line with those reported in the literature. A recent study⁸ analyzed CBCT images of 3618 teeth including incisors, canines, premolars, and first molars. The mean FAB width at anterior teeth was 0.9 mm and increased towards distal regions. Only 1.8% of anterior teeth reached 2 mm in width. The results of those studies that

have measured FAB width at the first and second maxillary premolars have reported increased thickness at the second premolar compared with the first premolar.^{10,12} These results possibly could be explained by the fact that the first premolar usually has two roots and is located in a more anterior zone where the alveolar ridge is usually thinner, while the second premolar usually has just one root and is located in a more posterior zone where the alveolar ridge tends to widen.

In recent years, thin cortical thickness has been linked to height loss after tooth extraction in the maxillary anterior regions. Many authors agree that the FAB width should be at least 2 mm wide if the alveolar bone level on the facial aspect is to be maintained after tooth extraction.^{13,14} Also, some studies have found a positive correlation between gingival thickness and FAB width.¹⁵⁻¹⁷

It is important to note that the data in our study were based on the dimensions of sockets in a “healthy” situation. The socket dimensions around diseased teeth may be very different from those reported herein.

A finite element study has assessed the impact of the implant design and dimensions and FAB width upon the peri-implant stress. The authors concluded that the most important factor was implant FAB.¹⁸ The study of FAB width before extraction is a key factor to predict the bone loss and to avoid implant treatment complications.

CONCLUSION

Within the limitations of our study, the results obtained suggest that FAB width at the second maxillary premolars is greater than at the first maxillary premolars. At 2 mm below the bone crest, most of the second maxillary premolars showed a FAB width of at least 2 mm, while very few first premolars reached this value.

ABBREVIATIONS

- CBCT: cone beam computed tomography
- CEJ: cementoamel junction
- FAB: facial alveolar bone
- FOV: field of view

NOTE

The authors declare no conflicts of interest related to the present study.

REFERENCES

1. Barone A, Toti P, Piattelli A, Iezzi G, Derchi G, Covani U. Extraction socket healing in humans after ridge preservation techniques: comparison between flapless and flapped procedures in a randomized clinical trial. *J Periodontol.* 2014;85:14–23.
2. Ferrus J, Cecchinato D, Pjetursson EB, Lang NP, Sanz M, Lindhe J. Factors influencing ridge alterations following immediate implant placement into extraction sockets. *Clin Oral Implants Res.* 2010;21:22–29.
3. Chappuis V, Engel O, Reyes M, Shahim K, Nolte LP, Buser D. Ridge alterations post-extraction in the esthetic zone: a 3D analysis with CBCT. *J Dent Res.* 2013; 92:1955–2015.

TABLE 3

Percentage of premolars that reached a FAB width of 2 mm*

Premolars that reached 2 mm width		
Distance from the bone peak	First (%)	Second (%)
1 mm	11.36	56.81
2 mm	25	70.83
3 mm	30.55	79.16
5 mm	20.83	76.30

*FAB indicates facial alveolar bone.

4. Braut V, Bornstein MM, Belser U, Buser D. Thickness of the anterior maxillary facial bone wall—a retrospective radiographic study using cone beam computed tomography. *Int J Periodontics Restorative Dent*. 2011;31:125–131.
5. Lee SL, Kim HJ, Son MK, Chung CH. Anthropometric analysis of maxillary anterior buccal bone of Korean adults using cone-beam CT. *J Adv Prosthodont*. 2010;2:92–96.
6. Tian YL, Liu F, Sun HJ, et al. Alveolar bone thickness around maxillary central incisors of different inclination assessed with cone-beam computed tomography. *Korean J Orthod*. 2015;45:245–252.
7. Huynh-Ba G, Pjetursson BE, Sanz M, Cecchinato D, Ferrus J, Lindhe J, Lang NP. Analysis of the socket bone wall dimensions in the upper maxilla in relation to immediate implant placement. *Clin Oral Implants Res*. 2010;21:37–42.
8. Zekry A, Wang R, Chau AC, Lang NP. Facial alveolar bone wall width – a cone-beam computed tomography study in Asians. *Clin Oral Implants Res*. 2014;25:194–206.
9. Wood R, Sun Z, Chaudhry J, et al. Factors affecting the accuracy of buccal alveolar bone height measurements from cone-beam computed tomography images. *Am J Orthod Dentofacial Orthop*. 2013;143:353–363.
10. Jin SH, Park JB, Kim N, et al. The thickness of alveolar bone at the maxillary canine and premolar teeth in normal occlusion. *J Periodontal Implant Sci*. 2012;42:173–178.
11. Wang HM, Shen JW, Yu MF, Chen XY, Jiang QH, He FM. Analysis of facial bone wall dimensions and sagittal root position in the maxillary esthetic zone: a retrospective study using cone beam computed tomography. *Int J Oral Maxillofac Implants*. 2014;29:1123–1129.
12. Vera C, De Kok IJ, Reinhold D, et al. Evaluation of buccal alveolar bone dimension of maxillary anterior and premolar teeth: a cone beam computed tomography investigation. *Int J Oral Maxillofac Implants*. 2012;27:1514–1519.
13. Nowzari H, Molayem S, Chiu CH, Rich SK. Cone beam computed tomographic measurement of maxillary central incisors to determine prevalence of facial alveolar bone width ≥ 2 mm. *Clin Implant Dent Relat Res*. 2012;14:595–602.
14. Fuentes R, Flores T, Navarro P, Salamanca C, Beltrán V, Borie E. Assessment of buccal bone thickness of aesthetic maxillary region: a cone-beam computed tomography study. *J Periodontal Implant Sci*. 2015;45:162–168.
15. Younes F, Eghbali A, Raes M, De Bruyckere T, Cosyn J, De Bruyn H. Relationship between buccal bone and gingival thickness revisited using non-invasive registration methods. *Clin Oral Implants Res*. 2016;27:523–528.
16. Khoury J, Ghosn N, Mokbel N, Naaman N. Buccal bone thickness overlying maxillary anterior teeth: a clinical and radiographic prospective human study. *Implant Dent*. 2016;25:525–531.
17. Okumura N, Stegaroiu R, Kitamura E, Kurokawa K, Nomura S. Influence of maxillary cortical bone thickness, implant design and implant diameter on stress around implants: a three-dimensional finite element analysis. *J Prosthodont Res*. 2010;54:133–142.