

Short Versus Longer Implants in Mandibular Alveolar Ridge Augmented Using Osteogenic Distraction: One-Year Follow-up of a Randomized Split-Mouth Trial

Sara Bernardi, DDS, PhD^{1*}
 Roberto Gatto, MD¹
 Marco Severino, DDS, PhD¹
 Gianluca Botticelli, DDS²
 Silvia Caruso, DDS¹
 Claudio Rastelli, DDS¹
 Ettore Lupi, MD³
 Adolfo Quiroz Roias, DDS⁴
 Enzo Iacomino, MD⁵
 Giovanni Falisi, DDS, PhD¹

The aim of this study was to evaluate the reliability of 6-mm-long implants compared with normal-length implants placed in a vertical augmented atrophic posterior mandible, supporting cemented single crowns. Thirty-six patients with bilateral posterior edentulous mandible and presenting a bone availability height less than 9 mm from the mandibular canal were enrolled in this study. Patient hemiarches were randomized to receive both 6-mm-long and normal-length implants (10 mm). The technique used for the vertical bone augmentation was the “sandwich” technique, using a bone substitute block as graft. The data outcomes at 1 year postloading follow-up were the loss of implants and complications. Eighty-six 6-mm-long implants and 84 normal implants were inserted. Five short implants and 13 normal implants were lost. In 28 patients, complications occurred, and in 21 cases, the complication was present on the side of the ridge vertical augmentation. From the statistical analysis, the association between the side of the ridge augmentation and the side of occurrence of the complication was statistically significant ($P < .05$). The results from this trial suggest short implants can be preferred over vertical bone augmentation for the placement of longer implants in the rehabilitation of edentulous posterior mandibles. These initial results must be confirmed by larger and longer follow-ups of 5 years or more.

Key Words: atrophic posterior mandible, vertical bone augmentation, short implants, RCTs

INTRODUCTION

Oral diseases and traumatic injuries involving the periodontal and dental tissues can lead to tooth loss with consequent atrophy of the alveolar bone of the jaws. Although a removable prosthesis is a low-risk solution, the mobility of the device often represents a discomfort that patients do not appreciate or tolerate. Indeed, excessive bone loss causes improper denture retention and consequent instability during normal daily oral functions, such as masticatory and phonatory acts.¹ Fixed rehabilitation on implants can reach high success levels,² but rehabilitating

atrophic jaws can be challenging, especially when the bone defect is wide.³ The resorption of the available bone leads the alveolar crest close to the noble anatomical structures (maxillary sinus and alveolar nerve) in the superior and inferior jaws. In classical implant dentistry, a minimal bone height between 10 and 12 mm is required to insert a 9–11 mm length implant.⁴ This particular length is considered one of the factors in achieving a long and favorable prognosis. After tooth loss, the alveolar bone tends to collapse and undergo a resorption process. Even with modern guided bone regeneration techniques, implant placement in a jaw with a low bone level is not predictable.⁵

The therapeutic options that are available nowadays for implant supported-prosthesis are the following³:

1. bone augmentation procedures such as osteogenic distraction,
2. use of zygomatic implants in case of maxillary jaws, and
3. use of so-called short implants, meaning fixtures with a length from 4 to 8 mm.

¹ Department of Life, Health and Environmental Sciences, University of L'Aquila, L'Aquila, Italy.

² Private practice, L'Aquila, Italy.

³ Maxillofacial Division, San Salvatore Hospital, L'Aquila, Italy.

⁴ Universidad Autonoma Gabriel Rene Moreno, Santa Cruz, Bolivia.

⁵ ENT Division, San Salvatore Hospital, L'Aquila, Italy.

* Corresponding author, e-mail: sara.bernardi@univaq.it

DOI: 10.1563/aaid-joi-D-16-00216

Augmentation surgical techniques are technically demanding, depending on the operator's skills; are associated with significant postoperative morbidity and complications; can be expensive; and may require longer times (up to 1 year) for prosthetics loading.⁶

The definition of "short" implants is still controversial: some authors consider short implants to have a length ranging between 7 and 10 mm, and others consider short those fixtures with an intrabony length of 8 mm or less than 9 mm.⁷

Because of the higher demands from edentulous patients for a fixed prosthodontics solution that lowers the surgical risks, the reliability of short implants as an alternative has been questioned through the years. Several systematic reviews and meta-analyses have examined these issues, and a need for additional clinical trials on the use of short implants in fixed-prosthodontic rehabilitation emerged.

The aim of this randomized split-mouth trial is to compare the implant survival rate of short implants (intrabony length of 6 mm) with the implant survival rate of longer, "normal" implant (intrabony length of 10 mm), placed in the vertical mandibular alveolar ridge in posterior atrophic mandibles. Complications and occurrence of side effects are considered.

MATERIALS AND METHODS

This trial was designed as a randomized trial of split-mouth design. The justifying reason in choosing a split-mouth design is that it yielded a more efficient comparison of treatments than a parallel design, providing a consistent number of test and control samples.⁸

The protocol has been approved by the University of L'Aquila Ethical Committee, protocol 38534. All patients were informed regarding the nature of the study and their participation, and written consent was granted by every participant according to the Helsinki Declaration of 1994.

Patient selection

Thirty-six patients attending the dental clinic of the University of L'Aquila were enrolled in the study.

The following inclusion criteria were adopted:

- 18 years or older
- Able to understand and sign an informed consent form
- No sign of facial trauma
- Presenting good oral hygiene (score of 0 or 1 according to the Simplified Oral Hygiene Index⁹),
- High compliance with oral hygiene
- Presenting a posterior bilateral edentulous mandible, with bone height quantity less than 9 mm

Exclusion criteria were:

- Patients who did not consent to join the experimental procedure
- Patients with a low grade of compliance
- Patients lacking in general good health, degrees 3 and 4 referring to American Society of Anesthesiologists physical classification system

- Patients with poor oral hygiene (score of 2 to 3 according to the Simplified Oral Hygiene Index⁹)
- Patients with bone availability height greater than 9 mm
- Patients on bisphosphonate therapy

Implant and graft material information

The normal long implant (10 mm, ConicalActive, Maco Dental Care, Salerno, Italy) presented a surface of titanium pure grade 4. The locking taper connection is a connection with a screw and internal hexagon, and the system profile is cylindrical-conical. The diameter used was 3.90 mm.

The short implant (6-mm long, IM Macon, Maco Dental Care) presented the same surface type as the "normal" ones. The connection was Morse taper type. The diameter used was 4.10 mm.

The graft material used was the bone block graft SP Block TecnoSS S.r.l. (Giaveno, Italy) of dimension 10 × 10 × 20 mm.

The prostheses were single crown cemented type. The data were analyzed at 1-year postloading follow-up.

Randomizing method

The patients were randomized with a simple sequence of list randomization. For each patient, the decision of whether to use the left or right side of the mandible as the test site (ie, short implant used) or the site of surgical bone augmentation was selected by flipping a coin and depending on the day of the surgery, described as follows.

If the side of the coin was head, the treatment would be a short implant placement, and if the day was an odd day, the side would be the right one.

Because of the surgical procedure, the blindness of the patients was not guaranteed, but the data blindness evaluation was guaranteed, since the researcher evaluator was different from the treating physician.

Surgical procedure: Placement of short implants and normal-length implants

All of the patients underwent professional oral hygiene sessions 3 days before any surgical interventions, whether undergoing the implant placement or the surgical bone augmentation procedure. Antibiotic prophylaxis was prescribed before any surgical procedure. For implant placement, the sequence of surgical drilling strictly complied with that provided by the manufacturing company. Sutures were removed after 7 days.

After the surgery, a sheet with postoperative instructions was provided to the patients. The instructions included the following:

- continue antibiotic prophylaxis,
- consume routine painkillers if necessary,
- bed rest with head elevated at about 30° and apply ice to avoid/decrease the swelling for the 24/48 hours after the surgery, and
- brush the teeth as usual as well as gently cleaning the surgical area.

Surgical bone augmentation procedure

The procedure used for the surgical bone augmentation followed the “sandwich technique.”¹⁰ The surgical protocol illustrated in this study included the expansion of the posterior mandibular alveolar crest of severe vertical atrophy conditions, characterized by a remaining height of 6 mm (Figure 1).

The preparation of the patients was the same as previously mentioned.

The osteotomies were performed by means the piezoelectric handpiece, which enables a more precise osteotomy line selective for the bone than traditional rotating instruments, resulting in maximum savings of bone tissue. The piezoelectric osteotomy is also characterized by reduced exposure of the operating field with minimal dissection and the selective cutting protects any type of soft tissue¹¹ increasing postoperative comfort in terms of edema and maintaining the vascularization of the cranial fragment, thus limiting the reabsorption. The first phase of surgery was represented by an incision horizontal of the vestibular mucosa in the free gingiva, compatible with the emergence of the inferior alveolar nerve. The second phase consisted with the detachment of the mucoperiosteal plans limited to the vestibular side, paying particular attention to saving the alveolar ridge in the area of surgical interest. Subsequently, using the piezo-handpiece, the surgical site was submitted to a partial osteotomy performing incisions in the vertical and horizontal direction, giving it a “drawer” shape. The osteotomy included the crest region to expand, preserving the cortical region of the tongue. The fragment previously osteotomized was then fractured to “green wood” type, and the alveolar ridge was expanded to “hinge” of about 5 mm. After the grafting stage, the stabilization of the fragments into the surgical site was reached through the use of a microplate fixed through microscrews titanium. The last step of the surgical procedure involved the surgical site closure with absorbable suture. After a reasonable period of healing (6 months), implants were placed.

Radiologic assessment

Following the last guidelines released from the European Association for Osseointegration, the radiologic assessment included the tridimensional evaluation of the anatomical condition to plan the surgery^{12,13} and the use of the orthopantomograph technique for the follows-up.¹⁴ Thus, each patient underwent a computerized tomography study prior to the first surgery, whether undergoing short implant placement or the augmentation. After each surgical operation, success was verified by means of orthopantomographs. A final orthopantomogram at 1-year follow-up was made to verify the status of the implants.

Statistical analysis

The variables considered from a statistical point of view were:

- The loss of normal implants
- The loss of short implants
- The side of the vertical augmentation
- The side where the complication raised

These variables were inserted in contingency tables and analyzed with association measures. The statistics measurements were performed using SAS University Edition software.¹⁵

RESULTS

At 1-year final follow-up, the collected data were inserted in a Excel spreadsheet to be statistically processed.

As stated in the “Materials and Methods” section, the statistical analysis of the data followed a preestablished plan. Each implant was considered as a statistical unit. The level of significance was set at the .05 level. The statistical results were reviewed by an independent statistician.

Demographic data

The 36 enrolled patients ranged in age from 43 to 77 years. Eighteen were female, and 18 were male (Table 1).

Short implants outcomes

Eighty-six short implants were placed, and 5 were lost for lack of primary stability ($n = 1$) and infections ($n = 4$). Forty-three implants were placed on the right side and 43 on the left side of the mandibles. Three patients experienced complications (paresthesia) on the side of the short implants placement (Figure 2).

Normal implant with surgical augmentation procedure outcomes

Thirty-six augmentation procedures were performed. Eighty-four normal implants were placed, and 13 were lost due to lack of primary stability ($n = 3$) and site infection ($n = 10$). Forty-five implants were inserted on the right side and 39 on the left side. Twenty-two patients experienced complications on the side of the ridge vertical augmentation. Nevertheless, with the use of a piezoelectric handpiece, the main complication experienced by the patients was paresthesia, a sign of a little touch of the alveolar inferior canal (Figure 2).

The representative orthopantomograms of an enrolled patient from the initial situation (Figure 3) to the implant placement (Figure 4) and to the 1-year follow-up (Figure 5) showed the good results obtained using both short and normal implants.

The intraoral radiographs at 1-year follow-up (Figure 6) confirm the good marginal level of the alveolar bone.

Statistical analysis

Statistical analysis was performed using SAS University Edition software.¹⁵ The Pearson chi-squared test on the contingency table comparing the side where the complication was raised and the side of the surgical augmentation procedure resulted in statistical significance, with a P value $< .05$, showing an association between the 2 variables (Table 2). Since the chi-squared test was not completely trustable, because 67% of the cells had expected counts less than 5, Fisher exact test was performed, confirming the significance of the association (Table 3).

The same statistical procedures had to be applied on the contingency tables comparing the loss of the normal-length

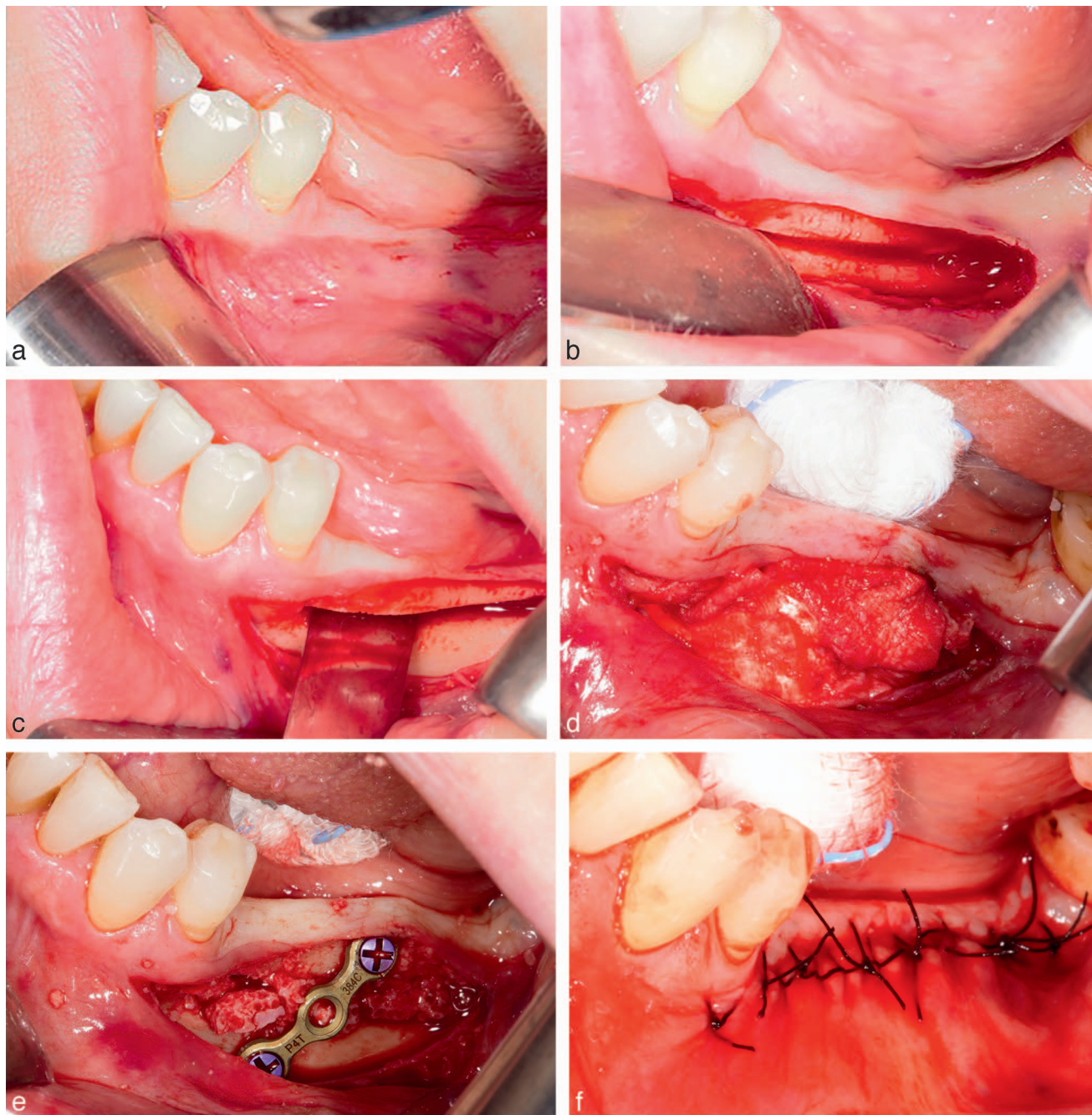


FIGURE 1. Surgical intervention. (a) Preoperative situation. (b) Horizontal osteotomy. (c) “Green wood” type fracture. (d) Grafting procedure. (e) Stabilization of the fragments into the surgical site by means of a microplate fixed through microscrews titanium. (f) Suture.

	n
Male	18
Female	18
Mean age (range) at implant insertion, y	62 (43–77)

Side of Vertical Ridge Augmentation Procedure	Side Where Complication Arose		Pearson Chi-Squared Test
	Dx	Sx	
Dx	13	1	$P = 8.84 \times 10^{-5}$
Sx	1	8	

*Dx indicates right side; Sx, left side.

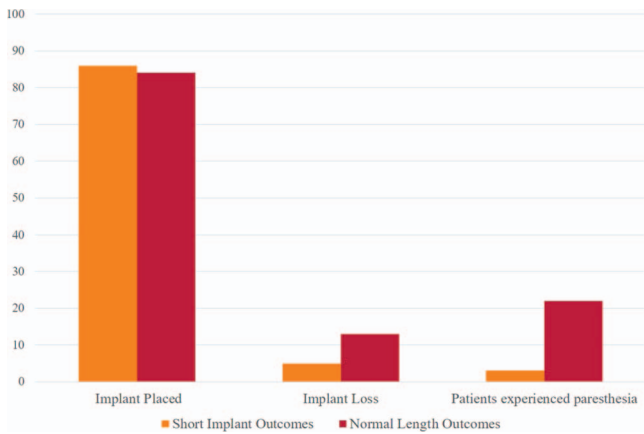
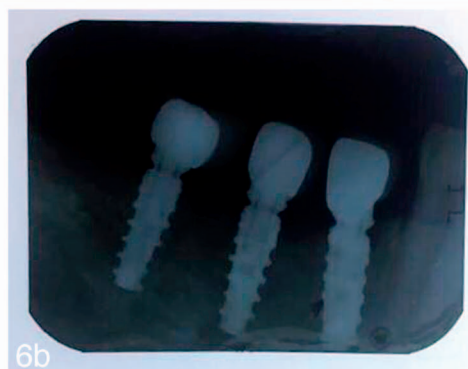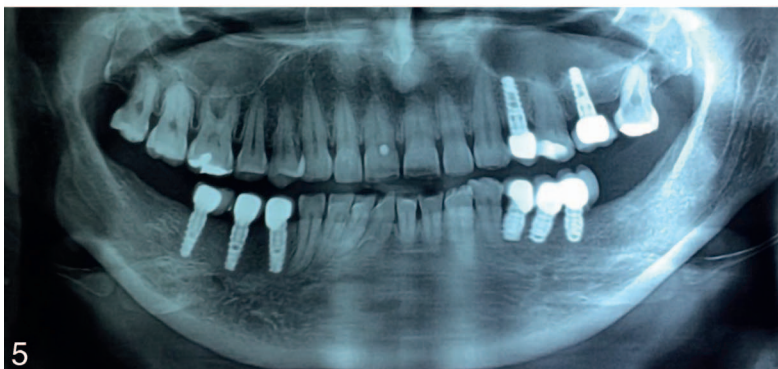
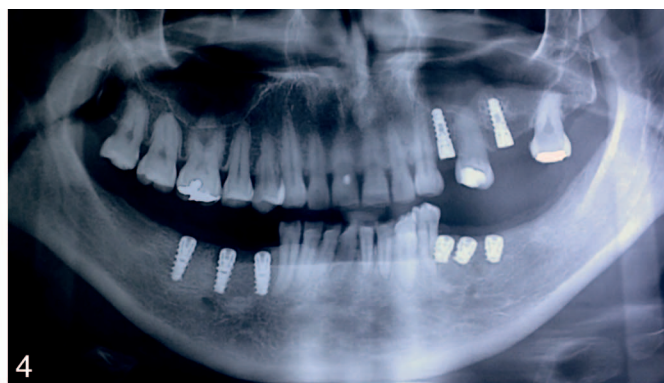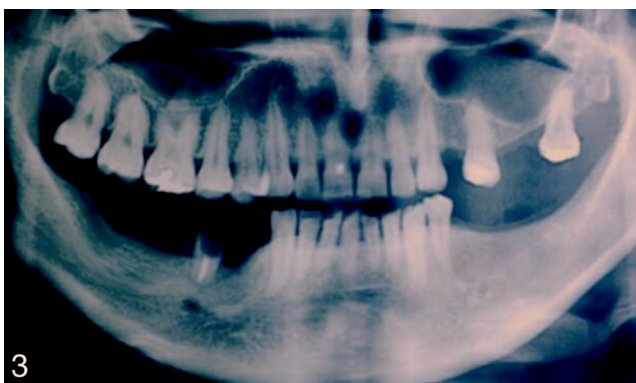


FIGURE 2. Informal representations of the short and normal implants outcomes.

implants and the side where the complication arose (Tables 4 and 5) and on the contingency table comparing the loss of the normal and the short implants (Tables 6 and 7). The association measures showed a *P* value >.05 and therefore were not statistically significant.

DISCUSSION

If the total loss of the normal long implant was low, the morbidity and complication rate was higher compared with the short implant outcomes. The causes of implant lost were similar in both groups. All these considerations are in perfect agreement with the data reported so far in the literature supporting the theory that the mandibular vertical bone augmentation procedures are demanding, highly susceptible to infection and postoperative complications because of their



FIGURES 3–6. **FIGURE 3.** Representative postoperative orthopantomography. **FIGURE 4.** Postoperative orthopantomography. **FIGURE 5.** One-year follow-up orthopantomography. **FIGURE 6.** Intraoral radiographs. (a) The short implants and (b) the normal-length implants. Both groups show good bone level on the margin of the implant.

TABLE 3

Contingency table comparing the frequency of the side where the vertical ridge augmentation procedures was performed and the side where the complications arose and the results of Fisher exact tests, including the 95% confidence interval and the odd ratio values*

Side of Vertical Ridge Augmentation Procedure	Side Where Complication Arose		Fisher Exact Test	95% CI	OR
	Dx	Sx			
Dx	13	1	$P = 1.55 \times 10^{-4}$	4.25–4694.29	65.55
Sx	1	8			

*Dx indicates right side; Sx, left side.

intrinsic nature⁵ and high microbial load present in the oral cavity,^{16–18} as well as extremely uncomfortable for the patients. The success of mandibular vertical ridge augmentation often relies on the clinical skills and experience of the operator as well as the anatomical difficulties of an atrophic alveolar site. Consequently, the vertical ridge augmentation is technically difficult to perform. Instead, following a specific protocol and the improvement of the bone-implant contact surface can lead to a more predictable result.

From a recent systematic review and meta-analysis by Nisand et al,¹⁹ it can be concluded that there is a similar trend in terms of survival rate of short implants and longer implants placed in vertical augmented mandibles, but the number of longer implants lost was slightly higher than the number of lost short implants.

In addition, it was pointed out that a significant increase in complications was experienced in patients who underwent the grafting procedure despite the experience of the involved surgeon. This concept, confirmed by our results, raised the question of the feasibility and the generalizability of this approach in daily clinical practice.¹⁹

Beyond these considerations, the biological basis of the vertical ridge augmentation in the mandible does not favor the results.^{20,21} The nature of the cortical bone and the blood supply seem to play fundamental roles in determining whether such a graft can be maintained in situ. Thus, the future resorption is unpredictable.²²

From this point of view, the sandwich technique seems quite adequate since the bone distraction provides a quite good blood supply to the graft integration.²³ The technique, used in the present study, has a quite low risk of total loss of the normal implants. Nevertheless, the sandwich technique is a

vertical bone augmentation and is thus susceptible to the related complications that vertical bone augmentation procedures have. They are more susceptible to the dislocation of the graft, infection, neurologic and vascular complications, and problems at the donor sites,²⁴ as reported in our results.

Over the years, the survival rate and success rate of short implants have been studied in order to reach a compromise for the supported fixed prosthetic implant. Indeed, at the beginning, the ratio of the length of the crown to implant was considered unfavorable, pushing the studies of the ratio crown-root in natural teeth for a computer-aided design/computer-aided manufacturing implant design.^{25,26} The improvement of the total surface bone contact, the study of the forces distribution on the fixture, and the successes in the clinical trials strongly suggest the use of short implants when bone is not available or when bone augmentation cannot be performed.^{7,27–30}

In particular, in a 2006 systematic review, das Neves et al²⁰ started to assess the success rate of short implants in longitudinal studies and found that the use of a 3.75- × 7-mm implant was successful. In our study, the diameter in the short implants was chosen according the principle in the das Neves et al systematic review,²⁰ reaching a compromise with the available bone horizontal width. The numerous randomized controlled trials (RCTs) by Esposito et al^{31–33} with the related updates and follow-up supported the therapeutic efficacy in terms of survival rate and marginal bone loss of the short implants vs the longer implants placed in the vertical augmented atrophic mandible, recommending use of a wide diameter (up to 6 mm) with short implant length of 5 mm.

One limitation of our study is the trial design: the crossover design is indeed not widely accepted, but since there are no

TABLE 4

Contingency table comparing the frequency of the side where the complications raised and the frequency of normal implant loss and results of the Pearson-chi squared test*

Normal Implant Loss	Side Where Complication Arose		Pearson Chi-Squared Test
	Dx	Sx	
No loss	10	4	$P = .07207$
Loss	3	6	

*Dx indicates right side; Sx, left side.

TABLE 5

Contingency table comparing the frequency of the side where the complications arose and the frequency of normal implant loss and results of the Fisher exact test, including the 95% confidence interval and odd ratio values*

Normal Implant Loss	Side Where Complication Arose		Fisher Exact Test	95% CI	OR
	Dx	Sx			
No loss	10	4	$P = .1023$	0.466–31.14	3.39
Loss	3	6			

*Dx indicates right side; Sx, left side.

TABLE 6

Contingency table comparing the presence/absence of short and normal implants at the 1-year follow-up using Pearson chi-squared test*

Short Implants	Normal Implants		Pearson Chi-Squared Test
	Presence	Lost	
Presence	23	9	$P = .3706$
Lost	2	2	

*The variables were transformed in dichotomic variables for statistical purpose. Dx indicates right side; Sx, left side.

drugs to test and surgical procedures always need quite high numbers of patients to be better assessed, the choice of crossover trial is justified. Another limitation of our study is the lack of data regarding the marginal bone level.

Since RCTs regarding the use of short implants are always needed, the data reported support the concept that short implants are to be preferred when the height of the bone does not allow the placement of normal long fixtures. These data will need to be updated with future follow-ups. However, more RCTs are necessary to better assess the protocols and the efficacy of the short implants in prosthetics therapy.

CONCLUSION

Both assessed techniques provided good and similar outcomes up to 1 year after loading. In addition, the short implant type can represent a preferable therapeutic choice to vertical bone augmentation for the placement of longer implants, because of the offered advantages in time, morbidity, and economics.

ABBREVIATION

Dx: right side
 RCT: randomized controlled trial
 Sx: left side

ACKNOWLEDGMENTS

The authors are grateful to Maco Dental Care for the contribution in providing the implants and to TECNOSS for providing the graft material. We are also grateful to Professor

TABLE 7

Contingency table comparing the frequency of the side where the complications arose and the frequency of normal implant loss and results of the Fisher exact test, including the 95% confidence interval and odd ratio values*

Short Implants	Normal Implants		Fisher Exact Test	95% CI	OR
	Presence	Lost			
Presence	23	9	$P = .5705$	0.15–39.23	2.48
Lost	2	2			

*The variables were transformed in dichotomic variables for statistical purpose.

Maurizo Maravalle for statistical support and for help in improving the presentation of results.

NOTE

Maco Dental Care (Salerno, Italy) partially supported this trial and donated the implants; however, the data belong to the authors and by no means did Maco Dental Care interfere with the conduct of the trial or the publication of the results.

REFERENCES

- Nikolovska J, Petrovski D, Petricevic N, Kapusevska B, Korunoska-Stevkovska V. Overdentures on implants for better quality of life among the fully edentulous patients—case reports. *Pril (Makedonska Akad na Nauk i Umet Oddelenie za Med Nauk)*. 2015;36:225–234.
- D’Ercole S, Tripodi D, Marzo G, et al. Microleakage of bacteria in different implant-abutment assemblies: an in vitro study. *J Appl Biomater Funct Mater*. 2015;13:e174–e180.
- Esposito M, Barausse C, Pistilli R, Sammartino G, Grandi G, Felice P. Short implants versus bone augmentation for placing longer implants in atrophic maxillae: one-year post-loading results of a pilot randomised controlled trial. *Eur J Oral Implantol*. 2015;8:257–268.
- Mish E CAH. *Contemporary Implant Dentistry*. St Louis, Mo: Mosby Elsevier; 2008.
- Draenert FG, Kämmerer PW, Berthold M, Neff A. Complications with allogeneic, cancellous bone blocks in vertical alveolar ridge augmentation: prospective clinical case study and review of the literature. *Oral Surg Oral Med Oral Pathol Oral Radiol*. 2016;122:e31–e43.
- Felice P, Piana L, Checchi L, Corvino V, Nannmark U, Piattelli M. Vertical ridge augmentation of an atrophic posterior mandible with an inlay technique and cancellous equine bone block: a case report. *Int J Periodontics Restorative Dent*. 2013;33:159–166.
- Al-Hashedi AA, Taiyeb Ali TB, Yunus N. Short dental implants: an emerging concept in implant treatment. *Quintessence Int*. 2014;45:499–514.
- Mills EJ, Chan A-W, Wu P, Vail A, Guyatt GH, Altman DG. Design, analysis, and presentation of crossover trials. *Trials*. 2009;10:27.
- Greene JC, Vermillion JR. The simplified oral hygiene index. *J Am Dent Assoc*. 1964;68:7–13.
- Schettler D, Holtermann W. Clinical and experimental results of a sandwich-technique for mandibular alveolar ridge augmentation. *J Maxillofac Surg*. 1977;5:199–202.
- Lambrecht JT. Intraoral piezo-surgery [in French, German]. *Schweizer Monatsschr Zahnmed*. 2004;114:28–36.
- Bernardi S, Mummolo S, Ciavarelli LM, Li Vigni M, Continenza MA, Marzo G. Cone beam computed tomography investigation of the antral artery anastomosis in a population of Central Italy. *Folia Morphol (Warsz)*. 2016;75:149–153.
- Bernardi S, Bianchi S, Continenza MA, Macchiarelli G. Frequency and anatomical features of the mandibular lingual foramina: systematic review and meta-analysis. *Surg Rad Anat*. 2017;39:1349–1357.
- Harris D, Horner K, Gröndahl K, et al. E.A.O. guidelines for the use of diagnostic imaging in implant dentistry 2011. A consensus workshop organized by the European Association for Osseointegration at the Medical University of Warsaw. *Clin Oral Implants Res*. 2012;23:1243–1253.
- Der G, Everitt B. *Essential Statistics Using SAS University Edition*. 1st ed. Cary, NC: SAS Institute Inc; 2015.
- Bernardi S, Marzo G, Continenza MA. Dorsal lingual surface and halitosis: a morphological point of view. *Acta Stomatol Croat*. 2016;50:151–157.
- Bernardi S, Zeka K, Mummolo S, Marzo G, Continenza MA. Development of a new protocol: a macroscopic study of the tongue dorsal surface. *Ital J Anat Embr*. 2013;118(s2):24.
- Bernardi S, Bianchi S, Botticelli G, et al. Scanning electron microscopy and microbiological approaches for the evaluation of salivary microorganisms behaviour on anatase titanium surfaces: in vitro study. *Morphologie*. 2018;102(336):1–6.
- Nisand D, Picard N, Rocchieta I. Short implants compared to

implants in vertically augmented bone: a systematic review. *Clin Oral Implants Res.* 2015;26:170–179.

20. das Neves FD, Fones D, Bernardes SR, do Prado CJ, Fernandes Neto AJ. Short implants: an analysis of longitudinal studies. *Int J Oral Maxillofac Implants.* 2006;21:86–93.

21. Bernardi S, Mummolo S, Tecco S, Continenza MA, Marzo G. Histological characterization of Sacco's concentrated growth factors membrane. *Int J Morphol.* 2017;35:114–119.

22. Simion M, Jovanovic SA, Tinti C, Benfenati SP. Long-term evaluation of osseointegrated implants inserted at the time or after vertical ridge augmentation: a retrospective study on 123 implants with 1-5 year follow-up. *Clin Oral Implants Res.* 2001;12:35–45.

23. Laino L, Iezzi G, Piattelli A, Lo Muzio L, Cicciù M. Vertical ridge augmentation of the atrophic posterior mandible with sandwich technique: bone block from the chin area versus corticocancellous bone block allograft—clinical and histological prospective randomized controlled study. *Biomed Res Int.* 2014;2014:982104.

24. Esposito M, Grusovin MG, Felice P, Karatzopoulos G, Worthington HV, Coulthard P. The efficacy of horizontal and vertical bone augmentation procedures for dental implants: a Cochrane systematic review. In: *Evidence-Based Practice: Toward Optimizing Clinical Outcomes.* New York, NY: Springer; 2010:195–218.

25. Fantozzi G, Leuter C, Bernardi S, Nardi GM, Continenza MA. Analysis of the root morphology of European anterior teeth. *Ital J Anat Embryol.* 2013; 118:78–91.

26. Di Angelo L, Di Stefano P, Bernardi S, Continenza MA. A new computational method for automatic dental measurement: the case of maxillary central incisor. *Comput Biol Med.* 2016;70:202–209.

27. Annibaldi S, Cristalli MP, Dell'Aquila D, Bignozzi I, La Monaca G, Pilloni A. Short dental implants: a systematic review. *J Dent Res.* 2012;91:25–32.

28. Bratu E, Chan H-L, Mihali S, et al. Implant survival rate and marginal bone loss of 6-mm short implants: a 2-year clinical report. *Int J Oral Maxillofac Implants.* 2014;29:1425–1428.

29. Lee S-A, Lee C-T, Fu MM, Elmisalati W, Chuang S-K. Systematic review and meta-analysis of randomized controlled trials for the management of limited vertical height in the posterior region: short implants (5 to 8 mm) vs longer implants (>8 mm) in vertically augmented sites. *Int J Oral Maxillofac Implants.* 2014;29:1085–1097.

30. Srinivasan M, Vazquez L, Rieder P, Moraguez O, Bernard JP, Belsler UC. Survival rates of short (6 mm) micro-rough surface implants: a review of literature and meta-analysis. *Clin Oral Implants Res.* 2014;25:539–545.

31. Esposito M, Pistilli R, Barausse C, Felice P. Three-year results from a randomised controlled trial comparing prostheses supported by 5-mm long implants or by longer implants in augmented bone in posterior atrophic edentulous jaws. *Eur J Oral Implantol.* 2014;7:383–395.

32. Felice P, Cannizzaro G, Barausse C, Pistilli R, Esposito M, Cannizzaro G. Short implants versus longer implants in vertically augmented posterior mandibles: a randomised controlled trial with 5-year after loading follow-up. *Eur J Oral Implant.* 2014;7:359–369.

33. Felice P, Cannizzaro G, Checchi V, et al. Vertical bone augmentation versus 7-mm-long implants in posterior atrophic mandibles: results of a randomised controlled clinical trial of up to 4 months after loading. *Eur J Oral Implantol.* 2009;2:7–20.