

Alveolar Ridge Preservation Using Allografts and Dense Polytetrafluoroethylene Membranes With Open Membrane Technique in Unhealthy Extraction Socket

Gi-Beom Cheon, DDS^{1†}
 Kyung Lhi Kang, DDS, PhD^{2†}
 Mi-Kyung Yoo, DDS, MSD¹
 Jeoung-A Yu, DDS, PhD¹
 Dong-Woon Lee, DDS, PhD^{1*}

We evaluated the effectiveness of the open membrane technique using a high-density polytetrafluoroethylene (dPTFE) membrane with freeze-dried bone allografts in damaged sockets for alveolar ridge preservation (ARP). This retrospective study included 26 sites from 20 patients who had received ARP for the placement of dental implants. ARP was conducted using dPTFE membrane with allografts on the day of extraction without primary closure. When the membrane was removed after 4 weeks, the newly formed reddish tissue at the grafted site was checked (first outcome, clinical evaluation). Four months after membrane removal, a core biopsy was performed from the center of the grafted site before implant placement (second outcome, histomorphometric evaluation). Radiographic measurements of alveolar bone changes between implant prosthesis delivery and the 1-year follow-up were obtained (third outcome, radiographic evaluation). A total of 23 sites from 18 patients had no complications during the follow-up period. Three sites from two patients were excluded because of early membrane removal. Newly formed reddish tissue was found at 15 sites, and partially formed tissue was found at 8 sites. Although we were unable to harvest bone core from all sites, histomorphometric analysis in 11 patients indicated that the mean area of new bone was $28.48\% \pm 6.60\%$, that of the remaining graft particle was $27.68\% \pm 9.18\%$, and that of fibrous tissue was $43.84\% \pm 6.98\%$. The mean loss of marginal bone was 0.13 ± 0.06 mm at the mesial area and 0.15 ± 0.06 mm at the distal area, as assessed using radiographic evaluations. The results of this nonrandomized study suggest that this technique may be an appropriate procedure for ARP. Further studies with a control group and more subjectives can be designed based on this study.

Key Words: alveolar ridge preservation, guided bone regeneration, histomorphometric analysis, marginal bone, barrier membrane

INTRODUCTION

Tooth extractions are accompanied by modeling and remodeling along the height and width of the alveolar bone.¹ Therefore, adequate site development after extraction and before implant placement is necessary for esthetics and long-term success in dental implants.¹⁻³ Among the many site development methods, alveolar ridge preservation (ARP) is considered to be the most efficient. ARP reduces the need for additional bone graft surgery and prevents alveolar bone resorption.^{4,5} ARP means site development in unhealthy extraction sockets.

The extraction defect sounding (EDS) classification was designed to provide treatment options. Sites were divided into 4 types based on the number of affected walls, biotype, and expected soft-tissue healing.⁶ EDS-1 indicates an undamaged

socket with 4 intact bony walls and a thick biotype. EDS-2 is characterized by a mild degree of crestal bone damage or interproximal tissue loss of 2 mm with 1 damaged socket wall. Alveolar bone crests are 3–5 mm away from the expected cervical margin of the final prosthesis. EDS-3 indicates a moderately compromised site with 1 or 2 damaged socket walls. In these cases, the crest is 6–8 mm away from the margin of the future restoration. EDS-4 indicates a severely compromised site with 2 or more reduced socket walls. The alveolar crest is located more than 8 mm away from the restorative cervical margin. We evaluated ARPs conducted on EDS-2, -3, or -4 sites (damaged sockets). The extraction sockets had 1 or 2 wall defects. None of the sites were classified as EDS-1 (pristine).

Nonresorbable membranes and other resorbable membranes have been shown to lead to good results in ARP.^{7,8} However, earlier exposure may lead to infection and negative consequences.^{9,10} High-density polytetrafluoroethylene (dPTFE) membranes have smaller pore sizes and help to address these issues. The small pore size ($0.2 \mu\text{m}$ to $0.4 \mu\text{m}$) reduces the chance of bacterial contamination and leads to less bacterial accumulation. Therefore, dPTFE membranes are not easily infected in the oral environment.^{10,11} dPTFE membranes are

¹ Department of Periodontology, Veterans Health Service Medical Center, Seoul, Korea.

² Department of Periodontology, School of Dentistry, Kyung Hee University, Seoul, Korea.

* Corresponding author, e-mail: dongden@daum.net

† These two authors contributed equally to this work.

DOI: 10.1563/aaid-joi-D-17-00012

TABLE 1
Patient population and site distribution

Patient	Gender	Age	Site*	Socket Walls
1	M	68	15	3
2	M	70	14	3
3	M	52	26	2
4	F	56	23, 24	3
5	M	58	37	3
6	M	67	45, 46	3
7	M	63	36, 37	2
8	M	67	24	2
9	M	71	27	2
10	M	65	33	3
11	M	67	33, 34	3
12	M	72	47	2
13	M	68	36	3
14	F	45	15, 16	3
15	M	54	37	2
16	M	67	25	2
17	M	64	47	3
18	M	69	47	3
19	F	65	36, 37	3
20	M	73	23	2
		Mean (SD) =	Total 26 sites	
		64.05 (7.3) years		

*FDI tooth numbers.

advantageous to keep the width of attached gingiva, as they do not require flap advancement for primary closure.^{10,12,13}

Many types of grafting material and membranes have been tested for use in ARP.^{14,15} However, the use of dPTFE membranes in humans has still not been extensively researched, especially in unhealthy extraction sockets. In this retrospective study, we evaluated the effectiveness of ARP using dPTFE membrane with an open membrane technique in unhealthy extraction sites with 2 or 3 walls by clinical, histomorphometric, and radiographic assessments.

MATERIALS AND METHODS

Patient population

We studied 26 sites from 20 patients (17 men and 3 women) who had received ARP for implant placement at the Department of Periodontology in Veterans Health Service (VHS) Medical Center between January 2011 and December 2013. The mean age of the patients was 64.05 years (range, 52–73 years; Table 1). The institutional review board of VHS Medical Center reviewed and approved the protocol for this non-randomized study (BOHUN 2016-05-002).

The inclusion criteria were (1) extraction sites planned for implant placement and (2) EDS-2, -3, or -4 classification with 1 or more damaged socket walls.⁶ The exclusion criteria were (1) sites that did not meet all inclusion criteria; (2) patients with systemic or localized disease (uncontrolled diabetes, hypertension, or coagulopathy); (3) patients with a history contraindicated for dental implant placement, such as bisphosphonate drug use, use of chemotherapeutic or immunosuppressive agents, and autoimmune disease; and (4) patients with heavy smoking habits (more than 10 cigarettes per day; Figure 1).

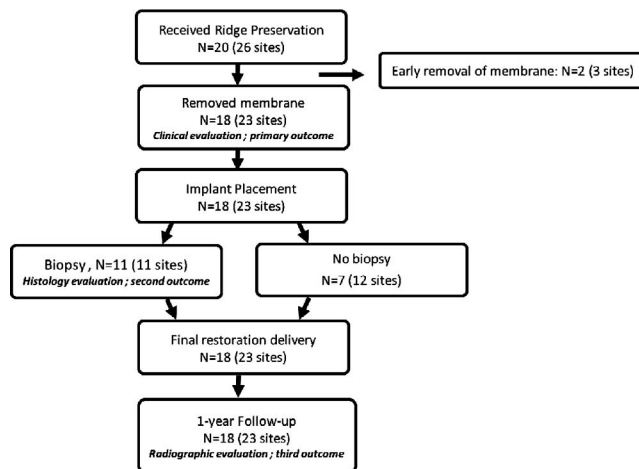


FIGURE 1. Flow chart of screening and evaluation process.

Surgical procedure and time table

Before surgery, scaling and oral hygienic care were performed in all patients. One vertical incision at the mesial or distal adjacent tooth was made using a No. 15 blade. Another incision around the extracted tooth was gently produced for the minimal elevation of the flaps. The flaps were elevated gently, and the tooth was extracted carefully. Extraction socket debridement was performed using a surgical curette. The socket walls were counted based on the adjacent alveolar bone.¹⁶

Extraction sockets were filled with allografts (ICB Cortical, Rocky Mountain Tissue Bank, Aurora, Colo) and covered with dPTFE (Cytoplast GBR200, Osteogenics, Lubbock, Tex) membranes. The flap was repositioned and sutured. Primary closure was intentionally not performed.

After ARP surgery, the patients received a dressing every week and performed chlorhexidine gargling for 1 minute twice per day for the prevention of secondary infection. After a 4-week healing period, the membrane was removed without flap elevation.^{17,18} Four months after removal of the membrane, 1 of 3 kinds of standard internal connection implants was placed in the socket (Table 2). Temporary and final prostheses were delivered by prosthodontists (Figure 2).

Clinical evaluation

The presence of newly formed reddish tissue under the membrane was confirmed upon membrane removal. In

TABLE 2
Distribution of placed dental implants*

Company (Type)	Surface	Amount
Biohorizons (tapered internal)	RBM with no machined neck	7
Camlog (root line)	SLA with 0.4-mm machined neck	2
Osstem (TS III)	SLA with no machined neck	14

*RBM indicates resorbable blast media; SLA, sandblasted with large-grit and acid etched.

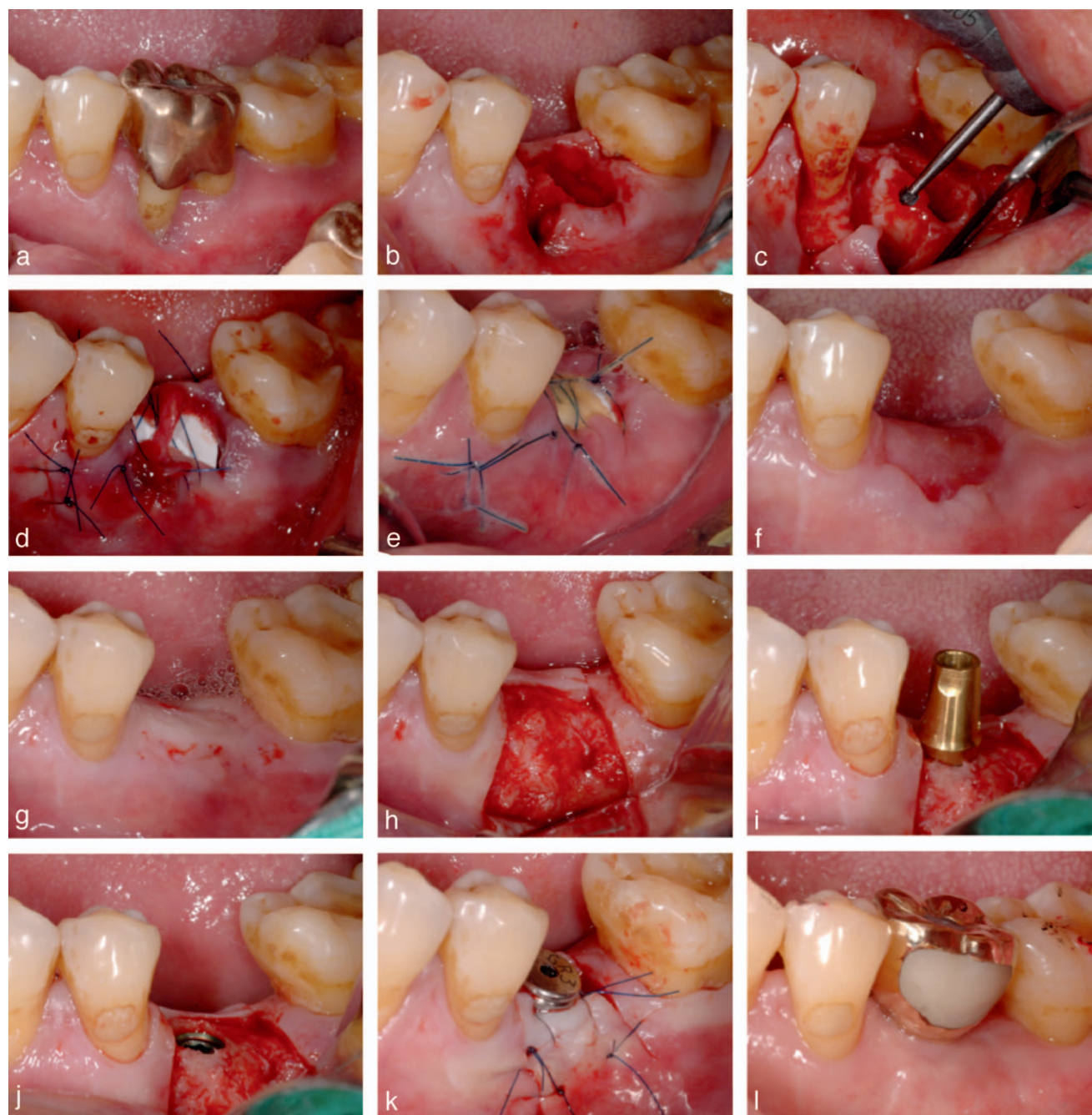

FIGURE 2. Case of a representative patient (No. 13). (a) Preoperation view. (b) After extraction. (c) Flap reflection and debridement. (d) Open membrane technique with high-density polytetrafluoroethylene membrane after bone graft. (e) Two weeks after alveolar ridge preservation (ARP). (f) Eight weeks after ARP, also 4 weeks after membrane removal. (g) Before reentry surgery (4 months after ARP). (h) Flap elevation for placement of implant. (i) Fixture installation. (j) View of implantation without additional bone graft. (k) Connection of healing abutment. (l) Prosthesis delivery.

addition, we checked for abnormal healing and other complications.

Histomorphometric evaluation

A trephine bur (Trephine Bur Kit Xit, Dentium, Seoul, Korea) with a 2.7-mm inner diameter was used to harvest bone from the central part of the preexisting socket during the implant placement surgery. This was the location of implant placement.

These core specimens were fixed using 10% formalin, decalcified using 5% formic acid, and embedded in paraffin. The specimens were cut into 4- to 6- μ m-thick sections longitudinally along the major axis. Slides were stained using hematoxylin and eosin. Areas of new bone, residual bone graft, and fibrous tissue were measured and calculated using an imaging program (Image-pro Plus 7, Media Cybernetics, Rockville, Md).

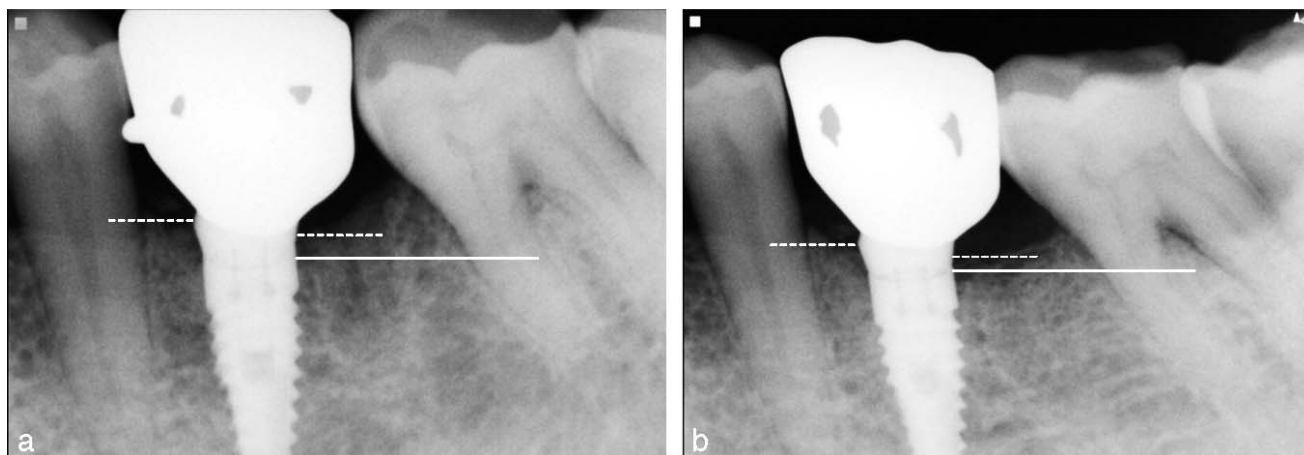


FIGURE 3. Radiographic assessment. (a) Radiographs at the time of prosthesis delivery. (b) Radiographs after 1-year follow-up (white spot lines on both sides of the implant indicate the mesial and distal bone level; white line indicates implant-abutment junction).

Radiographic evaluation

Final prostheses were delivered after the proper healing period. Intraoral radiographs were obtained at the time of final restoration delivery (baseline). All patients had a regular follow-up at least 1 year after setting of final restorations. To evaluate marginal bone stability, intraoral radiographs were obtained 1 year after prosthesis delivery to measure marginal bone level changes (Figure 3). Intraoral radiographs were obtained using a long-cone paralleling technique and a film holder (XCP-DS FIT, Dentsply, Waltham, Mass). Distances on each side were calculated using the digital caliper of a radiographic viewer (mViewer, Marotech, Seoul, Korea).

RESULTS

Clinical evaluation

All subjects received an ARP using a dPTFE membrane and freeze-dried bone allografts (FDBA) without primary closure. Twenty-three sites from 18 patients healed uneventfully. In 3 sites from 2 patients, membranes were removed in 2 weeks because of membrane loosening. Four weeks after ARP surgery,

the membranes were removed without flap elevation. Newly formed reddish tissues were found at 15 sites.

Histological evaluation

We studied samples from 11 patients (10 men and 1 woman) with a mean age of 61.8 years (range, 53–68 years). After 16 weeks (mean, 17.6 ± 2.1 weeks), the grafted sites had healed uneventfully. At this time, the bone cores were harvested. The other 7 patients in the study did not undergo biopsies. Three of the 7 patients did not undergo bone core harvest at the time of surgery, and the remaining 4 patients refused to agree to the biopsy. Histomorphometric analyses indicate that the mean area of new bone was $28.48\% \pm 6.60\%$, that of the remaining graft particle was $27.68\% \pm 9.18\%$, and that of fibrous tissue was $43.84\% \pm 6.98\%$ (Figures 4 and 5).

Radiographic evaluation

Final prostheses were delivered 6.6 ± 2.7 months after implant placement. To evaluate marginal bone stability, we obtained radiographic images at least 1 year after the start of implant function. The reference point used was the level of the implant-abutment junction (IAJ). We measured the distance between the IAJ and the top of the crestal bone. The mean loss of

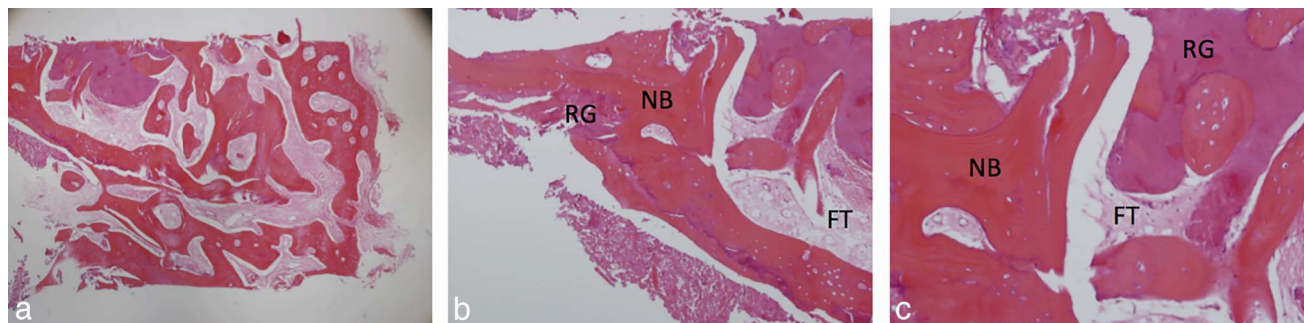


FIGURE 4. Specimens from representative patient (No. 1). (a) Section of biopsy (patient No. 1; hematoxylin and eosin [H&E]; original magnification, $\times 40$). (b) Higher magnification of the same sample (H&E; original magnification, $\times 100$; NB indicates new bone; RG, residual graft particles; FT, fibrous tissue). (c) Higher magnification of the same sample (H&E; original magnification, $\times 200$).

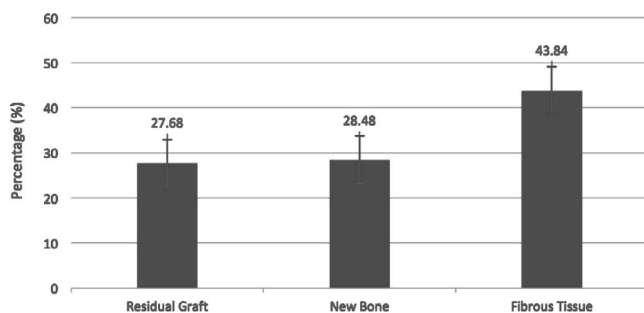


FIGURE 5. Histomorphometric assessment.

marginal bone was 0.13 ± 0.06 mm at the mesial area and 0.15 ± 0.06 mm at the distal area.

DISCUSSION

This study was conducted using the open membrane technique with dPTFE membrane and FDDBA in unhealthy sockets. There are only a few studies regarding the use of ARP with dPTFE membrane under these conditions (2 or 3 wall defects).^{17,19} In addition, we conducted a regular follow-up after the prosthesis was loaded. Therefore, marginal bone remodeling was assessed at least 1 year after the setting of the restoration. Average marginal bone loss was proposed as a success criteria.²⁰ However, the increased distance from the IAJ to the crestal bone due to platform switching can reduce marginal bone loss.²¹ Our results (mean, 0.14 mm) were similar to those of another study using a similar protocol, wherein a baseline at the time of final restoration was obtained.²² During the follow-up period (up to 2 years), 23 implants from 18 patients had a 100% survival rate. New bone area (28.4%), as assessed using histomorphometric analysis, was similar to that observed in a previous study (31.9%) of socket preservation using a combination of FDDBA and collagen membrane for 4 months.²³

There have been many research efforts to find the proper materials for use in ARP. However, there is still no definitive consensus on the appropriate material.^{24–26} Although more cross-comparison studies are required, FDDBA, which was used in this study, has led to better new bone formation than other bone grafting materials.^{27,28} The 4-month healing period after bone graft is supported by a previous study.²⁹

Expanded polytetrafluoroethylene (ePTFE) has been the gold standard when performing bone regeneration procedures. However, resorbable membranes are currently used in most cases, as they have advantages (no need of membrane removal, cost-effectiveness, decreasing patient morbidity, etc) compared with ePTFE that seem to lead to good ARP outcomes.^{23,30,31}

dPTFE membranes may have advantages in protecting open wound sites, such as extraction sockets, with different characteristics (high density, low porosity, etc) than other barriers. Both ePTFE and resorbable membranes require the complete closure of the overlying soft tissue. In addition, exposure to resorbable membranes is known to have adverse effects on bone maturation and the outcome of bone graft surgery.³² In contrast, dPTFE is well suited for ARP. Primary closure is not a prerequisite for using dPTFE in extraction sockets. Thus, the use of dPTFE allows for the easy treatment of

large defects and helps with the preservation of keratinized gingiva. It also prevents the ingrowth of fibrous tissue and bacterial contamination.^{10,17}

Many techniques have been suggested for a better outcome of ARP. In this study, we used full-thickness flaps with a single vertical incision in all procedures. Some studies have shown that flap elevation has adverse effects on alveolar bone resorption.³³ However, Barone et al³⁴ reported that flap elevation does not affect alveolar bone changes. In this study, full-thickness flaps were reflected to aid checking the socket defects first and complete debriding of soft tissue in the sockets.

The dPTFE membrane can be removed easily 4 weeks after extraction without the need for additional procedures. This reduces patient morbidity. In this study, newly formed reddish tissues were observed at the time of membrane removal. Eight of the 23 sites (34.7%) required additional bone grafts during the placement of the implant. Similar results were observed in a previous study (16 of 52 sites, 30.7%).³⁵ These reddish soft tissues seem closely related to bone maturation. We could not assess the relationship between newly formed reddish tissue and additional bone grafts in this study. Because 8 of the sites required additional bone grafts, only 2 sites did not have new reddish tissue.

CONCLUSION

The combination of FDDBA and dPTFE membrane with an open membrane technique may be one modality for ARP on unhealthy sockets prior to placement of dental implants. Further studies with a control group and more subjectives can be designed based on this study.

ABBREVIATIONS

ARP: alveolar ridge preservation
 dPTFE: high-density polytetrafluoroethylene
 EDS: extraction defect sounding
 ePTFE: expanded polytetrafluoroethylene
 FDDBA: freeze-dried bone allografts
 IAJ: implant-abutment junction
 VHS: Veterans Health Service

ACKNOWLEDGMENT

This study was supported by a VHS Medical Center Research Grant, Republic of Korea (grant VHSMC16009).

NOTE

The authors report no conflicts of interest.

REFERENCES

1. Hämmerle CHF, Araújo MG, Simion M, on behalf of the Osteology Consensus Group. Evidence based knowledge on the biology and treatment of extraction sockets. *Clin Oral Implants Res.* 2012;23:80–82.

2. Kan J, Rungcharassaeng K. Site development for anterior single implant esthetics: the dentulous site. *Compend Contin Educ Dent*. 2001;22:221–226.
3. Tan WL, Wong TL, Wong M, Lang NP. A systematic review of post-extraction alveolar hard and soft tissue dimensional changes in humans. *Clin Oral Implants Res*. 2012;23:1–21.
4. Morjaria KR, Wilson R, Palmer RM. Bone healing after tooth extraction with or without an intervention: a systematic review of randomized controlled trials. *Clin Implant Dent Relat Res*. 2014;16:1–20.
5. Eskow AJ, Mealey BL. Evaluation of healing following tooth extraction with ridge preservation using cortical versus cancellous freeze-dried bone allograft. *J Periodontol*. 2014;85:514–524.
6. Caplanis N, Lozada J, Kan J. Extraction defect assessment, classification and management. *J Calif Dent Assoc*. 2005;33:853–863.
7. Zubillaga G, Hagen SV, Simon BI, Deasy MJ. Changes in alveolar bone height and width following post-extraction ridge augmentation using a fixed bioabsorbable membrane and demineralized freeze-dried bone osteoinductive graft. *J Periodontol*. 2003;74:965–975.
8. Marouf HA, El-Guindi HM. Efficacy of high-density versus semipermeable PTFE membranes in an elderly experimental model. *Oral Surg Oral Med Oral Pathol Oral Radiol Endodontology*. 2000;89:164–170.
9. Machtei EE. The effect of membrane exposure on the outcome of regenerative procedures in humans: a meta-analysis. *J Periodontol*. 2001;72:512–516.
10. Rakhmatia YD, Ayukawa Y, Furuhashi A, Koyano K. Current barrier membranes: titanium mesh and other membranes for guided bone regeneration in dental applications. *J Prosthodont Res*. 2013;57:3–14.
11. Jung RE, Fenner N, Hämmerle CHF, Zitzmann NU. Long-term outcome of implants placed with guided bone regeneration (GBR) using resorbable and non-resorbable membranes after 12–14 years. *Clin Oral Implants Res*. 2013;24:1065–1073.
12. Barber HD, Lignelli J, Smith BM, Bartee BK. Using a dense PTFE membrane without primary closure to achieve bone and tissue regeneration. *J Oral Maxillofac Surg*. 2007;65:748–752.
13. Barboza EP, Stutz B, Mandarino D, Rodrigues DM, Ferreira VF. Evaluation of a dense polytetrafluoroethylene membrane to increase keratinized tissue: a randomized controlled clinical trial. *Implant Dent*. 2014;23:289–294.
14. Vignoletti F, Matesanz P, Rodrigo D, Figuero E, Martin C, Sanz M. Surgical protocols for ridge preservation after tooth extraction; a systematic review. *Clin Oral Implants Res*. 2012;23(suppl 5):22–38.
15. Jung RE, Philipp A, Annen BM, et al. Radiographic evaluation of different techniques for ridge preservation after tooth extraction: a randomized controlled clinical trial. *J Clin Periodontol*. 2013;40:90–98.
16. Elian N, Cho S, Froum S, Smith RB, Tarnow DP. A simplified socket classification and repair technique. *Pract Proced Aesthet Dent*. 2007;19:99–104.
17. Hoffmann O, Bartee BK, Beaumont C, Kasaj A, Deli G, Zafiroopoulos G-G. Alveolar bone preservation in extraction sockets using non-resorbable dPTFE membranes: a retrospective non-randomized study. *J Periodontol*. 2008;79:1355–1369.
18. Carbonell J, Martín IS, Santos A, Pujol A, Sanz-Moliner J, Nart J. High-density polytetrafluoroethylene membranes in guided bone and tissue regeneration procedures: a literature review. *Int J Oral Maxillofac Surg*. 2014;43:75–84.
19. Yamashita M, Horita S, Takei N. *Minimally Invasive Alveolar Ridge Preservation/Augmentation Procedure*. Fukuoka, Japan: Funakoshi Research Institute of Clinical Periodontology; 2015.
20. Albrektsson T, Zarb G, Worthington P, Eriksson A. The long-term efficacy of currently used dental implants: a review and proposed criteria of success. *Int J Oral Maxillofac Implants*. 1986;1:11–25.
21. Lazzara RJ, Porter SS. Platform switching: a new concept in implant dentistry for controlling postrestorative crestal bone levels. *Int J Periodontics Restorative Dent*. 2006;26:9–17.
22. Koutouzis T, Lundgren T. Crestal bone-level changes around implants placed in post-extraction sockets augmented with demineralized freeze-dried bone allograft: a retrospective radiographic study. *J Periodontol*. 2010;81:1441–1448.
23. Iasella JM, Greenwell H, Miller RL, et al. Ridge preservation with freeze-dried bone allograft and a collagen membrane compared to extraction alone for implant site development: a clinical and histologic study in humans. *J Periodontol*. 2003;74:990–999.
24. Athanasiou VT, Papachristou DJ, Panagopoulos A, Saridis A, Scopa CD, Megas P. Histological comparison of autograft, allograft-DBM, xenograft, and synthetic grafts in a trabecular bone defect: an experimental study in rabbits. *Med Sci Monit Basic Res*. 2009;16:BR24–BR31.
25. Kao ST, Scott DD. A review of bone substitutes. *Oral Maxillofac Surg Clin North Am*. 2007;19:513–521.
26. Lee D-W, Pi S-H, Lee S-K, Kim E-C. Comparative histomorphometric analysis of extraction sockets healing implanted with bovine xenografts, irradiated cancellous allografts, and solvent-dehydrated allografts in humans. *Int J Oral Maxillofac Implants*. 2009;24:609–615.
27. Beck TM, Mealey BL. Histologic analysis of healing after tooth extraction with ridge preservation using mineralized human bone allograft. *J Periodontol*. 2010;81:1765–1772.
28. Wood RA, Mealey BL. Histologic comparison of healing after tooth extraction with ridge preservation using mineralized versus demineralized freeze-dried bone allograft. *J Periodontol*. 2011;83:329–336.
29. Hammerle CH, Jung RE. Bone augmentation by means of barrier membranes. *Periodontology 2000*. 2003;33:36–53.
30. Whetman J, Mealey BL. Effect of healing time on new bone formation after tooth extraction and ridge preservation with demineralized freeze-dried bone allograft: a randomized controlled clinical trial. *J Periodontol*. 2016;87:1022–1029.
31. Arbab H, Greenwell H, Hill M, et al. Ridge preservation comparing a nonresorbable PTFE membrane to a resorbable collagen membrane: a clinical and histologic study in humans. *Implant Dent*. 2016;25:128–134.
32. Machtei EE. The effect of membrane exposure on the outcome of regenerative procedures in humans: a meta-analysis. *J Periodontol*. 2001;72:512–516.
33. Fickl S, Zuhr O, Wachtel H, Bolz W, Huerzeler M. Tissue alterations after tooth extraction with and without surgical trauma: a volumetric study in the beagle dog. *J Clin Periodontol*. 2008;35:356–363.
34. Barone A, Borgia V, Covani U, Ricci M, Piattelli A, Iezzi G. Flap versus flapless procedure for ridge preservation in alveolar extraction sockets: a histological evaluation in a randomized clinical trial. *Clin Oral Implants Res*. 2015;26:806–813.
35. Koutouzis T, Lipton D. Regenerative needs following alveolar ridge preservation procedures in compromised and noncompromised extraction sockets: a cone beam computed tomography study. *Int J Oral Maxillofac Implants*. 2016;31:849–854.