

Reactive Fibrous Hyperplasia of Peri-implant Mucosa

Fotios Bountaniotis, DDS^{1*}

Fotios Tzerbos, DDS, MD, PhD¹

Konstantinos Tosios, DDS, MSc, PhD²

Ioannis Melakopoulos, DDS, PhD³

INTRODUCTION

Implant-related reactive lesions of the oral mucosa are uncommon, compared with tooth-related ones. Although their pathogenesis is undetermined, local irritating factors such as dental plaque, tartar, and trauma are thought to be involved.^{1,2} Most implant-related reactive lesions reported up to date are pyogenic granulomas (PG) and peripheral giant cell granulomas (PGCG),³ but 1 case each of hemangioma and parulis-like soft tissue tumor³ were also reported.

The aim of this paper is to describe a case of a fibrous hyperplasia that developed around 2 healing caps and discuss its possible pathogenesis, differential diagnosis, and treatment. To the best of our knowledge, there is no report of implant-related fibrous hyperplasia in the literature.

CASE REPORT

A 65-year-old female was treated with the insertion of 2 implants (3.8 × 9.5 mm, XiVE, Dentsply-Friadent, Mannheim, Germany) in the second premolar and second molar positions for the rehabilitation of the edentulous left posterior mandible. Medical history included hypothyroidism and high cholesterol levels, both under medication. Four months later, new, unused healing caps were screwed on the implants and no temporary restoration was applied. After 3 weeks the patient presented for a “painful swelling” around the implants. Clinical examination showed a sessile mass, arising from the lingual peri-implant mucosa that was ulcerated adjacent to the implants (Figure 1); it measured 3.2 × 0.8 × 0.8 cm, and was firm and slightly painful on palpation. According to the patient the lesion appeared 2 weeks before presentation and enlarged rapidly. With the clinical diagnosis of an inflammatory lesion, double antibiotic treatment (amoxicillin, 500 mg, and metronidazole, 500 mg, every 8 hours) was prescribed for a week. In addition, the healing caps were replaced by cover screws, to eliminate any possible irritation. However, the lesion did not regress (Figure 2). Radiographic examination did not reveal bone involvement or ossifications within the lesion (Figure 3). Based on the clinical and radiographic findings, differential diagnosis included fibrous hyperplasia and PG. An excisional biopsy with scalpel was

performed under local infiltration anesthesia. During surgery, no tartar or foreign bodies were identified around the implants.

Microscopic examination of 5 μm thick sections of formalin-fixed and paraffin embedded tissue revealed dense, vascular fibrous connective tissue, with focal inflammatory infiltrations mostly by lymphoplasmacytes (Figure 4). The overlying epithelium was acanthotic, parakeratinized stratified squamous. The diagnosis was fibrous hyperplasia. Healing was uneventful and an implant-supported restoration was fabricated, taking care to avoid any local mechanical irritation. Four years later the restoration is in place and the patient is free of recurrence.

DISCUSSION

Implant-related reactive lesions may be associated with local irritating factors, in particular dental plaque, tartar, or trauma from inappropriate healing caps or ill-fitting prosthesis,^{1,2} as well as metal particles originating from the implant.^{5,6} In our case, none of the aforementioned factors was identified. It is hypothesized that due to the short alveolar ridge height, the lingual alveolar mucosa moved over the healing caps during normal function of the tongue, and the healing caps traumatized it, acting as a local irritating factor.

Differential diagnosis of implant-related reactive lesions mostly includes PG and PGCG.³ Although tooth-related PG is more common than the implant-related one, PGCG is more common when implants are involved.⁷ Only 7 cases of implant-related PG have been reported in the literature and no recurrence is mentioned.⁴ On the other hand, according to Brown et al. the recurrence rate of PGCG is 46.2%, although the number of reported cases (13 cases) is too small for valid conclusions.⁷ Implant-related peripheral ossifying fibroma has not been reported up to date, while the absence of ossifications on radiographic examination was against this diagnosis. Overall, the posterior area of the jaws, especially of the mandible, is the most common site of occurrence of implant-related reactive lesions.⁷⁻⁹

Microscopically, the presence of dense fibrous connective tissue was consistent with the diagnosis of fibrous hyperplasia.¹⁰ Fibrous hyperplasias are caused by chronic low-grade irritation, that is from dental plaque or ill-fitting dental appliances,^{10,11} that result in inflammation and formation of granulation tissue that may progressively mature to dense fibrous connective tissue. Therefore, this lesion may be considered as a mature pyogenic granuloma, as different histopathological findings may represent various stages in the physical history of the same disease process.

As in all reactive lesions, surgical excision is curative for implant-related lesions, and elimination of etiologic factors is of utmost importance for preventing recurrence.

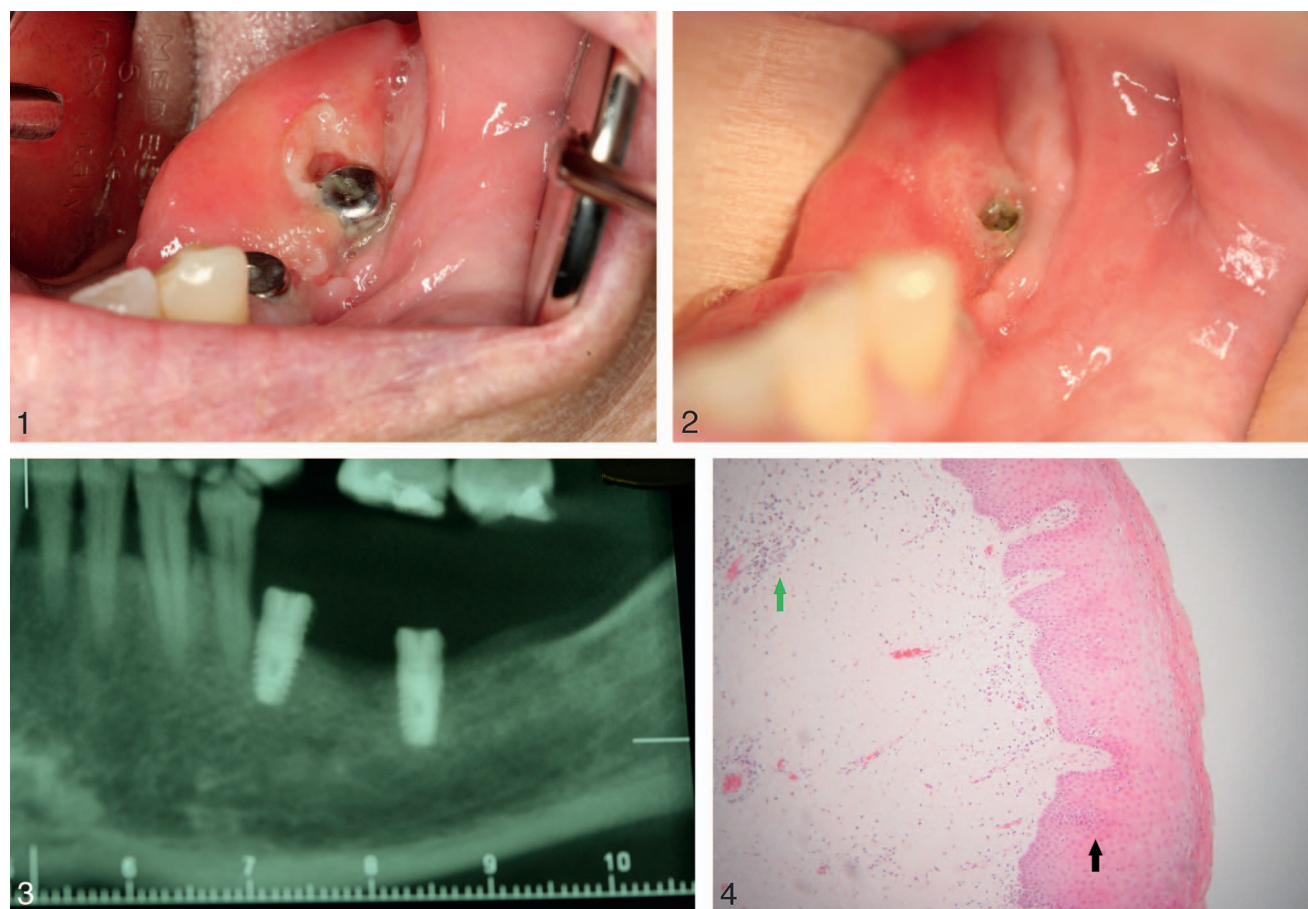
¹ Department of Oral & Maxillofacial Surgery, Dental School of Athens, National and Kapodistrian University of Athens, Goudi, Athens, Greece.

² Department of Oral Pathology, Dental School of Athens, National and Kapodistrian University of Athens, Goudi, Athens, Greece.

³ Department of Oral and Maxillofacial Surgery, HYGIEIA Hospital, Athens, Greece.

* Corresponding author, e-mail: fboudaniotis@yahoo.gr

DOI: 10.1563/aid-joi-D-17-00021



FIGURES 1–4. **FIGURE 1.** Clinical photograph of the hyperplastic lesion on the lingual peri-implant mucosa around the healing caps. **FIGURE 2.** The lesion remained stable in size 1 week after the removal of the healing caps. **FIGURE 3.** Panoramic radiograph does not reveal bone erosion or ossifications in the lesion. **FIGURE 4.** Hyperplastic fibrous connective tissue with focal inflammatory infiltration (green arrow) and acanthosis of epithelium (black arrow) (hematoxylin–eosin stain, $\times 200$ magnification).

ABBREVIATIONS

PG: pyogenic granuloma

PGCG: peripheral giant cell granuloma

ACKNOWLEDGMENT

Fotios Bountaniotis is a Scholar of the Onassis Foundation.

NOTE

The authors declare that there are no conflicts of interest.

REFERENCES

1. Dojcinovic I, Richter M, Lombardi T. Occurrence of a pyogenic granuloma in relation to a dental implant. *J Oral Maxillofac Surg.* 2010;68:1874–1876.
2. Etöz OA, Soylu E, Kiliç K, Günhan Ö, Akcay H, Alkan A. A reactive lesion (pyogenic granuloma) associated with dental implant: a case report. *J Oral Implantol.* 2013;39:733–736.
3. Bountaniotis F, Tosios K, Tzerbos F, Melakopoulos I. A Parulis-Like Soft Tissue Tumor in Relation With a Dental Implant: Case Report. *J Oral Implantol.* 2016;42:505–507.
4. Kang YH, Byun JH, Choi MJ, et al. Co-development of pyogenic granuloma and capillary hemangioma on the alveolar ridge associated with a dental implant: a case report. *J Med Case Rep.* 2014;8:192.
5. Paknejad M, Bayani M, Yaghobee S, Kharazifard MJ, Jahedmanesh N. Histopathological evaluation of gingival tissue overlying two-stage implants after placement of cover screws. *Biotechnol Biotechnol Equip.* 2015;29:1169–1175.
6. Olmedo DG, Paparella ML, Brandizzi D, Cabrini RL. Reactive lesions of peri-implant mucosa associated with titanium dental implants: a report of 2 cases. *Int J Oral Maxillofac Surg.* 2010;39:503–507.
7. Brown AL, Moraes PC, Sperandio M, Soares AB, Araujo VC, Passador-Santos F. Peripheral giant cell granuloma associated with a dental implant: a case report and review of the literature. *Case Rep Dent.* 2015;2015:697673.
8. Peñarocha-Diago MA, Cervera-Ballester J, Maestre-Ferrín L, Peñarocha-Oltra D. Peripheral giant cell granuloma associated with dental implants: clinical case and literature review. *J Oral Implantol.* 2012;38:527–532.
9. Jané-Salas E, Albuquerque R, Font-Muñoz A, González-Navarro B, Estrugo Devesa A, López-López J. Pyogenic granuloma/Peripheral giant-cell granuloma associated with implants. *Int J Dent.* 2015;2015:839032.
10. Hunasgi S, Koneru A, Vanishree M, Manvikar V. Assessment of reactive gingival lesions of oral cavity: a histopathological study. *J Oral Maxillofac Pathol.* 2017;21:180.
11. de Santana Santos T, Martins-Filho PS, Piva MR, de Souza Andrade ES. Focal fibrous hyperplasia: a review of 193 cases. *J Oral Maxillofac Pathol.* 2014;18:86–89.
12. Halperin-Sternfeld M, Sabo E, Akrish S. The Pathogenesis of Implant-Related Reactive Lesions: A Clinical, Histologic and Polarized Light Microscopy Study. *J Periodontol.* 2016;87:502–510.