

# Human Studies of Vertical and Horizontal Alveolar Ridge Augmentation Comparing Different Types of Bone Graft Materials: A Systematic Review

Suraj Chavda<sup>1</sup>  
Liran Levin, DMD<sup>2\*</sup>

Alveolar ridge augmentation can be completed with various types of bone augmentation materials (autogenous, allograft, xenograft, and alloplast). Currently, autogenous bone is labeled as the “gold standard” because of faster healing times and integration between native and foreign bone. No systematic review has currently determined whether there is a difference in implant success between various bone augmentation materials. The purpose of this article was to systematically review comparative human studies of vertical and horizontal alveolar ridge augmentation comparing different types of bone graft materials (autogenous, allograft, xenograft, and alloplast). A MEDLINE search was conducted under the 3 search concepts of bone augmentation, dental implants, and alveolar ridge augmentation. Studies pertaining to socket grafts or sinus lifts were excluded. Case reports, small case series, and review papers were excluded. A bias assessment tool was applied to the final articles. Overall, 219 articles resulted from the initial search, and 9 articles were included for final analysis. There were no discernible differences in implant success between bone augmentation materials. Generally, patients preferred nonautogenous bone sources as there were fewer hospital days, less pain, and better recovery time. Two articles had industrial support; however, conclusions of whether that support influenced the outcomes could not be determined. Future comparative studies should compare nonautogenous bone sources and have longer follow-up times.

**Key Words:** bone graft, bone, dental implants, peri-implantitis, implant failure

## INTRODUCTION

Implant placement in patients with atrophic mandible or maxilla is becoming more prevalent.<sup>1</sup> Atrophy or bone loss can be due to periodontal disease, trauma, or postextraction resorption. This loss may not be sufficient from an esthetic or functional perspective for implant placement; thus, bone augmentation might be recommended.<sup>1</sup>

Bone grafting or bone augmentation is the process of adding bone in anatomically or functionally deficient areas. Bone augmentation is performed for procedures such as sinus augmentation, socket grafting, or alveolar ridge augmentation. The purpose of the new bone is to provide stability and support for the future dental implant. As native bone grows, it replaces the graft material and, with time, results in an integrated region of new bone.<sup>2</sup> This process will vary among the different bone substitutes used with relation to their resorption properties; for some bone substitutes, very minimal resorption was reported. New bone may grow by osteogenesis, osteoinduction, or osteoconduction.<sup>3</sup> Osteogenesis occurs when osteoprogenitor cells in the graft material can survive transplantation and can differentiate into osteoblasts and later

osteocytes.<sup>4</sup> Osteoinduction is when undifferentiated mesenchymal cells in the native bone are induced into osteoblasts or chondroblasts to grow new bone by surrounding tissue. This is often dependent on bone morphogenic proteins (BMPs).<sup>2</sup> Osteoconduction is defined as a material encouraging bone formation from already existing bone or differentiated mesenchymal cells via scaffolding.<sup>2</sup>

Bone grafting materials vary by their source. Autogenous bone grafts may be harvested from the patient's iliac crest, mandibular ramus, or other intraoral sites. The donor site chosen is determined based on the volume of graft material required.<sup>5</sup> Autogenous bone heals in three phases. The first phase is osteogenesis, and here the surviving cells form the osteoid. The second phase is osteoinduction and starts 2 weeks after grafting. The blood vessels from the host bone invade the graft, and native bone cells follow the vessels. Bone formation and resorption are now mediated by BMP. The third phase occurs as the minerals from the graft act as scaffolding for native bone to form a matrix upon. The third phase is synonymous with osteoconduction. These 3 phases overlap and are not separate entities.<sup>5</sup> Disadvantages of autografts include the need for a second surgical site and the morbidity related to bone harvesting.<sup>4</sup> Autogenous bone may also require a longer time period for resorption than some synthetics or demineralized freeze-dried bone allografts (DFDBA) mixed with calcium sulfate. This could also be a disadvantage if full graft

<sup>1</sup> Faculty of Medicine and Dentistry, University of Alberta, Canada.

<sup>2</sup> Division of Periodontology, Faculty of Medicine and Dentistry, University of Alberta, Canada.

\* Corresponding author, e-mail: liran@ualberta.ca

DOI: 10.1563/aaid-joi-D-17-00053

TABLE 1	
PICO framework	
Population	Humans requiring alveolar ridge augmentation for dental implants
Intervention	Horizontal or vertical alveolar ridge augmentation with bone grafting materials
Comparison	Two bone grafting material types
Outcome	Implant failures, complications, follow-up period, healing time, patient satisfaction, and any other significant criteria

resorption is desired in a short time frame, which will not occur with autogenous cortical bone grafts.

Allograft material is bone material from another individual of the same species—often cadaveric. The bone material is sterilized, processed, and stored in bone banks.<sup>2,5</sup> Allografts act via osteoinduction and have osteoconductive capabilities as well on native undifferentiated mesenchymal cells. They are known to form bone via osteoconduction by a combination of resorption of the graft matrix and deposition of new bone on the residual scaffold. Osteogenesis is not an option for allografts as the cells are not vital. Some challenges with this type of bone are that the medical history of the donor must be cleared of infections, cancers, and other problems for the recipient's safety. It has been hypothesized that bone formation is slower and may produce less volume for allografts vs autografts as allografts do not conduct osteogenesis.<sup>5</sup> Those findings, however, are controversial. There are 2 main types of allografts: frozen and freeze-dried (lyophilized) or demineralized freeze-dried bone.<sup>2</sup>

Xenograft material is bone material from equine, porcine, or bovine sources that is mostly deproteinized and further processed.<sup>6</sup> The organic components of these materials are removed to mitigate immune reactivity or pathogen transmission. The remaining minerals act as a scaffolding for native bone growth. They might be used in combination with growth factors or allografts to simulate the autogenous bone. Bone formation occurs mostly via osteoconduction.<sup>7</sup> The resulting crystal structure is described as being rather similar to human cancellous bone.<sup>7,8</sup>

Alloplastic material is entirely synthetic and synthesized from nonorganic sources.<sup>9</sup> The most prevalent type of alloplasts are bioactive ceramics such as calcium phosphates.<sup>2</sup> Ceramics (calcium phosphates, bioglass, calcium sulfate) can be mixed with growth factors and ions to increase bone mineral density and osteoblast proliferation.<sup>2,4</sup> The mode of bone formation for these ceramics is osteoconduction. When transplanted, osteoid is produced directly onto the ceramic surface by native bone and later undergoes remodeling.<sup>4</sup> Particle sizes and porosity influence the resorption rates of these materials along with other physical properties. Larger particles have a greater expectancy to remain at the augmentation site. Greater porosity has faster resorption rates than osteoclasts and can penetrate the graft more readily than dense material.<sup>5</sup> Certain ceramics can dissolve via the extracellular matrix as well.

Numerous studies have been performed to determine if there is a significant difference between these types of bone materials. The aim of this work was to systematically review comparative human studies of vertical and horizontal alveolar ridge augmentation comparing 2 different types of bone graft

materials (autogenous, allograft, xenograft, and alloplast) for the purposes of dental implantation.

## METHODS

### Types of studies

The research objective was constructed per the PICO framework<sup>10</sup> (Table 1). The search's inclusion criteria were articles that investigated horizontal or vertical alveolar ridge augmentation in human subjects for the purposes of dental implantation. The studies must have directly compared 2 (or more) of the 4 groups of bone grafts (autogenous, allografts, xenografts, and alloplasts) to be included in the review. Studies were limited to retrospective or prospective clinical trials. There were no search limitations on follow-up period, publication date, and sample size to prevent loss of data. Exclusion criteria included studies that compared the same graft types. In addition, sinus augmentations or socket grafting procedure related to bone grafting were excluded. Case report and small case series articles were excluded. Studies that included the same data set were considered as a single publication. The PRISMA protocol was followed for this systematic review.<sup>11</sup> The PRISMA diagram is presented in Figure 1.

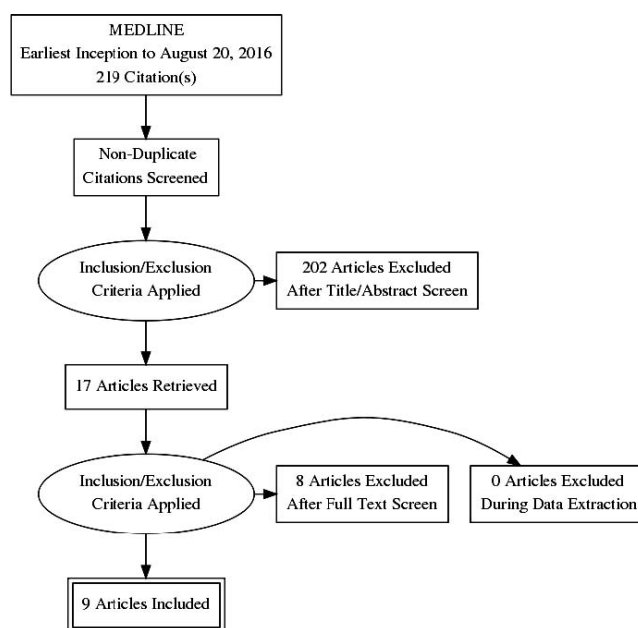


FIGURE 1. PRISMA diagram indicating included and excluded articles.

# ▲	Searches	Results
1	exp Bone Transplantation/ or bone grafts.mp.	31340
2	bone graft*.mp.	23338
3	bone augment*.mp.	1197
4	1 or 2 or 3	41461
5	exp Dental Implantation, Endosseous/ or exp Dental Implantation/	18157
6	dental implant*.mp.	31313
7	5 or 6	31329
8	(vertical* or horizontal*).mp.	146530
9	exp Alveolar Ridge Augmentation/	3371
10	8 or 9	149248
11	4 and 7 and 10	1701
12	limit 11 to (humans and comparative study)	219

FIGURE 2. Search query and limitations for MEDLINE database.

**Search method**

Full-text articles in English were searched on MEDLINE based on a search query (Figure 2). The articles were included from earliest inception until August 20, 2016. The search method was planned in collaboration with an experienced librarian at John W. Scott Library at the University of Alberta based on the research objective. The search identified papers that were tagged under (1) bone transplantation, (2) dental implantation, and (3) alveolar ridge augmentation. Key search words included “bone graft/grfts/grafted/grafting,” “bone augment/augmented/augmenting/augmentation,” “dental implant/implants/implanted/implanting,” “vertical,” or “horizontal.” The 2 limitations on this query were human studies and comparative studies.

**Data extraction**

Following title review, abstracts were assessed per inclusion and exclusion criteria. The included full articles were fully assessed, and the significant results were recorded into a chart. Data were recorded on a spreadsheet, including authorship, patient characteristics, compared materials, outcomes, follow-up after augmentation, complications, main results, and limitations/strengths. A 9-item quality and risk of bias

assessment tool was used and recorded in a separate spreadsheet.<sup>12,13</sup> The bias assessment recorded any conflicts of interest, clarity of objectives described, and the source of the patients. Conflict of interest was defined as all financial relationships with companies whose products the researchers are evaluating in the transcript.

**RESULTS**

The MEDLINE search initially identified 219 articles. Following a title- and abstract-based search, 17 articles were selected for full-text review. Upon full review of these articles, only 9 publications were included for data extraction and descriptive analysis in accordance with the inclusion criteria.<sup>14-22</sup>

In the included articles, there were a total of 181 patients who underwent alveolar ridge augmentation for future dental implantation. Of those, 68 patients had mandibular defects and 79 patients had maxillary defects. Table 2 describes the number of graft sites and implants for each bone graft material. Overall, 304 implants were recorded for 196 graft sites in 181 patients. Of those, 15 patients were treated in studies with a split-mouth design; thus, there are 15 more graft sites than patients.<sup>16,19</sup> Three studies did not state if the implants were placed in the maxilla or mandible.<sup>14,19,22</sup> One study had not placed any implants at the time of publication of those patients.<sup>14</sup> Mini-implants were not included in these calculations as they were never loaded with a prosthesis and thus are not comparable with normal dental implants. One study had used a mix of 70% autogenous (ramus) and 30% bovine porous bone mineral as their test graft and was included under the xenograft group.<sup>17</sup> Two studies are based on the same data set; however, the latter is 1 year later of follow-up.<sup>15,20</sup> Both articles contain different results and thus have been kept as 2 separate inclusions.

The main results, subject demographics, and procedures among other criteria from all 9 publications were summarized in Appendix Ia and Ib. Table 3 summarizes the 9-item quality and risk of bias assessment tool results for all 9 publications.

Vertical bone gain differences were not statistically significant between bone materials, except in 1 study.<sup>15</sup> This study found that although the individual vertical bone height for autogenous (iliac crest) and bovine Bio-OSS were significant,

	Graft Sites				Implants			
	Mandible	Maxilla	Unknown	Total	Mandible	Maxilla	Unknown	Total
Autogenic	37	36		73	38	10	81	129
Intraoral (ramus, retromandibular region)	22	21			20	10		
Iliac crest	15	15			18		81	
Allogenic	25	6	0	31	12	0	0	12
DFDBA	5	0			12	0	0	
FFB	20	6						
Xenograft	41	26	0	67	28	10	96	134
Bovine	34	19			28	10	32	70
Equine	7	7					64	64
Alloplast	14	11		25			29	29
		Total graft sites		196		Total implants		304

\*DFDBA indicates demineralized freeze-dried bone allograft.

TABLE 3

Quality and risk of bias assessment for the selected publications<sup>14–22</sup>

Author(s)	Are Patients Collected in More Than 1 Center?	Where Was the Study Conducted? (University, Private Clinic, Community, etc)	Is the Aim of the Study Clearly Described?	Are the Inclusion and Exclusion Criteria Clearly Reported?	Is There a Clear Definition of the Outcomes Reported?	Were Data Collected Prospectively?	Are the Main Findings of the Study Clearly Described?	Are Losses to Follow-up Clearly Described?	Are Conflicts of Interest/Industrial Support Present?
Spin-Neto et al <sup>14</sup>	No	University	Yes	Yes	Yes	Yes	Yes	Yes	Yes
Felice et al <sup>15</sup>	No	University	Yes	Yes	Yes	Yes	Yes	Yes	No
Fontana et al <sup>16</sup>	No	University	Yes	Yes	Yes	Yes	Yes	Yes	No
Corinaldesi et al <sup>17</sup>	No	University	Yes	Yes	Yes	Yes	Yes	Yes	No
Piatelli et al <sup>18</sup>	No	University	Yes	Yes	Yes	Yes	Yes	Yes	No
Merli et al <sup>19</sup>	No	Private clinic	Yes	Yes	Yes	Yes	Yes	Yes	No
Felice et al <sup>20</sup>	No	University	Yes	Yes	Yes	Yes	Yes	Yes	No
Spin-Neto et al <sup>21</sup>	No	University	Yes	Yes	Yes	Yes	Yes	Yes	No
Pistilli et al <sup>22</sup>	yes	University and private clinic	Yes	Yes	Yes	Yes	Yes	Yes	Yes

the difference between the materials was not significant. Significantly more residual graft was found in the bovine group by 10%–13% vs autogenous.<sup>20</sup> Significantly more vital bone and less soft connective tissue was found for autogenous bone vs allogeneic bone.<sup>14</sup> Microvascular density was deemed not to be significantly different between studied materials (autogenous and bovine).<sup>18</sup> Degree or penetration of graft material into native bone was less extensive for allogeneic bone than autogenous bone.<sup>21</sup>

Bone-to-implant contact was measured in 2 studies, and the difference between materials was not found to be statistically significant. Implant failure rates were not found to be statistically different between bone materials, except in 1 study that found statistically significant worse outcomes (graft failures, implant failures, higher complication rates) for bovine grafts vs autogenous grafts.<sup>22</sup> Complication rates among studies were not found to be different in a statistically significant manner between studied materials among studies. All articles except one used autogenous bone grafts as their control to directly compare another bone graft.<sup>19</sup> A total of 3 studies included smokers.<sup>15,20,22</sup> One study had only 5 patients, and thus the statistical significance was impossible to deduce.<sup>16</sup>

The measured outcomes varied greatly among studies such that a meta-analysis was not considered feasible. Several studies have solely investigated the integration between the graft types and native bone<sup>16</sup> or compared the microvascular density of the bone grafts,<sup>18</sup> whereas others had directly assessed the success of the implants and prosthesis within each bone graft type.<sup>19,20,22</sup> The follow-up period after implant loading varied and was between 6 and 14 months.

Table 3 presents the bias assessment tool results. One study was financially supported by Brazilian agencies Fapesp and CNPq.<sup>14</sup> Another study was supported by Bioteck, Arcugnano

(VI), but the authors stated the data was their own.<sup>22</sup> All other articles declared no conflict of interest or did not discuss conflict of interests. All studies were conducted at universities except for 1 study at a private clinic<sup>19</sup> and 1 study that collected patients from a private clinic and a university.<sup>22</sup> All studies collected data prospectively. All studies had clear objectives and clearly described their main outcomes.

## DISCUSSION

Autogenous bone appears to be the current gold standard for alveolar ridge augmentation against which other materials are chosen to be compared.<sup>14–18,21,22</sup> Per the current review, most studies compared autogenous bone material to another material type. The results of these studies do not suggest that autogenous bone has significantly greater implant or prosthesis success rates. Some studies suggested that autogenous bone has lesser healing time and better compatibility with native bone because of noticeably greater integration although not statistically more significant than its comparators.<sup>14,22</sup> A major implication of this review is that autogenous grafts may not be a clinically superior choice for alveolar ridge augmentation as they are associated with more pain and morbidity.<sup>15,22–24</sup>

These results are in general concurrence with the current comparative literature on bone graft materials. A systematic review of randomized clinical trials of bone graft materials for dental implants showed that there was no significant difference in bone gains between materials.<sup>25</sup> The authors also similarly concluded that nonautogenous bone grafts are a feasible alternative to autogenous grafts. Another systematic review and meta-analysis of the effect of bone graft materials on healing time of sinus floor augmentation concluded that



autogenous grafts have significantly greater growth of bone vs xenografts, allografts, or alloplasts.<sup>24</sup> However, the authors did conclude that the nonautogenous bone graft materials would be viable alternatives because of lesser morbidity and limited availability.<sup>26</sup> A systematic review of clinical outcomes of autogenous bone and other bone substitutes for sinus floor augmentation showed the current evidence does not favor autogenous bone over the others.<sup>27</sup> The implications of this article's results are supportive of the current standing of bone augmentation literature in dentistry.

When performing the MEDLINE search, there were no other reviews found of this nature; however, it should be noted that other reviews have looked at bone augmentation materials but not exclusively for human comparative studies for horizontal and vertical augmentation. Furthermore, the results do concur with current bone augmentation literature.

There are several limitations of this review. There were only 9 articles finally included under the stated search query and inclusion/exclusion criteria. Most of the articles (Appendix Ia and Ib) have autogenous bone as one of the compared bone materials. This resulted in less information about the relative efficacy of xenograft, allograft, and alloplast bone materials. A meta-analysis was not possible because of the low number of articles, small sample sizes, variable procedures, and short follow-up periods. These limitations have been cited in similar reviews.<sup>25</sup>

Disappointingly, the follow-up times of the selected publications ranged from 4 months postaugmentation to 16 months postloading of implants. Longer follow-up times are needed to truly assess the long-term success and failure rates of implants in the different bone graft materials' types.

As smokers were included in multiple studies in this review, it is worth discussing the clinical significance of tobacco smokers.<sup>15,19,22</sup> Smoking is associated with greater risk of alveolar bone loss around dental implants.<sup>28-32</sup> However, some articles have shown that although smoking does contribute to peri-implant bone loss, it has not been shown to be correlated with greater implant failures.<sup>33-35</sup> Thus, it is feasible to conclude that including smokers would not be a limitation of these studies.

Future directions of research should have long-term follow-up postaugmentation and postimplantation of at least 5 to 10 years. As nonautogenous bone substitutes are deemed comparable and in some respects advantageous to autogenous bone, future studies should compare nonautogenous bone substitutes to each other to determine if there are differences in vitality, osseointegration, or clinical outcomes.

### CONCLUSION

The results of this systematic review of the literature suggested no clinically significant differences between autogenous bone types and other bone substitutes in terms of implant and prosthesis survival and success. Future studies should be promoted to compare outcomes of dental implants between nonautogenous bone grafts. Longer-term follow-up studies are necessary for our future understanding and decision making in that field.

### ABBREVIATIONS

BMP: bone morphogenic protein  
DFDBA: demineralized freeze-dried bone allograft

### NOTE

The authors report no conflicts of interest.

### REFERENCES

1. Chiapasco M, Casentini P, Zaniboni M. Bone augmentation procedures in implant dentistry. *Int J Oral Maxillofacial Implants*. 2009;24:237-259.
2. Saima S, Jan S, Shah A, Yousuf A, Batra M. Bone grafts and bone substitutes in dentistry. *J Oral Res Rev*. 2016;8:36-38.
3. Kumar P, Vinitha B, Fathima G. Bone grafts in dentistry. *J Pharm Bioallied*. 2013;5:125-127.
4. Giannoudis PV, Dinopoulos H, Tsiridis E. Bone substitutes: an update. *Injury*. 2005;36:S20-S27.
5. Misch CE, Dietsch F. Bone grafting materials in implant dentistry. *Implant Dent*. 1993;2:158-167.
6. Nazirkar G, Singh S, Dole V, Nikam A. Effortless effort in bone regeneration: a review. *J Int Oral Health*. 2014;6:120-124.
7. Kao S, Scott S. A review of bone substitutes. *Oral Maxillofacial Surg Clin*. 2007;19:513-521.
8. Seth J, Aeran H, Sharma A. Bone augmentation materials: a literature review. *J Dentofacial Sci*. 2013;2:1-6.
9. Booth PW, Ward-Booth P, Eppley B, Schmelzeisen R. *Maxillofacial Trauma and Esthetic Facial Reconstruction*. Edinburgh, UK: Churchill Livingstone; 2003.
10. Richardson W, Wilson M, Nishikawa J, Hayward R. The well-built clinical question: a key to evidence-based decisions. *ACP J Club*. 1995;123:A12-A13.
11. Moher D. Preferred reporting items for systematic reviews and meta-analyses: the PRISMA statement. *Ann Intern Med*. 2009;151:264.
12. Kwon T, Bain PA, Levin L. Systematic review of short- (5-10 years) and long-term (10 years or more) survival and success of full-arch fixed dental hybrid prostheses and supporting implants. *J Dent*. 2014;42:1228-1241.
13. Annibaldi S, Cristalli MP, Dell'Aquila D, Bignozzi I, La Monaca G, Pilloni A. Short dental implants: a systematic review. *J Dent Res*. 2011;91:25-32.
14. Spin-Neto R, Stavropoulos A, Coletti FL, Faeda RS, Pereira LAVD, Marcantonio E. Graft incorporation and implant osseointegration following the use of autologous and fresh-frozen allogeneic block bone grafts for lateral ridge augmentation. *Clin Oral Implants Res*. 2013;25:226-233.
15. Felice P, Marchetti C, Iezzi G, et al. Vertical ridge augmentation of the atrophic posterior mandible with interpositional bloc grafts: bone from the iliac crest vs. bovine anorganic bone. Results up to delivery of the final prostheses from a split-mouth, randomised controlled clinical trial. *Eur J Oral Implantol*. 2008;1:183-198.
16. Fontana F, Santoro F, Maiorana C, Iezzi G, Piatelli A, Simion M. Clinical and histologic evaluation of allogeneic bone matrix versus autogenous bone chips associated with titanium-reinforced e-PTFE membrane for vertical ridge augmentation: a prospective pilot study. *Int J Oral Maxillofac Implants*. 2008;23:1003-1012.
17. Corinaldesi G, Pieri F, Marchetti C, Fini M, Aldini NN, Giardino R. Histologic and histomorphometric evaluation of alveolar ridge augmentation using bone grafts and titanium micromesh in humans. *J Periodontol*. 2007;78:1477-1484.
18. Piattelli A, Degidi M, Alessio Di Stefano D, Rubini C, Fioroni M, Strocchi R. Microvessel density in alveolar ridge regeneration with autologous and alloplastic bone. *Implant Dent*. 2002;11:370-375.
19. Merli M, Moscatelli M, Pagliaro U, Raffaelli E, Nieri M. Comparing membranes and bone substitutes in a one-stage procedure for horizontal bone augmentation: a double-blind randomised controlled trial. *Eur J Oral Implantol*. 2015;8:271-281.
20. Felice P, Marchetti C, Iezzi G, et al. Vertical ridge augmentation of the atrophic posterior mandible with interpositional bloc grafts: bone from

the iliac crest vs. bovine anorganic bone. Clinical and histological results up to one year after loading from a randomized-controlled clinical trial. *Clin Oral Implants Res.* 2009;20:1386–1393.

21. Spin-Neto R, Landazuri Del Barrio RA, Pereira LAVD, Marcantonio RAC, Marcantonio E, Marcantonio E Jr. Clinical similarities and histological diversity comparing fresh frozen onlay bone blocks allografts and autografts in human maxillary reconstruction. *Clin Implant Dent Relat Res.* 2011;15:490–497.

22. Pistilli R, Piatelli M, Nisii A, Barausse C, Esposito M. Blocks of autogenous bone versus xenografts for the rehabilitation of atrophic jaws with dental implants: preliminary data from a pilot randomised controlled trial. *Eur J Oral Implantol.* 2014;7(2):1–19.

23. Schwartz-Arad D, Levin L. Symphysis revisited: clinical and histologic evaluation of newly formed bone and reharvesting potential of previously used symphyseal donor sites for onlay bone grafting. *J Periodontol.* 2009;80:865–869.

24. Levin L, Nitzan D, Schwartz-Arad D. Success of dental implants placed in intraoral block bone grafts. *J Periodontol.* 2007;78:18–21.

25. Papageorgiou SN, Papageorgiou PN, Deschner J, Götz W. Comparative effectiveness of natural and synthetic bone grafts in oral and maxillofacial surgery prior to insertion of dental implants: systematic review and network meta-analysis of parallel and cluster randomized controlled trials. *J Dent.* 2016;48:1–8.

26. Danesh-Sani SA, Engebretson SP, Janal MN. Histomorphometric results of different grafting materials and effect of healing time on bone maturation after sinus floor augmentation: a systematic review and meta-analysis. *J Periodont Res.* 2017;52:301–312.

27. Nkenke E, Stelzle F. Clinical outcomes of sinus floor augmentation

for implant placement using autogenous bone or bone substitutes: a systematic review. *Clin Oral Implants Res.* 2009;20:124–133.

28. Uribarri A, Bilbao E, Marichalar-Mendia X, Martínez-Conde R, Aguirre JM, Verdugo F. Bone remodeling around Implants placed in augmented sinuses in patients with and without history of periodontitis. *Clin Implant Dent Relat Res.* 2017;19:268–279.

29. Levin L, Ofec R, Grossmann Y, Anner R. Periodontal disease as a risk for dental implant failure over time: a long-term historical cohort study. *J Clin Periodontol.* 2011;38:732–737.

30. Anner R, Grossmann Y, Anner Y, Levin L. Smoking, diabetes mellitus, periodontitis, and supportive periodontal treatment as factors associated with dental implant survival: a long-term retrospective evaluation of patients followed for up to 10 years. *Implant Dent.* 2010;19:57–64.

31. Levin L, Hertzberg R, Har-Nes S, Schwartz-Arad D. Long-term marginal bone loss around single dental implants affected by current and past smoking habits. *Implant Dent.* 2008;17:422–429.

32. Levin L, Schwartz-Arad D. The effect of cigarette smoking on dental implants and related surgery. *Implant Dent.* 2005;14:357–361.

33. Koszuta P, Grafka A, Koszuta A. The effect of cigarette smoking on the therapeutic success of dental implants. *Iran J Public Health.* 2016;45:1376–1377.

34. Sun C, Zhao J, Jianghao C, Hong T. Effect of heavy smoking on dental implants placed in male patients posterior mandibles: a prospective clinical study. *J Oral Implantol.* 2016;42:477–483.

35. Sakkas A, Ioannis K, Winter K, Schramm A, Wilde F. Clinical results of autologous bone augmentation harvested from the mandibular ramus prior to implant placement: an analysis of 104 cases. *GMS Interdiscip Plast Reconstr Surg DGPW.* 2016;5:Doc21. eCollection 2016.

Appendix Ia

Summary of final selected publications including follow-up, complications, main results, and observation/strength/limitation\*

Reference	Follow-up	Complications	Main Results	Observation/Strength/Limitation
Spin-Neto et al <sup>14</sup>	Mini implant was inspected 6 mo postimplantation for maxillary and 4 mo for mandibular Biopsies retrieved at 6 mo postaugmentation	1 patient had block mobility due to intrasurgical complications; 1 patient had an exposed graft at 30 d but was treated with no further complications; both patients were in the allogenic material group	Statistically significantly more vital bone ( $P = .0002$ ) and less soft connective tissue ( $P < .001$ ) in autogenous versus allogenic group Less necrotic bone was found in autogenous bone group but not statistically significant More BIC and more bone between implant threads for autogenous bone group No significant difference of BIC or bone between threads between groups	More resorption for allogenic bone was deemed to explain the less vital bone found relative to autogenous grafts; this difference is partially attributed to the different architecture of the allogenic bone Mini-implant was placed perpendicular to augmented site; no real implants Group allocation was not random as subjects with less donor intraoral bone were assigned to the allogenic group Sample was small but gave significant results Remodelling delay of allogenic grafts Nonsignificant bone loss for autogenous bone can be explained by the larger variation of the results in that group as 1 graft failed; the bovine group has less variation Authors concluded Bio-Oss to be more favorable over autogenous bone due to reduced patient discomfort 3 smokers
Felice et al <sup>16</sup>	Bone augmentation procedure to 1 mo after final prosthesis loading (14 mo postaugmentation)	Autogenous group: 1 patient had a dehiscence and a later implant exposure; 1 patient was a complete prosthesis failure Xenograft group: exposed bone which was treated without further complications	Autogenous average vertical bone height was 5.1 mm ( $P < .001$ ); bovine bone had an average bone height of 6.2 mm ( $P < .001$ ); both are gains are significant but difference between groups was not statistically significant Difference in prosthesis and implant failures was not statistically significant Bone loss for bovine was significant ( $P < .001$ ) unlike autogenous bone, however the difference in bone loss between bone groups was not significant Bio-Oss group regained mental sensitivity significantly faster (4 vs 6.3 d; $P = .03$ ) More patients preferred bovine Bio-Oss versus autogenous bone	
Fontana et al <sup>16</sup>	Postprosthetic and radiologic follow-up was 1–3 y	Autogenous bone group: 1 patient had an exposed membrane which was treated without further complication	Mean autogenous vertical bone gain = 4.7 mm (SD 0.48 mm) Mean allogenic vertical bone gain = 4.10 mm (SD 0.88 mm) Autogenous BIC = 32.8% (SD 17.43%) Allogenic BIC = 25.25% (SD 7.09%)	Small sample size thus results could not be statistically analyzed Interface between the autogenous graft and native bone was indistinguishable at certain areas of BIC Osteoid and bone marrow was present in the middle and coronal third where lamellar bone was near apical third Soft tissue layer between membrane and regenerated bone was detected in areas not filled Similar osteogenic behavior between allogenic and autogenous bone Longer follow up needed

Appendix Ia  
Continued

Reference	Follow-up	Complications	Main Results	Observation/Strength/Limitation
Corinaldesi et al <sup>17</sup>	8–9 mo post-augmentation	No complications	<p>Histomorphometric results: autogenous new bone amount: 62.38% ± 13.02%; autogenous and BPBM new bone amount: 52.88% ± 11.47% (no significant difference between groups)</p> <p>Soft tissue amount: autogenous bone 37.61% ± 13.02%; autogenous and BPBM 29.96% ± 12.58%</p> <p>Residual volume for mixed autogenous and BPBM bone was 17.16% ± 2.72%</p> <p>Percentage of bone formed in maxilla (55.21% ± 8.32%) was not significantly difference than bone formed in mandible (60.05% ± 16.49%)</p> <p>No statistical difference of new bone between groups</p> <p>Autogenous bone MVD = 25.6 ± 3.425</p> <p>Bovine Bio-Oss MVD = 29.7 ± 2.4</p> <p>Control MVD = 25.6 ± 3.43</p> <p>MVD difference between autogenous and bovine Bio-Oss groups is not statistically significant</p> <p>MVD of both groups relative to the control was statistically significant (<math>P = .023</math>)</p> <p>Slight significant difference between groups was peri-implant bone loss favoring the alloplast group</p> <p>No implant failures observed</p> <p>Pain scale was low for both groups</p>	<p>Combination of BPBM and autogenous bone did not yield a lower percentage of new bone relative to 100% autogenous bone</p> <p>BPBM particles had newly formed bone surrounding them; potentially osteoconductivity is observable.</p> <p>Different times of implant placement for each group: implants placed 3 mo for autogenous bone and 6 mo for Bio-Oss due to faster resorption times</p>
Piatelli et al <sup>18</sup>	NA			
Merli et al <sup>19</sup>	6 mo postloading (12 mo postaugmentation) 1 y and 3 y postloading data will be in successive publications	<p>Bovine Bio-Oss—3 complications: (1) dehiscence of mucosa at 90 d after surgery; (2) purulent exudate 60 d after surgery; (3) tingling and hyposensitivity 7 d after surgery</p> <p>Synthetic resorbable bone group: dehiscence of mucosa 30 d after surgery, and 2 incidents of purulent exudate 14 d after surgery</p> <p>No significant difference of complications between the groups</p> <p>No failures</p> <p>No significant difference in complications and failures between groups</p> <p>Autogenous bone group: 1 augmentation failure, 1 prosthesis failure, 2 implant failures, 1 peri-implantitis, 2 infections</p> <p>Bovine Bio-Oss group: 1 prosthesis failure, 1 implant failure, 1 soft tissue dehiscence</p>	<p>Synthetic resorbable bone resorption is 6–18 mo whereas Bio-Oss resorption is questionable.</p> <p>4 smokers in bovine Bio-Oss group and 3 smokers in synthetic resorbable bone group</p>	
Felice et al <sup>20</sup>	Follow up was 3 wk, 6 wk and 3 mo postaugmentation. Followed up 1 y after Felice et al <sup>15</sup> (16 mo postloading)		<p>Significantly more residual graft in the bovine (Bio-Oss) group (10–13%) (<math>P = .009</math>)</p> <p>1 y postloading both groups lost statistically significant amounts of peri-implant marginal bone but no significant differences between groups (autogenous bone group: 0.83 mm; bovine Bio-Oss group: 0.59 mm)</p>	<p>Variable implant brands were used between patients</p> <p>Small sample size yet significant results still produced 3 smokers (less than 15 cigarettes/d)</p> <p>Xenograft requires less invasive procedures for patient and thus may be preferable as both groups have similar results</p>



Appendix Ia  
Continued

Reference	Follow-up	Complications	Main Results	Observation/Strength/Limitation
Spin-Neto et al <sup>21</sup>	Biopsied 7 mo postaugmentation.	No complications	Delayed remodeling in the allogenic group Clear interface between allogenic graft and native bone but difficult to distinguish interface between autogenous graft and native bone Less vessel penetration in allogenic bone Pain: 14 autogenous patients had moderate pain and 6 xenograft patients had moderate pain 3-6 d 10 iliac crest patients and 1 Xenograft patient had moderate pain at 10 days 14 patients harvested iliac crest were hospitalized for 3.1 nights vs 7 patients for 1.4 nights Total infirmity days: autogenous: 126 d; xenograft: 23 Partial infirmity days: autogenous: 220 d; xenograft: 93 Patients fully satisfied with prosthesis function: autogenous: 17; xenograft: 19 Patients satisfied with prostheses aesthetics: autogenous: 18; xenograft: 12	Maxilla only Patients received 1-6 grafts. Autogenous bone is overall more vascular and integrated in a shorter time
Pistilli et al <sup>22</sup>	4 mo postloading of implants	Autogenous group: 1 implant failure Xenograft group: 11 implant failures in 4 patients Prosthesis delay: 1 in autogenous group; 4 in xenogenic group Complications: 4 in autogenous group; 15 in 12 xenograft patients 7 consecutive failures occurred with xenograft treated mandibles 10 total graft failures (equine and mandibular) and 3 partial graft failures (all maxillary; 2 equine and 1 iliac crest)		No differences between outcomes of 2 centers with exception of prosthesis failures and complication Patients grouped as non-smokers, moderate smokers (under 10 cigarettes/d) and heavy (over 10 cigarettes/d) Different healing times—4 mo for autogenous graft and 7 mo for xenografts Difference of autogenic bone site (iliac crest vs ramus) was based on patient donor capacity and needs Mandibular atrophied patients were no longer recruited due to consecutive failures More smokers in xenograft group vs autogenous group Iliac crest was used for harvesting if more than 10 mL of autogenous bone was needed.

\*M indicates male; F, female; NA, not applicable; BIC, bone-implant contact; BPBM, bovine porous bone mineral; MVD, micro-vessel density.

Appendix 1b

Summary of final selected publications including population total, average age, sex, population characteristics, compared materials, procedure, and outcome\*

Reference	Population Total	Average Age (Range)	Sex	Population Characteristics	Compared Materials	Procedure	Outcome
Spin-Neto et al <sup>14</sup>	34	47 (27–29)	12 M; 22 F	At least 1 site with <4 mm deficiency of alveolar ridge width and need regular-sized implant	Autogenous (ramus) Allogenic (fresh frozen bone)	Lateral ridge augmentation Implants placed, biopsies retrieved, and mini-implants placed 6 mo postaugmentation Healing abutment placement done 4 mo later for mandible and 6 mo later for maxilla; mini-implants were retrieved From the total, 12 allogenic and 8 autogenous subjects had mini-implants placed to assess BIC and amount of bone between threads of implant	Vital bone; necrotic bone; soft tissue; BIC; bone between implant threads
Felice et al <sup>16</sup>	10	NA	4 M; 6 F	Bilateral partial edentulism in posterior mandible with 5–7 mm residual bone height and at least 5 mm thickness above alveolar canal	Autogenous bone (iliac crest) Xenograft (anorganic bovine blocks [Bio-Oss])	Posterior mandible interpositional block grafts Vertical augmentation for 2 implants per side 38 total implants placed	Prosthesis failure Implant failure Biological or prosthetic complication Patient preference Peri-implant bone height Vertical bone gain Recovery time (days) Vertical bone gain Biologic complications BIC
Fontana et al <sup>16</sup>	5	55 (47–66)	All F	Bilateral posterior mandibular partial edentulism in whom vertical bone augmentation was needed for esthetics or function Subjects had a vertical defect greater than 3 mm.	Autogenic bone (retromolar region) Allogeneic bone (DFDBA)	2 stage bilateral vertical ridge augmentation Split-mouth design approach with titanium reinforced e-PTFE membrane Guided bone regeneration techniques 25 implants total: 13 autogenic and 12 allogenic	Mean total bone volume Residual graft volume Soft tissue
Corinaldesi et al <sup>17</sup>	12	57 (49–67) 49.33 ± 5.08 (42–55)	6 autogenous subjects (2 M; 4 F) 6 autogenous and BPBM (3 M; 3 F)	Partially edentulous patients (maxilla or mandible) requiring implants with Cawood and Howell Class V or VI defects where teeth had been extracted >6 mo previously 6 maxillary and 6 mandibular patients	Autogenous bone (ramus) 70% autogenous (ramus) and 30% BPBM	Vertical ridge augmentation with titanium micromesh Implant placed and biopsy retrieved 8–9 mo postaugmentation Prostheses placed 3 mo after implant placement for mandible and 4 mo for maxilla. Fixed implant-supported prosthesis fabricated	
Piatelli et al <sup>18</sup>	18	49 (33–62)	12 M; 6 F	At least 1 maxillary ridge defect resulting from extractions Implants placed not stated as this occurred after the study	Autogenous bone (intraoral) Xenograft (bovine Bio-Oss) Control (nonaugmented sites)	Vertical ridge augmentation with implants placed 3 months postaugmentation (autogenous bone) or 6 mo (bovine Bio-Oss) Biopsies retrieved during implant placement 18 patients had 12 autogenous and 12 Bio-Oss grafts retrieved	MVD in Haversian canals and marrow spaces of graft bone

Appendix Ib  
Continued

Reference	Population Total	Average Age (Range)	Sex	Population Characteristics	Compared Materials	Procedure	Outcome
Merli et al <sup>19</sup>	50	NA	NA	Horizontal defect due to extraction that occurred at least six weeks before implant placement Bovine Bio-Oss group: 25 patients (32 implants)	Xenograft (anorganic bovine bone Bio-Oss) with collagen porcine membrane Alloplast (synthetic resorbable bone [pure beta-tricalcium phosphate])with porcine pericardium collagen membrane	One-stage procedure for vertical and horizontal bone augmentation with porcine collagen membranes followed by implant placement Synthetic resorbable bone group: 25 patients (29 implants)	Implant failure Complications Clinical bone gain Complete filling of bony defect Chair-time Postoperative pain Peri-implant marginal bone level changes
Felice et al <sup>20</sup>	10	54 (32-73)	4 M; 6 F	Posterior mandible residual bone height between 5-7 mm and thickness of at least 5 mm above inferior alveolar canal and requires augmentation for 2 implants per side	Autogenous (iliac crest) Xenograft (anorganic bovine bone Bio-Oss)	Split mouth design and vertical augmentation via interpositional block grafts Implants placed 4 mo postaugmentation Provisional prosthesis placed 4 mo post-implant placement Definitive prosthesis 4 mo later 38 implants total (mandibular)	Vertical bone gain Prosthesis failure Implant failure Biological or prosthetic complications Peri-implant marginal bone levels
Spin-Neto et al <sup>21</sup>	12	Average age = NA Age range = 25-60 y	5 M; 7 F	Partially or totally edentulous patients needing titanium implants with at least 1 site of bone deficiency (<4 mm alveolar ridge width) 6 patients for autogenous and 6 for allografts	Autogenous (extra-oral or retromandibular region) Allograft (fresh-frozen bone)	Horizontal ridge augmentation (onlay bone grafts) followed by fixed or definitive prosthetics 40 implants placed Patients had 1 to 6 graft blocks resulting in 12 autogenous grafts and 17 allogenic grafts	Area of residual bone Interface of graft and native bone Area of unmodeled graft bone.
Pistilli et al <sup>22</sup>	40	NA	NA	Total or partially edentulous patients with less than 5 mm of crestal bone height and/or less than 3 mm bone thickness and 3 mo postextraction. Patients had to be in need of veneer or onlay block 2 moderate smokers were in autogenous (10%) 5 moderate smokers and 3 heavy smokers were equine (40%)	Autogenous (iliac crest or ramus) Xenograft (equine blocks of spongy bone) 81 implants in autogenous; 64 implants in equine bone	Horizontal and vertical augmentation Implants placed 4 mo later for autogenous bone and 7 mo later for xenografts Followed by bar-retained overdentures or provisional prostheses 4 mo later. Definitive fixed prostheses 4 mo later 28 maxillary patients (15 autogenous and 13 xenogenic) 12 mandible patients (5 autogenous and 7 xenograft) Parallel group design	Prosthesis failure Implant failure Complications Patient satisfaction Pain Hospitalization days Total and partial infirmity days

\*M indicates male; F, female; NA, not applicable; BIC, bone-implant contact; DFDBA, demineralized freeze-dried bone allograft; BPBM, bovine porous bone mineral; MVD, micro-vessel density.